



ELSEVIER

Contents lists available at [ScienceDirect](https://www.sciencedirect.com)

Trauma Case Reports

journal homepage: www.elsevier.com/locate/tcr

Case Report

Traumatic abdominal wall hernia caused by a low fall

Obteene Azimi-Ghomi^{*}, John D. Ehrhardt Jr, Shaikh Hai

Division of Trauma and Acute Care Surgery, Department of Surgery, Kendall Regional Medical Center, Miami, FL, USA

ARTICLE INFO

Keywords:

Traumatic abdominal wall hernia
Low-energy blunt trauma
Incarcerated hernia
Mesh hernia repair

ABSTRACT

Background: Traumatic abdominal wall hernias (TAWH) are uncommon injuries classically associated with high-energy blunt traumatic mechanisms. Motor vehicle collisions cause the highest proportion of all TAWH. Literature is currently limited, with some debate existing over surgical management strategies.

Case presentation: A 67-year-old man presented after falling from a short step stool while landscaping his yard. On exam, an exquisitely tender lateral flank mass was present with peristaltic movement. CT imaging revealed a TAWH with incarcerated large and small bowel. He was taken to the OR for exploratory laparotomy and mesh hernia repair. The patient was discharged on the third postoperative day with no untoward complications.

Discussion: This patient's mechanism and injury pattern are together a rare combination. Exam findings and radiologic technologies are used to hone the clinical index of suspicion for TAWH. Traumatic abdominal wall defects can have unusual anatomic borders, not always obeying well-known hernia patterns. In this case, the potential space for visceral herniation was created by an 11th rib fracture with associated avulsion of the oblique musculature. Operative approach can be open or laparoscopic, however concomitant injuries directly influence surgical management. Evidence for mesh versus primary repair for TAWH is conflicted by the current literature.

Conclusions: Nearly any amount of blunt abdominal force can cause TAWH. For wall defects with bowel herniation caused directly by trauma, the safest approach may involve exploratory laparotomy. Future multi-center studies may be able to distinguish TAWH repair strategies based on herniation through old defects versus newly-created abdominal wall injuries.

Background

Traumatic abdominal wall hernias (TAWH) are uncommon injuries which are most often associated with high-energy blunt mechanisms. Roughly 15,000 patients are affected annually in the US [1], with TAWH incidence estimated anywhere between 0.1 and 1.0% of all blunt injuries seen at designated trauma centers [2]. These figures appear to be increasing due to a higher volume of motor vehicle collisions (MVCs), as well as higher diagnosis rates with now widespread use of CT imaging in trauma. Nonetheless, a relative paucity of described cases and studies has raised questions regarding evidence-based management for TAWH. The largest series to-date came in 2016, and outlined three major surgical decisions which remain debatable within the trauma community: (1) the indication for exploratory laparotomy with TAWH, (2) whether repair is necessary for TAWH, and (3) the role of mesh in operations for TAWH repair [3].

In light of these points, this clinical report contributes a unique case and adds to the discussion on TAWH. This case emphasizes an

^{*} Corresponding author at: 11750 SW 40th St, Miami, FL 33175, USA.

E-mail address: Obteene.AzimiGhomi@HCAHealthcare.com (O. Azimi-Ghomi).

<https://doi.org/10.1016/j.tcr.2021.100572>

Accepted 5 December 2021

Available online 9 December 2021

2352-6440/© 2021 Published by Elsevier Ltd. This is an open access article under the CC BY-NC-ND license

(<http://creativecommons.org/licenses/by-nc-nd/4.0/>).

uncommon mechanism of injury, interesting physical exam findings, thoughts on patterns of injuries, and commentary on current management strategies for TAWH.

Case presentation

A 67-year-old healthy-appearing man was brought to our trauma center after sustaining a 3-foot fall from a step stool onto a tree stump, landing on his right flank, as reported by the patient himself. A sizeable mass manifested immediately after his fall. On primary survey, he was GCS 15 with airway intact, breath sounds symmetric, and pulses intact in all extremities. A large 8-cm bulge was noted over the right hemi-abdomen and lateral flank, which was exquisitely tender to palpation (Fig. 1). Peristaltic waves were noted on the skin overlying the lesion (Video supplement). CT abdomen imaging demonstrated a traumatic abdominal wall hernia containing small and large bowel (Fig. 2).

Per the patient, his only had a past medical history of hypertension controlled by medications. He denies any history of corticosteroid use, liver or renal dysfunction, collagen disorder, history of poor healing, or any metabolic or nutritional abnormalities. He denied any past surgical history, nor tobacco, alcohol, or illicit substance use.

The patient was taken emergently to the operating room for exploratory laparotomy. The herniated bowel was manually reduced and the intestines were inspected from the ligament of Treitz to the rectum. A small serosal hematoma was noted on the large bowel at the hepatic flexure, a segment which had originally incarcerated in the traumatic hernia. The remaining bowel was intact without any lesions. With the hernia defect being far from the median incision, it was deemed impractical to perform the repair from midline. A second incision was made overlying the defect, which was now dissected and localized between the right 11th and 12th ribs, which had fractured, and the external and internal oblique muscles which had avulsed anteriorly from the floating ribs (Fig. 3A). The underlying peritoneum was closed using running absorbable vicryl suture. We tailor-cut a repair from a 15 × 15-cm polypropylene mesh to fit the defect, which was secured at three points with permanent suture: the 11th rib periosteum, as well as the external and internal oblique fasciae (Fig. 3B). Torn oblique musculature was re-approximated to the floating ribs with interrupted absorbable sutures. The TAWH was anterior enough that the entire repair could be conducted with the patient in supine position. The subcutaneous tissues were closed over a flat drain positioned over the repair. The median laparotomy incision was closed in the usual fashion. The patient was extubated and taken to medical-surgical floor after anesthesia recovery. Oral diet was started on post-operative day 1, and the drain was removed on post-operative day 2. The patient was subsequently discharged post-operative day 3, with his pain well-controlled and tolerating diet well.

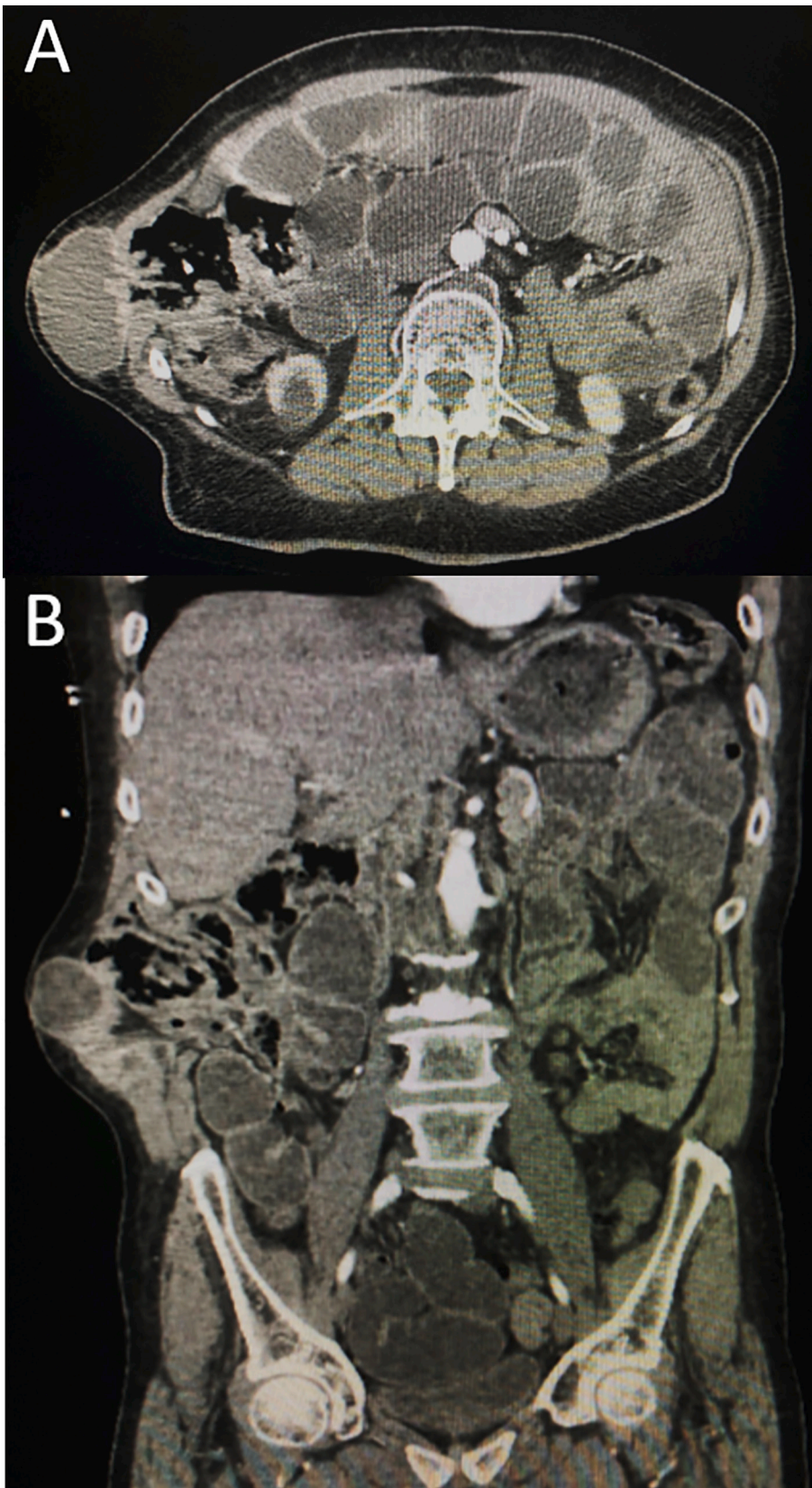
Discussion

We present a case of a patient who sustained a traumatic flank hernia with incarcerated large and small bowel. Several aspects of this case deserve elaboration, including mechanism of injury, physical exam findings, location of hernia defect, and operative decision-making.

The common denominator in nearly all TAWH is the creation of an abdominal wall defect in the setting of direct or indirect blunt

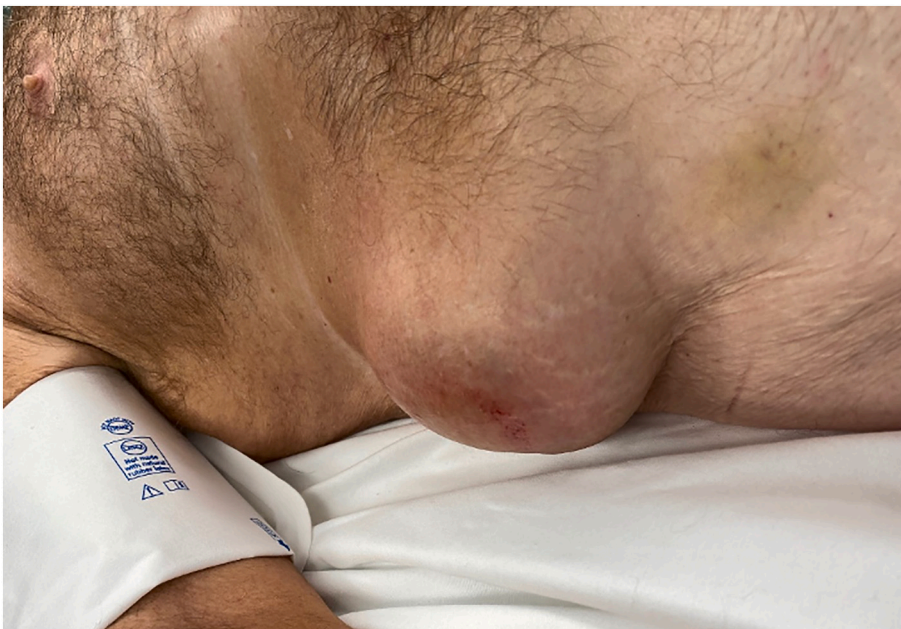

Fig. 1. Right lateral abdominal bulging mass noted on physical exam.



(caption on next page)

Fig. 2. CT abdomen-pelvis imaging, (A) axial, and (B) coronal slices, demonstrating the TAWH containing both small and large bowel.

trauma. This often occurs simultaneously with increased intra-abdominal pressure, resulting in visceral herniation. The mechanism of injury in this case was notable in that the patient fell from 3 ft from a low step stool, an event not generally associated with high morbidity. Many published cases have emphasized high-energy blunt traumatic mechanisms, most often characterized by motor vehicle collisions (MVCs) in adults [4,5], as well as bicycle handle bar injuries in children [6,7]. Several retrospective reviews have established motor vehicle collisions as the most common cause of TAWH [1–3], with deceleration against a seatbelt creating supra-physiologic abdominal pressure responsible for injury. Descriptive analyses from recent years have categorized falls from height as accounting for approximately 5% of cases [3]. Most falls which resulted in TAWH were from higher structures, like roofs and scaffolds, which create higher forces from the acceleration of gravity than the low fall our patient endured.

TAWH have been viewed as curiosities in the surgical literature for well over a century. Ohio surgeon Clarence Selby provided the first clinical description for TAWH in 1906 [8]. His patient fell from a scaffolding with a wheelbarrow, and sustained a traumatic flank hernia in a similar manner to our patient. Modernized classification schemes emerged much later, some emphasizing anatomical location of TAWH [9,10]. One system proposed by Wood in 1988 blended mechanism of injury with size of defect, forming three major categories of TAWH: (1) small lower quadrant abdominal defects and inguinal hernias, those typically from blunt trauma with bicycle handlebars; (2) larger abdominal wall defects sustained in motor vehicle collisions, and (3) intra-abdominal herniations through rents in the retroperitoneum [11]. More recently, these injuries were subdivided by causation into low-energy and high-energy mechanisms, as this dictum helps guide operative management [12]. Low energy injuries occur after impact on a blunt object, as in the present case. High-energy injuries are sustained during motor vehicle accidents or automobile versus pedestrian accidents [3,12].

Preexisting abdominal wall defects may make visceral herniation more likely, representing a confounder in the trauma literature. Old hernias can certainly come to clinical attention as TAWH, harboring new or exacerbated hernia contents after trauma. It would be expected that in those cases, newly herniated contents would follow weaknesses along classically described anatomic borders, such as ventral, inguinal, and lumbar hernias. Other times, like in the present case, the trauma itself produced an abdominal wall defect, namely a fractured floating rib and avulsed oblique musculature, which was followed by bowel herniation. Flank hernias comprised 47.5% of all TAWH in one large retrospective analysis [3]. In these cases, muscular avulsion from bony structures causes abdominal wall injury (AWI), an event for which the flank has two prime locations: the ilium, and the floating ribs. Descriptive analysis has found that traumatic flank defects are more common in the lower quadrants, near the ileum, than in the upper quadrants at the margins of the lower ribs [3].

Diagnosis can be suspected in the presence of an abdominal or flank bulge with tenderness and ecchymosis. There are several physical exam and radiologic clues which can be used to guide diagnosis. Careful attention may reveal peristalsis of the hernia contents visualized through the abdominal wall. The presence or absence of peristalsis in abdominal wall lesions is not diagnostic, but the phenomenon is rarely discussed in trauma and can greatly aid in diagnosis. Traumatic hernia contents will be exquisitely tender to palpation, in contrast to other lesions, like subcutaneous hematomae. Bowel sounds may be present on auscultation. Radiologic technologies can be used to build supporting evidence towards diagnosis, including abdominal radiographs, direct ultrasonography, and Doppler signaling [13]. Above all, CT imaging is the diagnostic gold standard [1,3,12]. A roman-numeric I-VI grading system exists for AWIs based on CT imaging, with grades V-VI representing those with visceral herniation, and evisceration, respectively [14]. In the austere clinical setting without CT scanner availability, the aforementioned physical exam findings and adjunct radiographic modalities can be used to build evidence required to take a patient to the operating room.

Due to a paucity of information regarding TAWH, operative management should be tailored to clinical presentation, mechanism, associated injuries, concern for bowel viability, and hemodynamic stability. Timing of repair has been a point of debate, with current consensus being that the patient's concomitant injuries and condition should be the primary determinant to whether repair should be performed in an acute or delayed setting [15].

Low energy TAWH are generally not associated with intra-abdominal injuries, and can often be repaired after local exploration through an incision overlying the defect. If there is any suspicion of intestinal injury or peritonitis, an exploratory laparotomy should be performed to assess intestinal viability prior to repair [15]. For patients with equivocal findings, diagnostic laparoscopy can play an important role and guide further decision-making. In our case, the decision for laparotomy was made based on the large herniation of small and large bowel, which had become markedly edematous and incarcerated in the abdominal wall defect, bringing concerns for bowel injury. Mesh repair is recommended in the absence of intestinal injury [15]. After reduction and examination of the bowel in our case, a modest colonic serosal hematoma informed our decision for mesh repair.

High-energy TAWH should undergo exploratory laparotomy as these injuries have a high association with bowel injury and need for resection, with rates of 44–49% in the literature [1,3,15]. Prosthetic repair is typically avoided in these cases due to the high incidence of post-operative infection. Given these limitations, defects caused by high-energy mechanisms are usually repaired in a primary fashion.

Recurrence rates in TAWH repairs are high, with literature reviews demonstrating recurrence rates anywhere between 13 and 37.5% [1,3,15]. A retrospective review noted that 70% of these recurrences are seen in TAWH repaired in a primary fashion, however pooled analysis has demonstrated no statistical significant difference between primary and mesh repair [15]. It would be interesting if future studies evaluated TAWH recurrence based on whether the abdominal wall defect was believed to be pre-existing versus a product of acute trauma, a confounder described above. Another factor not incorporated into data on hernia recurrence are other comorbidities, like obesity, tobacco use, metabolic syndromes, and other variables, most of which are rarely controlled for in studies focused on the success of operations for acute trauma.

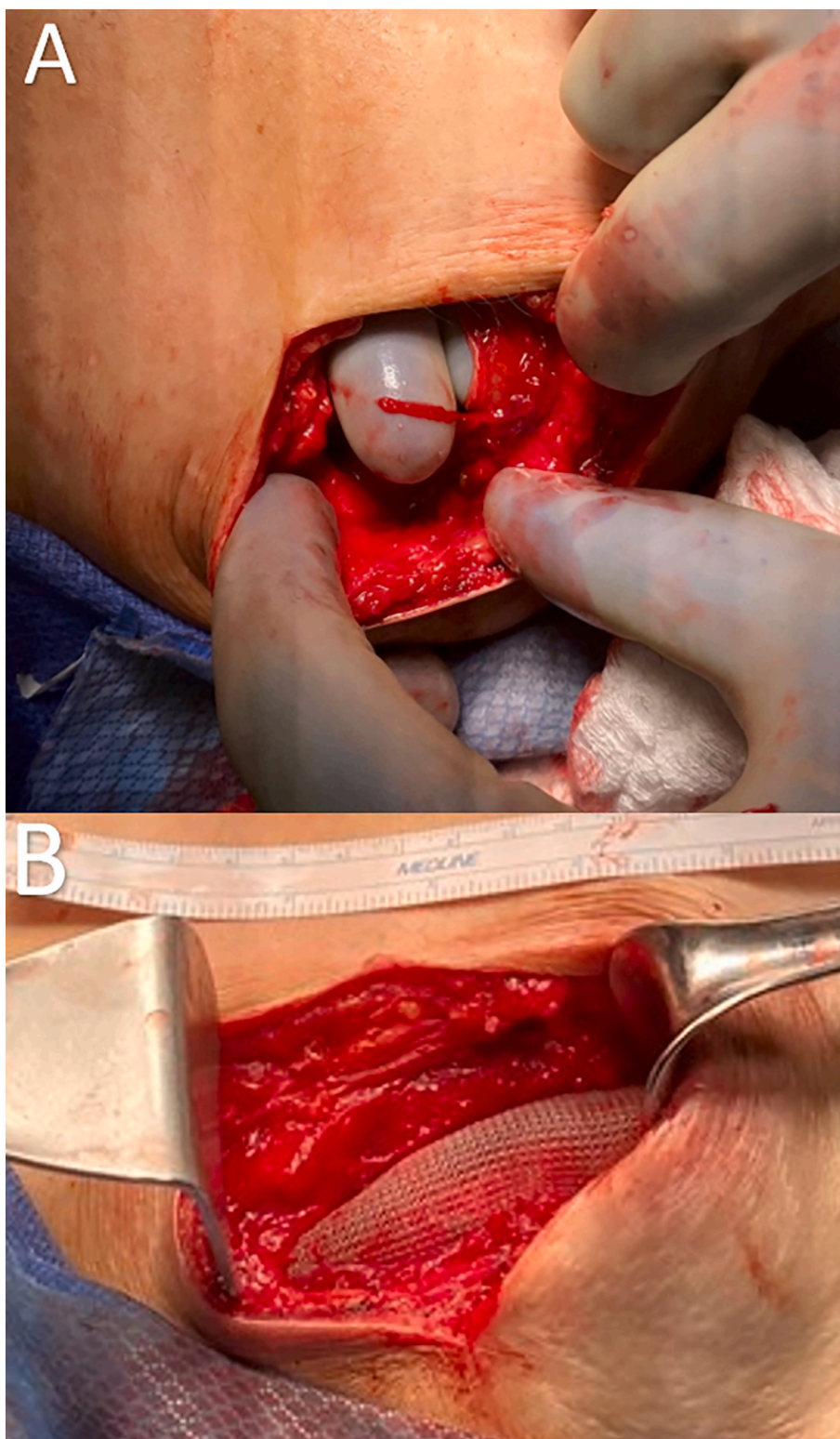


Fig. 3. (A) Incision overlying the traumatic abdominal wall hernia defect after reduction of herniated viscera, (B) polypropylene mesh repair of the TAWH.

Supplementary data to this article can be found online at <https://doi.org/10.1016/j.tcr.2021.100572>.

References

- [1] F.A. Netto, P. Hamilton, S.B. Rizoli, et al., Traumatic abdominal wall hernia: epidemiology and clinical implications, *J. Trauma* 61 (5) (2006) 1058–1061.
- [2] L. Liasis, I. Tierris, F. Lazarioti, C.C. Clark, H.T. Papaconstantinou, Traumatic abdominal wall hernia: is the treatment strategy a real problem? *J. Trauma Acute Care Surg.* 74 (4) (2013) 1156–1162.
- [3] J.J. Coleman, E.K. Fitz, B.L. Zarzaur, et al., Traumatic abdominal wall hernias: location matters, *J. Trauma Acute Care Surg.* 80 (3) (2016 Mar) 390–396, discussion 396–397.
- [4] F.D. Brenneman, B.R. Boulanger, O. Antonyshyn, Surgical management of abdominal wall disruption after blunt trauma, *J. Trauma* 39 (1995) 539–544.
- [5] K.L. Kileen, S. Girard, J.H. DeMeo, et al., Using CT to diagnose traumatic lumbar hernia, *AJR* 174 (2000) 1413–1415.
- [6] L.A. Griffin, V.C. Scogletti, T.C. Nolan, et al., Traumatic abdominal wall hernia from a handlebar injury, *Am. Surg.* 79 (5) (2013 Apr) E192–E193.
- [7] A.J. van Bommel, A.G. van Marle, P.M. Schlejen, et al., Handlebar hernia: a case report and literature review on traumatic abdominal wall hernia in children, *Hernia* 15 (2011) 439–442.
- [8] C.D. Selby, Direct abdominal hernia of traumatic origin, *JAMA* 47 (1906) 1485–1486.
- [9] A. Clain, Traumatic hernia, *Br. J. Surg.* 51 (1964) 549–550.
- [10] H.R. Guly, I.P. Stewart, Traumatic hernia, *J. Trauma* 23 (3) (1983) 250–252.
- [11] R.J. Wood, A.L. Ney, M.P. Bubrick, Traumatic abdominal hernia: a case report and review of the literature, *Am. Surg.* 54 (11) (1988 Nov) 648–651.
- [12] C.T. Lane, A.J. Cohen, M.E. Cinat, Management of traumatic abdominal wall hernia, *Am. Surg.* 69 (1) (2003 Jan) 73–76.
- [13] F. Lassandro, F. Lasiello, N.L. Pizza, et al., Abdominal hernias: radiographic features, *World J. Gastrointest. Endosc.* 3 (6) (2011 Jun) 110–117.
- [14] R.W. Dennis, A. Marshall, H. Deshmukh, et al., Abdominal wall injuries occurring after blunt trauma: incidence and grading system, *Am. J. Surg.* 197 (3) (2009 Mar) 413–417.
- [15] S. Karhof, R. Boot, R.K.J. Simmermacher, et al., Timing of repair and mesh use in traumatic abdominal wall defects: a systematic review and meta-analysis of current literature, *World J. Emerg. Surg.* 17 (14) (2019 Dec) 59.