

Short-term Preoperative Octreotide for Thyrotropin-secreting Pituitary Adenoma

Hong-Juan Fang¹, Yu Fu¹, Huan-Wen Wu², Yi-Lin Sun³, Yang-Fang Li⁴, Ya-Zhuo Zhang⁴, Li-Yong Zhong¹

¹Department of Endocrinology, Beijing Tiantan Hospital, Capital Medical University, Beijing 100050, China

²Department of Pathology, Peking Union Medical College Hospital, Peking Union Medical College, Chinese Academy of Medical Sciences, Beijing 100730, China

³Department of Ultrapathology, Beijing Neurosurgical Institute, Capital Medical University, Beijing 100050, China

⁴Beijing Neurosurgical Institute, Beijing Institute for Brain Disorders, Brain Tumor Center, Beijing Tiantan Hospital, Capital Medical University, Beijing 100050, China

Abstract

Background: Thyrotropin-secreting pituitary adenomas (TSHomas) are a rare cause of hyperthyroidism. Somatostatin (SST) analogs work by interacting with somatostatin receptors (SSTRs). This study aimed to evaluate short-term preoperative octreotide (OCT) use in TSHoma patients and to investigate SSTR2 and SSTR5 expression and observe structural changes in tumor tissue.

Methods: We reviewed records and samples from eight TSHoma patients treated between July 2012 and July 2015. We tested immunohistochemically for SSTR2/5 expression and examined TSHoma cells for morphological changes. Signed rank sum test was used to compare the efficacy of short-term preoperative OCT treatment.

Results: OCT treatment (median time: 7.9 days, range: 3–16 days; median total dose: 1.8 mg, range: 0.9–4.2 mg) led to significant decrease in all patients' thyroid hormone levels (FT3 [nmol/L]: 8.33 [7.02, 12.29] to 4.67 [3.52, 5.37] [$P = 0.008$]; FT4 [pmol/L]: 25.36 [21.34, 28.99] to 16.66 [14.88, 21.49] [$P = 0.016$]; and TSH [$\mu\text{U/ml}$]: 5.80 [4.37, 6.78] to 0.57 [0.19, 1.24] [$P = 0.008$]). All the eight tumor specimens expressed high SSTR2 protein levels; 5/8 expressed high SSTR5, but 3/8 that expressed low SSTR5 presented a significantly higher TSH suppression rate ($P = 0.036$). Electron microscopy showed subcellular level impairments, including clumped nuclear chromatin and reduced cytoplasmic volume. Golgi complexes were observed in the OCT-treated TSHoma specimens.

Conclusions: OCT can control hormone levels and damage the ultrastructure of tumor cells and organelles. Short-term response to OCT may be related to SSTR5 expression. Preoperative SST analog treatment for TSHoma could be considered as a combination therapy.

Key words: Electron Microscopy; Somatostatin Analogs; Somatostatin Receptor; Therapy; Thyrotropin-secreting Pituitary Adenoma

INTRODUCTION

Thyrotropin-secreting pituitary adenomas (TSHomas) account for only 0.5–3.0% of all functioning pituitary adenomas.^[1-4] These tumors may cause hyperthyroidism through inappropriate secretion of TSH, which can also lead to perioperative thyroid storm.^[5] Thus, thyroid hormone (TH) levels need to be preoperatively controlled for these patients. The first-line therapy for TSHoma is neurosurgery, yet surgical cure rates vary reportedly around only 50–60%.^[6-10] TSHomas are often invasive and fibrous which hamper complete removal; somatostatin (SST) analogs are therefore primarily used in palliative care or for patients who were not cured by surgery. The role of somatostatin receptors (SSTRs) as therapeutic targets in pituitary adenomas is well established.^[11] SST analogs are

reportedly effective in hormonal control of TSHomas and growth hormones (GH)-secreting adenomas.^[1,12,13]

SSTR have five subtypes (SSTR1–5) – mostly SSTR2 and SSTR5 – those are widely expressed in both normal and neoplastic human pituitary cells.^[14] Understanding of the highly variable expression of SSTR subtypes in pituitary adenomas has risen sharply in recent years. Interactions between ligands and receptors serve as the molecular

Address for correspondence: Dr. Li-Yong Zhong,

Department of Endocrinology, Beijing Tiantan Hospital, Capital Medical University, Beijing 100050, China
E-Mail: zhongliyong@126.com

This is an open access article distributed under the terms of the Creative Commons Attribution-NonCommercial-ShareAlike 3.0 License, which allows others to remix, tweak, and build upon the work non-commercially, as long as the author is credited and the new creations are licensed under the identical terms.

For reprints contact: reprints@medknow.com

© 2017 Chinese Medical Journal | Produced by Wolters Kluwer - Medknow

Received: 28-11-2016 **Edited by:** Yuan-Yuan Ji

How to cite this article: Fang HJ, Fu Y, Wu HW, Sun YL, Li YF, Zhang YZ, Zhong LY. Short-term Preoperative Octreotide for Thyrotropin-secreting Pituitary Adenoma. Chin Med J 2017;130:936-42.

Access this article online

Quick Response Code:



Website:
www.cmj.org

DOI:
10.4103/0366-6999.204098

basis of drug-targeting therapy. Therefore, the expression profile of SSTR subtypes in pituitary adenomas would be helpful to know. Octreotide (OCT), a clinically available SSTR2-preferring analog, normalizes hormone levels for approximately 90% of TSHoma patients,^[15,16] yet its preoperative use is rarely reported.^[17]

In our center, patients with TSHoma are started on short-term preoperative SST analog to restore euthyroidism before transsphenoidal surgery as a definitive therapy. To probe into the underlying mechanisms of OCT in TSHoma treatment, we assessed the outcomes of short-term preoperative OCT treatment for patients with TSHoma and investigated SSTR2 and SSTR5 expression by immunohistochemistry (IHC) in tumor specimens, as well as their subcellular characteristics at electron microscopy, aiming at providing evidence for TSHoma medical therapy.

METHODS

Patients

We included eight patients (six men and two women) who were diagnosed with TSHoma in the Department of Endocrinology, Beijing Tiantan Hospital, between July 2012 and July 2015, based on their combinations of typical signs and symptoms of hyperthyroidism and/or intracranial compression (e.g., visual loss, headache, nasal obstruction, and hypopituitarism); unsuppressed TSH levels with elevated TH levels; evidence of a pituitary tumor by imaging; and confirmation by pathological diagnosis. Patients with resistance to TH syndrome were excluded from the study. All participants gave written informed consent and the study was approved by the Institutional Ethical Review Board of Beijing Tiantan Hospital (No. KY2013-015-02). Sanger sequencing was used to search for point mutations and deletions in the thyroid hormone receptor (TR) β gene, but no definite pathogenic mutations were found. Pituitary adenoma tissues were obtained from the patients at the time of transsphenoidal surgery. Medical records of all the patients were thoroughly reviewed in terms of their sexes, ages at diagnosis, pathological diagnoses, tumor sizes, and dates of their last follow-ups.

Therapy

OCT used in this investigation was obtained from Novartis Pharmaceuticals Corporation (East Hanover, NJ, USA). Each patient received an initial dose of 100 μg , injected subcutaneously at 8:00 a.m. If the patient showed no obvious side effects (such as nausea, vomiting, stomach ache, and diarrhea), dosages were increased to 100 μg 2 or 3 times/day. Serum TSH, free triiodothyronine (FT3), free thyroxin (FT4), total triiodothyronine (TT3), and total thyroxin (TT4) concentrations were measured by chemiluminescent enzyme assays using commercially available kits. The following formula was used to determine TSH suppression rate: TSH suppression rate (%) = (before treatment – after treatment)/before treatment \times 100%.

Immunohistochemistry methods

Serial 4- μm -thick sections were cut from formalin-fixed and paraffin-embedded pituitary adenoma tissues and used for histological diagnosis and IHC staining for SSTR2 and SSTR5. For adenoma classification, specimens were subjected to routine IHC staining with monoclonal antibodies against TSH, adrenocorticotrophic hormone, growth hormone, luteinizing hormone, follicle-stimulating hormone, and prolactin. Fixed in formalin, the slides were prepared in unstained 3- μm sections and 48 dot cores (diameter: 2.0 mm) matrix chip template. IHC staining was performed using a Leica BOND-III, automatic IHC and ISH stainer (Leica Biosystems, Nussloch, Germany), which was a fully automated, continuous-access IHC slide-staining system. Laboratory IHC protocols included 10-min heat-induced epitope retrieval and 15-min antibody incubation. The primary SSTR2 antibody was ab13120 (1:100), and the primary SSTR5 antibody was ab13121 (1:100; Abcam, Cambridge, UK).

Quantification of immunostaining

Sections were assessed independently by two experienced pathologists who were blinded to both clinical and pathological data. Scoring of each section was determined by consensus, by the immunoreactive score (IRS) method,^[18] which entailed multiplying staining intensity (0 = no staining, 1 = weak staining, 2 = moderate staining, and 3 = strong staining) by percentage of positively stained cells (0 = 0%, 1 = 1–33%, 2 = 34–66%, and 3 = >66%), for IRS scores ranging from 0 (no staining) to 9 (maximum staining), IRS scores of 0–4 were considered low expression and 5–9 were high expression.

Electron microscopy

Specimens from all the eight patients were examined by an electron microscope. For electron microscopy, 1-mm-thick sections were double fixed by 2.5% glutaraldehyde (by volume) and 2% formaldehyde solution for 2 h at 4°C, and then washed three times with phosphate-buffered saline (PBS).^[19,20] Samples were then fixed in 1% osmium tetroxide, washed with PBS, dehydrated in an ethanol gradient, and embedded, using fresh EMBED-812, in labeled embedding molds and polymerized. Section blocks were conformed and cut into 60-nm sections, stained in uranyl acetate and lead citrate, and their specific ultrastructure features were observed under a Hitachi H-7650 (120 kV) transmission electron microscope. As controls, we randomly selected eight sets of electron microscopy data from patients who received surgical treatment instead of OCT therapy.

Statistical analysis

SAS 9.4 (SAS Institute, Inc., North Carolina, USA) was used to analyze the data, and the statistical description of variables was shown as median (interquartile range). Signed rank sum test was used to compare the efficacy of short-term preoperative OCT treatment. Wilcoxon rank-sum test was used to investigate TSH suppression rate and SSTR5 expression. A $P < 0.05$ was considered statistically significantly different.

RESULTS

Clinical features

The study included eight patients (6 men and 2 women) with TSHoma whose average age was 39.8 years (range: 25–52 years). Their average duration of symptoms was 2.6 years (range: 2 months–7 years). Magnetic resonance imaging showed one patient with microadenoma and seven with macroadenoma [Table 1]. All the eight patients had unsuppressed TSH levels with elevated TH levels; neuroimaging revealed pituitary lesions.

All the patients showed various thyrotoxicosis symptoms with goiters, including palpitations, excessive sweating, fatigue, and weight loss; five also exhibited symptoms of intracranial compression, including paroxysmal headache and blurry vision. All seven patients who had received

thyroid ultrasonography had presented with thyroid nodule disease. Patient 3 had been misdiagnosed with Graves' disease and treated with antithyroid drugs (thiamazole) irregularly for 2 years. Patient 4 had been misdiagnosed with Hashimoto's thyroiditis for 3.5 years, but had received no treatment before his TSHoma diagnosis. Patient 8 presented with high levels of TSH receptor antibodies and antithyroid peroxidase antibodies associated with hyperthyroxinemia and – unexpectedly – normal TSH values.

Effects and safety of short-term octreotide treatment

Short-term preoperative OCT administration was highly effective in normalizing excessive hormone concentrations, with tolerable side effects. After OCT treatments for a median of 7.9 days (range: 3–16 days) and with a total median dose of 1.8 mg (range: 0.9–4.2 mg), all patients presented significant decreased TSH and TH levels (FT3 [nmol/L]:

Table 1: Clinical characteristics of eight patients with TSHomas

Case number	Sex	Age (years)	IRS		Therapy dose (mg)	Time days	Medical therapy	TSH 0.35–4.94 (μU/ml)
			SSTR2	SSTR5				
1	Male	31	9	6	4.2	16	Before	4.32
							After	0.58
2	Male	52	9	6	1.2	6	Before	4.52
							After	0.77
3	Male	33	9	6	1.9	8	Before	6.84
							After	6.08
4	Male	51	9	6	2.2	11	Before	1.76
							After	0.57
5	Male	25	9	6	0.9	3	Before	6.61
							After	1.40
6	Female	27	9	2	1.2	6	Before	5.21
							After	0.12
7	Male	52	9	6	1.7	6	Before	7.36
							After	0.13
8	Female	47	9	3	1.3	7	Before	6.39
							After	0.36

Case number	FT3 2.63–5.70 (pmol/L)	FT4 9.00–19.04 (pmol/L)	Tumor size (mm ³)	Thyroid ultrasonography	Misdiagnose
1	8.43	25.00	9×6×8	Multiple thyroid cyst, thyroid parenchymal echo pattern heterogeneous	–
	3.63	16.02			
2	10.23	25.72	11×12×10	Thyroid parenchymal echo pattern heterogeneous	–
	4.52	17.30			
3	5.93	21.69	32×28×25	Multiple thyroid cyst, thyroid parenchymal echo pattern heterogeneous	Misdiagnose GD
	4.82	21.94			
4	8.22	28.12	16×14×18	Unexamined	Misdiagnose HT
	2.28	12.12			
5	40.96	52.27	48×44×29	Thyroid gland with diffuse lesion, thyroid nodules, and thyroid cyst	–
	15.37	24.16			
6	6.68	21.22	17×18×12	Multiple thyroid nodules	–
	4.97	15.01			
7	8.03	20.06	15×17×23	Multiple thyroid nodules	–
	3.48	14.84			
8	12.98	29.28	18×18×16	Multiple thyroid nodules	Coexistence with GD
	5.49	20.14			

SSTR: Somatostatin receptor; IRS: Immunoreactive score; TSH: Thyroid-stimulating hormone; FT3: Free triiodothyronine; FT4: Free thyroxin; GD: Graves' disease; HT: Hashimoto's thyroiditis; TSHoma: Thyrotropin-secreting pituitary adenoma.

8.33 [7.02, 12.29] to 4.67 [3.52, 5.37] [$P = 0.000$]; FT4 [pmol/L]: 25.36 [21.34, 28.99] to 16.66 [14.88, 21.49] [$P = 0.016$]; and TSH [$\mu\text{U/ml}$]: 5.80 [4.37, 6.78] to 0.57 [0.19, 1.24] [$P = 0.008$] [Table 2]. Reference ranges are TSH: 0.35–4.94 $\mu\text{U/ml}$; FT3: 2.63–5.7 nmol/L; and FT4: 9.00–19.04 pmol/L.

Safety of treatment with SST analogs was proven; no patients discontinued treatment due to unbearable side effects although patient 4 suffered diarrhea for 2 days, for which his OCT dose was reduced to 100 μg one time/day for 11 days.

Relationship between somatostatin receptor expression and thyrotropin suppression rate

Patients' histology examinations showed positive staining for TSH, thus confirming the diagnoses of TSHoma [Figure 1]. The IHC staining for SSTR2 and SSTR5 was positive in the cytoplasm, and notably, greater for SSTR2 than SSTR5 in TSHoma. All patients showed high SSTR2 immunoreactivity (IRS 9), yet with heterogeneous and less intense staining for SSTR5 (SSTR5 IRS: 5/8 high and 3/8 low). Due to small sample size, we saw no significant relationships between the TSH suppression rate and patients' age, sex, tumor size, or treatment dosage; however, TSH suppression rate and SSTR5 expression were significantly related [$P = 0.036$, Table 3].

Tumor cells observed by electron microscopy

Ultrastructurally, well-differentiated adenomatous thyrotrophs resemble normal ones, whereas poorly

differentiated adenomas were composed of elongated angular cells with irregular nuclei, poorly developed rough endoplasmic reticulum, long cytoplasmic processes, and sparse small secretory granules (50–200 nm) that mostly line up along the cell membrane [Figure 2]. Compared with the normal specimens, those from patients treated with OCT showed changes (to varying degrees) in such tumor subcellular structure as mitochondrial swelling, dilatation of endoplasmic reticulum, vacuole formation, membrane dissolution and fracture, blurring of nucleus and organelle, cell disintegration, and thickened vascular basal lamina. Characteristic apoptotic morphological changes were seen in TSHoma cells after treatment with OCT under transmission microscope. Various types of damages were found at organelles and subcellular level, and decreased secretion activity in OCT-treated tumor cells, which contribute to tumor shrinkage due to long-term actions of OCT.

DISCUSSION

TSHoma is a rare lesion of the endocrine system, which favors no particular age group and neither sex.^[13] TSHoma and primary hyperthyroidism share some symptoms of thyrotoxicosis and diffuse enlargement of the thyroid gland.^[21] TSH secretion is autonomous and refractory to negative feedback by THs (inappropriate TSH secretion). TSH itself can hyperstimulate the thyroid gland and lead to hypersecretion of T4 and T3. The differential diagnosis of inappropriate TSH secretion includes nonthyroidal

Table 2: Comparison of thyroid function before and after short-term octreotide treatment ($n = 8$)

Thyroid hormone	Before	After	P
TT3 (nmol/L)	3.27 (2.66–4.08)	1.59 (1.25–1.86)	0.008
TT4 (nmol/L)	169.42 (148.75–201.77)	110.99 (95.88–143.36)	0.008
FT3 (pmol/L)	8.33 (7.02–12.29)	4.67 (3.52–5.37)	0.008
FT4 (pmol/L)	25.36 (21.34–28.99)	16.66 (14.88–21.49)	0.016
TSH ($\mu\text{U/ml}$)	5.80 (4.37–6.78)	0.57 (0.19–1.24)	0.008

Data were shown as median (interquartile range). TT3: Total triiodothyronine; TT4: Total thyroxine; FT3: Free triiodothyronine; FT4: Free thyroxine; TSH: Thyroid-stimulating hormone.

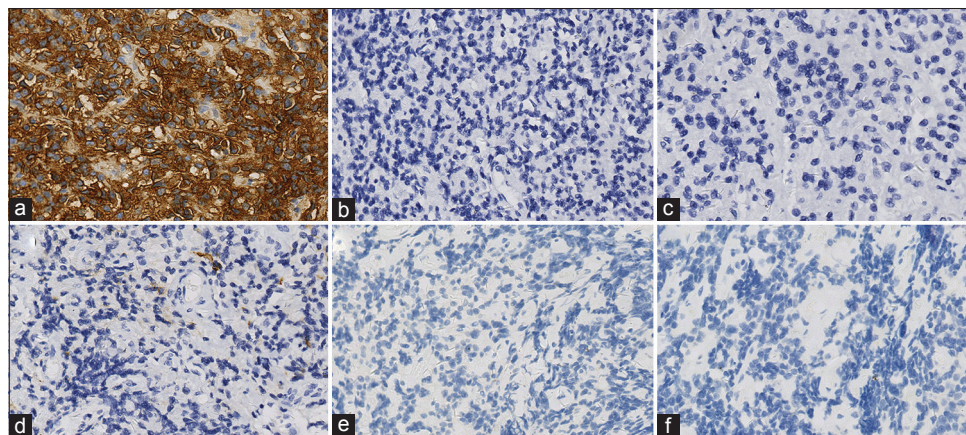


Figure 1: Immunohistochemistry of TSHoma tissue samples (original magnification $\times 200$). (a) Strong staining for TSH. (b) Negative for adrenocorticotropic hormone. (c) Negative for growth hormone. (d) Negative for luteinizing hormone. (e) Negative for follicle-stimulating hormone. (f) Negative for prolactin. TSHoma: Thyrotropin-secreting pituitary adenoma; TSH: Thyrotropin.

Table 3: Relationship between thyroid-stimulating hormone suppression rate and SSTR5 expression (n = 8)

Case number	SSTR5 expression*	TSH suppression rate (%)
1	High	86.68
2	High	82.97
3	High	11.07
4	High	67.37
5	High	78.85
6	Low	97.79
7	Low	98.22
8	Low	94.33

*Low expression: 0–4; High expression: 5–9. TSH suppression rate (%) = (before treatment – after treatment)/before treatment × 100%. Analyzed with two independent sample Wilcoxon rank sum test, patients with low SSTR5 expression presented a significantly higher TSH suppression rate ($P = 0.036$). TSH: Thyroid-stimulating hormone; SSTR: Somatostatin receptor.

illness, medications, assay interference due to heterophilic antibodies, TH resistance, and TSHoma. The syndrome of pituitary resistance to thyroid hormone (PRTH) is characterized by tissue hyposensitivity to elevated levels of FT3 and FT4 in association with unsuppressed serum TSH (signs and symptoms are subjective).^[22] Differentiating between these forms of PRTH and TSHomas may be difficult. As mutations in the *TRβ* gene are responsible for PRTH, we excluded PRTH by Sanger sequencing. Normal or elevated TSH levels with elevated FT3 and FT4 concentrations in these hyperthyroid patients provided a clue to TSHoma, and the confirmed diagnoses were based on IHC results.

Approximately, 30% of the patients with TSHoma are misdiagnosed with primary hyperthyroidism and might undergo such thyroid ablative treatment as antithyroid medication, thyroidectomy, or radioactive iodine thyroid ablation before their pituitary lesion is found.^[23] In our study, one patient had been misdiagnosed with Hashimoto's thyroiditis. Another was misdiagnosed with Graves' disease and treated with antithyroid drugs that worsened his thyroid functions.

Most patients present with mild signs of thyrotoxicosis and possible neurological features, due to pituitary mass; they often have thyroid nodule disease.^[2,24] Apparently, TSH is the primary mediator of thyrocyte proliferation.^[25] TSHomas may be associated with thyroid diseases, and in diagnosing TSHoma, the possibility of thyroid disease should be investigated and followed up. Patient 8 had both autoimmune thyroid disease and TSHoma. Postoperative endocrine studies reported total blood triiodothyronine concentrations of 0.78 nmol/L (normal range [NR]: 1.18–2.23 nmol/L), total thyroxine of 54.22 nmol/L (NR: 57.92–154.44 nmol/L), and TSH of 0.263 mU/ml (NR: 0.47–4.64 mU/ml). Central hypothyroidism was diagnosed, and postoperative hypothyroidism replacement therapy with levothyroxine 50 µg once daily was begun postoperatively.

TSHomas are often diagnosed as macroadenomas and as plurihormonal; they are clinically heterogeneous and difficult

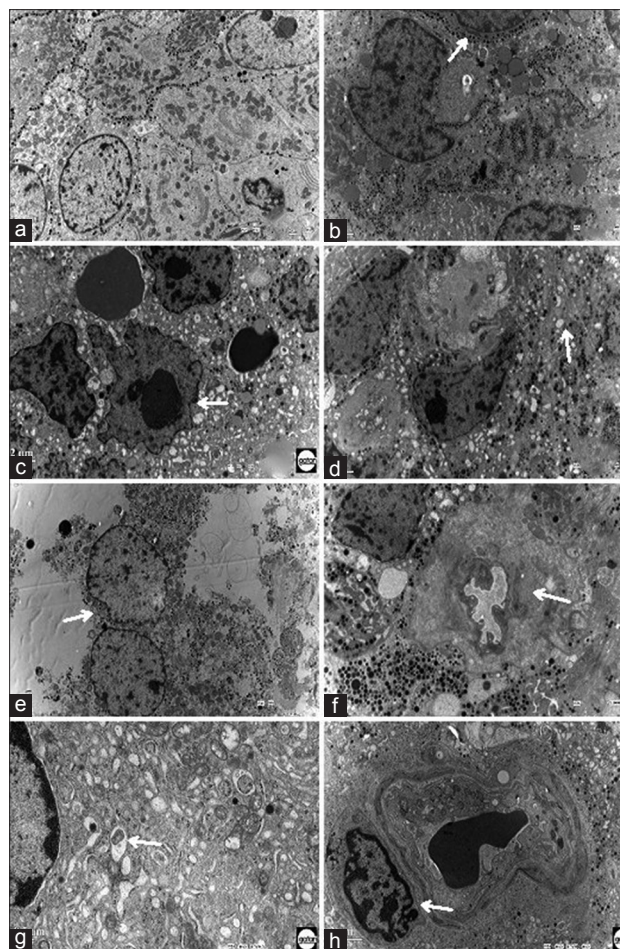


Figure 2: Electron microscopy of TSHoma specimens treated with OCT (original magnification ×200). (a) Control TSHoma cells with no OCT treatment show regular morphology. (b) Arrow points to untreated adenoma cells – mostly round; exteriors are dotted evenly with black TSH secretion granules along the cell membranes. (c) Arrow points to actively growing pituitary adenoma cell with an irregular shape, mild dysplasia, and deep staining; its nucleus is larger than those seen in normal cells. (d) Arrow points to mitochondria with varying degrees of swelling, transparent mitochondrial matrix, missing granules, disorderly arrangement, and fractured cristae. (e) Electron microscope shows cell membrane missing and fractured, as well as local defect and blurred structure of cell organelles and nuclei. (f) Electron microscope shows thickened vascular basement membrane around tumor. (g) Arrow points to elongated rough endoplasmic reticulum, which may lead to vacuole denaturalization if extended significantly. (h) Apoptotic cell. TSHoma: Thyrotropin-secreting pituitary adenoma; OCT: Octreotide; TSH: Thyrotropin.

to treat.^[6] Most patients (80%) have macroadenomas; microadenomas are less common.^[26] The primary therapeutic approach is neurosurgery.^[4,27] If surgery is contraindicated or declined, radiotherapy might be an option. Medically, SST analogs can control hormone hypersecretion for 90% of patients; long-time therapy should cause significant tumor shrinkage for about 45% of patients.^[28]

Reportedly, TSHomas that express SSTRs support the use of OCT for TSH-dependent hyperthyroidism.^[28] Characteristic SSTR expression patterns in pituitary adenomas are species-,

tissue-, and subtype-specific. An *SSTR5* mutation in tumor tissue was reported in one acromegalic patient who was resistant to SST analog treatment, which implies a role for *SSTR5* in predicting response.^[29] *SSTR5* expression on the top of *SSTR2* reportedly may account for long-term suppression of hormone hypersecretion^[24] and tumor growth.^[30] Additional studies with a larger number of cases are necessary to establish the exact role of *SSTR5* in OCT therapy for TSHoma.

In general, *SSTR2* was expressed at higher levels than *SSTR5* in TSHomas. Use of *SSTR2*- and *SSTR5*-preferring OCT and lanreotide may be a useful treatment for TSHoma.^[31] All patients were significantly improved by OCT treatment in our study, implying that OCT can both help restore euthyroidism preoperatively and decrease the risk of perioperative thyroid storm, for better surgical outcomes. Variations in response result from high concentration of *SSTRs* on TSH-secreting tumors. The OCT test before surgery can also predict whether OCT therapy would be effective if surgery alone is not curative.

Current studies on the effects of bromocriptine have shown shrunken cytoplasm and greater karyoplasmic ratios. Changes confirmed with ultrastructural analyses included nuclear chromatin aggregation and margination, marked reduction of rough endoplasmic reticulum and Golgi complexes, vascular degenerations, and necrosis and autolysis of tumor cells with dark cells and/or naked nuclear cells.^[32] Electron microscopy used to elucidate the mechanism of OCT in treating TSHomas showed that specimens from patients who received short-term OCT treatment presented ultrastructural changes at the organelle and subcellular levels that were not seen in TSHomas patients who did not receive OCT treatment.

Our main finding was that short-term preoperative OCT use achieved the desired clinical outcome and biochemical euthyroidism. Our second important finding is that TSHomas expressed higher levels of *SSTR2* than *SSTR5*. All these facts indicate that OCT acts directly on tumor cell *SSTRs*, causing damage to tumor cells and organelles to varying degrees, which is consistent with the existing studies. The first-generation SST analogs may serve as a medical alternative to surgical treatment, especially for patients in whom surgery is contraindicated or who present with invasive macroadenomas that render complete surgical resection difficult.

The most obvious limitations of this study were the small size of our cohort, its single-institution design, and the patients' rather short follow-up. Optimally, a larger series with long-term follow-up is needed to determine outcomes and remission rates for OCT-treated TSHomas. Safety and ethical concerns require that surgery should be performed only on the premise of hyperthyroidism control. Another potential limitation is that before–after studies in the same patients and case-control study may be biased, and can also mask cause-and-effect relationships or, alternatively,

suggest correlations where none exist. Finally, apoptosis and necrosis measured by electron microscopy reflect only qualitative instead of quantitative analysis levels. Resolving these limitations is the objective of our ongoing studies.

In conclusion, OCT works on pituitary adenoma cells by binding to *SSTR2* and *SSTR5*. Its short-term use as part of preoperative preparation for patients with TSHomas can effectively control central hyperthyroidism, increase surgical safety, and present favorable long-term effects on proliferation, apoptosis, and tumor growth. We suggest that patients with TSHoma can be managed with a combination of OCT therapy and subsequent surgery, and recommend immunohistochemical staining to detect *SSTR* subtypes in all surgical specimens.

Financial support and sponsorship

This study was supported by grants from the Special Research Fund for Public Welfare Industry Health (No. 201402008), and the National High Technology Research and Development Program of China (“863” Program; No. 2014AA020610).

Conflicts of interest

There are no conflicts of interest.

REFERENCES

1. Beck-Peccoz P, Brucker-Davis F, Persani L, Smallridge RC, Weintraub BD. Thyrotropin-secreting pituitary tumors. *Endocr Rev* 1996;17:610-38. doi: 10.1210/edrv-17-6-610.
2. Beck-Peccoz P, Persani L, Mannavola D, Campi I. Pituitary tumours: TSH-secreting adenomas. *Best Pract Res Clin Endocrinol Metab* 2009;23:597-606. doi: 10.1016/j.beem.2009.05.006.
3. Önnestam L, Berinder K, Burman P, Dahlqvist P, Engström BE, Wahlberg J, *et al.* National incidence and prevalence of TSH-secreting pituitary adenomas in Sweden. *J Clin Endocrinol Metab* 2013;98:626-35. doi: 10.1210/jc.2012-3362.
4. Beck-Peccoz P, Lania A, Beckers A, Chatterjee K, Wemeau JL. 2013 European thyroid association guidelines for the diagnosis and treatment of thyrotropin-secreting pituitary tumors. *Eur Thyroid J* 2013;2:76-82. doi: 10.1159/000351007.
5. Page KA, Roehmholdt BF, Jablonski M, Mayerson AB. Development of thyroid storm after surgical resection of a thyrotropin-secreting pituitary adenoma. *Endocr Pract* 2008;14:732-7. doi: 10.4158/EP.14.6.732.
6. Clarke MJ, Erickson D, Castro MR, Atkinson JL. Thyroid-stimulating hormone pituitary adenomas. *J Neurosurg* 2008;109:17-22. doi: 10.3171/JNS.2008.109.7.0017.
7. Elston MS, Conaglen JV. Clinical and biochemical characteristics of patients with thyroid-stimulating hormone-secreting pituitary adenomas from one New Zealand Centre. *Intern Med J* 2010;40:214-9. doi: 10.1111/j.1445-5994.2009.02107.x.
8. Taylor TJ, Donlon SS, Bale AE, Smallridge RC, Francis TB, Christensen RS, *et al.* Treatment of a thyrotropinoma with octreotide-LAR in a patient with multiple endocrine neoplasia-1. *Thyroid* 2000;10:1001-7. doi: 10.1089/thy.2000.10.1001.
9. van Varsseveld NC, Bisschop PH, Biermasz NR, Pereira AM, Fliers E, Drent ML. A long-term follow-up study of eighteen patients with thyrotrophin-secreting pituitary adenomas. *Clin Endocrinol (Oxf)* 2014;80:395-402. doi: 10.1111/cen.12290.
10. Zhao W, Ye H, Li Y, Zhou L, Lu B, Zhang S, *et al.* Thyrotropin-secreting pituitary adenomas: Diagnosis and management of patients from one Chinese center. *Wien Klin Wochenschr* 2012;124:678-84. doi: 10.1007/s00508-012-0216-z.
11. Ferone D, Gatto F, Arvigo M, Resmini E, Boschetti M, Teti C, *et al.* The clinical-molecular interface of somatostatin, dopamine and their receptors in pituitary pathophysiology. *J Mol Endocrinol* 2009;42:361-70. doi: 10.1677/JME-08-0162.

12. Shimatsu A, Murabe H, Kamoi K, Suzuki Y, Nakao K. Treatment of thyrotropin-secreting pituitary adenomas with octreotide. *Endocr J* 1999;46:113-23. doi: 10.1507/endocrj.46.113.
13. Socin HV, Chanson P, Delemer B, Tabarin A, Rohmer V, Mockel J, *et al*. The changing spectrum of TSH-secreting pituitary adenomas: Diagnosis and management in 43 patients. *Eur J Endocrinol* 2003;148:433-42. doi: 10.1530/eje.0.1480433.
14. Gatto F, Barbieri F, Gatti M, Wurth R, Schulz S, Ravetti JL, *et al*. Balance between somatostatin and D2 receptor expression drives TSH-secreting adenoma response to somatostatin analogues and dopastatins. *Clin Endocrinol (Oxf)* 2012;76:407-14. doi: 10.1111/j.1365-2265.2011.04200.x.
15. Chanson P, Weintraub BD, Harris AG. Octreotide therapy for thyroid-stimulating hormone-secreting pituitary adenomas. A follow-up of 52 patients. *Ann Intern Med* 1993;119:236-40. doi: 10.7326/0003-4819-119-3-199308010-00010.
16. Beck-Peccoz P, Persani L. Medical management of thyrotropin-secreting pituitary adenomas. *Pituitary* 2002;5:83-8. doi: 10.1023/A:1022360414062.
17. Iglesias P, Diez JJ. Long-term preoperative management of thyrotropin-secreting pituitary adenoma with octreotide. *J Endocrinol Invest* 1998;21:775-8. doi: 10.1007/BF03348045.
18. Remmele W, Stegner HE. Recommendation for uniform definition of an immunoreactive score (IRS) for immunohistochemical estrogen receptor detection (ER-ICA) in breast cancer tissue. *Pathologie* 1987;8:138-40.
19. Bertholon-Grégoire M, Trouillas J, Guigard MP, Loras B, Tourmiaire J. Mono- and plurihormonal thyrotropic pituitary adenomas: Pathological, hormonal and clinical studies in 12 patients. *Eur J Endocrinol* 1999;140:519-27. doi: 10.1530/eje.0.1400519.
20. Sanno N, Teramoto A, Osamura RY. Thyrotropin-secreting pituitary adenomas. Clinical and biological heterogeneity and current treatment. *J Neurooncol* 2001;54:179-86. doi: 10.1023/A:1012917701756.
21. Losa M, Giovanelli M, Persani L, Mortini P, Faglia G, Beck-Peccoz P. Criteria of cure and follow-up of central hyperthyroidism due to thyrotropin-secreting pituitary adenomas. *J Clin Endocrinol Metab* 1996;81:3084-90. doi: 10.1210/jcem.81.8.8768879.
22. Rivas AM, Lado-Abeal J. Thyroid hormone resistance and its management. *Proc (Bayl Univ Med Cent)* 2016;29:209-11. doi: 10.1177/2324709616658495.
23. Yoshihara A, Isozaki O, Hizuka N, Nozoe Y, Harada C, Ono M, *et al*. Expression of type 5 somatostatin receptor in TSH-secreting pituitary adenomas: A possible marker for predicting long-term response to octreotide therapy. *Endocr J* 2007;54:133-8. doi: 10.1507/endocrj.K06-133.
24. Losa M, Fortunato M, Molteni L, Peretti E, Mortini P. Thyrotropin-secreting pituitary adenomas: Biological and molecular features, diagnosis and therapy. *Minerva Endocrinol* 2008;33:329-40.
25. Fiore E, Vitti P. Serum TSH and risk of papillary thyroid cancer in nodular thyroid disease. *J Clin Endocrinol Metab* 2012;97:1134-45. doi: 10.1210/jc.2011-2735.
26. Calvo Romero JM, Morales Pérez F, Alvarez Barreiro JA, Diaz Pérez de Madrid J. Thyrotropin-producing hypophyseal adenomas. *Rev Clin Esp* 1999;199:285-7.
27. Liu HC, Wu Z, Wang L, Xiao XR, Li D, Jia W, *et al*. Frontolateral approach applied to sellar region lesions: A retrospective study in 79 patients. *Chin Med J* 2016;129:1558-64. doi: 10.4103/0366-6999.184457.
28. Caron P, Arlot S, Bauters C, Chanson P, Kuhn JM, Pugeat M, *et al*. Efficacy of the long-acting octreotide formulation (octreotide-LAR) in patients with thyrotropin-secreting pituitary adenomas. *J Clin Endocrinol Metab* 2001;86:2849-53. doi: <https://doi.org/10.1210/jcem.86.6.7593>.
29. Ballarè E, Persani L, Lania AG, Filopanti M, Giammona E, Corbetta S, *et al*. Mutation of somatostatin receptor type 5 in an acromegalic patient resistant to somatostatin analog treatment. *J Clin Endocrinol Metab* 2001;86:3809-14. doi: 10.1210/jcem.86.6.7593.
30. Horiguchi K, Yamada M, Umezawa R, Satoh T, Hashimoto K, Tosaka M, *et al*. Somatostatin receptor subtypes mRNA in TSH-secreting pituitary adenomas: A case showing a dramatic reduction in tumor size during short octreotide treatment. *Endocr J* 2007;54:371-8. doi: 10.1210/jcem.86.8.7787.
31. Zhang CF, Liang D, Zhong LY. Efficacy of the long-acting octreotide formulation in patients with thyroid-stimulating hormone-secreting pituitary adenomas after incomplete surgery and octreotide treatment failure. *Chin Med J* 2012;125:2758-63. doi: 10.3760/cma.j.isn.0366-6999.2012.15.020.
32. Asa SL, Ezzat S. Medical management of pituitary adenomas: structural and ultrastructural changes. *Pituitary* 2002;5:133-9. doi: 10.1023/A:1022320732718.