

Sensitivity and Specificity of Central Vein Sign as a Diagnostic Biomarker in Egyptian Patients with Multiple Sclerosis

Hend Abdel Ghany¹, Ahmed Karam-Allah¹, Ramy Edward², Maged Abdel Naseer¹,
Mohamed I Hegazy¹

¹Neurology Department, Faculty of Medicine, Cairo University, Cairo, Egypt; ²Radiology Department, Faculty of Medicine, Cairo University, Cairo, Egypt

Correspondence: Mohamed I Hegazy, Neurology Department, Cairo University, 108 Al Manial street, Degla, Maadi, Cairo, 11435, Egypt, Tel +20 1223130686, Email mhegazy@kasralainy.edu.eg

Purpose: Magnetic resonance imaging (MRI) findings in multiple sclerosis (MS) overlap with numerous MS mimics. The central vein sign (CVS) can help to differentiate MS from other mimics. This study aimed to determine the value of CVS as a diagnostic biomarker for distinguishing MS from its mimics.

Patients and Methods: Patients were prospectively recruited into two groups: a typical clinical (TC) MS presentation with an atypical MRI for MS and an atypical clinical (ATC) MS presentation with a typical MRI for MS. Patients underwent a 1.5T MRI brain scan with a T2*-weighted gradient-echo sequence. The presence of the central vein was assessed by a radiologist blinded to patients' clinical presentation. The MS consultant made the final diagnosis without reviewing the T2*-weighted gradient-echo sequence or the CVS analysis results.

Results: Forty-two patients were included. Ten (40%) out of 25 TC patients were diagnosed with clinically definite MS (CDMS), with a mean percentage of CV-positive lesions of 65.5% among CDMS patients. Four (23.5%) out of 17 ATC patients were diagnosed with CDMS with a mean CV-positive lesions percentage of 68.25% among CDMS patients. TC patients who were not diagnosed as CDMS had a mean CV-positive lesions percentage of 10.13%, while ATC patients who were not diagnosed as CDMS had a mean CV-positive lesions percentage of 16.38%. The CVS showed 85.7% sensitivity and 100% specificity (95% confidence interval: 0.919–1.018) for diagnosis of MS at a cut off value of 45% ($p < 0.001$). The percentage of CV-positive lesions was significantly higher in oligoclonal bands (OCBs) positive patients compared to OCBs negative patients ($p < 0.001$) and those with spinal cord lesions compared to patients with no spinal cord lesions ($p = 0.017$).

Conclusion: The CVS has 85.7% sensitivity and 100% specificity for the diagnosis of MS at a cutoff value of 45%.

Keywords: multiple sclerosis, central vein, mimics, cutoff, gradient-echo

Introduction

Brain magnetic resonance imaging (MRI) is now considered the cornerstone for diagnosing multiple sclerosis (MS).¹ MRI findings in MS often overlap with numerous MS mimics,² such as neuromyelitis optica, small vessel disease, migraine, and systemic lupus erythematosus.^{3–5} This presents challenges for the radiological diagnosis of MS in some patients. There is a need for reliable radiological diagnostic biomarkers to avoid false diagnosis of MS or missing MS patients with atypical radiological presentations.

The central vein sign (CVS) has recently gained significant interest as a radiological biomarker to help improve the accuracy of MS diagnosis.⁶ Evidence indicates that the CVS in certain lesions can accurately differentiate MS from other mimics.^{7,8} Studies in patients with MS conducted using high-field MRI scanners using the gradient-echo technique have revealed that a small central vein (CV) is frequently detected in MS lesions and can distinguish MS from other radiological mimics, such as small vessel disease.^{7,9} Thus, the North American Imaging in MS (NAIMS) cooperative

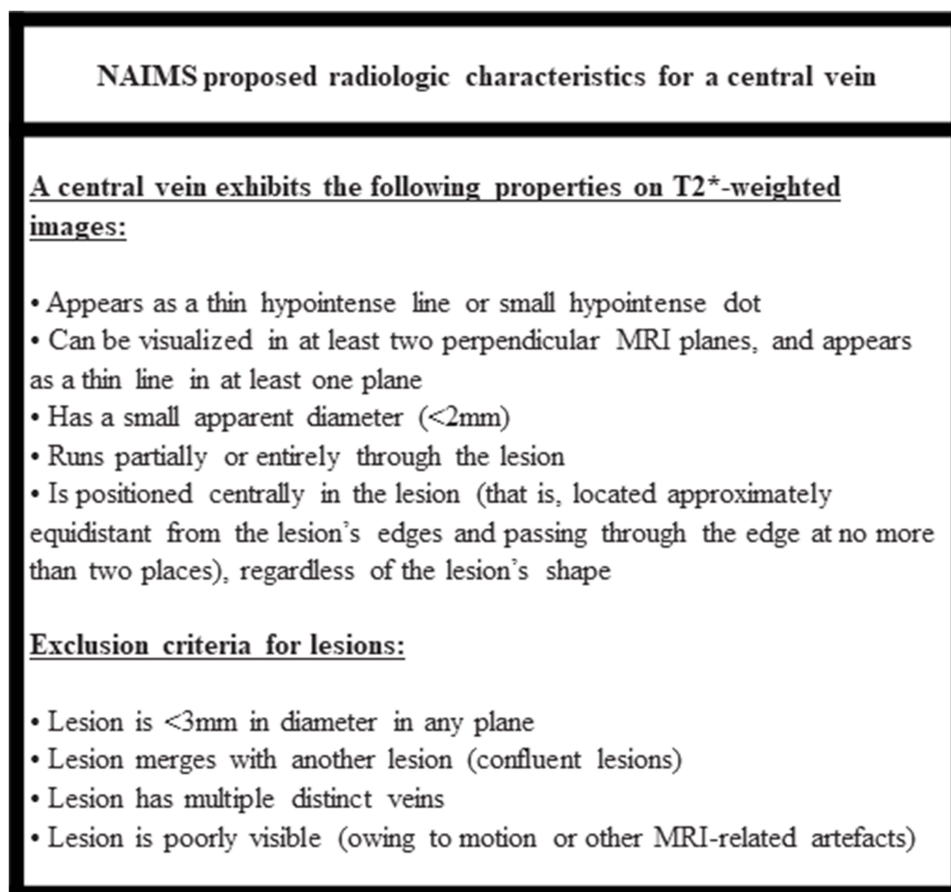


Figure 1 Radiologic characteristics for a CV proposed by NAIMS.

proposed the radiological characteristics of a CV⁶ (Figure 1). Moreover, various criteria have been proposed to determine whether a scan is considered central vein-positive:

1. At least 40% of lesions have a visible central vein.⁹
2. A combination of a CV-positive lesion count and location.¹⁰
3. At least six CV-positive lesions; if the total lesion count is fewer than six, the majority of lesions must have a CV.⁷
4. At least three CV-positive lesions.¹¹

The aim of this study was to determine the value of CVS as a diagnostic biomarker that can distinguish MS from its mimics in Egyptian MS patients using 1.5T MRI scanners.

Methods

Sample

Patients were recruited prospectively from the MS clinic of Cairo University Hospital between July 2020 and November 2020. Patients were eligible if they were aged 18–59 years and fell into one of the following two categories: a typical clinical (TC) presentation suggestive of MS with an atypical MRI for MS and an atypical clinical (ATC) presentation of MS with a typical MRI suggestive of MS. We included 42 patients, of whom 30 were female (71.4%) and 12 were male (28.6%). The age of patients ranged from 18 to 55 years, with a mean age of 34 years. A patient was considered to have a typical clinical presentation if he/she presented with one or more of the following symptoms: acute/subacute unilateral diminution of vision, acute/subacute double vision or ophthalmoplegia, acute/subacute monoparesis,

hemiparesis or paraparesis, acute/subacute limb or gait ataxia, acute/subacute well-defined consistent positive or negative sensory symptoms and acute/subacute sphincteric symptoms. A typical MRI for MS was defined as

central nervous system white matter lesions on MRI that are ovoid, well-circumscribed, > 3 mm, and homogeneously hyperintense on T2-weighted images with or without involvement of the corpus callosum.¹²

The study protocol was approved by the institutional review board of the Faculty of Medicine, Cairo University (REC code: MD-62-2020). The study was conducted in accordance with the principles established by the 18th World Medical Assembly (Helsinki, 1964) and all applicable amendments laid down by it, International Council for Harmonization guidelines for good clinical practice, and in compliance with all national and international laws and regulations. A written informed consent was obtained from all study participants prior to enrollment.

Workup

All patients underwent routine clinical assessment by an MS consultant, a cerebrospinal fluid analysis for oligoclonal bands (OCBs), immunoglobulin G index and cytology, an autoimmune laboratory workup, and visual evoked potential examination. Additional investigations were requested if the consultant deemed them necessary for diagnosis (eg chest computed tomography when sarcoidosis was suspected or a pathology test when Behcet's disease was suspected).

All patients underwent an MRI scan of the brain and cervical spine on a 1.5T Philips Achieva system (Philips Medical Systems Nederland B.V.) at the Radiology Department of Cairo University Hospital. The brain MRI included a three-dimensional T2*-weighted gradient-echo scan (without contrast). The parameters for the 3D FLAIR sequence were: FOV 250, TE 308 ms, TR 4.8 s, Flip Angle 90, and the parameters for the T2* sequence were: FOV 230, TE 50 ms, TR 35 ms, Flip Angle 15. The white matter lesions (WMLs) were outlined, and the presence or absence of the CV was assessed. WMLs were detected on the axial view, and the presence of a CV was confirmed by its presence on one of the other two orthogonal planes, as recommended by the NAIMS cooperative (Figure 1).

An experienced radiology consultant outlined the WMLs visible on the T2*-weighted scans, detected the presence or absence of a CV, and calculated the percentage of WMLs with CVs for each patient. Lesions smaller than 3 mm on the shorter axis and confluent and infratentorial lesions were not analyzed. The radiology consultant was blinded to the clinical presentation of the patient.

The MS consultant made the final diagnosis according to the 2017 revision of McDonald's criteria¹ without having access to the T2*-weighted gradient-echo sequence (they did have access to the standard MRI scan) or the results of the CVS analysis.

Statistical Analysis

Data were coded and entered using the Statistical Package for the Social Sciences (SPSS) version 26 (IBM Corp., Armonk, NY, USA). Quantitative data are summarized as means, standard deviations, medians, minimums, and maximums, and categorical data are described as frequencies (counts) and relative frequencies (percentages). Comparisons between quantitative variables were performed using non-parametric Kruskal–Wallis and Mann–Whitney tests.

For comparisons of categorical data, we used chi-square (χ^2) tests. The exact test was used if the expected frequency was less than five. Correlations between quantitative variables were performed using Spearman correlation coefficient. A receiver operating characteristic (ROC) curve was constructed using the area under the curve analysis to determine the best cutoff value of the CVS for the detection of MS. A $p < 0.05$ was considered statistically significant.

Results

Of the 42 patients included in the study, 25 patients (59.5%) presented with TC MS with an atypical MRI for MS, and 17 patients (40.5%) presented with ATC MS with a typical MRI for MS. We found that TC MS patients presented with sensory, visual, motor, and brainstem symptoms and ataxia, whereas the ATC MS patients presented with headaches, seizures, behavioral symptoms, and psychosis.

Ten (40%) out of 25 TC MS patients received a final diagnosis of clinically definite MS (CDMS), of whom eight (80%) had a high percentage of CV-positive lesions (50–100%), and the remaining two patients had a low percentage of CV-positive lesions (20% and 22% of lesions). The mean percentage of CV-positive lesions among the 10 patients diagnosed with CDMS in the TC MS group was 65.5%. The 15 patients in the TC MS group who received a non-MS diagnosis had CV-positive lesion percentages ranging from 0% to 25%, with a mean percentage of 10.13%.

In the ATC MS group, four (23.5%) out of 17 patients received a final diagnosis of CDMS, and all four patients had a high percentage of CV-positive lesions (57–75%), with a mean percentage of 68.25% (Figure 2). The 13 patients in the ATC group who received a non-MS diagnosis had CV-positive lesion percentages ranging from 0% to 40%, with a mean percentage of 16.38%. The percentage of CV-positive lesions for 12 out of these 13 patients ranged from 0% to 25%, and one patient who was diagnosed with anti-phospholipid syndrome had CV-positive lesions in 40% of all lesions. The mean number and percentage of CV-positive lesions were significantly higher in patients who received a CDMS diagnosis from the TC and ATC groups as compared to patients who did not receive a CDMS diagnosis ($p < 0.0001$ for both number and percentage). Table 1 summarizes the clinical and paraclinical characteristics of patients in the TC and ATC groups who received or did not receive a CDMS diagnosis. Table 2 shows the final diagnoses of TC and ATC MS patients who received a non-MS diagnosis alongside their CV-positive lesion percentage.

The ROC curve analysis showed high sensitivity (85.7%) and specificity (100%) of the CVS for diagnosing MS (95% confidence interval: 0.919–1.018) at a cutoff value of 45% ($p < 0.001$; Figure 3). The percentage of CV-positive lesions was significantly higher in patients with positive OCBs than in patients with negative OCBs ($p < 0.001$). Similarly, the percentage of CV-positive lesions was significantly higher in patients with spinal cord lesions than in patients without spinal cord lesions ($p = 0.017$; Table 3). Age, disease duration, and disability, as assessed by expanded disability status scale, were not correlated with the percentage of CV-positive lesions.

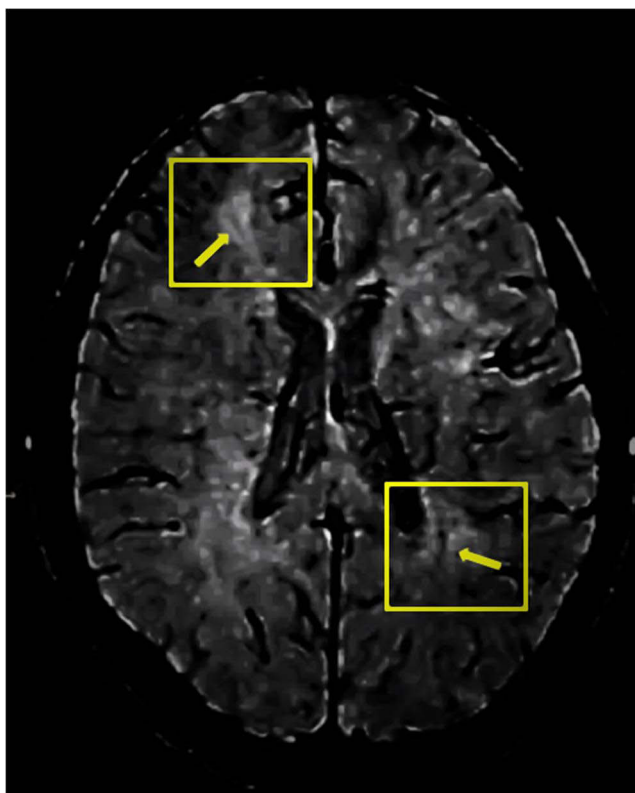


Figure 2 T2*-weighted gradient-echo MRI scan. Scan of a 19-year-old female patient from the ATC group who presented with seizures and was eventually diagnosed with CDMS with positive OCBs and CV-positive lesions in 57% of all lesions. Inside each of the yellow boxes lies a central vein positive lesion with the yellow arrows pointing to central vein.

Table 1 Clinical and Paraclinical Characteristics of Patients in the TC and ATC Groups Who Received or Did Not Receive a CDMS Diagnosis

	TC Patients Diagnosed as CDMS (n=10)	TC Patients Not Diagnosed as CDMS (n=15)	ATC Patients Diagnosed as CDMS (n=4)	ATC Patients Not Diagnosed as CDMS (n=13)
Mean n (mean %) of CV-positive lesions	4.1 (65.5%)	0.93 (10.13%)	6.75 (68.25%)	1.23 (16.38%)
n (%) of OCBs positive patients	9 (90%)	0 (0%)	4 (100%)	2 (15.38%)
n (%) of patients with spinal cord lesions	8 (80%)	4 (26.6%)	1 (25%)	1 (7.69%)
n (%) of patients with affected VEP	5 (50%)	6 (40%)	2 (50%)	2 (15.38%)
n (%) of patients fulfilling both DIS +DIT according to McDonald's criteria 2017	10(100%)	4 (26.67%)	4 (100%)	1 (7.69%)

Abbreviations: TC, typical clinical; ATC, atypical clinical; CDMS, clinically definite multiple sclerosis; n, number; %, percentage; CV, central vein; OCBs, oligoclonal bands; VEP, visual evoked potential; DIS, dissemination in space; DIT, dissemination in time.

Table 2 Final Diagnoses of Patients Who Received a Non-MS Diagnosis and Their CV-Positive Lesion Percentage

	Final Diagnosis	Number of Patients	CV-Positive Lesion n (%)
Patients with typical clinical presentation + atypical MRI (TC)	Neuromyelitis optica	4	0 (0%), 0 (0%), 1 (14%), 2 (25%)
	Isolated optic neuritis	3	0 (0%), 0 (0%), 0 (0%)
	Chronic migraine	3	1 (11%), 1 (12%), 2 (22%)
	Small vessel disease	2	0 (0%), 1 (10%)
	CADASIL	1	2 (16%)
	Progressive systemic sclerosis	1	2 (20%)
	Behcet's disease	1	2 (22%)
Patients with atypical clinical presentation + typical MRI (ATC)	Chronic migraine	7	0 (0%), 1 (14%), 1 (16%), 2 (18%), 1 (20%), 3 (20%), 1 (25%)
	Headache (non-specific)	1	1 (6%)
	Neuromyelitis optica	1	1 (20%)
	Small vessel disease	1	1 (12%)
	Connective tissue disease	1	2 (22%)
	Anti-phospholipid syndrome	1	2 (40%)
	Systemic lupus erythematosus	1	0 (0%)

Abbreviations: n, number; %, percentage; CV, central vein; TC, typical clinical; CADASIL, cerebral autosomal dominant arteriopathy with subcortical infarcts and leukoencephalopathy; ATC, atypical clinical.

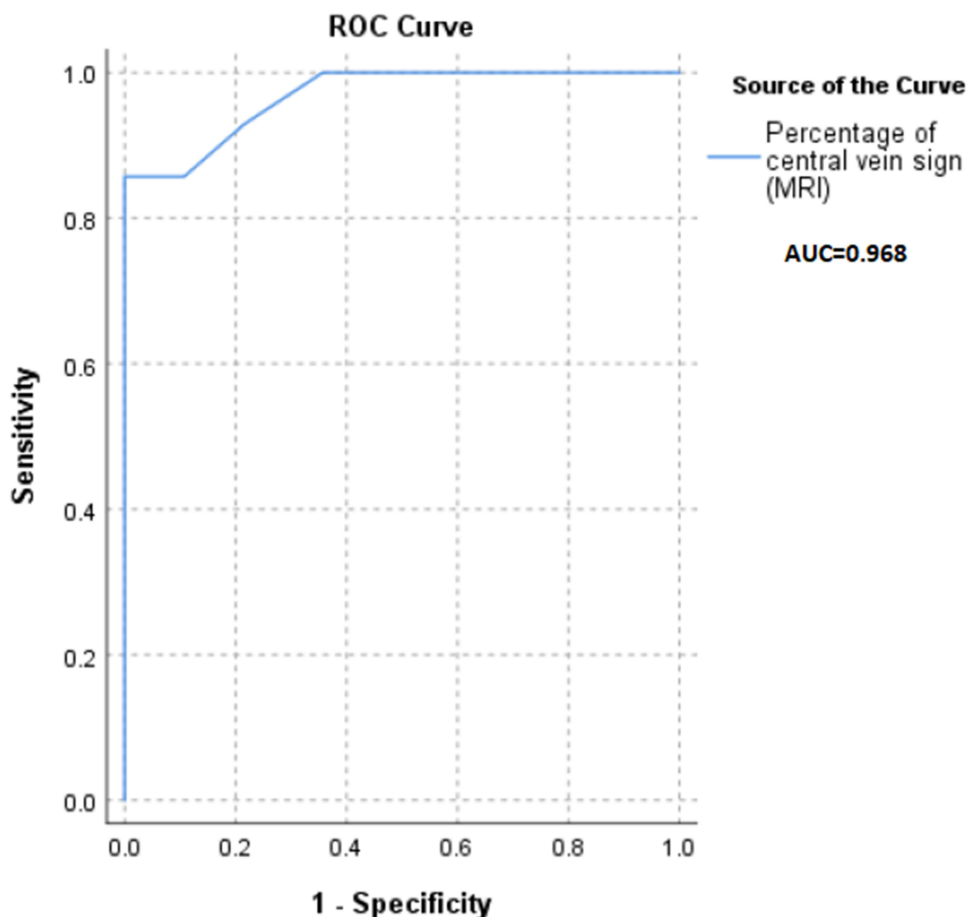


Figure 3 ROC curve analysis showing the diagnostic accuracy of the CVS.

Discussion

We assessed the value of the CVS in distinguishing between MS lesions and their mimics using a 1.5T MRI scanner in 42 patients. We found that the CVS has 85.7% sensitivity and 100% specificity at a cutoff value of 45% of the total lesions ($p < 0.001$). The mean percentage of CV-positive lesions was significantly higher in patients who received a CDMS diagnosis from the TC and ATC groups as compared to patients who did not receive a CDMS diagnosis ($p < 0.0001$). Several studies have assessed the value of the CVS in MS patients and confirmed its ability to distinguish MS lesions from their mimics with good sensitivity and specificity; those studies used a range of scanners with various magnetic fields’ strengths: 1.5T scanners,^{14,15} 3 T scanners,^{6,13} and 7T scanners.^{8,11} For example, Tallantyre et al conducted a 7T MRI study to assess the CVS in 28 MS patients with a total of 901 lesions and 17 non-MS patients with a total of 428

Table 3 Percentage of CV-Positive Lesions in Patients with Positive/Negative OCBs and Patients with/without Spinal Cord Lesions

	OCB-Positive					OCB-Negative					P-value
	Mean	SD	Median	Minimum	Maximum	Mean	SD	Median	Minimum	Maximum	
Percentage of CV-positive lesions	64.13	24.06	75.00	14.00	100.00	12.26	9.24	14.00	0.00	25.00	< 0.001
	With spinal cord lesions					No spinal cord lesions					
	50.00	36.50	66.00	0.00	100.00	22.17	21.83	16.00	0.00	75.00	0.017

Abbreviations: OCB, oligoclonal bands; CV, central vein; SD, standard deviation.

lesions and determined a 40% cutoff for differentiating CDMS patients from non-MS patients.⁸ Clarke et al used 3T MRI to investigate the diagnostic value of the CVS and found that the CVS threshold for distinguishing MS patients from non-MS patients was 40.7%, which resulted in 100% sensitivity and 73.9% specificity.¹³ Anan et al conducted a study in Egyptian patients using a 1.5T MRI scanner and found that the CVS had a specificity of 100% for detecting MS lesions when the load of CV-positive lesions was $\geq 44.24\%$.¹⁴

A recent systematic review that included 21 studies evaluating the CVS according to the NAIMS criteria in 501 MS patients using T2*-weighted imaging reported an overall cutoff of 45% CV-positive lesions of total lesions, yielding 97% sensitivity and 99% specificity.¹⁶ In another recent systematic review conducted by Castellaro et al that reviewed 35 studies including 1047 patients (256 patients with clinically isolated syndrome and 791 patients with CDMS), the optimal cutoff value obtained from pooled patient data was 40%, with 95% sensitivity and 92% specificity.¹⁷ They also highlighted that the higher the magnetic field of the MRI scanner used, the higher the percentage of CV-positive lesions detected; the 1.5T scanners detected the lowest percentage of CV-positive lesions (58%) compared with both the 3T (74%) and 7T (82%) scanners.¹⁷

We found that the percentage of CV-positive lesions was significantly higher in OCB-positive patients compared to OCB-negative patients ($p < 0.001$) and patients with spinal cord lesions compared to patients with no spinal cord lesions ($p = 0.017$). This further confirmed the diagnostic value of the CVS because it is well-established that both OCBs and spinal cord lesions have high diagnostic value for MS.^{18,19} Our findings confirmed the value of the CVS as a reliable radiological biomarker for differentiating MS lesions from other non-specific WMLs that mimic MS lesions. We also revealed that the CVS can function as an accurate test for ruling out MS in cases with ATC presentations, such as migraines where patients frequently present with non-specific WMLs in their MRI.²⁰

One of the strengths of this study is its prospective design, where patients had experienced their first clinical presentation or their MRI suggested MS without TC MS presentation. Another strength is the blinding procedure, whereby the MS and radiology consultants were blinded to the CV analysis results and patients' clinical presentation, respectively. However, this study was limited by the small sample size and the use of a 1.5T scanner - despite being reflective to everyday practice - limited the percentage of CV-positive lesions detected.¹⁶

Conclusions

The CVS has 85.7% sensitivity and 100% specificity for the diagnosis of MS at a cutoff value of 45% and can serve as an important diagnostic biomarker to differentiate MS from its mimics.

Acknowledgments

The authors are grateful to all patients for their willingness to participate in this study.

Disclosure

The authors declare that they have no competing interests.

References

1. Thompson AJ, Banwell BL, Barkhof F, et al. Diagnosis of multiple sclerosis: 2017 revisions of the McDonald criteria. *Lancet Neurol.* 2018;17(2):162–173. PMID: 29275977. doi:10.1016/S1474-4422(17)30470-2
2. Gherardi R, Ciccarelli O, Barkhof F, et al.; Jacqueline Palace on behalf of the MAGNIMS study group. The current role of MRI in differentiating multiple sclerosis from its imaging mimics. *Nat Rev Neurol.* 2018;14(4):213. Erratum for: *Nat Rev Neurol.* 2018 Mar 09. PMID: 29582852. doi:10.1038/nrneuro.2018.39
3. Huh SY, Min JH, Kim W, et al. The usefulness of brain MRI at onset in the differentiation of multiple sclerosis and seropositive neuromyelitis optica spectrum disorders. *Mult Scler.* 2014;20(6):695–704. PMID: 24072726. doi:10.1177/1352458513506953
4. Liu S, Kullnat J, Bourdette D, et al. Prevalence of brain magnetic resonance imaging meeting Barkhof and McDonald criteria for dissemination in space among headache patients. *Mult Scler.* 2013;19(8):1101–1105. PMID: 23380650. doi:10.1177/1352458512471874
5. Sati P, Oh J, Constable RT, et al.; NAIMS Cooperative. The central vein sign and its clinical evaluation for the diagnosis of multiple sclerosis: a consensus statement from the North American imaging in multiple sclerosis cooperative. *Nat Rev Neurol.* 2016;12(12):714–722. PMID: 27834394. doi:10.1038/nrneuro.2016.166
6. Mistry N, Abdel-Fahim R, Samaraweera A, et al. Imaging central veins in brain lesions with 3-T T2*-weighted magnetic resonance imaging differentiates multiple sclerosis from microangiopathic brain lesions. *Mult Scler.* 2016;22(10):1289–1296. PMID: 26658816. doi:10.1177/1352458515616700

7. Solomon AJ, Schindler MK, Howard DB, et al. “Central vessel sign” on 3T FLAIR* MRI for the differentiation of multiple sclerosis from migraine. *Ann Clin Transl Neurol.* 2015;3(2):82–87. PMID: 26900578; PMCID: PMC4748312. doi:10.1002/acn3.273
8. Tallantyre EC, Dixon JE, Donaldson I, et al. Ultra-high-field imaging distinguishes MS lesions from asymptomatic white matter lesions. *Neurology.* 2011;76(6):534–539. PMID: 21300968; PMCID: PMC3053180. doi:10.1212/WNL.0b013e31820b7630
9. Kilsdonk ID, Wattjes MP, Lopez-Soriano A, et al. Improved differentiation between MS and vascular brain lesions using FLAIR* at 7 Tesla. *Eur Radiol.* 2014;24(4):841–849. PMID: 24317461. doi:10.1007/s00330-013-3080-y
10. Solomon AJ, Watts R, Ontaneda D, Absinta M, Sati P, Reich DS. Diagnostic performance of central vein sign for multiple sclerosis with a simplified three-lesion algorithm. *Mult Scler J.* 2018;24(6):750–757. doi:10.1177/1352458517726383
11. Mistry N, Dixon J, Tallantyre E, et al. Central veins in brain lesions visualized with high-field magnetic resonance imaging: a pathologically specific diagnostic biomarker for inflammatory demyelination in the brain. *JAMA Neurol.* 2013;70(5):623–628. PMID: 23529352. doi:10.1001/jamaneurol.2013.1405
12. Okuda DT, Mowry EM, Beheshtian A, et al. Incidental MRI anomalies suggestive of multiple sclerosis: the radiologically isolated syndrome. *Neurology.* 2009;72(9):800–805. Erratum in: *Neurology.* 2009 Apr 7;72(14):1284. PMID: 19073949. doi:10.1212/01.wnl.0000335764.14513.1a
13. Clarke MA, Samaraweera AP, Falah Y, et al. Single test to ARrive at multiple sclerosis (STAR-MS) diagnosis: a prospective pilot study assessing the accuracy of the central vein sign in predicting multiple sclerosis in cases of diagnostic uncertainty. *Mult Scler.* 2020;26(4):433–441. PMID: 31668125. doi:10.1177/1352458519882282
14. Anan RA, El-Adalany MA, Belal TMI, Elmogy SAE. Detection of central veins using susceptibility weighted imaging (SWI) for discrimination between lesions in multiple sclerosis (MS) and cerebral small vessel disease (CSVD). *Egypt J Radiol Nucl Med.* 2020;51(1):63. doi:10.1186/s43055-020-00185-3
15. Sparacia G, Agnello F, Gambino A, Sciortino M, Midiri M. Multiple sclerosis: high prevalence of the ‘central vein’ sign in white matter lesions on susceptibility-weighted images. *Neuroradiol J.* 2018;31(4):356–361. PMID: 29565219; PMCID: PMC6111438. doi:10.1177/1971400918763577
16. Suh CH, Kim SJ, Jung SC, Choi CG, Kim HS. The “Central Vein Sign” on T2*-weighted images as a diagnostic tool in multiple sclerosis: a systematic review and meta-analysis using individual patient data. *Sci Rep.* 2019;9(1):18188. PMID: 31796822; PMCID: PMC6890741. doi:10.1038/s41598-019-54583-3
17. Castellaro M, Tamanti A, Pisani AI, Pizzini FB, Crescenzo F, Calabrese M. The use of the central vein sign in the diagnosis of multiple sclerosis: a systematic review and meta-analysis. *Diagnostics.* 2020;10(12):1025. PMID: 33260401; PMCID: PMC7760678. doi:10.3390/diagnostics10121025
18. Arrambide G, Tintore M, Espejo C, et al. The value of oligoclonal bands in the multiple sclerosis diagnostic criteria. *Brain.* 2018;141(4):1075–1084. PMID: 29462277. doi:10.1093/brain/awy006
19. Patrucco L, Rojas JJ, Cristiano E. Assessing the value of spinal cord lesions in predicting development of multiple sclerosis in patients with clinically isolated syndromes. *J Neurol.* 2012;259(7):1317–1320. PMID: 22179784. doi:10.1007/s00415-011-6345-x
20. Hamedani AG, Rose KM, Peterlin BL, et al. Migraine and white matter hyperintensities: the ARIC MRI study. *Neurology.* 2013;81(15):1308–1313. doi:10.1212/WNL.0b013e3182a8235b

Neuropsychiatric Disease and Treatment

Dovepress

Publish your work in this journal

Neuropsychiatric Disease and Treatment is an international, peer-reviewed journal of clinical therapeutics and pharmacology focusing on concise rapid reporting of clinical or pre-clinical studies on a range of neuropsychiatric and neurological disorders. This journal is indexed on PubMed Central, the ‘PsychINFO’ database and CAS, and is the official journal of The International Neuropsychiatric Association (INA). The manuscript management system is completely online and includes a very quick and fair peer-review system, which is all easy to use. Visit <http://www.dovepress.com/testimonials.php> to read real quotes from published authors.

Submit your manuscript here: <https://www.dovepress.com/neuropsychiatric-disease-and-treatment-journal>