



## First Report of a Known Pathogenic Variant in the *FZD6* Gene, in an Iranian Family with Recessive Nail Dysplasia: A Case Report

**Mirsajjad MOUSAVI-ASL GERMEH CHESHMEH<sup>1</sup>, Ali NAJIZADEH<sup>2</sup>, Saied HOSSEINI-ASL<sup>3</sup>, Hooshang ZAIMKOHAN<sup>4,5</sup>, \*Roshanak JAZAYERI<sup>4,5</sup>**

1. Student Research Committee, Ardabil University of Medical Sciences, Ardabil, Iran
2. Student Research Committee, Alborz University of Medical Sciences, Karaj, Iran
3. Homa Gene Clinic, Department of Genetics, School of Medicine, Ardabil University of Medical Sciences, Ardabil, Iran
4. Non-Communicable Diseases Research Center, Alborz University of Medical Sciences, Karaj, Iran
5. Department of Biochemistry, Genetics and Nutrition, Faculty of Medicine, Alborz University of Medical Sciences, Karaj, Iran

\*Corresponding Author: Email: roshanakjazayeri@gmail.com

(Received 20 Jul 2018; accepted 11 Oct 2018)

### Abstract

Congenital Nail abnormalities are rare ectodermal defects. Autosomal recessive nail dysplasia is much rarer. Recently it has been recognized as a condition resulting in nail dystrophy in the absence of other cutaneous or extracutaneous disorders. Few case reports have identified mutations in the Frizzled 6 (*FZD6*) gene in families presenting with abnormal nails consistent with Non-Syndromic Congenital Nail Dysplasia. We report a family presenting, they lived in Namin a country of the Ardabil Province, northwestern Iran in 2016, for the first time in Iran in whom we identified mutations in *FZD6* with abnormal nails formation.

**Keywords:** Nail dysplasia; *FZD6* gene; Autosomal recessive; Iran

### Introduction

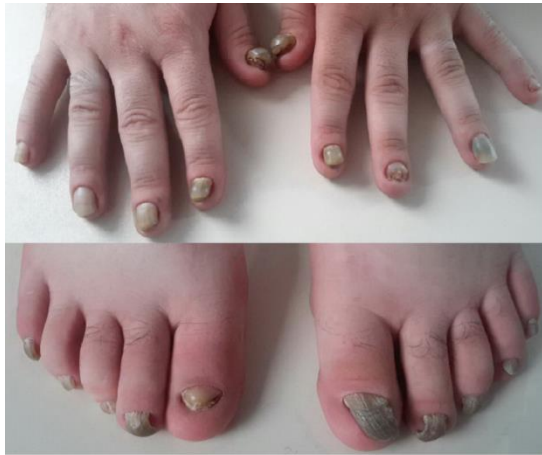Congenital Nail abnormalities are rare ectodermal defects. Including very rare conditions nail dysplasia. These defects may show no significant changes or complete absence of nails (1,2).

Wnt–FZD signaling pathway plays an important role in the development of ectodermal appendages including nails. Mutations in the gene Frizzled 6 (*FZD6*) can cause autosomal-recessive nail dysplasia (2-4). We have recently identified clinical presentation of the nail disorder with a mutation in the gene frizzled causing isolated nail dysplasia in a Turkish family from Namin a country of the Ardabil Province, northwestern Iran. Some people in this area have nail dysplasia where all fingernails and toenails were claw-shaped and thickened from childhood.

This report describes a previously known missense mutation in the mentioned gene in an Iranian family, a condition reported for the first time in Iran.

### Case Report

A 26-yr-old male medical student of Ardabil University of Medical Sciences in 2016, born of a healthy non-consanguineous parent's but the same region, referred to the genetic clinic with nail dysplasia. On clinical examination, all of the 20-nail was a variable degree of nail dystrophy, hyperkeratosis onychauxis (thick nails), hyponychia, onycholysis and claw-appearance with yellow bed (Fig.1).



**Fig. 1:** Hands and feet of proband showing that abnormality and claw-shaped in both finger and toenails at the age of 26 old years

From the age of about 1 year; his nails became thickened, claw-shaped and hyperplastic but did not seem to grow out. The growing of toenails was very slower than fingernails. At first, his thumb of hands was thicker, hyperplastic and discolored and then all of the nails had symmetrical involvement the same sign. Having dealt with the surrounding surfaces deformed nail was cracked at the cuticle and extremely painful and bleeding, then separated from the nail bed and fall.

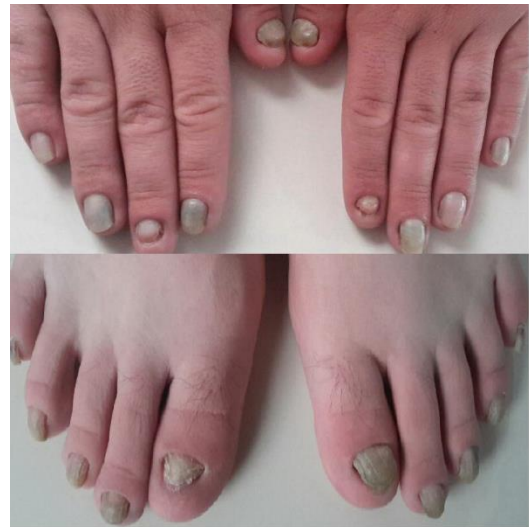The hyperkeratotic nails developed into claw-like structures on completion of the first decade of life possibly because of an outgrowth from below the edge of the nail. No associated abnormality was found in the affected individual in his hair, teeth, skin, and scalp.

Since four years ago, he has had numerous medical problems. Such as GERD, lymphedematous on the left leg, rhinitis allergic, Lung CT Scan showed that he had allergic asthma, and abdominal ultrasonography revealed fatty liver changes in grade 4.

His sister and brother were 21 and 20 yr old. His sister is healthy but his brother has the same signs and symptoms in his toenails and fingernails (Fig.2). All observed nail abnormalities were a similar pattern of ticking and detachment of the nail from the nail bed of fingernails and toenails

in both boys of this family. He had 16 aunt and uncles with no problem in their nails.

He is married and his non-consanguineous wife from another country of the Ardabil Province. She was healthy and they had no child.



**Fig. 2:** Hands and feet of the affected brother at the age of 20 year

Genomic DNA was obtained from blood samples from the proband. We suggested him to test his family.

Informed consent was obtained from his family and this study complied with the Declaration of Helsinki Principles. Clinical information and dermatologic examination were obtained for his family members with particular attention to nails. Permission to undertake the study was obtained from the Ethics Committee of Alborz University of Medical Sciences (Ethics Code:1395103), Karaj, Iran. Written informed consent was obtained from all patients.

#### **Mutation detection**

5 ml venous blood was obtained from the proband and was collected in EDTA-coated tubes. The genomic DNA was extracted using the Nucleospin® DNA extraction kit (Macherey-Nagel, Düren, Germany). All seven coding exons and flanking splicing junctions of the candidate *FZD6* gene associated with autosomal recessive non-

syndromic congenital Nail Dysplasia was amplified using polymerase chain reaction (PCR), using the primers listed in Table1. Exon 4 was amplified into two overlapping parts so as to have shorter fragments. Each reaction

mixture (25 µl) contained 20 ng genomic DNA, 1X PCR buffer, 1.5 mM MgCl<sub>2</sub>, 0.2 mM dNTPs, 0.5 µM forward primer, 0.5 µM reverse primer and 2.5 Units Taq DNA polymerase (Qiagen, Mississauga, ON, Canada).

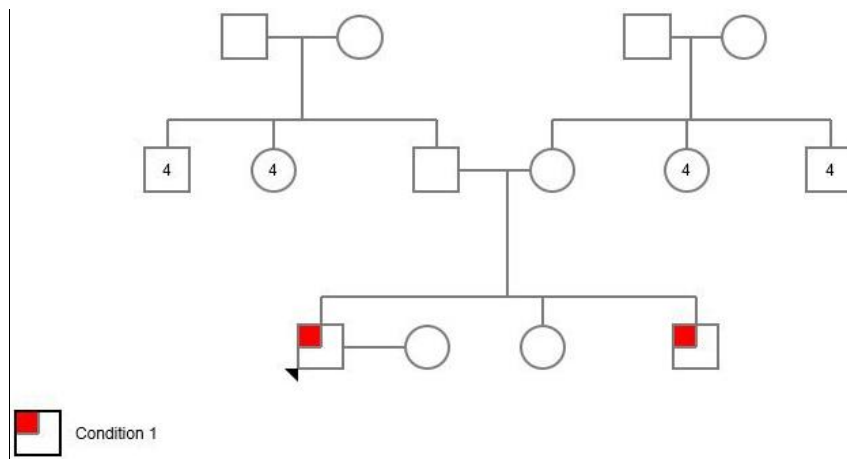
**Table 1:** Polymerase chain reaction primers for specific amplification of FZD6 gene

Exon	Primer sequence		Tm
2	Forward: 5'- GGGGATCTTCTGAGGATGCAA-3'	Reverse: 5'-ACACAACCTTGAAGAAATCGGCT-3'	58°
3	Forward: 5'- AGTTCATAAGTCTGATAGAGGGAGA-3'	Reverse: 5'- CCAGAGAGCTAGTACCAGTAGTAAA-3'	62°
4-1	Forward: 5'-TGCATTTTCATGTTACCTGCT-3'	Reverse: 5'-TGCTCGATGGCTTCACAACT-3'	60°
4-2	Forward: 5'-TGTGCAACTCTGTTACATTCC-3'	Reverse: 5'-TGGCTCTTGTATTTTCTCACCT-3'	60°
5	Forward: 5'-TCCCCTTTCTAGAGATTTGGTACA-3'	Reverse: 5'-ACATTGATTTGAACAGTTCCCTTGGT-3'	62°
6	Forward: 5'-TCITGTCCTTAATTTCTITGCCAGT-3'	Reverse: 5'-AGGCTGAACCCAAACTTCCT-3'	58°
7	Forward: 5'-TGGACACTGGTTAGGGGTGA-3'	Reverse: 5'-ACAGTGCATAGGTCACITCCA-3'	62°

The following PCR program was used for DNA amplification: 95 °C for 5 min; followed by 35 cycles at 95 °C for 30 sec, 57-63 °C for 30 sec (annealing temperature difference according to primer), 72 °C for 30 sec, and a final extension at 72 °C for 10 min. The PCR product of the proband was sequenced using the ABI PRISM Big

Dye Terminator Cycle Sequencing Kit and ABI PRISM 3130 Genetic Analyzer (AB Applied Biosystems Veriti (96 well thermal cycler)). Alleles were discriminated using Codon Code Aligner software.

Pedigree of this family was shown in Fig. 3.



**Fig. 3:** Pedigrees of families analyzed with an autosomal-recessive inherited form of isolated nail dysplasia in this study. Circles and squares represent women and men He has 16 healthy aunt and uncles

Circles and squares represent females and males, respectively. Clear symbols represent unaffected and filled symbols represent affected individuals. After the gene analyzed, the proband was homozygous for *FZD6* mutation c.1531C>T (p. Arg511Cys) (Fig.4). In addition, siblings and par-

ents were also sequenced, to confirm appropriate co-segregation of the allele within the family. His younger affected brother was homozygous for the *FZD6* mutation (Fig. 5). His unaffected parents and sister were all heterozygous for the mutation (Fig. 6).

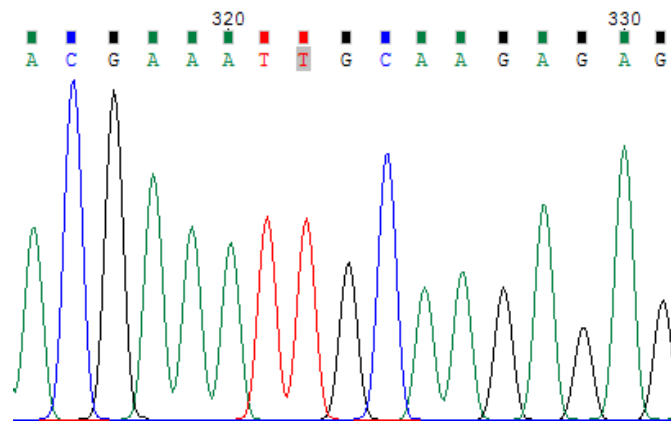


Fig. 4: Homozygous for the FZD6 Mutations Associated with Autosomal-Recessive Nail Dysplasia (proband)

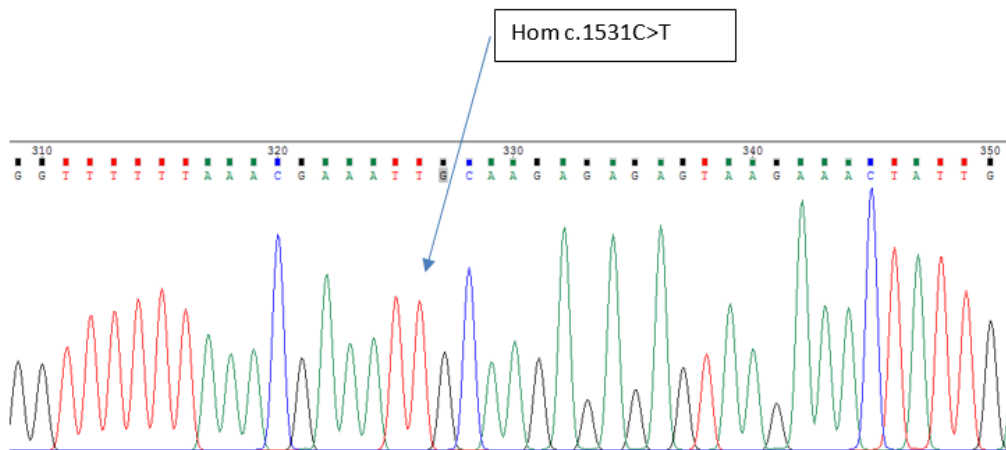


Fig. 5: Homozygous for the FZD6 Mutations Associated with Autosomal-Recessive Nail Dysplasia (His brother: HGC339)

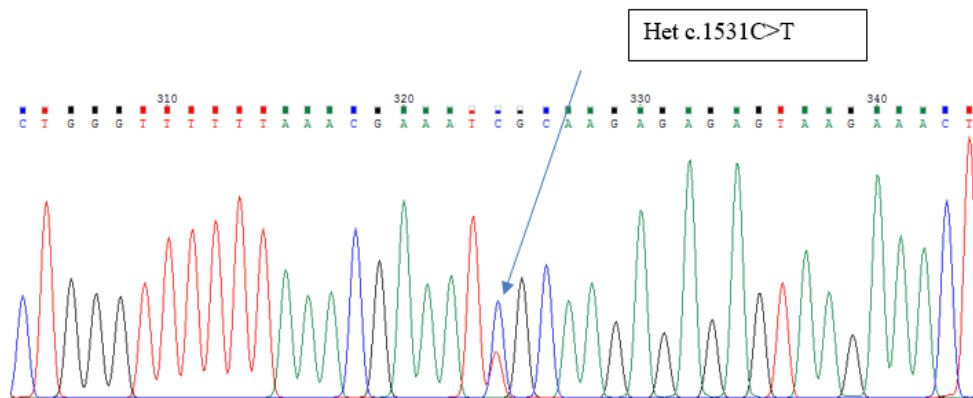


Fig. 6: His unaffected father was heterozygous for the mutation FDZ6 (Father: HGC338)

## Discussion

WNT-FZD signaling is important for the deformation of ectodermal appendages, like claw-shaped nails. It belongs to the Frizzled gene family members that serve as receptors for Wnt signaling proteins. It was mapped on chromosome 8q22.3 (2, 5-8).

Sequence analysis of *FZD6*, as the most promising gene, identified a homozygous missense mutation, in exon 4 of the gene *FZD6* in both affected individuals of our family.

This missense mutation is concordant with S.I. Raza report, identified for the first time, all with Pakistani origin (2, 7).

The missense mutation involves a C to T transition at nucleotide position 1531(c.1531C>T) substituting Arginine with Cysteine at amino acid position 511 (p. Arg511Cys). The two patients were homozygous for variant p. Arg511Cys, their parents and their normal sister were heterozygous, thus the variant co-segregated with the disease phenotype. This is an already known mutation reported for the fourth time in the world and the first time in Iran. The C>T transition changes the codon CGC (encoding arginine) to TGC (encoding cysteine) "rs number 151339003". S.I. Raza reported the same mutation has been previously in another Pakistani family (5, 7).

All proband had a variable degree of nail dysplasia and them homozygous for carrying mutation *FDZ6* (1, 2, 8-10). During normal nail formation, the nail plate must be properly attached to the nail bed. Keratins constitute a major component of the cytoskeleton of the differentiated nail plate, and expression of *FZD6* in the nail plate corresponded to the figure and shape of affected individuals (3, 11).

The missense mutation (p. Arg511Cys) was identified in the present study, lies in the sixth transmembrane domain of the mutant *FZD6*. Considering the effect of the missense mutation (p. Arg511Cys) described the mutation (p. Arg511Cys) lies in the transmembrane domain, it is possible that mutant *FZD6* reaches to the plasma membrane and can affect the binding of

Wnt ligand with *FZD6*, which in turn will affect recruitment of intracellular protein.

Dermatologists should consider the genetic analysis of individuals with hereditary isolated nail dysplasia, which aids in correct genetic counseling for their family.

## Ethical considerations

Ethical issues (Including plagiarism, informed consent, misconduct, data fabrication and/or falsification, double publication and/or submission, redundancy, etc.) have been completely observed by the authors.

## Acknowledgments

We thank the family members involved in this study. We also thank Doctor Gita Gorji, MD & Dermatologist for her assistance with the diagnosis of proband and useful comments.

## Conflict of interest

The authors declare that there is no conflict of interests.

## References

1. Wilson NJ, Hansen CD, Azkur D, et al (2013). Recessive mutations in the gene encoding frizzled 6 cause twenty nail dystrophy--expanding the differential diagnosis for pachyonychia congenita. *J Dermatol Sci*, 70(1):58-60.
2. Frojmark AS, Schuster J, Sobol M, et al (2011) Mutations in Frizzled 6 cause isolated autosomal-recessive nail dysplasia. *Am J Hum Genet*, 88(6):852-60.
3. Cui CY, Klar J, Georgii-Heming P, et al (2013). Frizzled6 deficiency disrupts the differentiation process of nail development. *J Invest Dermatol*, 133(8):1990-7.
4. De Marco P, Merello E, Rossi A, et al (2012). *FZD6* is a novel gene for human neural tube defects. *Hum Mutat*, 33(2):384-90.

5. Khan S, Ansar M, Kamal Khan A, et al (2018). A Homozygous Missense Mutation in SLC25A16 is Associated with Autosomal Recessive Isolated Fingernail Dysplasia in a Pakistani Family. *Br J Dermatol*, 178(2): 556–558.
6. Kasparis C, Reid D, Wilson NJ, et al (2016). Isolated recessive nail dysplasia caused by FZD6 mutations: report of three families and review of the literature. *Clin Exp Dermatol*, 41(8):884-9.
7. Raza SI, Muhammad N, Khan S, Ahmad W (2013). A novel missense mutation in the gene FZD6 underlies autosomal recessive nail dysplasia. *Br J Dermatol*, 168(2):422-5.
8. Naz G, Pasternack SM, Perrin C, et al (2012). FZD6 encoding the Wnt receptor frizzled 6 is mutated in autosomal-recessive nail dysplasia. *Br J Dermatol*, 166(5):1088-94.
9. Kilander MB, Dahlstrom J, Schulte G (2014). Assessment of Frizzled 6 membrane mobility by FRAP supports G protein coupling and reveals WNT-Frizzled selectivity. *Cell Signal*, 26(9):1943-9.
10. Khan S, Basit S, Habib R, Kamal A, Muhammad N, Ahmad W (2015). Genetics of human isolated hereditary nail disorders. *Br J Dermatol*, 173(4):922-9.
11. Krebsova A, Hamm H, Karl S, Reis A, Hennies HC (2000) Assignment of the gene for a new hereditary nail disorder, isolated congenital nail dysplasia, to chromosome 17p13. *J Invest Dermatol*, 115(4):664-7.