

Nonsyndromic palate Synechia with floor of mouth

Access this article online

Website:
www.amsjournal.com

DOI:
10.4103/2231-0746.161102

Quick Response Code:



Sharan Naidoo¹, Kurt W. Bütow^{1,2,3}

¹Department of Maxillofacial and Oral Surgery, Facial Cleft Deformity Clinic, University of Pretoria, Pretoria,

²Department of Health Sciences, University of KwaZulu-Natal, Durban,

³Life Wilgers Hospital, Pretoria, South Africa

Address for correspondence:

Dr. Sharan Naidoo, Department of Maxillofacial and Oral Surgery, University of Pretoria,
P. O Box 1266, Pretoria, 0001, South Africa.

E-mail: sharannaidoo@gmail.com

ABSTRACT

To discuss the embryological basis, sequela and management of intraoral synechia, and to report on the incidence of this condition at a facial cleft deformity clinic (FCDC), with specific attention to two rare cases of mucosal bands involving the floor of the mouth and palate. Review of the literature and a retrospective analysis of FCDC and case report of two cases. During the period of 30 years (1983–2013), the FCDC - University of Pretoria has managed in excess of 4000 cases. A review of the clinic statistics revealed only six cases in which intraoral synechia occurred. The rarity of this condition at the FCDC is in keeping with the rare incidence in the international literature. Four syndromic cases were identified. Three cases were cleft palate lateral synechia syndrome, and one was an orofacial digital syndrome. Two nonsyndromic cases were identified, and both cases involved the floor of the mouth and palate. The attending physicians and surgeons should be aware of the most appropriate timing for management of this condition, in order to avoid unwanted sequelae. Supportive care should be provided, and emergency airway protocol should be available for all cases. A differential diagnosis should be considered which includes syndromic conditions.

Keywords: Floor of the mouth, palate, synechia

INTRODUCTION

Synechia is a broad term which describes a fibrous or soft tissue connection between anatomical structures.^[1] Oral synechia presents in many different configurations usually involving the intraoral maxillary and mandibular structures.^[2] Congenital oral synechia is a rare phenomenon with only a few documented cases in the literature.^[1,2]

The soft tissue fusion may be complete or incomplete, and may present as an isolated malformation or occur in the presence of other abnormalities.^[2]

This condition may be associated with syndromes or may less commonly be nonsyndromic. The syndromes which are associated are Demarque-Van der Woude syndrome (DVWS), popliteal pterygium syndrome (PPS) [Figures 1 and 2], cleft palate lateral alveolar synechia syndrome, orofacial digital syndrome (OFDS) and Frys syndrome.^[2,3,4]

Various pathogenetic mechanisms have been proposed, however no single suggestion can be validated. This article describes two

cases of an uncommon presentation of nonsyndromic intraoral floor of the mouth synechia.

CASE REPORTS

Case 1

A 6-week-old baby was referred to the facial cleft deformity clinic (FCDC)-University of Pretoria with a diffuse mucosal band extending from the floor of the mouth to the palate [Figures 3 and 4]. The weight was 3.2 kg and the birth weight was reported to be 2.5 kg. The baby received nasogastric feeds since after birth.

There was an associated mandibular retrusion and limited mouth opening. It was elected to perform an endoscopic oral examination under inhalation anesthesia, to exclude other congenital abnormalities beyond the mucosal bands. An associated soft palate cleft and 40% hard palate cleft was noted, with no further abnormalities.

The mucosal banding was separated with the aid of an electrocautery. This releases the mandibula and resulted in

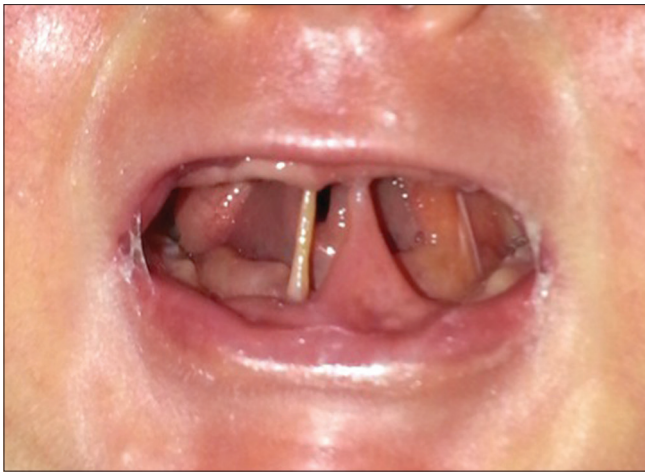

Figure 1: Oral synechia in popliteal pterygium syndrome

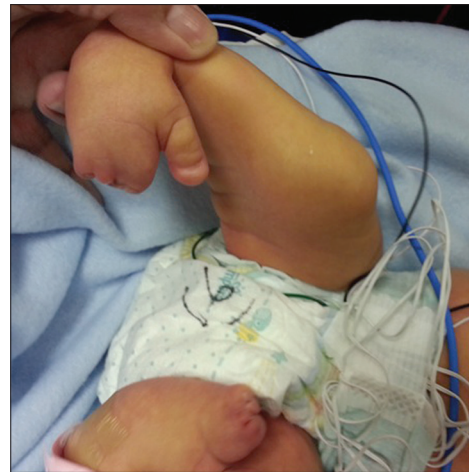

Figure 2: Limb deformities in a patient with popliteal pterygium syndrome and oral synechia

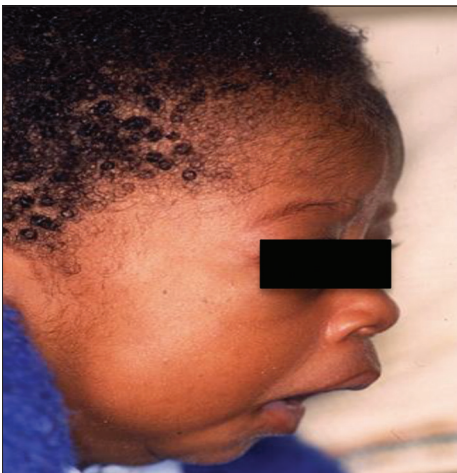

Figure 3: Preoperative lateral facial profile

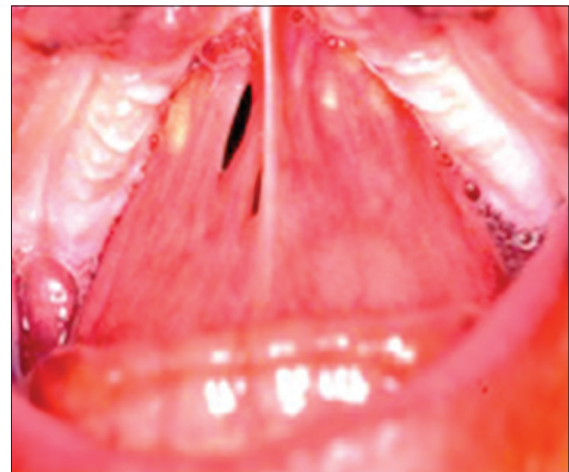


Figure 4: Intra-surgical view for synechia repair. Note the surgical slit for endoscopic examination beyond the defect

improved mouth opening with significant feeding benefits [Figure 5]. Mandibular catch-up growth was noted at the long-term follow-up. The soft and hard palate defect was reconstructed at a later stage.

Case 2

A 17-day-old female was referred to the FCDC from a rural hospital. The baby was born at 38 weeks gestation with apgar scores 9/10 and 10/10. The child was born with low birth weight and as a result was managed with nasogastric feeds in neonatal Intensive Care Unit.

At the time of consultation, the baby received expressed breast milk through cup feeds. The baby presented with a mucosal band extending from the floor of the mouth associated with the left sublingual gland [Figures 6 and 7], to the edges of the complete soft and partial (25%) hard palate cleft, which obstructed anterior posturing of the tongue. Surgical transection of the band was performed under inhalation anesthesia since endotracheal intubation was deemed too difficult.

Immediately, after removal of the band, it was noted that the tongue was displaced into the nasopharynx [Figure 8].

A glossopexy [Figure 9] was performed to maintain the tongue in an anterior position so as to prevent airway obstruction.

The baby progressed well and was discharged to homecare after 1 week following the procedure.

DISCUSSION

During the 7th week of embryological development, normal oral development depends on the downward and forward movement of the tongue to allow for the palatal shelf fusion in the midline. The tongue protrudes through the oral cavity and as a result prevents fusion of the oral components. With the absence of tongue protrusion, prolonged contact between the alveolar arches results in the fusion.^[2,5]

A number of theories regarding the pathogenesis of oral synechia have been proposed, which were all based on abnormalities occurring during embryological development. In the publication of Dinardo *et al.* it is mentioned that Hayward and co-worker postulated the connections to be a result of the close contact of

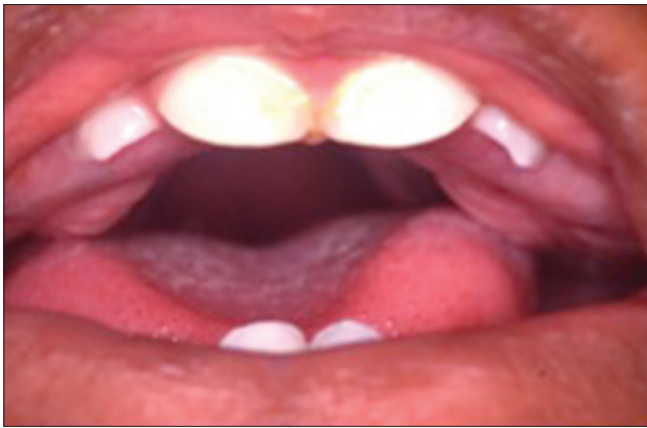

Figure 5: Posttransection mandibular catch-up growth

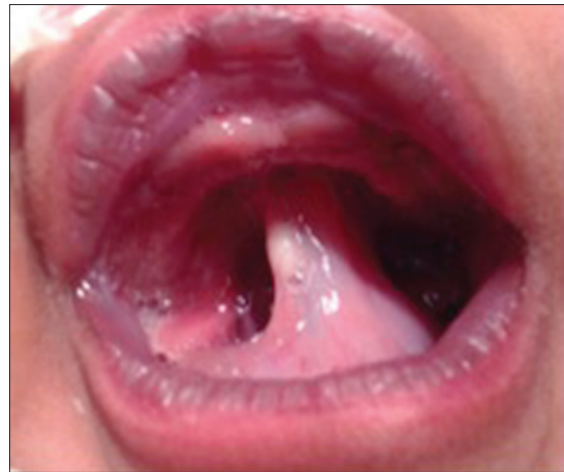

Figure 6: Oral synechia in case report 2

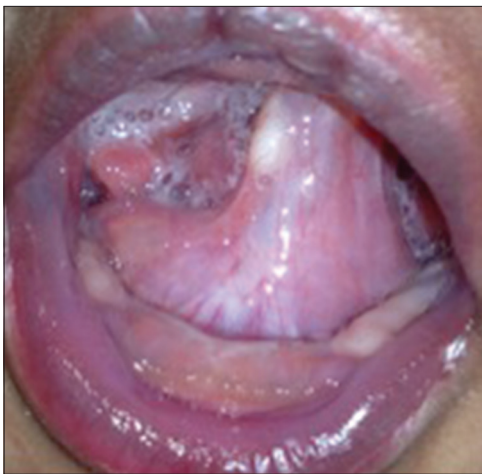

Figure 7: Oral synechia (central and left)

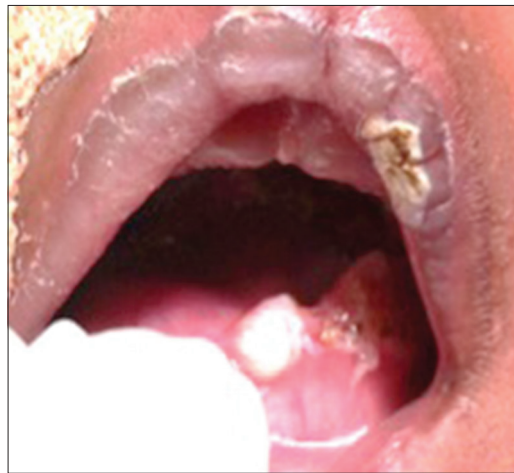

Figure 8: Immediate posttransection of the synechial band

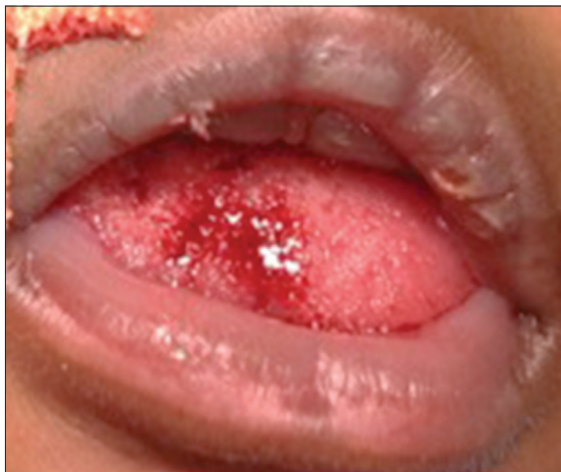

Figure 9: Glossopexy in case report 2 to alleviate airway compromise

the palate to the epithelium of the alveolar ridge or floor of the mouth. A commonly accepted theory proposed by Mathis in 1962 suggested that these fibrous bands to be remnants of the buccopharyngeal membrane.^[1]

Goodacre and co-worker are quoted to concur with the theory suggested by Mathis, but also implicated the presence of amniotic

bands in the vicinity of the developing branchial arches as another plausible etiological factor. Environmental factors, such as meclozine and high dosage Vitamin A, genetic insults and other teratogenic agents which result in failure of migration of mesodermal elements into the midline structures, should never be discounted as possible causative factors.^[2,5] Gartland is quoted to have proposed two etiological theories for cleft palate lateral synechiae syndrome. The first is due a persistent buccopharyngeal membrane, which prevents closure of the palate and causing entrapment of the soft tissue between the cleft margins. The second theory is as a result of a subglossopalatal membrane which forms prior to the development of the cleft, and displaces the tongue into the nasal cavity, resulting in closure approximation of the associated structure with subsequent tissue fusion.^[3]

It has been suggested that the presence of oral banding and cleft palate be regarded as a sequence. This was based on the premise that the pathological membrane prevented anterior and forward movement of the tongue, which in-turn prevented midline fusion of the palatal shelves and resulted in the formation of a cleft palate deformity.^[6]

Oral synechia may present as an isolated abnormality or as a component of the syndrome. Common syndromic associations

occur with DVWS, PPS, OFDS, cleft palate lateral synechia syndrome and Fryns syndrome.^[2,3,6]

Demarque-Van Der Woude syndrome appears to be a less severe form of PPS based on etiological and genetic similarities. Abnormalities in the interferon regulatory factor 6 have been implicated in the DVWS-PPS disease spectrum. DVWS is associated with lip pitting, cleft lip and/or palate, dental defects, limb abnormalities, cardiovascular defects and Hirschsprung disease.^[4,7] PPS is a rare condition with an autosomal dominant mode of inheritance and is associated with popliteal webbing, syndactyly and nail defects. A variable involvement of oral structures may include features similar to DVWS.^[6]

Orofacial digital syndrome is a genetic condition involving abnormalities of the face, oral cavity and digits of both upper and lower limbs. Oral features of this condition include hyperplastic frenums, pseudo-clefting of the upper lip, tongue abnormalities, cleft palate and high arched palate. Hard tissue features include abnormalities of the anterior teeth ranging from hypoplasia to supernumerary or missing teeth.^[8]

Cleft palate-lateral synechia syndrome is a condition first described by Fuhrmann and co-workers in 1972, which composed of mucosal banding from the floor of the mouth to margins of the cleft and micrognathia. There is great variability in the expression of the banding, which ranges from a thin friable membrane to thick mucosal bands.

Fryns syndrome was first described in 1979 as a “variable multiple congenital anomaly syndrome,” and constituted of major features involving a coarse face with microformed eyes with clouded corneas, soft palate clefting, lung and diaphragm abnormalities. Deformities of the distal limbs were also noted. This condition has been identified to have an autosomal recessive inheritance pattern and is significantly lethal in the neonatal period of development.^[9]

Oral bands cause significant feeding difficulties either by preventing the baby from latching on to the nipple or by obstructing the passage of feeds into the oral cavity.^[5] Suckling is almost impossible, and hypoglycemia may set in at an early stage.^[6] Feeding has to be invariably done through an enteral tube. A nasogastric tube may be utilized for this purpose; however care should be taken to assess if the tube results in nasal obstruction. The baby should be kept in 45° head elevation to reduce to chances of vomiting.^[6] Alternatively an orogastric tube may be advanced through the oral aperture after an endoscopic assessment. If these interventions are unsuccessful, the patient should be considered as a candidate for a percutaneous enterogastric tube. These feeding access procedures are essential interventions for weight gain as part of preparation for surgical treatment under general anesthesia.^[5]

When surgical transection of the band is elected, this may be achieved by merely disrupting the band with the aid of a surgical blade or electrocautery device. It is the authors preference to

utilize an electrosurgery unit with a needle-tip Colorado needle (Stryker Leibinger Inc., USA) as it allows for precise surgical and hemostatic control throughout the procedure. The selection of anesthetic techniques must be given serious consideration. Intubation is challenging and would be needed to be performed in a blind fashion. An alternative would be to provide inhalation anesthesia, while the surgeon expedites transection of the band. As the airway remains a priority in these patients, provision should always be made for an emergency surgical airway.^[9]

Timing of the surgical intervention depends on whether the patient presents with an airway problem. The bands need to be transected as soon as possible. Surgery may be delayed for 2–3 weeks if feeding is a problem. This window allows for nutritional supplementation and weight gain. Adequate mouth opening is usually achieved after excision of the band.^[10]

CONCLUSION

The buccopharyngeal membrane initially serves as a barrier between the primitive oral cavity and the oropharynx. Complete or partial persistence of the buccopharyngeal membrane results in oral banding.^[1,2,5,6,8] Management of these patients rests on securing a definitive airway, provision of nutritional support, and resection of the bands at an early age, in order to prevent growth abnormalities and ankylosis.

REFERENCES

1. Dinardo NM, Christian JM, Bennett JA, Shutack JG. Cleft palate lateral synechia syndrome. Review of the literature and case report. *Oral Surg Oral Med Oral Pathol* 1989;68:565-6.
2. Bozdog S, Erdev O, Konas E, Tuncbilek G, Dilmel U. Management of serious isolated gingival synechia in a newborn: Case report and review of the literature. *Int J Oral Maxillofac Surg* 2011;40:1428-31.
3. Donepudi SK, Stocks RM, Pivnick EK, Mineck C, Thompson JW. Cleft palate lateral synechia syndrome: An opportunity for unique surgical closure. *Int J Pediatr Otorhinolaryngol* 2009;73:861-6.
4. Redelinghuys IF, de Witt TW. Demarquay-Van Der Woude syndrome - Incidence and surgical treatment of the lower lip. Vol. 6: *Hands-On, Hanson*; 1994. p. 37-9.
5. Steinberg B, Saunders V. Popliteal pterygium syndrome. *Oral Surg Oral Med Oral Pathol* 1987;63:17-20.
6. Garca MF, Goktas U, Isik Y, Isik D. Is the coexistence of intraoral synechia and cleft palate anomaly a sequence? *J Craniofac Surg* 2012;23:e194-5.
7. Svee A, Frykholm P, Linder A, Hakelius M, Skoog V, Nowinski D. Early release of interalveolar synechia under general anesthesia through fiberoptic nasal intubation. *J Craniofac Surg* 2012;23:e299-302.
8. Soneji B. Duplication of the mandibular primary dentition in orofacial-digital syndrome type IV. *Cleft Palate Craniofac J* 2010;47:259-63.
9. Jaeger A, Kapur R, Whelan M, Leung E, Cunningham M. Cleft-palate lateral synechia syndrome: Insight into the phenotypic spectrum of Fryns syndrome? *Birth Defects Res A Clin Mol Teratol* 2003;67:460-6.
10. Sahin U, Ozdil K, Ussetin I, Saylkan S, Oktem F, Yuce S, *et al*. Cleft palate and congenital alveolar synechia syndrome. *Plast Reconstr Surg* 2005;115:1212-3.

Cite this article as: Naidoo S, Bütow KW. Nonsyndromic palate Synechia with floor of mouth. *Ann Maxillofac Surg* 2015;5:100-3.

Source of Support: Nil, **Conflict of Interest:** None declared.