

Does the occurrence of pleomorphic xanthoastrocytoma in the elderly carries a poor prognosis: A case report and review of literature

Mayur Sharma, Shubnum Chaudhery¹, Ashish Sonig, Sudheer Ambekar, Anil Nanda

Departments of Neurosurgery and ¹Pathology, Louisiana State University Health Science Center, Shreveport, Louisiana, USA

ABSTRACT

Pleomorphic xanthoastrocytoma (PXA) is a rare slow growing tumor which accounts for <1% of all astrocytic neoplasms. PXA usually affects young patients in their second decade of life and carries a favorable prognosis. We present the clinical, radiological and histopathological features of PXA involving the left temporal lobe in an 84-year-old male with right upper motor neuron facial paresis of 2 weeks duration. Histopathology confirmed the diagnosis of PXA. Our case is unique in that our patient is the oldest one reported in the literature with favorable histopathological features. The occurrence of these tumors in elderly patients may indicate an aggressive behavior with unfavorable outcome. Gross total resection achieves higher recurrence free and overall survival rates.

Key words: Elderly, pleomorphic, prognosis, xanthoastrocytoma

Introduction

Pleomorphic xanthoastrocytoma (PXA) accounts for <1% of all astrocytic tumors. PXA was first described by Kepes *et al.*^[1] in 1979 as a distinct clinicopathological entity in 12 young patients and was subsequently classified as Grade 2 astrocytoma by WHO in 1993.^[2] PXAs are slow growing tumors and usually affect young patients in their second decade of life with no gender predilection.^[3,4] Headache and long-standing seizures are the typical presenting features.^[5,6] PXAs are superficial tumors with a predilection for the temporal lobe followed by parietal, frontal and occipital lobes. Other rare locations are cerebellum, spinal cord and retina.^[3] Despite favorable prognosis, malignant transformation in PXA has been described as an anaplastic variant.^[3,7,8]

Although PXA commonly affects young patients, this entity has been described in elderly patients with variable

prognosis.^[5,6,9] We present a rare case of PXA involving the left temporal lobe in an 84-year-old male with right upper-motor neuron (UMN) facial paresis. Our case is unique in that our patient is the oldest one reported in the literature with benign histopathological features.

Case Report

An 84-year-old white male presented to the outpatient department with right sided facial droop of 2 weeks duration. The weakness was gradual in onset and was not associated with extremity weakness. There was no history of diminished sensations over the face or similar episodes in the past. He denied any history of trauma, seizures, vomiting, fever or other associated symptoms.

On examination, higher mental functions were normal. There was an -UMN type of facial paresis on the right side. Rest of the cranial nerves and neurological examination was normal.

Computed tomography scan of the brain with and without contrast revealed an intra-axial heterogeneously enhancing mass in the left temporoparietal region. Magnetic resonance imaging (MRI) scan of the brain revealed an intra-axial solid lesion in the left temporo-parietal region extending into the left insula. The lesion was hypo to isointense on T1-weighted images, heterogeneously hyperintense on T2-weighted and showed heterogeneous enhancement on gadolinium contrast [Figure 1].

The patient underwent a left temporal craniotomy under stealth guidance using a linear incision over the left temporal

| Access this article online | |
|---|----------------------------------|
| Quick Response Code: | Website: www.asianjns.org |
|  | DOI: 10.4103/1793-5482.146635 |

Address for correspondence:

Dr. Anil Nanda, Department of Neurosurgery, Louisiana State University Health Sciences, 1501 Kings Highway, Shreveport, Louisiana 71130-3932, USA. E-mail: ananda@lsuhsc.edu

region. The tumor was intra-axial in location, grayish white in color and with well-defined margins. A gross total excision was achieved.

Histopathological examination revealed markedly pleomorphic tumor composed of cells with epithelioid appearance and scattered xanthic cells. Cells with hyperchromatic, pleomorphic nuclei, at times, multinucleated with only scant bright eosinophilic granular bodies were present. Intranuclear inclusions were also noted. Despite the pleomorphic appearance and cellularity, mitotic activity was very low with Ki-67/MIB-1 labeling index from low to focally moderate (4-6%). The reticulin stain highlighted the presence of pericellular reticulin network which was helpful in differentiating PXA from higher grade gliomas. The tumor cells were diffusely immunoreactive for glial fibrillary acidic protein (GFAP), focally immunoreactive for synaptophysin and negative for chromogranin. Neurofilament demonstrated a paucity of entrapped neurites at the center of the tumor, but abundant entrapped neurites within the tumor periphery, supporting the morphologic interpretation that the tumor was infiltrative. The tumor cells showed weak staining for p53 [Figures 2 and 3].

In the postoperative period facial nerve function had gradually improved. Postoperative MRI scan showed gross total excision of the tumor [Figure 4]. However, the patient lost to follow-up and subsequently expired 3 months after the procedure.

Discussion

Pleomorphic xanthoastrocytoma is a rare slow growing astrocytic tumor. These tumors usually originate in the supratentorial compartment with a predilection for the temporal lobe.^[3,6] They are thought to arise from the subpial astrocytes due to the presence of “basal lamina,” which is a characteristic feature of these astrocytes.^[1,2,10,11] Affected patients are usually in their first three decades of life.^[3,5,9,12] Ng *et al.*^[6] reported a left fronto-temporal PXA in a 76-year-

old female, who was managed with subtotal excision and palliative radiation therapy. However, the patient expired 6 months later due to the rapid progression of the tumor. Perry *et al.*^[9] described a composite PXA and ganglioglioma in an 82-year-old male patient involving the left frontal lobe, who was subsequently lost to follow-up. Similarly, Bucciero *et al.*^[5] reported an atypical PXA in a 65-year-old man involving the left capsulo-thalamic region who was managed with subtotal excision and fractionated external beam radiotherapy. The patient expired 22 months after the excision due to a massive recurrence of the tumor. Our patient was an 84-year-old male who was managed with gross total resection [Table 1].

The characteristic histopathological features of PXA as described by Kepes *et al.* includes marked cellular pleomorphism with spindle cells, multinucleated giant cells with bizarre nuclei, prominent lipid droplets, eosinophilic granular bodies, perivascular lymphocytic infiltration and dense reticulin network. Mitotic figures are rare, and necrosis is usually absent.^[1,12] On immunohistochemical analysis, GFAP and S-100 is positive in all tumors.^[12] Synaptophysin reactivity ranges from 38% to 100% and neurofilament protein expression is seen in 8-71% of tumors.^[3,12,13]

Although PXA has been described as a tumor with a favorable prognosis, 20% of these tumors can undergo malignant transformation and classified as anaplastic PXA.^[3,6-8,14] Various factors such as increased mitotic activity, high Ki-67, MIB-1, proliferating cell nuclear antigen labeling index, endothelial proliferation, presence of necrosis, diffuse proliferation of monomorphic cells, decreased reticulin fibers and the extent of surgical resection, have been shown to predict the unfavorable outcome in patients with PXA.^[3,6,7,9,12,15] In the present case, there were no unfavorable histopathological features. Similarly Ng *et al.*^[6] reported the presence of necrosis with low MIB-1 index in a 76-year-old female patient with adverse outcome. In contrast Bucciero *et al.*^[5] reported a case

Table 1: Cases of PXA in elderly patients reported in the literature

| Authors | Gender/age (years) | Location | Presentation | Management | Pathological features | Outcome |
|--|--------------------|-----------------------------|---|--|---|---|
| Bucciero <i>et al.</i> 1997 ^[5] | Male/65 | Left capsulothalamic region | Impaired consciousness speech difficulties and right hemi paresis | Subtotal excision and fractionated EBRT* | Atypical with increased mitosis, cellularity and areas of necrosis | Expired 22 months later due to recurrence |
| Perry <i>et al.</i> 1997 ^[9] | Male/82 | Left frontal lobe | Mental changes | Excisional biopsy | Composite PXA and ganglioglioma, MIB index 5.6%, no vascular proliferation or mitosis | Lost to follow-up |
| Ng <i>et al.</i> 2008 ^[6] | Male/76 | Left frontotemporal | Dysphasia and right hemiparesis | Subtotal excision and palliative radiation therapy | MIB index <4%, with areas of necrosis and infarction | Expired 6 months later due to recurrence |
| Present case 2013 | Male/84 | Left temporoparietal | Right UMN facial paresis | Gross total excision | MIB-1 index-4-6% with no necrosis | Lost to follow-up and subsequently expired three months after the procedure |

*External beam radiation therapy. PXA – Pleomorphic xanthoastrocytoma; UMN – Upper-motor neuron

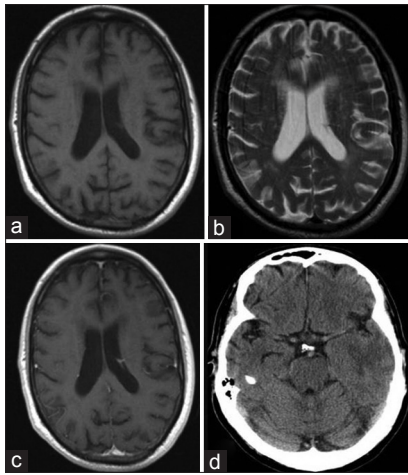


Figure 1: Preoperative (a) magnetic resonance imaging (axial view) T1-weighted image. (b) T2-weighted axial image. (c) Postgadolinium contrast enhanced MRI image. (d) Noncontrast computed tomography scan of the brain showing an intra-axial heterogeneously enhancing mass in the left temporoparietal region

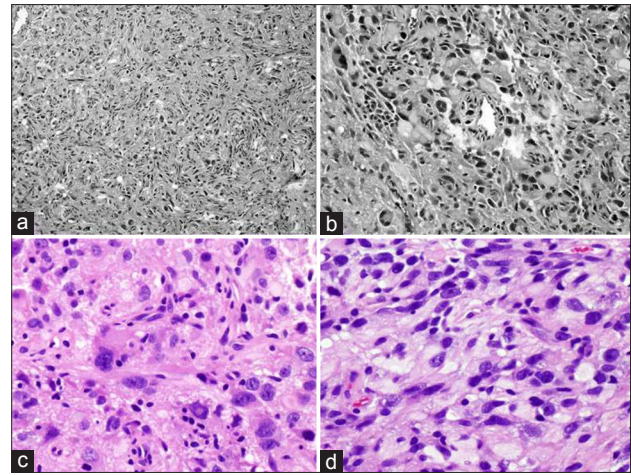


Figure 2: Histopathological examination (a) low-power image shows a markedly pleomorphic tumor with epithelioid appearance as well as scattered xanthic cells arranged in a somewhat fascicular architecture. (b) Cellular pleomorphism with mononucleated and multinucleated giant cells. (c) Enlarged, irregular nuclei with hyperchromasia and intranuclear cytoplasmic invaginations. (d) Large xanthomatous cells with abundant cytoplasmic vacuolization

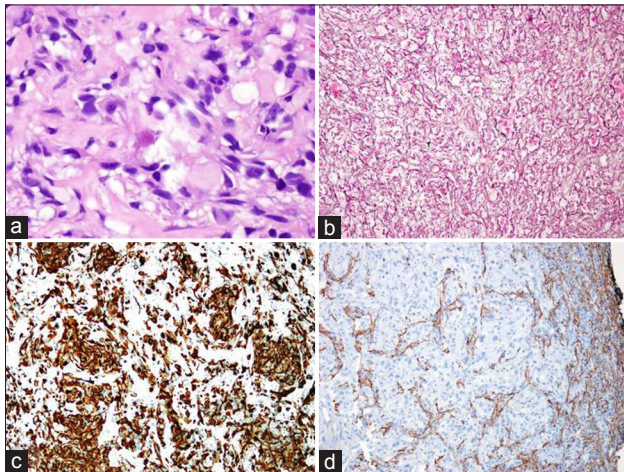


Figure 3: Histopathological examination (a) showing few scattered eosinophilic granular bodies. (b) A rich reticulin network surrounds individual cells and small cell nests. (c) The tumor cells are diffusely positive for glial fibrillary acidic protein immunoperoxidase stain. (d) Neurofilament demonstrates increasing entrapped neurites at the periphery of the tumor

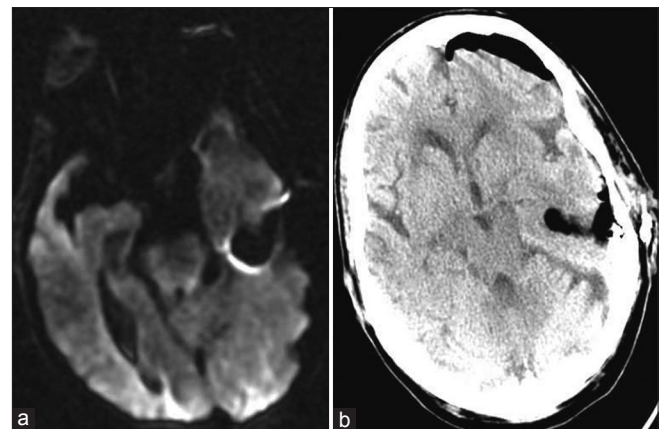


Figure 4: Postoperative (a) magnetic resonance imaging brain (axial image). (b) Computed tomography scan of the brain without contrast showing gross total excision of the lesion

of anaplastic PXA in a 65-year-old male with the presence of necrosis, increased mitosis and cellularity with a poor outcome. Mackenzie^[16] described a specific histological variant of PXA in a 62-year-old male suggesting an aggressive behavior. These reports may suggest an aggressive variant of PXA in elderly patients.

The extent of surgical resection is an important predictor of outcome in patients with PXA.^[3,12] Adjunct treatment (radiotherapy and/or chemotherapy) can be offered to patients with recurrent or partially resected tumors or those with unfavorable histological features.^[12,15] Overall survival ranges between 70% and 80% at 5 and 10 years follow-up after gross total resection.^[3]

Conclusion

Pleomorphic xanthoastrocytoma is a rare slow growing tumor of glial origin. These tumors generally have a favorable prognosis in young patients. The occurrence of these tumors in elderly patients may display aggressive behavior despite favorable histological features. Gross total resection is required to achieve higher recurrence-free and overall survival rates.

References

1. Kepes JJ, Rubinstein LJ, Eng LF. Pleomorphic xanthoastrocytoma: A distinctive meningeocerebral glioma of young subjects with relatively favorable prognosis. A study of 12 cases. *Cancer* 1979;44:1839-52.
2. Kepes JJ. Pleomorphic xanthoastrocytoma: The birth of a diagnosis and a concept. *Brain Pathol* 1993;3:269-74.
3. Giannini C, Scheithauer BW, Burger PC, Brat DJ, Wollan PC, Lach B, *et al.* Pleomorphic xanthoastrocytoma: What do we really know about it? *Cancer* 1999;85:2033-45.

4. Herpers MJ, Freling G, Beuls EA. Pleomorphic xanthoastrocytoma in the spinal cord. Case report. *J Neurosurg* 1994;80:564-9.
5. Bucciero A, De Caro M, De Stefano V, Tedeschi E, Monticelli A, Siciliano A, *et al.* Pleomorphic xanthoastrocytoma: Clinical, imaging and pathological features of four cases. *Clin Neurol Neurosurg* 1997;99:40-5.
6. Ng WH, Lim T, Yeo TT. Pleomorphic xanthoastrocytoma in elderly patients may portend a poor prognosis. *J Clin Neurosci* 2008;15:476-8.
7. Bayindir C, Balak N, Karasu A, Kasaroglu D. Anaplastic pleomorphic xanthoastrocytoma. *Childs Nerv Syst* 1997;13:50-6.
8. Lubansu A, Rorive S, David P, Sariban E, Seligmann R, Brotchi J, *et al.* Cerebral anaplastic pleomorphic xanthoastrocytoma with meningeal dissemination at first presentation. *Childs Nerv Syst* 2004;20:119-22.
9. Perry A, Giannini C, Scheithauer BW, Rojiani AM, Yachnis AT, Seo IS, *et al.* Composite pleomorphic xanthoastrocytoma and ganglioglioma: Report of four cases and review of the literature. *Am J Surg Pathol* 1997;21:763-71.
10. Gill M, Pathak HC, Madan R, Bhattacharya S, Choudhary GS. Primary spinal pleomorphic xanthoastrocytoma. *Neurol India* 2010;58:771-3.
11. Nakamura M, Chiba K, Matsumoto M, Ikeda E, Toyama Y. Pleomorphic xanthoastrocytoma of the spinal cord. Case report. *J Neurosurg Spine* 2006;5:72-5.
12. Sharma A, Nand Sharma D, Kumar Julka P, Kishor Rath G. Pleomorphic xanthoastrocytoma-a clinico-pathological review. *Neurol Neurochir Pol* 2011;45:379-86.
13. Giannini C, Scheithauer BW, Lopes MB, Hirose T, Kros JM, VandenBerg SR. Immunophenotype of pleomorphic xanthoastrocytoma. *Am J Surg Pathol* 2002;26:479-85.
14. Asano K, Miyamoto S, Kubo O, Kikkukawa T, Yagihashi A, Ohkuma H. A case of anaplastic pleomorphic xanthoastrocytoma presenting with tumor bleeding and cerebrospinal fluid dissemination. *Brain Tumor Pathol* 2006;23:55-63.
15. Macaulay RJ, Jay V, Hoffman HJ, Becker LE. Increased mitotic activity as a negative prognostic indicator in pleomorphic xanthoastrocytoma. Case report. *J Neurosurg* 1993;79:761-8.
16. MacKenzie JM. Pleomorphic xanthoastrocytoma in a 62-year-old male. *Neuropathol Appl Neurobiol* 1987;13:481-7.

How to cite this article: Sharma M, Chaudhery S, Sonig A, Ambekar S, Nanda A. Does the occurrence of pleomorphic xanthoastrocytoma in the elderly carries a poor prognosis: A case report and review of literature. *Asian J Neurosurg* 2014;9:237-8.

Source of Support: Nil, **Conflict of Interest:** None declared.