

## Clinical Article

# Accuracy of Pedicle Screw Insertion Using Fluoroscopy-Based Navigation-Assisted Surgery : Computed Tomography Postoperative Assessment in 96 Consecutive Patients

Keong Duk Lee, M.D.,<sup>1</sup> In Uk Lyo, M.D.,<sup>1</sup> Byeong Seong Kang, M.D.,<sup>2</sup> Hong Bo Sim, M.D.,<sup>1</sup> Soon Chan Kwon, M.D.,<sup>1</sup> Eun Suk Park, M.D.<sup>1</sup>

Departments of Neurosurgery,<sup>1</sup> Radiology,<sup>2</sup> Ulsan University Hospital, Ulsan, Korea

**Objective :** Two-dimensional fluoroscopy-based computerized navigation for the placement of pedicle screws offers the advantage of using stored patient-specific imaging data in providing real-time guidance during screw placement. The study aimed to describe the accuracy and reliability of a fluoroscopy-based navigation system for pedicle screw insertion.

**Methods :** A total of 477 pedicle screws were inserted in the lower back of 96 consecutive patients between October 2007 and June 2012 using fluoroscopy-based computer-assisted surgery. The accuracy of screw placement was evaluated using a sophisticated computed tomography protocol.

**Results :** Of the 477 pedicle screws, 461 (96.7%) were judged to be inserted correctly. Frank screw misplacement [16 screws (3.3%)] was observed in 15 patients. Of these, 8 were classified as minimally misplaced ( $\leq 2$  mm); 3, as moderately misplaced (2.1–4 mm); and 5, as severely misplaced ( $>4$  mm). No complications, including nerve root injury, cerebrospinal fluid leakage, or internal organ injury, were observed in any of the patients.

**Conclusion :** The accuracy of pedicle screw placement using a fluoroscopy-based computer navigation system was observed to be superior to that obtained with conventional techniques.

**Key Words :** Accuracy · Pedicle screw · Fluoroscopy-based navigator.

## INTRODUCTION

Transpedicle screw insertion is commonly used to treat various spinal disorders, including fractures, scoliosis, spondylolisthesis, and degenerative instabilities. Pedicle screw insertion is a delicate operation because of the variability in the width, height, and spatial orientation of the spinal pedicles. In performing a conventional procedure with a posterior approach to the spine, a surgeon uses his/her anatomical knowledge to define the entry point of the pedicle in the dorsal part of the vertebra. Pilot holes are prepared, and screws are inserted into the pedicle without any direct visual control. A slight error in direction may result in a significant error in the position of the tip of the screw. Previous studies on conventional surgical procedures have shown a significant rate of incorrect pedicle screw placement

(range, 15–40%)<sup>17,19</sup>. Furthermore, clinical studies that performed adequate postoperative computed tomography (CT) assessments also observed pedicle screw malpositioning at rates of 13.4–40% for conventional procedures<sup>1,8,9</sup>. Screws that perforate the pedicle cortex may increase the risk of dural tearing, neural damage, and vascular or visceral complications. Moreover, malpositioning of pedicle screws may result in the loss of fixation, especially if it occurs at the lower end of a construct. Therefore, proper placement of pedicle screws is important not only for the prevention of neurological injury, but also for the maintenance of long-term spinal stability. Hence, the use of guidance modalities for improving the accuracy of pedicle insertion could offer both immediate and long-term positive outcomes.

This study aimed to assess the results of transpedicle screw insertion as performed using a two-dimensional (2-D) fluoros-

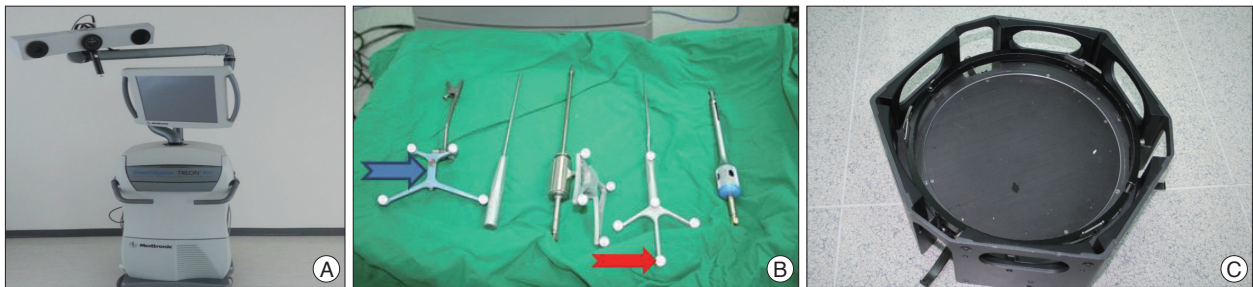
• Received : January 23, 2014 • Revised : May 1, 2014 • Accepted : July 15, 2014

• Address for reprints : In Uk Lyo, M.D.

Department of Neurosurgery, Ulsan University Hospital, 877 Bangeojin Sunhwando-ro, Dong-gu, Ulsan 682-714, Korea

Tel : +82-52-250-7139, Fax : +82-52-250-7138, E-mail : iulyo@uuh.ulsan.kr

• This is an Open Access article distributed under the terms of the Creative Commons Attribution Non-Commercial License (<http://creativecommons.org/licenses/by-nc/3.0>) which permits unrestricted non-commercial use, distribution, and reproduction in any medium, provided the original work is properly cited.



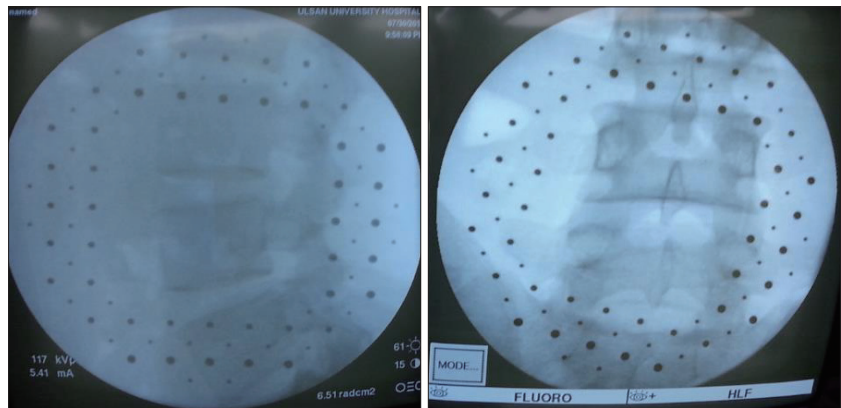
**Fig. 1.** A : Stealth Station Treon Plus® (Medtronic Surgical Navigation Technologies). B : Navigated tools and markers. Each tool is equipped with passive markers (blue arrow). The reference frame (red arrow) is also visible. C : The calibration grid is fixed to the image intensifier and contains radio-opaque elements arranged on 2 parallel plates.

copy-based navigation system.

## MATERIALS AND METHODS

### Patients

We retrospectively reviewed 96 consecutive patients who underwent posterior lumbar fixation with 477 inserted screws between October 2007 and June 2012. All patients presented with intractable pain, neurological signs, or both. In all cases, preoperative CT and magnetic resonance imaging were performed.



**Fig. 2.** Two single radiographic views. The anterior-posterior and lateral views are acquired within the intended operative area.

### System set-up and surgical procedure

All surgeries were performed by a senior spinal neurosurgeon using a standard posterior approach. If required, decompressive procedures were performed, including partial or total facetectomies, discectomies, and laminectomies. All surgeries were performed using a 2-D fluoroscopy-based navigation system. In particular, a 2-D optical localizer [Medtronic; Stealthstation Treon Plus Surgical Navigation (Fig. 1A) and the Mach 4.0™ graphical user interface, which provides target-centric accuracy and color 3-D guidance] was used to track the position of the surgical tools (pointer, bradawl, and screw guide), patient reference frame, and a C-arm image intensifier near the operating table based on passive markers provided for each component and the aid of a 3-D optical localizer (Fig. 1B).

The distortion typically characterizing fluoroscopic images is attributable to 3 factors : 1) the planarity of the image intensifier input screen, 2) the insufficient rigidity of the C-arm, and 3) the surrounding magnetic field. For correcting the image intensifier distortions and calibrating the images, a calibration grid (2 parallel plates with radio-opaque elements arranged along them) (Fig. 1C) was rigidly attached to the input screen of the image intensifier. The aim was to understand the mapping between the image pixels and the “physical” surgical space to calibrate the computer-generated projection of the surgeon’s tool with different radiographic information (e.g., radiographic view from the lateral position in the operating field). The radio-opaque elements in the

lower plate were used to correct the image distortions, while those in the upper plate were used to determine the position of the X-ray source. For determining the position of the X-ray source, passive markers were fixed on the calibration device, and the 3-D optical tracking system was used to localize the fluoroscopic imaging device. The correction of the original images was possible because the radio-opaque elements in the lower plate were projected on the images.

The reference frame (Fig. 1B) was a rigid body equipped with passive markers and firmly attached to the vertebra (the one to be operated on) to both follow and compensate for any motions caused by respiration or displacement, thereby providing the real-time position of the vertebra in the “surgical space.” Subsequently, a radiographic view for calibrating the C-arm was acquired. Afterwards, 2 single radiographic views from the anterior-posterior (A-P) and lateral positions within the area to be operated on were acquired (Fig. 2). The data were automatically transferred to the computer (Fig. 1A). After the computer calibrated the acquired radiographs, the fluoroscope was turned off and removed from the operating field. The calibrated views were then displayed on the computer screen, including the AP and lateral views. A computer-generated projection of the surgical tools was also displayed with each view. This was equivalent to the representation under conventional constant fluoroscopic control. On this screen, real-time navigation in several views was possible.

### Evaluation method

Postoperative CT was performed 1 month after surgery in all patients to evaluate the implant position and the coronal and sagittal reformatting of the lumbar spine. A 256 channel-Philips Brilliance i-CT scanner was used to obtain 3.0 mm-thick sections with a field of view adequate for visualization of the spine. The screw position was assessed by independent observers (one neurosurgeon and one radiologist). The evaluation of screw placement was performed according to the criteria devised by Learch et al.<sup>10</sup> The screw position was classified as “cortical encroachment” (or questionable violation) if the pedicle cortex could not be visualized or as “frank misplacement” when the screw was outside the pedicle boundary. Frank misplacement was further classified according to the distance that the edge of the screw thread extended outside the pedicle cortex; the screws were classified as minimally misplaced ( $\leq 2.0$  mm), moderately misplaced (2.1–4 mm or  $< 1$  screw thread diameter), or severely misplaced ( $> 4$  mm or  $> 1$  screw diameter). Bilateral pedicle screws were usually placed in the S1 vertebra and were therefore not included in our misplacement analysis.

### RESULTS

The mean age of the patients was 62.5 years (Table 1). Indications for surgery were isthmic spondylolisthesis (n=39), stenosis (n=31), fracture (n=10), infection (n=6), foraminal stenosis (n=6), and “other” (n=4). The level most frequently fused was L4–5 (67 patients). A single-level fusion was performed in 53 patients (55.2%); 2-level fusion, in 35; 3-level fusion, in 5; 4-level fusion, in 2; and 5-level fusion, in 1.

Of the 477 pedicle screws inserted in 96 patients, 16 (3.3%) showed frank misplacement. Of these, 3 screws were classified as moderately misplaced (2.1–4 mm); 5, as severely misplaced

( $> 4$  mm); and 8, as minimally misplaced ( $\leq 2$  mm) (Table 2). The remaining 461 screws (96.7%) were judged to be inserted correctly. We did not observe any frank misplacement in the cranium, penetration in the disc, or over-penetration along the anterior position in the reformatted images. None of the 16 patients with screw misplacement required revision surgery since they were asymptomatic and showed no radiographic signs of postoperative instability. Other complications, such as nerve root injury, cerebrospinal fluid leakage, and internal organ injury, were not observed in the patient population.

### DISCUSSION

In conjunction with the increasing use of pedicle screws for internal stabilization of the lumbar spine, numerous reports on the accuracy of this procedure have been published. Clinical studies of conventional pedicle screw placement have reported a malposition rate of up to 42% in the thoracic and lumbar spine<sup>12</sup>. A meta-analysis of the literature published between 1966 and 2006 (130 studies involving a total of 37337 pedicle screw insertions) determined a mean misplacement rate of 8.7%<sup>7</sup>. Further, one study of 4790 implanted screws reported a misplacement rate of 5.1%<sup>11</sup>. However, the most common method of investigation in these reviews employed plain radiographs, which can reveal only the presence or absence of a pedicle screw violation. Therefore, a more accurate method of investigation would reveal the true (higher) rate of pedicle screw violation.

Many studies have demonstrated that CT is more accurate than conventional radiography in determining the location of pedicle screws. CT scans have revealed ~10-fold more pedicle violations than radiographs<sup>3</sup>. The discrepancy between radiographs and CT scans is most striking for medially misplaced screws, with CT depicting 8–10 times as many frank or questionable misplacements of the pedicle cortex as compared to conventional radiographs<sup>1</sup>. In one study, 49 out of 123 pedicle screws (39.8%) had perforated the pedicle wall<sup>1</sup>, while another study found that 48 out of 167 screws (28.7%) had penetrated the pedicular cortex<sup>3</sup>. Using a postoperative CT assessment, Ju et al.<sup>5</sup> reported that 58 of 144 pedicle screws (40.3%) were improperly placed, while Laine et al.<sup>9</sup> observed that 32 out of 152 screws (21.1%) had perforated the pedicle cortex. High rates of pedicle screw malpositioning (21.1–40.3%) have also been reported in clinical studies that use conventional insertion techniques and adequate postoperative CT assessment.

Image-guidance techniques were first implemented in 1995 for use in spinal surgery procedures, and were designed to increase the accuracy of spinal instrumentation placement<sup>6</sup>. In the past 2 decades, image-guided technology has greatly broadened the scope of modern spinal surgery and been used in clinical practice. Among the available image-guidance techniques, the currently used ones include CT-based navigation and intraoperative 2-D or 3-D fluoroscopy-based navigation. Compared to 2-D fluoroscopy-based navigation, both CT-based naviga-

**Table 1.** Demographic data

Age (year)	Men	Women	Total
21–30	0	2	2
31–40	1	2	3
41–50	3	6	9
51–60	11	16	27
61–70	11	30	41
71–80	7	7	14
Total	33	63	96

**Table 2.** Screw placement evaluated using CT

Screw placement	No. of screws (%)
Correct	412 (86.4)
Encroachment (or questionable)	49 (10.3)
Minimal ( $\leq 2$ mm)	8 (1.7)
Moderate (2.1–4 mm)	3 (0.6)
Severe ( $> 4$ mm)	5 (1.0)
Total	477 (100)

tion and 3-D fluoroscopy-based navigation can provide the surgeon with 3-D visualization of the spinal anatomy. However, CT-based navigation requires a preoperative CT scan performed using a specific protocol, and image discrepancies can result because of differences in the relative position of structures obtained at the time of the scan and their position at the time of surgery<sup>4)</sup>. Moreover, CT-based navigation requires a greater amount of time to register because of an intraoperative registration process<sup>4)</sup>. Meanwhile, 3-D fluoroscopy-based navigation systems have been adopted most recently in clinical practice and offer a number of advantages. The risk of navigation inaccuracy due to intervertebral alignment differences between the preoperative CT data set and the intraoperative position is eliminated, and the need for a preoperative CT scan with a specific image-guided protocol is not required. The anatomical registration process is also not required because the navigation can commence immediately after the images have been transferred to the workstation. However, the major disadvantage of this technology is the cost of the specialized fluoroscopic unit. It requires radiation shielding, a larger operating room spacious enough to accommodate specialized intraoperative imaging equipment, and additional staff trained in the operation of the machine<sup>14)</sup>. The 2-D fluoroscopy-based navigation system is unable to generate reconstructed axial images, in contrast to CT-based or 3-D fluoroscopy-based navigation, but displays the real-time, multiplanar position of the instrument in reference to previously acquired fluoroscopic images. Since the saved fluoroscopic images are obtained while the surgical team stands away from the operative field, the occupational radiation exposure is significantly reduced<sup>4)</sup>. Moreover, the navigation system does not need an expensive specialized fluoroscopic unit, a larger operative room, or a preoperative CT scan performed using a specific protocol.

In general, all of these navigation systems have >85% accuracy for pedicle screw insertion<sup>16)</sup>. Nonetheless, a recent meta-analysis showed that CT-based or 3-D fluoroscopy-based navigation provided more accurate pedicle screw insertion than 2-D fluoroscopy-based navigation<sup>15)</sup>. However, our results showed that 2-D fluoroscopy-based navigation systems had a high accuracy (96.7%), indicating that 2-D fluoroscopy-based navigation systems can compete with other navigation systems and are, without doubt, superior to conventional techniques. We consider the high accuracy rate observed in the present study to be the result of all the procedures being performed by a senior spine neurosurgeon and well-trained navigation team, including a skillful C-arm technician who was able to obtain an optimal image for screw insertion. Considering the shortcomings of CT-based navigation systems (high preoperational preparation and high radiation doses) and the disadvantages of 3-D fluoroscopy-based navigation systems (expensive unit costs, the necessity of radiation shielding, and larger operating rooms), we believe that the technique presented here is a reasonable option for use in spinal surgery requiring pedicle screw insertion.

Although an improved precision was observed for screw in-

sertion in the present study, 3.3% of the screws were not correctly placed. Several possibilities could explain these results. First, a difference in the angulation between the virtual and intraoperative images appears to have been present. Oertel et al.<sup>13)</sup> found a difference of  $2.8 \pm 1.9^\circ$  between the virtual and intraoperative pedicle screws, probably because of improper fixation of the tools to the implants. Another possibility is the inadequate fixation of the frame to the spinous process, which can result in minimal frame dislocation<sup>18)</sup>. In obese or osteopenic patients or those with significant spinal deformity, the interpretation of some of the images may be difficult and adversely affect the navigation<sup>4)</sup>. For obtaining higher accuracy for screw insertion, knowledge about the above-mentioned factors is important, and efforts will be needed to correct for these types of errors.

## CONCLUSION

New methods of pedicle screw placement that use computer systems and allow real-time image processing have been explored since the early 1990s with the aim of improving accuracy. The present results indicate that 2-D fluoroscopy-based navigation systems provide are more accurate, safer, and useful than conventional instrumented surgical techniques.

## References

1. Castro WH, Halm H, Jerosch J, Malms J, Steinbeck J, Blasius S : Accuracy of pedicle screw placement in lumbar vertebrae. *Spine (Phila Pa 1976)* 21 : 1320-1324, 1996
2. Farber GL, Place HM, Mazur RA, Jones DE, Damiano TR : Accuracy of pedicle screw placement in lumbar fusions by plain radiographs and computed tomography. *Spine (Phila Pa 1976)* 20 : 1494-1499, 1995
3. Gertzbein SD, Robbins SE : Accuracy of pedicular screw placement in vivo. *Spine (Phila Pa 1976)* 15 : 11-14, 1990
4. Holly LT : Image-guided spinal surgery. *Int J Med Robot* 2 : 7-15, 2006
5. Ju SM, Kim YS, Kim SB, Ko Y, Oh SH : Radiologic evaluation of proper pedicle screw placement after pedicle screw fixation in degenerative lumbar disc disease. *J Korean Neurosurg Soc* 38 : 265-268, 2005
6. Kalfas IH, Kormos DW, Murphy MA, McKenzie RL, Barnett GH, Bell GR, et al. : Application of frameless stereotaxy to pedicle screw fixation of the spine. *J Neurosurg* 83 : 641-647, 1995
7. Kosmopoulos V, Schizas C : Pedicle screw placement accuracy : a meta-analysis. *Spine (Phila Pa 1976)* 32 : E111-E120, 2007
8. Laine T, Lund T, Ylikoski M, Lohikoski J, Schlenzka D : Accuracy of pedicle screw insertion with and without computer assistance : a randomised controlled clinical study in 100 consecutive patients. *Eur Spine J* 9 : 235-240, 2000
9. Laine T, Mäkitalo K, Schlenzka D, Tallroth K, Poussa M, Alho A : Accuracy of pedicle screw insertion : a prospective CT study in 30 low back patients. *Eur Spine J* 6 : 402-405, 1997
10. Learch TJ, Massie JB, Pathria MN, Ahlgren BA, Garfin SR : Assessment of pedicle screw placement utilizing conventional radiography and computed tomography : a proposed systematic approach to improve accuracy of interpretation. *Spine (Phila Pa 1976)* 29 : 767-773, 2004
11. Lonstein JE, Denis F, Perra JH, Pinto MR, Smith MD, Winter RB : Complications associated with pedicle screws. *J Bone Joint Surg Am* 81 : 1519-1528, 1999
12. Merloz P, Tonetti J, Pittet L, Coulomb M, Lavallée S, Sautot P : Pedicle screw placement using image guided techniques. *Clin Orthop Relat*



- Res (354) : 39-48, 1998
13. Oertel MF, Hobart J, Stein M, Schreiber V, Scharbrodt W : Clinical and methodological precision of spinal navigation assisted by 3D intraoperative O-arm radiographic imaging. *J Neurosurg Spine* 14 : 532-536, 2011
  14. Shin MH, Ryu KS, Park CK : Accuracy and safety in pedicle screw placement in the thoracic and lumbar spines : comparison study between conventional C-arm fluoroscopy and navigation coupled with O-arm<sup>®</sup> guided methods. *J Korean Neurosurg Soc* 52 : 204-209, 2012
  15. Tian NF, Huang QS, Zhou P, Zhou Y, Wu RK, Lou Y, et al. : Pedicle screw insertion accuracy with different assisted methods : a systematic review and meta-analysis of comparative studies. *Eur Spine J* 20 : 846-859, 2011
  16. Tian NF, Xu HZ : Image-guided pedicle screw insertion accuracy : a meta-analysis. *Int Orthop* 33 : 895-903, 2009
  17. Vaccaro AR, Rizzolo SJ, Balderston RA, Allardyce TJ, Garfin SR, Dolinskas C, et al. : Placement of pedicle screws in the thoracic spine. Part II : An anatomical and radiographic assessment. *J Bone Joint Surg Am* 77 : 1200-1206, 1995
  18. Van de Kelft E, Costa F, Van der Planken D, Schils F : A prospective multicenter registry on the accuracy of pedicle screw placement in the thoracic, lumbar, and sacral levels with the use of the O-arm imaging system and StealthStation Navigation. *Spine (Phila Pa 1976)* 37 : E1580-E1587, 2012
  19. Weinstein JN, Spratt KF, Spengler D, Brick C, Reid S : Spinal pedicle fixation : reliability and validity of roentgenogram-based assessment and surgical factors on successful screw placement. *Spine (Phila Pa 1976)* 13 : 1012-1018, 1988