

CASE REPORT

Nagoya J. Med. Sci. 79. 259 ~ 266, 2017
doi:10.18999/nagjms.79.2.259

A case of metachronous left ovarian metastasis 8 years after surgery for cecal cancer and right ovarian metastasis: Report of a case

Itaru Shigeyoshi¹, Koji Komori¹, Takashi Kinoshita¹, Taihei Oshiro¹, Seiji Ito¹, Tetsuya Abe¹, Yoshiki Senda¹, Kazunari Misawa¹, Yuichi Ito¹, Norihisa Uemura¹, Seiji Natsume¹, Jiro Kawakami¹, Akira Ouchi¹, Masayuki Tsutsuyama¹, Takahiro Hosoi¹, Tomoyuki Akazawa¹, Daisuke Hayashi¹, Hideharu Tanaka¹, Yasushi Yatabe² and Yasuhiro Shimizu¹

¹Department of Gastroenterological Surgery, Aichi Cancer Center Hospital, Aichi, Japan

²Department of Pathology and Molecular Diagnostics, Aichi Cancer Center Hospital, Aichi, Japan

ABSTRACT

Metachronous ovarian metastasis of colorectal adenocarcinoma is mostly identified within 3 years. Here we present a case of a 64-year-old woman with cecal cancer who underwent right oophorectomy for ovarian metastasis. Imaging was performed because of abdominal bloating; it detected a swollen right ovary with ascites. On laparotomy, a right ovarian tumor and cecal cancer were identified. After right oophorectomy, a diagnosis of unilateral ovarian metastasis from colon cancer was made. One month later, right hemicolectomy was performed. Eight years after initial surgery, the patient presented with vaginal bleeding. A computed tomography (CT) scan revealed a pelvic mass approximately 10 cm in diameter, but no mass was evident on a CT image taken 6 months before. The patient was diagnosed with left ovarian metastasis from colon cancer. A third laparotomy revealed a left ovarian tumor, but there was no evidence of other metastases or peritoneal dissemination. Left oophorectomy was performed. Oophorectomy is considered to be associated with a survival benefit in ovarian metastasis without other extensive metastasis. However, ovarian metastasis is often bilateral. Although complete resection was achieved in the present case, the findings support performing prophylactic bilateral oophorectomy if metastasis is identified in a unilateral ovary.

Key Words: metachronous ovarian metastasis, colon cancer, prophylactic bilateral oophorectomy

This is an Open Access article distributed under the Creative Commons Attribution-NonCommercial-NoDerivatives 4.0 International License. To view the details of this license, please visit (<http://creativecommons.org/licenses/by-nc-nd/4.0/>).

INTRODUCTION

Metastasis to the ovaries occurs in 0.8%–7.4% of colorectal cancer cases in women.¹⁾ In the presence of ovarian metastasis, the prognosis of colorectal cancer is poor. Metachronous ovarian metastasis occurs in 0.1%–4% of cases²⁻⁷⁾ and is mostly identified within 3 years.⁶⁾ We experienced a rare case of a patient with cecal cancer and synchronous ovarian metastasis who

Received: December 26, 2016; accepted: March 6, 2017

Corresponding author : Itaru Shigeyoshi, MD

Department of Gastroenterological Surgery, Aichi Cancer Center Hospital, Nagoya city, Chikusa-ku, Kanokoden 1-1 Aichi 464-8681, Japan

Email : ishigeyoshi@aichi-cc.jp

developed metachronous preserved ovarian metastasis identified 8 years after initial surgery. In this case, complete resection was achieved two times.

CASE PRESENTATION

A 64-year-old Japanese woman presented to the Department of Gynecology of Aichi Cancer Center Hospital (Nagoya, Aichi Prefecture, Japan) with a 2-month history of abdominal bloating. An imaging study detected swelling of the right ovary with ascites, which led to suspicion of a primary ovarian neoplasm and cancerous peritonitis (Fig. 1A). No malignant cells were detected in the ascites. An exploratory laparotomy was performed, which detected a right ovarian tumor and cecum tumor. Barium enema X-ray inspection performed before surgery failed to detect the tumor. There was no evidence of peritoneal dissemination, thus, a right oophorectomy was performed. The right ovary measured 10 × 7.3 × 6.5 cm and was histologically diagnosed as an adenocarcinoma (Fig. 1B, C). After surgery, a total colonoscopy in association with biopsy confirmed a diagnosis of cecum colon cancer. As a result, a diagnosis of unilateral ovarian metastasis from colon cancer was made.

One month later, right hemicolectomy with regional lymph node dissection (D2) was performed. The pathological diagnosis was of a well-differentiated adenocarcinoma (T3/SS, tub1, ly1, v1, infβ, N0 (0/29)). The macroscopic and histological findings are shown in Fig. 2A, B. The patient received S-1 chemotherapy for 4 years. No recurrence was detected during the follow-up period.

After 8 years, the patient presented with vaginal bleeding and abdominal bloating. A computed tomography (CT) scan revealed a pelvic mass approximately 10 cm in diameter, but no mass was evident on a CT image taken 6 months before (Fig. 3A, B). Blood tests showed progressive anemia (hemoglobin, 9.6 g/dl) and a high level of the tumor marker carcinoembryonic antigen (26.0 ng/ml). The patient was diagnosed with left ovarian metastasis from colon cancer. A third laparotomy revealed a left ovarian tumor but no evidence of other metastasis or peritoneal dissemination. Left oophorectomy was performed. The left ovary measured 12 × 11 × 3 cm and was pathologically diagnosed as an adenocarcinoma consistent with metastasis of colon cancer (Fig. 4 A, B). Immunohistochemistry confirmed cytokeratin 7 (CK-7) negativity, cytokeratin 20 (CK-20) positivity, caudal-type homeobox transcription factor 2 (CDX2) positivity, and paired box protein-8 (PAX8) negativity ; findings consistent with a metachronous colon cancer metastasis to the ovary (Fig. 5A, B, C, D, E).

S-1 chemotherapy was started again 1 month after surgery. Nine years after initial surgery, peritoneal metastasis was found, which was treated with modified infusional intravenous fluorouracil and levofolinate with oxaliplatin. At the time of writing, tumor progression is being controlled.

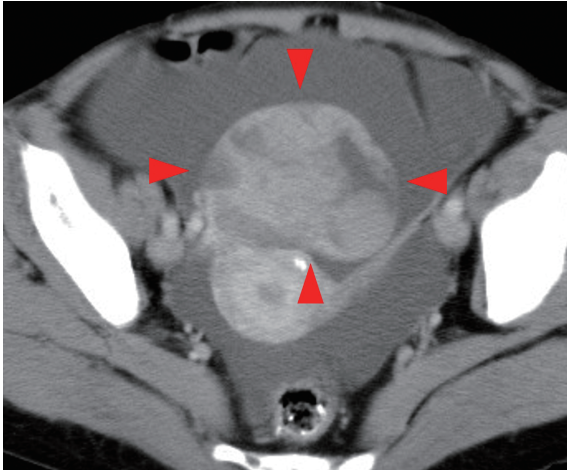


Fig. 1A

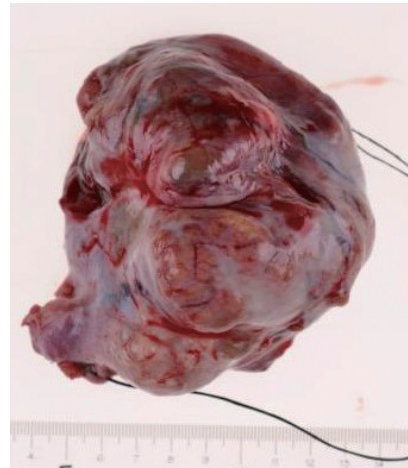


Fig. 1B

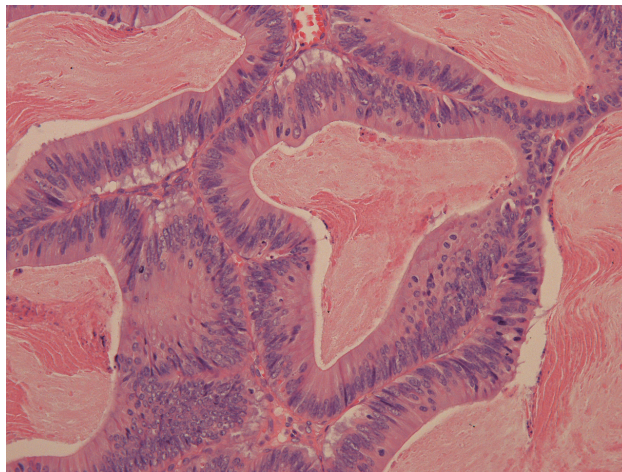


Fig. 1C

- Fig. 1** Preoperative image, the resected specimen, and histological findings of the first laparotomy
- Fig. 1A:** Computed tomography demonstrated a swollen right ovary (arrow) with ascites.
- Fig. 1B:** The resected right ovary measured 10 × 7.3 × 6.5 cm.
- Fig. 1C:** Histologically, the right ovary contained a solid lesion and a cystic lesion. In the solid lesion, adenocarcinoma composed of tall columnar cells was revealed. The tumor was suspected to have metastasized from colorectal cancer.

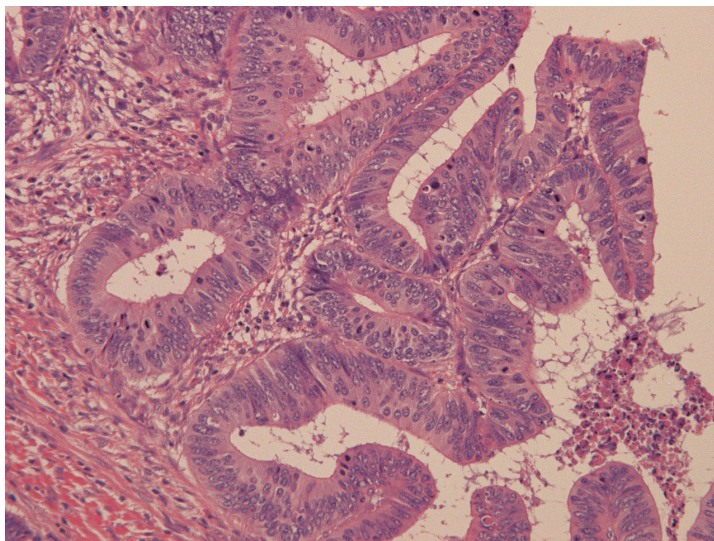
**Fig. 2A****Fig. 2B**

Fig. 2 The resected specimen and histological findings of the second laparotomy.

Fig. 2A: Macroscopic view of the cecal cancer (arrow)

Fig. 2B: The pathological diagnosis was well-differentiated adenocarcinoma.

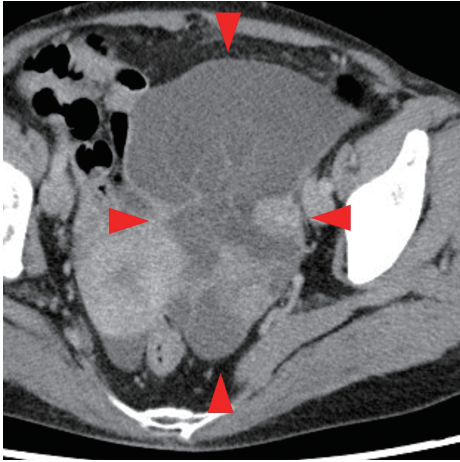


Fig. 3A

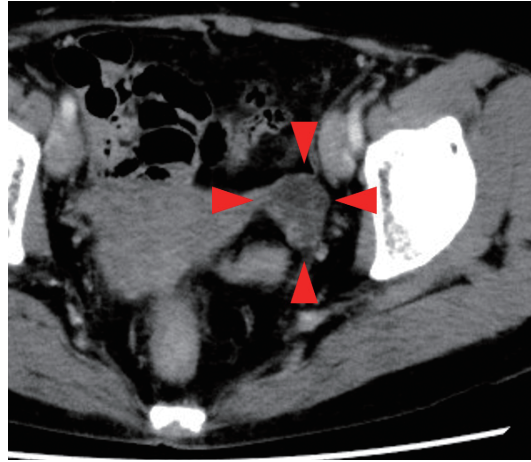


Fig. 3B

Fig. 3 reoperative images of the third laparotomy.

Fig. 3A: A CT scan taken 6 months before surgery showed that the size of the left ovary was normal.

Fig. 3B: The left ovary was recognized as a 10-cm pelvic mass on a CT scan taken just before surgery.

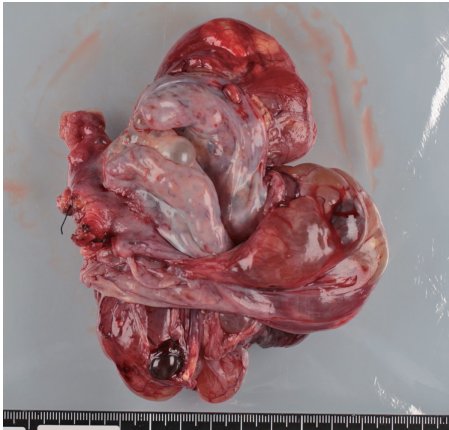


Fig. 4A

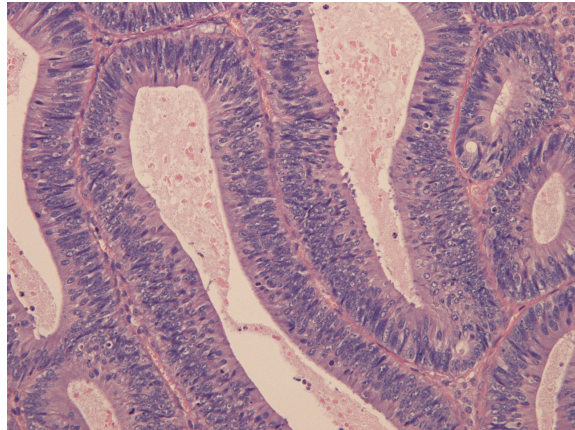


Fig. 4B

Fig. 4 The resected specimen and histological findings of the third laparotomy

Fig. 4A: The resected left ovary measured 12 × 11 × 3 cm.

Fig. 4B: The histological diagnosis was adenocarcinoma consistent with metastasis of colon cancer.

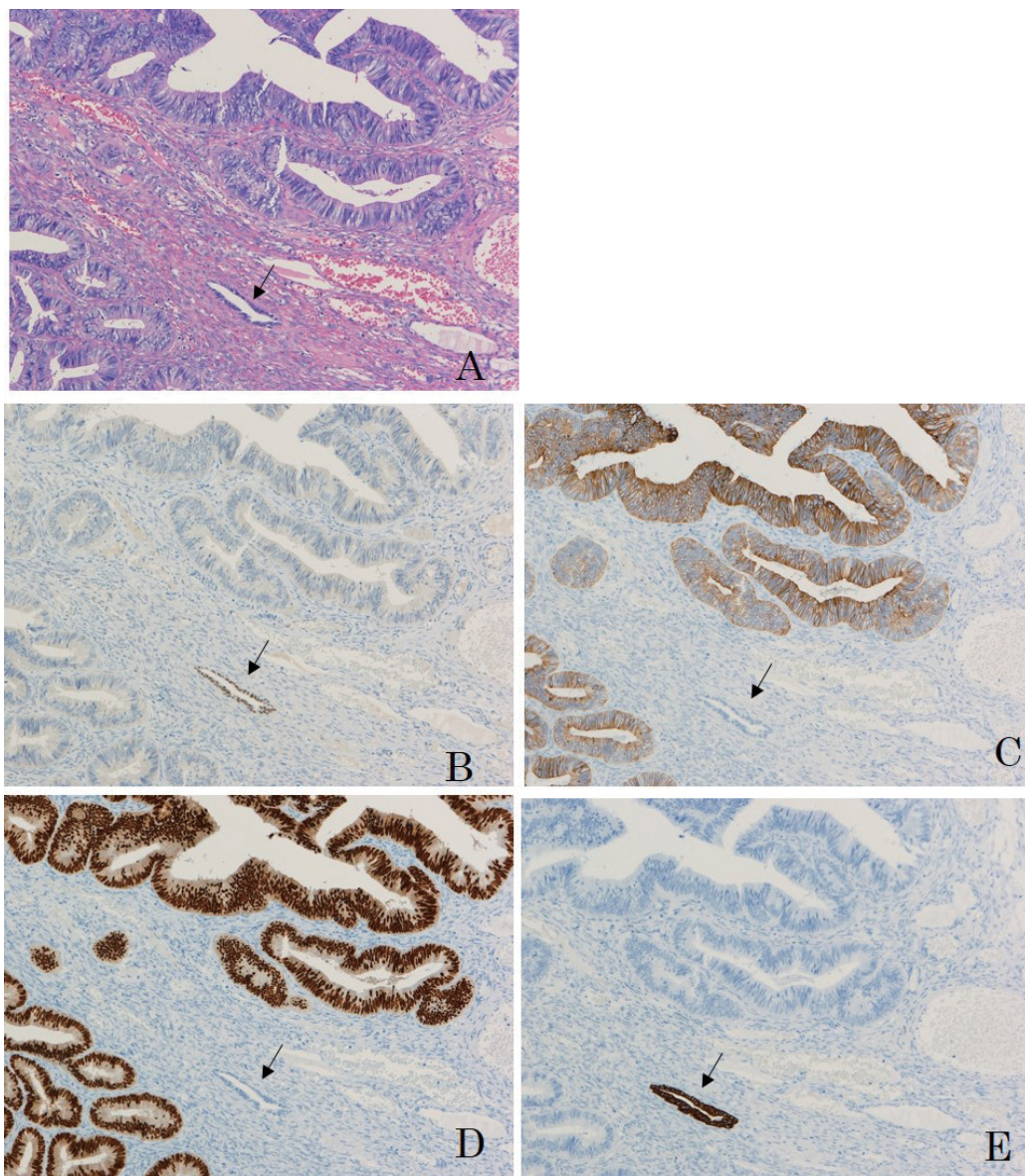


Fig. 5 Immunohistochemistry of the left ovary

Fig. 5A: Hematoxylin and eosin staining

Fig. 5B: Immunohistochemical stains for CK-7 ; the tumor cells are negative.

Fig. 5C: Immunohistochemical stains for CK-20 ; the tumor cells are positive.

Fig. 5D: Immunohistochemical stains for CDX2 ; the tumor cells are positive.

Fig. 5E: Immunohistochemical stains for PAX8 ; the tumor cells are negative.

These stain pattern were consistent with that in colon cancer.

In ovarian epithelium (arrow in each figure), stain pattern was different from that in tumor cells.

DISCUSSION

The incidence of ovarian metastases from colorectal cancer is estimated at 3%–14%.⁶⁾ Ovarian metastases occur in about 0.8%–7.4% of all colorectal cancer cases in women.¹⁾ In Japan, synchronous metastases from colorectal cancer to other organs also occurs—liver (10.9% patients), peritoneum (4.5%), lung (2.4%), and other organs (1.9%).⁸⁾ Among the 5230 cases that underwent curative resection of colon cancer, metastases occurred in 906 (17.3%). Metastases to the liver occurred in 7.1% of cases, to the lung in 4.8%, recurred locally in 4.0%, to the anastomosis site in 0.4%, and to other organs in 3.8%.⁸⁾ These data suggest that ovarian metastases are not rare.

Metachronous metastases from colorectal cancer at or after 5 years from the initial surgery reportedly occur in 0.63% of cases.⁸⁾ Kim *et al.* reported that 82.8% of metachronous ovarian metastases occurred within 3 years.⁶⁾ In the present case, metachronous ovarian metastasis was identified 8 years after the initial surgery, which is relatively rare.

The metastatic pathways of ovarian tumors have not yet been established. The present case showed no evidence of peritoneal dissemination at laparotomy, no lymphatic metastasis on pathological findings, and no recurrence for 8 years. Therefore, the main route of ovarian metastasis in this case may have been hematogenous spread.

In the presence of ovarian metastasis, metastasis of colorectal cancer is usually extensive and is considered to have a poor prognosis. Morrow *et al.* reported that in their study, about half of the cases of metachronous ovarian metastasis occurred with peritoneal metastasis, with a 5-year survival rate of 0%.⁹⁾ Suzuki *et al.* also reported a mean survival time of ovarian metastases of 21.3 months.¹⁰⁾

Erroi *et al.* reported that the overall survival at 3 years of 10 patients after radical oophorectomy for isolated ovarian metastases was 80%.¹¹⁾ Tomiki *et al.* reported 5-year survival rates of 29.1% for 26 cases of ovarian metastases from colorectal cancer and 67.5% in 10 cases of isolated ovarian metastases.¹²⁾ Our patient is alive 10 years after the initial surgery.

These data demonstrate that oophorectomy can prolong survival in cases of isolated ovarian metastases from colorectal cancer. In many recent reports, bilateral oophorectomy at the time of surgery for colorectal cancer without macroscopic ovarian metastases was found to be unwarranted.^{2,13)} However, 43–70% of ovarian metastases occur to the bilateral ovaries,⁶⁾ and some studies have reported metastasis to the preserved ovary after unilateral oophorectomy, as with the present case.¹³⁾

Complete resection for metastasis to the preserved ovary was achieved in the present case. Yamaguchi *et al.* reported two cases with severe clinical symptoms and metastasis to the preserved ovary, but the general condition of these patients contraindicated additional laparotomy.¹³⁾ Therefore, in cases of ovarian metastases from colorectal cancer without other extensive metastases, bilateral oophorectomy should be performed. If the premenopausal patient requires preservation of hormonal and reproductive functions by performing unilateral oophorectomy, a strict follow-up is necessary to detect any metachronous recurrence in the preserved ovary. The findings in this case suggest that if there is no recurrence for 5 years after unilateral oophorectomy, follow-up should be continued.

CONCLUSIONS

We experienced a case of metachronous left ovarian metastasis 8 years after surgery for cecal cancer and right ovarian metastasis. In cases of isolated ovarian metastasis from colorectal cancer, oophorectomy is associated with a survival benefit. If metastasis from colon cancer is identified

in a unilateral ovary, prophylactic bilateral oophorectomy should be performed. When unilateral oophorectomy is performed, a strict and long-term follow-up is mandatory.

CONFLICTS OF INTEREST

All authors certify that they have no personal financial or institutional interest in the subject matter, materials, or drugs in this article.

REFERENCES

- 1) Hanna NN, Cohen AM. Ovarian neoplasms in patients with colorectal cancer: understanding the role of prophylactic oophorectomy. *Clin Colorectal Cancer*, 2004; 3: 215–222.
- 2) Young-Fadok TM, Wolff BG, Nivatvongs S, Metzger PP, Ilstrup DM. Prophylactic oophorectomy in colorectal carcinoma: preliminary results of a randomized, prospective trial. *Dis Colon Rectum*, 1998; 41: 277–283; discussion 283–275.
- 3) Yang TS, Hsu KC, Tang R, Chang TC. Colon carcinoma with synchronous ovarian metastasis—report and discussion of five cases. *Anticancer Drugs*, 2000; 11: 279–283.
- 4) Sielezneff I, Salle E, Antoine K, Thirion X, Brunet C, Sastre B. Simultaneous bilateral oophorectomy does not improve prognosis of postmenopausal women undergoing colorectal resection for cancer. *Dis Colon Rectum*, 1997; 40: 1299–1302.
- 5) Koves I, Vamosi-Nagy I, Besznyak I. Ovarian metastases of colorectal tumours. *Eur J Surg Oncol*, 1993; 19: 633–635.
- 6) Kim DD, Park IJ, Kim HC, Yu CS, Kim JC. Ovarian metastases from colorectal cancer: a clinicopathological analysis of 103 patients. *Colorectal Dis*, 2009; 11: 32–38.
- 7) Graffner HO, Alm PO, Oscarson JE. Prophylactic oophorectomy in colorectal carcinoma. *Am J Surg*, 1983; 146: 233–235.
- 8) Watanabe T, Itabashi M, Shimada Y, Tanaka S, Ito Y, Ajioka Y, *et al.* Japanese Society for Cancer of the Colon and Rectum (JSCCR) Guidelines 2014 for treatment of colorectal cancer. *Int J Clin Oncol*, 2015; 20: 207–239.
- 9) Morrow M, Enker WE. Late ovarian metastases in carcinoma of the colon and rectum. *Arch Surg*, 1984; 119: 1385–1388.
- 10) Suzuki O, Sekishita Y, Shiono T, Fujimori M, Katoh H. Two Cases of Ovarian Metastasis after Curative Resection of Colon Cancer. *The Japanese Journal of Gastroenterological Surgery*, 2002; 35: 1629–1633.
- 11) Erroi F, Scarpa M, Angriman I, Cecchetto A, Pasetto L, Mollica E, *et al.* Ovarian metastasis from colorectal cancer: prognostic value of radical oophorectomy. *J Surg Oncol*, 2007; 96: 113–117.
- 12) Tomiki Y, Kamano T, Kunii Y, Okada T, Kasamaki S, Negami N, *et al.* Risk Factors of Ovarian Metastasis from Colorectal Cancer by Using Multivariate Analysis. *The Japanese Journal of Gastroenterological Surgery*, 2002; 35: 11–17.
- 13) Yamaguchi T, Takahashi H, Kagawa R, Takeda R, Sakata S, Yamamoto M, *et al.* The role of prophylactic bilateral oophorectomy at the time of initial diagnosis of a unilateral ovarian metastasis in cases with colorectal adenocarcinoma. *Hepatogastroenterology*, 2008; 55: 434–437.