



A Rare Cause of Upper Gastrointestinal Bleeding: *Sarcina ventriculi*

Emily B. Worrall, MD¹, Anuj Chhaparia, MD², Danielle Carpenter, MD³, and Brent A. Neuschwander-Tetri, MD²

¹Department of Internal Medicine, Saint Louis University School of Medicine, Saint Louis, MO

²Division of Gastroenterology and Hepatology, Saint Louis University School of Medicine, Saint Louis, MO

³Department of Pathology, Saint Louis University School of Medicine, Saint Louis, MO

ABSTRACT

We describe a patient who presented with hematemesis and was found to have unusually well-demarcated erythematous mucosa with a 2–3 cm irregular nonbleeding necrotic ulcer in the gastric body on esophagogastroduodenoscopy. Biopsy and pathologic examination of the tissue indicated infection with a rare bacterium, *Sarcina ventriculi*, prompting treatment with an unproven combination of 4 agents: metronidazole, ciprofloxacin, sucralfate, and pantoprazole. Repeat esophagogastroduodenoscopy 8 weeks later revealed complete resolution of the ulceration and surrounding erythema. These results may contribute toward establishing an appropriate therapeutic regimen for future *S. ventriculi* infections.

INTRODUCTION

Sarcina ventriculi is a rare gram-positive anaerobic coccus that thrives in acidic environments and uses carbohydrate fermentation as its sole source of energy, with ethanol, acetate, and hydrogen as important end products.^{1,2} The organism's ability to survive and thrive in a broad range of environments with varying pH circumvents the natural defense mechanisms of the stomach's acidic conditions and instead may make it an ideal environment for growth.² John Goodsir first observed *S. ventriculi* in gastric contents in 1842 after a patient presented with months of abdominal distension, nausea, and associated frothy emesis.³ Additional investigation revealed that the bacterium is commonly identified in patients with delayed gastric emptying or gastric outlet obstruction.^{4,5} *Sarcina ventriculi* has been implicated as a cause of gastric ulcer, emphysematous gastritis, and gastric perforation as well as gastric adenocarcinoma and pancreatic adenocarcinoma.^{5,6}

CASE REPORT

A 68-year-old woman with gastroesophageal acid reflux, type 2 diabetes, hypertension, and end-stage renal disease on hemodialysis presented with hematemesis for 1 day. Before admission, the patient was not on a proton pump inhibitor and did not have factors that predisposed her to developing gastric ulcers. She was hemodynamically resuscitated and given an intravenous proton pump inhibitor. Esophagogastroduodenoscopy (EGD) demonstrated a large area of erythematous mucosa with unusually well-defined margins involving a significant proportion of the gastric fundus and proximal body. Within this area was a 2–3 cm irregular nonbleeding necrotic ulcer suggestive of malignancy (Figure 1). Multiple biopsies were obtained from the ulcer edge and erythematous mucosa. Pathology was significant for erosive gastropathy with superficial erosion and reactive changes as well as ulcer pathology with mucosal necrosis and erosion. Interestingly, there were scattered intraluminal microorganism's characteristic of *S. ventriculi* on hematoxylin and eosin stain (Figure 1). There was no background of chronic gastritis as typically seen in *Helicobacter pylori* infection, but given the active inflammation, immunostaining for *H. pylori* was found to be negative. Based on the few available case reports, the patient was treated with 1 week of metronidazole 500 mg 3 times daily, ciprofloxacin 500 mg once daily, and sucralfate 1 gm once daily as well as 8 weeks of pantoprazole 40 mg 2 times daily.^{5,7} The doses were adjusted for a patient who was on hemodialysis. During and after completion of the treatment, the patient did not report further episodes of hematemesis. Repeat EGD 8 weeks later demonstrated a normal esophagus, stomach,

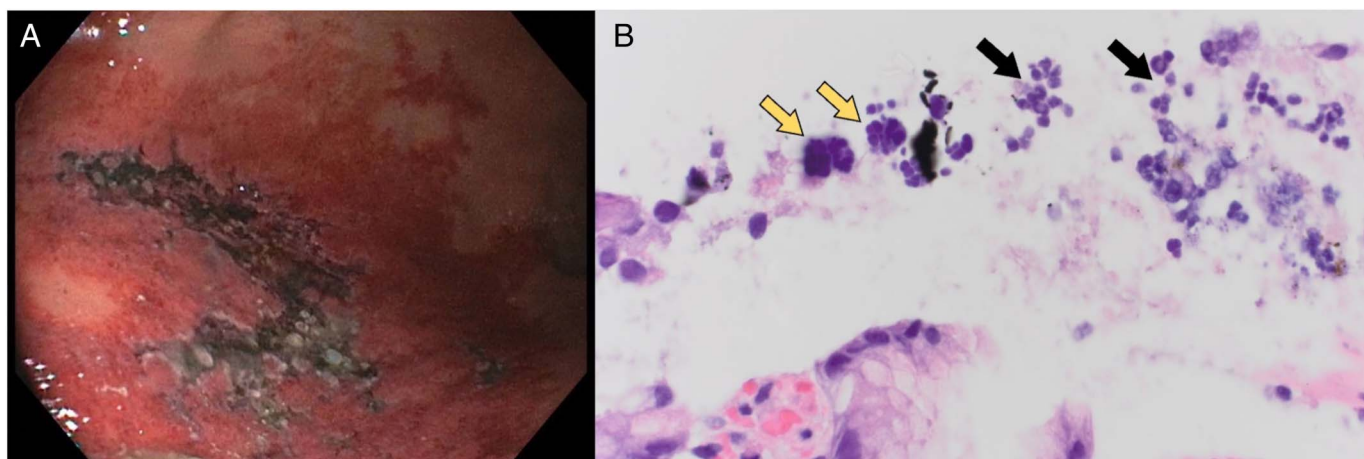


Figure 1. (A) A 2–3 cm irregular nonbleeding necrotic ulcer in the gastric body surrounded by deeply erythematous mucosa with atypically well-demarcated margins; (B) 1,000× hematoxylin and eosin (H&E) staining indicating necroinflammatory debris (black arrows) and admixed *Sarcina* organisms (yellow arrows) arranged in tetrads.

and duodenal bulb. There was no endoscopic evidence of residual ulceration or erythema in the stomach; therefore, repeat biopsies were not obtained.

DISCUSSION

Sarcina ventriculi is a rare bacterium associated with delayed gastric emptying or gastric outlet obstruction. In this case, diabetes was the predisposing risk factor to the patient developing delayed gastric emptying. This case demonstrated several noteworthy points related to the initial presentation, endoscopic and histopathologic identification, and treatment of this infection. Hematemesis as the initial presenting symptom of *S. ventriculi* infection in an otherwise asymptomatic patient, as in this case, is exceedingly rare. A review of the literature revealed that individuals suffering from infection with *S. ventriculi* typically present with epigastric abdominal pain or spasms, abdominal distension, nausea, and subsequent emesis.⁵ Typically, in cases of *S. ventriculi* infection, endoscopy revealed esophageal and gastric inflammation with diffuse erythema, gastric ulcer, and retained food and bile.^{5,7} Endoscopic evaluation in this case revealed a unique well-defined margin between normal and abnormal mucosae that, to the best of our knowledge, has not been previously described but could be a feature that would raise suspicion of this infection at the time of endoscopic evaluation.

S. ventriculi demonstrates distinctive histopathologic features: cuboid organisms that occur in tetrads or packets of 8 as a result of cell division in 2 planes of growth, with basophilic staining with hematoxylin-eosin.⁴ Histopathologic identification in this case indicated basophilic staining organisms arranged in tetrads with surrounding necroinflammatory debris consistent with a diagnosis of *S. ventriculi* (Figure 1). Although this presentation is representative of typical *S. ventriculi* infection, other organisms including *Micrococcus* species, *Staphylococcus* species, and even *H. pylori* are among the differential diagnosis and are easily

eliminated as causative organisms based on their size, shape, and growth pattern.

Currently, there is no consensus regarding the best therapeutic agents or duration of treatment in cases of infection with *S. ventriculi*. Given the organisms' association with serious and life-threatening sequelae, we elected to proceed with a multidrug treatment based on the few available case reports. Therefore, the patient was treated with 1 week of metronidazole, ciprofloxacin, and sucralfate as well as 8 weeks of pantoprazole.^{5,7} The doses were adjusted for a patient who was on hemodialysis. Endoscopic evaluation 8 weeks after treatment with this regimen demonstrated complete resolution of the gastric erythema and necrotic ulcer. Clinically, the patient denied gastrointestinal symptoms including abdominal pain, distention, nausea, and further episodes of hematemesis. Based on the healthy gastric mucosa observed on repeat EGD and lack of clinical symptoms, treatment success was achieved and repeat biopsies were not obtained. These results contribute to establishing an appropriate treatment regimen for future cases in infections with *S. ventriculi*. The organism's association with gastric ulcers, emphysematous gastritis, and gastric perforation as well as gastric adenocarcinoma and pancreatic adenocarcinoma makes its identification, management, and treatment clinically important.

DISCLOSURES

Author contribution: EB Worrall reviewed the literature, wrote, and approved the manuscript and is the article guarantor. A. Chhaparia reviewed the literature and revised the manuscript. D. Carpenter provided the pathology images. BA Neuschwander-Tetri edited the manuscript.

Financial disclosure: None to report.

Previous presentation: This study was presented in a poster presentation at the American College of Gastroenterology

Annual Scientific Meeting and Postgraduate Course; October 24, 2021; Las Vegas, Nevada.

Informed consent was obtained for this case report.

Received December 22, 2021; Accepted July 14, 2022

REFERENCES

1. Lowe SE, Pankratz HS, Zeikus JG. Influence of pH extremes on sporulation and ultrastructure of *Sarcina ventriculi*. *J Bacteriol*. 1989;171(7):3775–81.
2. Goodwin S, Zeikus JG. Physiological adaptations of anaerobic bacteria to low pH: Metabolic control of proton motive force in *Sarcina ventriculi*. *J Bacteriol*. 1987;169(5):2150–7.
3. Goodsir J, Wilson G. History of a case in which a fluid periodically ejected from the Stomach contained vegetable organisms of an undescribed form. *Edinb Med Surg J*. 1842;57(151):430–43.
4. Lam-Himlin D, Tsiatis AC, Montgomery E, et al. *Sarcina* organisms in the gastrointestinal tract: A clinicopathologic and molecular study. *Am J Surg Pathol*. 2011;35(11):1700–5.
5. Al Rasheed MR, Senseng CG. *Sarcina ventriculi*: Review of the literature. *Arch Pathol Lab Med*. 2016;140(12):1441–5.
6. Singh K. Emphysematous gastritis associated with *Sarcina ventriculi*. *Case Rep Gastroenterol*. 2019;13(1):207–13.
7. Ratuapli SK, Lam-Himlin DM, Heigh RI. *Sarcina ventriculi* of the stomach: A case report. *World J Gastroenterol*. 2013;19(14):2282–5.

Copyright: © 2022 The Author(s). Published by Wolters Kluwer Health, Inc. on behalf of The American College of Gastroenterology. This is an open access article distributed under the terms of the Creative Commons Attribution-Non Commercial-No Derivatives License 4.0 (CCBY-NC-ND), where it is permissible to download and share the work provided it is properly cited. The work cannot be changed in any way or used commercially without permission from the journal.