

Endovascular treatment of descending thoracic aneurysms

R. Chiesa, E. Civilini, Y. Tshomba, E.M. Marone, L. Bertoglio, D. Baccellieri, G. Coppi, D. Logaldo, G. Melissano

Department of Vascular Surgery, Università Vita-Salute San Raffaele, Milan, Italy

HSR Proceedings in Intensive Care and Cardiovascular Anesthesia 2010; 2: 261-270

ABSTRACT

Introduction: Current strategies for repair of descending thoracic aortic aneurysms consist of open repair with surgical graft replacement or thoracic endovascular aortic repair. We review and update our overall experience in aortic thoracic diseases and specifically analyzed our outcomes with thoracic endovascular aortic repair in patients with descending thoracic aortic aneurysms.

Methods: From 1993 to present a total of 1144 patients were treated in our Center for pathology involving the thoracic aorta. Since 1998, 322 patients underwent thoracic endovascular aortic repair, and among this group, in 188 cases the descending aorta was involved. In 74% of patients treated for a descending thoracic aortic lesion, a degenerative aneurysm was observed.

Results: In patients with descending thoracic aortic aneurysms receiving thoracic endovascular aortic repair, our technical success rate, i.e. deployment of endograft with complete exclusion of the lesion/minimal endoleak, was 99.5% (one case required emergent open conversion) with a perioperative mortality of 2.6% (five patients). The rate of spinal cord ischemia, manifesting either as paraplegia or paraparesis, was 4.7%. Delayed onset spinal cord ischemia ameliorated with adequate arterial pressure and cerebrospinal fluid drainage.

Conclusions: Our experience of selected patients undergoing thoracic endovascular aortic repair of descending thoracic aorta aneurysms is satisfactory with very low mortality and morbidity. A large use of thoracic endovascular aortic repair is foreseen in the next future.

Keywords: *thoracic aortic aneurysm, endovascular aortic repair, aortic endoprotheses, thoracic aortic aneurysms, type B aortic dissection.*

INTRODUCTION

Thoracic endovascular aortic repair (TEVAR) could reduce perioperative mortality and pulmonary, cardiac and renal complications when compared to open repair. Furthermore, most of the past series

data included devices that will soon not be marketed anymore. In an ironic way, these data are losing their value exactly in the moment they have the most to say. We therefore can speculate further TEVAR outcomes improvements with the newest updated devices.

In this paper we present our experience in the management of patients with descending thoracic aortic aneurysm undergoing TEVAR, including preoperative imaging modalities, endovascular procedures techniques, follow up, results and complications.

Corresponding author:
 Prof. Roberto Chiesa, MD
 IRCCS H. San Raffaele
 Department of Vascular Surgery
 Via Olgettina, 60
 e.mail: r.chiesa@hsr.it

METHODS

Preoperative planning and sizing

Accurate planning is mandatory when a TEVAR is considered, because precise quantitative measurements are needed besides the usual qualitative diagnosis (*Figure 1*). Diameters, lengths and angles need to be measured very accurately together with the presence of thrombus, calcifications, anomalies, etc. (*Figure 2*).

A timely diagnosis and an accurate planning and sizing allow to offer an effective treatment to many patients, however, in spite of a flawlessly executed operation, several important complications may occur after thoracic aortic procedures. The most severe complication after these procedures

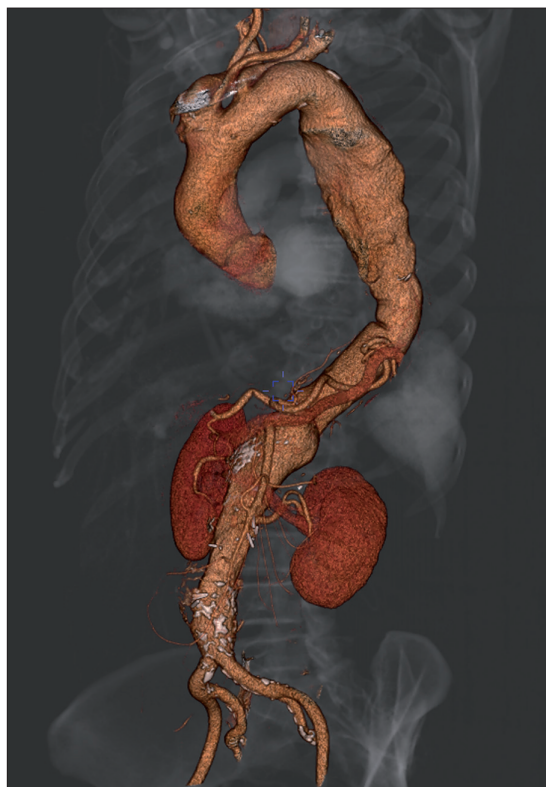

Figure 1 - Three-dimensional rendering of the entire aorta in a patient with a descending thoracic aortic aneurysm obtained with the OsiriX software.

is certainly spinal cord ischemia which can cause symptoms as dramatic as paraplegia.

Endovascular procedure

All the procedures were performed in the operating room, using a portable digital C-arm image intensifier with road-mapping capabilities (series 9600, OEC Medical System or Moonray, Simad Medical Technology).

Cerebrospinal fluid drainage has a protective role in open surgical repair of descending thoracic and thoracoabdominal aortic aneurysms, while its role in TEVAR is less defined.

Our current indications for cerebrospinal fluid drainage in TEVAR includes:

1. Long coverage (predicted use of more than one endograft).
2. Coverage of high risk area including T10-T12.
3. Previous abdominal or thoracic aortic surgery.

In our series, the overall cerebrospinal fluid drainage institution rate was 48 %.

Intraoperative trans-esophageal echocardiography monitoring is routinely used during all thoracic endovascular procedures. In our experience trans-esophageal echocardiography is useful under many aspects as it allows to double check for the most appropriate landing zone of the endograft (in particular when the left subclavian artery origin has to be spared). As a second instance trans-esophageal echocardiography is capable of documenting thrombosis or the presence of slow flow inside the aneurysm sack after deployment of the endograft, thus avoiding repeated angiography and the use of high doses of contrast media. In our specific experience in the treatment of type B dissection, trans-esophageal echocardiography has become mandatory. In particular it allows to detect whether the guide wire is correctly positioned inside the true lumen or it has moved inside a patent false lumen. As a second, and most important instance,

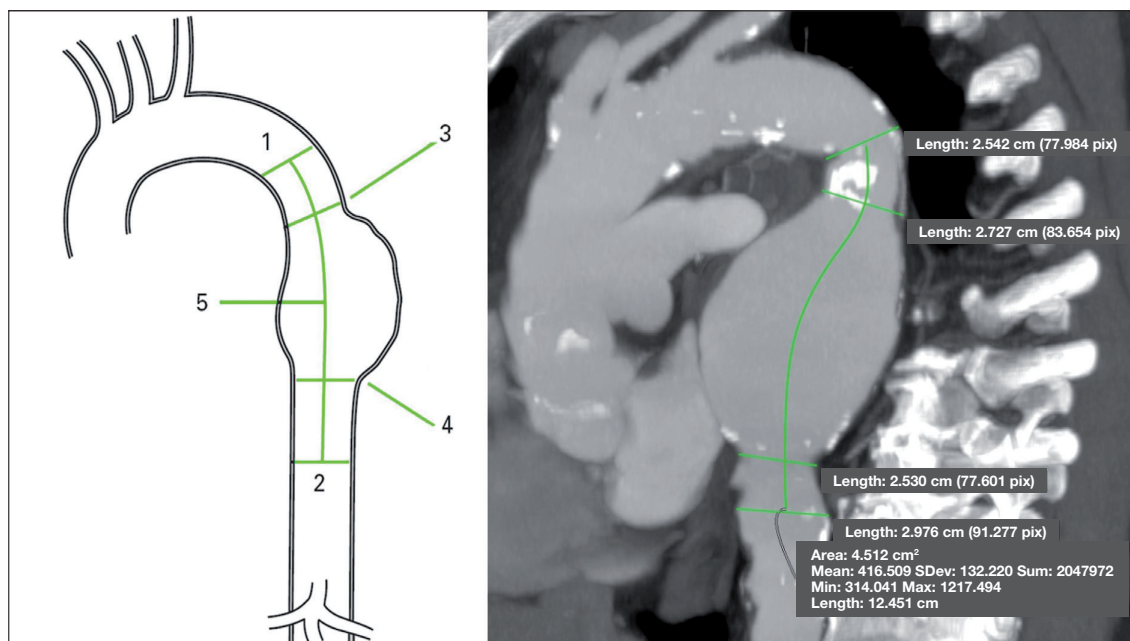


Figure 2

An example of sizing required to plan an endovascular procedure for a thoracic aortic aneurysm.

trans-esophageal echocardiography easily documents the presence and position of proximal entry tear, the presence of additional distal tears (eventually not detected by angiography) and thrombosis or reperfusion of the false lumen.

Our preferred choice is to perform the endovascular procedure under general anesthesia; in selective cases, depending of the patient general condition and comorbidity, the strategy of access site for endograft insertion and the institution of cerebrospinal fluid drainage, we also perform local or spinal anesthesia.

Patients are placed in the dorsal decubitus position, and the operative field is prepared and draped. It is mandatory that the operating field is prepared in such a way to allow a laparotomy for access and abdominal aorta and/or iliac arteries control.

In most cases the common femoral artery is exposed through an inguinal transverse incision. A bolus of heparin (70 IU/Kg)

is administered. The contra-lateral femoral artery is percutaneously punctured for diagnostic guidance. In case of extremely diseased (calcific) external iliac arteries we routinely use the common iliac through a paramedian extraperitoneal approach as the access site; we use to directly puncture the artery through a purse string. In rare cases the abdominal aorta has been used as the access site, with direct puncture and then closure with a purse string suture. A 260-cm long, 0.035-inch precurved super stiff guidewire (Lunderquist, Cook Medical Inc.) is advanced up to the aortic arch under fluoroscopic guidance.

The endograft is then passed over the guide wire into the appropriate position within the descending thoracic aorta or aortic arch under fluoroscopic guidance. During deployment, a mild systemic hypotension is induced pharmacologically by the anaesthesiologist with a bolus of fast-acting venous or arterial vasodilators such nitrates, urapi-

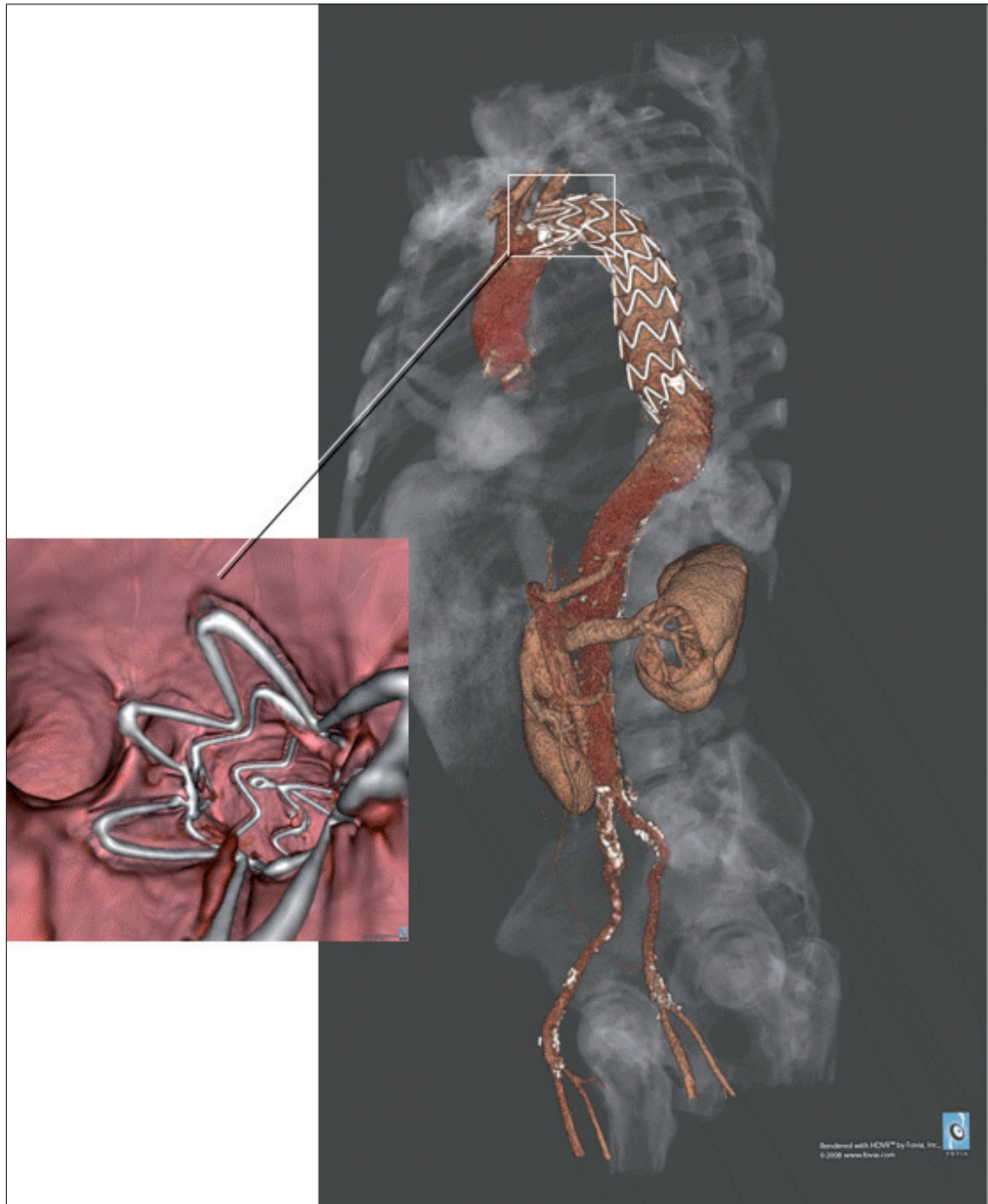


Figure 3

Three-dimensional computed tomography angiography (3D CTA) of thoracic aortic aneurysm exclusion. In the box is visible the endoluminal reconstruction of 3D CTA: note that proximal stent lays at the origin of left carotid artery without covering it.

dil. Nitroprusside or adenosine-induced asystole is never used. After deployment of the endograft on the selected location a completion angiogram is performed.

The wounds are closed as our standard practice. Special care is mandatory when removing the introducer sheath, as rupture of the external iliac artery at its origin is more likely to happen with thoracic endografts. It is particularly advisable to leave the guide wire in place until the sheath is completely removed in order to perform an emergent endoclamp in case of iliac rupture.

Endograft

The objective of a device intended for treatment of an aortic aneurysm is clear cut: it must prevent aneurysm rupture. This is achieved by effectively excluding the aneurysmal sac from circulation, in the absence of blood flow and pressure within the sac, thrombus will form and with time the sac itself may regress or disappear altogether. For aortic dissection the degree of uncertainty is greater, in uncomplicated acute cases without dilatation of the aortic wall, closure of the proximal intimal tear may achieve healing of the aorta. However the device itself may produce additional tears at both the proximal and distal level of the fragile diseased aorta. Most currently available endografts are not primarily intended for the treatment of this condition especially if they carry proximal or distal uncovered stents, hooks or barbs. For chronic cases, closure of the intimal tear may produce thrombosis of the false lumen. Stabilization of the flap and enlargement of the true lumen are also desirable. It must be remembered that effective obliteration of the false lumen may compromise the circulation to arteries that arise from the false lumen itself (i.e. left renal artery), flow to all important vessels must therefore be verified and additional procedures (i.e. stent-

ing) may be necessary to restore flow in these vessels.

In most other cases the use of aortic endografts is off label and experimental; for instance experience with endovascular treatment of traumatic lesions, penetrating ulcers, intra-mural hematoma is increasing and a few cases have been described in the literature.

Follow-up

Once an endograft has been successfully implanted, the patients need to undergo follow up imaging to confirm that everything is working properly, and if something is wrong, to allow for a timely and safe procedure to fix the problem.

The presence of metal parts (that are very radio-opaque) in the endovascular prostheses makes the postoperative scans not only important for the patient's safety but also fascinating to look at (*Figure 3*). Once again appropriate post-processing of the images is mission-critical for an accurate diagnosis.

RESULTS

Our experience with use of thoracic endovascular aortic repair started back in 1998. Since then we have performed a total of 322 procedures. Of these 116 involved the aortic arch with partial/total rerouting of the supra-aortic vessels, 172 involved the descending thoracic aorta, and 34 were hybrid procedures for pathology of the thoracoabdominal district. A total of 126 procedures were conducted for degenerative aneurysms of the descending thoracic aorta. Considering specifically the descending thoracic aorta our technical success rate, i.e. deployment of endograft with complete exclusion of the lesion/minimal endoleak, was 99.4% (with one case requiring emergent open conversion). Perioperative mortality was 2.9% (five patients).

The rate of pulmonary complication, i.e. the need for more than 24 hours of mechanical ventilation, was 1.2%. The rate of cardiac complication, i.e. new onset myocardial necrosis demonstrated by positive cardiac biomarkers tests, has been 0.6%. The rate of renal complication, i.e. the need for temporary or permanent renal replacement therapy, was 1.9%. Cerebrovascular accident, defined as a new neurologic deficit lasting more than 24 hours confirmed by imaging, occurred in 1.2% of patients. The rate of spinal cord ischemia, manifesting either as paraplegia or paraparesis, was 5.2%. We experienced an even distribution between early and delayed onset paraplegia/paraparesis. Delayed onset spinal cord ischemia had a tendency towards amelioration with adequate pressure support and cerebrospinal fluid drainage.

DISCUSSION

In spite of the great enthusiasm that endovascular techniques provoked and that are confirmed by the excellent results of our case series, it must be remembered that particularly at the level of the thoracic aorta these techniques are by no means completely safe. A significant mortality and morbidity is described in all published series. A French report from Ricco JB and coworkers for example, analyzed a countrywide experience over two years and showed an high rate of complications (1).

Damage to access vessels

Several literature reports pointed out that serious and even fatal problems may arise from introduction of the device from the femoral artery. In particular rupture or avulsion of the external iliac artery have been reported, this usually becomes dramatically evident only at the time the large introducer sheath used for endograft de-

livery is withdrawn. We therefore liberally switch to extra-peritoneal surgical exposure of the common iliac artery or even the distal aorta if it is difficult to advance the device through the femoral arteries.

Stroke

Cerebrovascular accidents are among the most common and dreaded complications of endovascular therapy of thoracic aortic disease. They are mainly linked to atheromatous embolization into the cerebral arteries caused by guide wires, catheters, introducer sheaths manipulation or the endograft itself (2). It should be remembered that angiography for diagnostic purposes alone carries a 1-2% risk of complications (3). Second generation commercial grafts are surely less prone to this complication than the home made devices used initially. This is due to the better flexibility of the grafts and sheaths and to the smaller profiles, that results in improved navigability through the access vessels. Greater experience of the operators may also play a role both in the selection of candidates with adequate anatomical characteristics and during the procedure itself. Anyhow, minimal manipulation of the wires and catheters and a meticulous technique do play a significant role in the prevention of perioperative stroke.

Paraplegia

Endoluminal repair allows the avoidance of aortic cross clamping and its sequelae; however, the intercostal arteries covered by the endograft cannot be reimplemented. The reported incidence of both immediate and delayed paraplegia in patients undergoing endovascular procedures of thoracoabdominal aortic aneurysms can be as high as 12% of cases (4-6). The coverage of a long thoracic aortic segment has been reported to be a significant risk factor for spinal cord injury (7). Patients who have open abdomi-

nal aortic aneurysms repair also appear to be prone to such a risk because of the marginal spinal cord collateral blood supply secondary to the ligation of lumbar arteries performed during the surgical procedure. Also, proximal collateral circulation of the spinal cord may be put at risk by the occlusion of the left subclavian artery (landing zone 2) that abolishes the contribution to the blood supply provided by the anterior spinal artery, a branch of the ipsilateral vertebral artery. Finally, spinal cord injury could be precipitated by the late sealing of a type II endoleak or late thrombosis of collateral pathways.

In a recent study (8) we analyzed our most recent 5-year experience with repairs of thoracic aortic pathology to evaluate the incidence and investigate the determinants of spinal cord ischemia in endovascular procedures, identify patients at risk, and assess the role and efficacy of prophylactic adjuncts and therapeutic measures. Our data showed that the lack of collateral spinal cord blood supply through the lumbar arteries in patients with previous aortic repair appears to be a relevant risk factor even though it did not reach statistical significance in our series. The intentional occlusion of the left subclavian was not a predictor of paraplegia and neither was the exclusion of an extensive thoracic aortic segment. Among the perioperative variables, only a mean arterial pressure < 70 mmHg was a statistically significant determinant of delayed neurologic deficit ($P < .0001$). A delayed neurologic deficit developed in four patients, completely resolved after the institution of CSF drainage, steroids administration, and arterial pressure pharmacologic adjustment.

Our experience addresses the importance of hemodynamic control to prevent postoperative neurologic deficits and encourages aggressive, postoperative care of these patients. In our practice, we now try to main-

tain a perioperative mean arterial pressure of > 90 mmHg and use cerebrospinal fluid drainage in patients deemed at high risk, including those who received abdominal aortic aneurysms repair. In this respect, patients with synchronous thoracic and abdominal aortic aneurysms, which we earlier treated simultaneously for both aneurysms, currently undergo staged procedures to better allow the development of collaterals for spinal cord blood supply. In the case of delayed paraplegia, prompt cerebrospinal fluid drainage, if not previously instituted, is also used to keep the cerebrospinal fluid pressure < 10 mm Hg and possibly reverse the deficit.

Aorto-esophageal fistula

As follow-up is becoming longer and the reported series larger, new serious complications are emerging. One of the most ominous one is endograft infection (*Figure 4*), especially if sustained by an aorto-esophageal fistula (*Figure 5*).

There are at this time several reports in the literature. It may be caused by erosion of the endograft through the aortic wall into the esophagus, and we may speculate that excessive over-sizing may contribute. This complication does not seem to be specific to a single device. Sometimes it presents as a fatal hemorrhage however sometimes the presentation is less dramatic at it may be characterized by pain, dysphagia, hematemesis, and septic symptoms. Treatment is very problematic and the outcome without treatment is invariably fatal.

Migration

Successful long term aneurysm exclusion requires the durability of proximal and distal fixation sites against the bloodstream forces, the fatigue of the materials and the morphological behavior of the aneurysm. The Society for Vascular Surgery/American Association for Vascular Surgery (SVS/

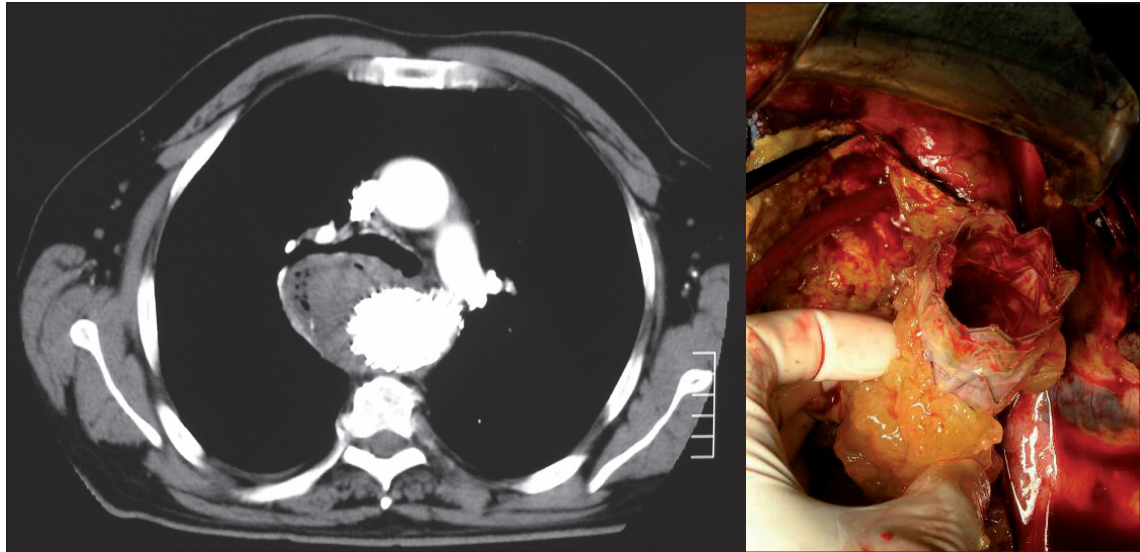


Figure 4

On the left: axial computed tomography scan of an infected thoracic endograft. Note the presence of air bubbles (arrows) clearly indicating the presence of bacterial flora. On the right: intraoperative picture showing the removal of the stent graft.

AAVS) standards (9) defined endograft migration any movement relative to anatomical therapy. To address this problem, a variety of fixation methods such as hooks,

barbs, free-flows and longitudinal support devices have been developed (10) and each presented peculiar advantages and drawbacks. Due to the extreme friability of the

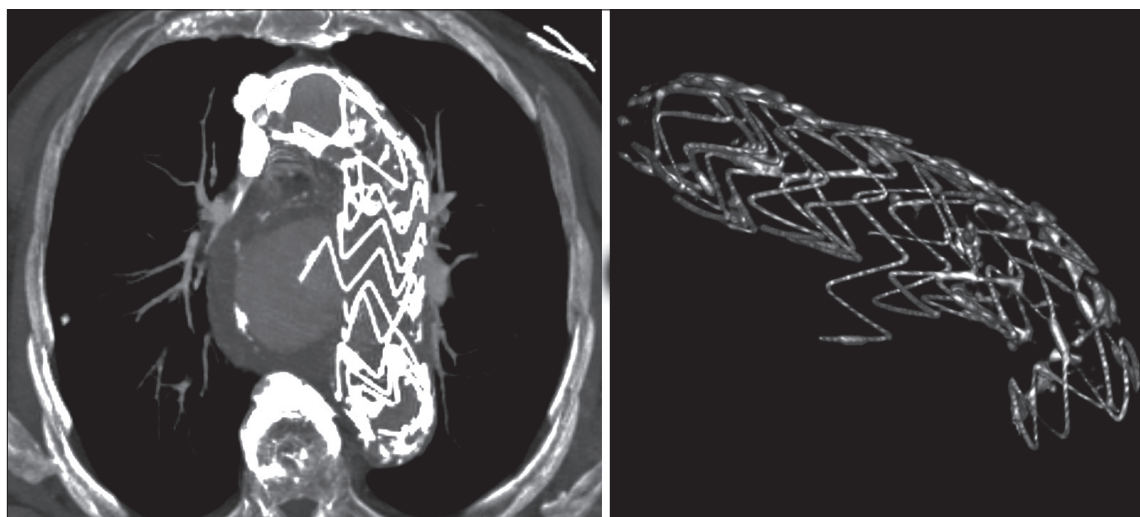


Figure 5

Postoperative computed tomography showing endograft stent rupture leading to bleeding and aorto-esophageal fistula.

aortic wall of a dissected aorta, the use of trans-rupture of the longitudinal support wire is a well known complication that affected the first generation thoracic Gore TAG device stressed by the bending forces arising in the arch or in kinked aneurysms.

CONCLUSION

The descending thoracic aorta is the ideal morphological site for application of endograft technology being the more large straight tubular arterial segment of human body. It has been the first site of aortic aneurysm endograft exclusion as published by Volodos' et al. yet in 1988 (11), 3 years before Parodi et al. reported the first series of abdominal aortic aneurysm stent-graft repair (12). Since the pioneering experience of Volodos' and the first renowned short series of thoracic aortic aneurysm endovascular repair published by Dake et al in '94 (13), many series, registries and trials have confirmed feasibility and reduced invasivity of thoracic aortic aneurysms endovascular repair leading to a real worldwide revolution in the therapeutic approach to the descending aortic diseases.

The endovascular era opened new attractive scenarios with many hopes so that, currently, the open repair of an aneurysm limited to the descending aorta, especially to its middle part has become a really unusual occurrence in the most of European vascular centers.

Even in our Center, in the last years we observed a progressive shift in the selection of patients for TEVAR of the descending thoracic aorta. At the beginning of our experience (the first 4-5 years) TEVAR was limited to those patients presenting with one or more serious comorbidities, while open surgery remained the choice for those in fair clinical conditions. In particular TEVAR was the treatment of choice in the elderly

(> 77 years), in patients with a depressed ejection fraction (< 40%), in patients with severe pulmonary disease (home oxygen therapy, severe obstruction) and with a life expectancy of less than 5 years.

Starting 3 years ago, mainly within investigational protocols and trials, we have gradually increased the rate of patients undergoing TEVAR. Derived from this new attitude, we experienced really appealing results of TEVAR also in fit surgical patients, especially with critical intercostal arteries left uncovered.

However, studies clearly addressing the respective roles of open and endovascular repair are still not available, and the worldwide spreading of expensive endovascular materials and facilities, with the extensive follow-up for endografting add to the cumulative escalation of overall health care costs.

Furthermore the stents have been designed to have a durability of 10 years based on ISO (International Standardization Organization) stress testing and the series with the greatest number of patients reach maximum 5 years of follow-up, and are by now associated to a high rate of reinterventions (14).

In conclusion, in order to treat both patients unfit for open surgery and patients with long life-expectancy especially with challenging anatomies for endograft deployment, both TEVAR and open repair (15) should be part of therapeutic armamentarium of every modern vascular surgeon efficiently approaching thoracic vascular diseases.

REFERENCES

1. Ricco JB, Goeau-Brissonniere O, Rodde-Dunet MH, et al. Use of abdominal aortic endovascular prostheses in France from 1999 to 2001. *J Vasc Surg* 2003; 38: 1273-1281.
2. Taylor PR, Gaines PA, McGuinness CL, et al. Thoracic aortic stent grafts - early experience from two centres using commercially available

- devices. *Eur J Vasc Endovasc Surg* 2001; 22: 70-76.
3. Willinsky RA, Taylor SM, TerBrugge K, et al. Neurologic complications of cerebral angiography: prospective analysis of 2,899 procedures and review of the literature. *Radiology* 2003; 227: 522-528.
 4. Bell RE, Taylor PR, Aukett M, et al. Mid-term results for second-generation thoracic stent grafts. *Br J Surg*. 2003; 91: 811-817.
 5. Criado FJ, Clark NS, Barnatan MF. Stent graft repair in the aortic arch and descending thoracic aorta: a 4-year experience. *J Vasc Surg* 2002; 31: 1121-1128.
 6. Greenberg R, Resch T, Nyman U, et al. Endovascular repair of descending thoracic aortic aneurysms: an early experience with intermediate-term follow-up. *J Vasc Surg* 2000; 31: 147-156.
 7. Gravereaux EC, Faries PL, Burks JA, et al. Risk of spinal cord ischemia after endograft repair of thoracic aortic aneurysms. *J Vasc Surg*. 200; 34: 997-1003.
 8. Chiesa R, Melissano G, Marrocco-Trischitta MM, et al. Spinal cord ischemia after elective stent-graft repair of the thoracic aorta. *J Vasc Surg*. 2005; 42: 11-17.
 9. Chaikof EL, Blankensteijn JD, Harris PL, et al. Reporting standards for endovascular aortic aneurysm repair. *J Vasc Surg*. 2002; 35: 1048-1060.
 10. Malina M, Lindblad B, Ivancev K, et al. Endovascular AAA exclusion: will stents with hooks and barbs prevent stent-graft migration? *J Endovasc Surg* 1998; 5: 310-317.
 11. Volodos' NL, Karpovich IP, Shekhanin VE, et al. A case of distant transfemoral endoprosthesis of the thoracic artery using a self-fixing synthetic prosthesis in traumatic aneurysm. *Grudn Khir* 1988; 84-86.
 12. Parodi JC, Palmaz JC, Barone HD. Transfemoral intraluminal graft implantation for abdominal aortic aneurysms. *Ann Vasc Surg* 1991; 5: 491-499.
 13. Dake MD, Miller DC, Semba CP, et al. Transluminal placement of endovascular stent-grafts for the treatment of descending thoracic aortic aneurysms. *N Engl J Med* 1994; 331: 1729-1734.
 14. Makaroun MS, Dillavou ED, Wheatley GH, et al; Gore TAG Investigators. Five-year results of endovascular treatment with the Gore TAG device compared with open repair of thoracic aortic aneurysms. *J Vasc Surg*. 2008; 47: 912-918.
 15. R. Chiesa, Y. Tshomba, E. Civilini, et al. Open repair of descending thoracic aneurysms. *HSR Proceedings in Intensive Care and Cardiovascular Anesthesia* 2010; 3: 177-190.