


Case Report

A case of omental herniation through the esophageal hiatus successfully treated by laparoscopic surgery

Koichiro Sueyoshi,¹  Yoshiaki Inoue,^{1, 3} Yuka Sumi,¹ Ken Okamoto,¹ Daisuke Azuma,² Seiichiro Yoshikawa,² Masaki Fukunaga,² and Hiroshi Tanaka¹

¹Department of Emergency and Critical Care Medicine, ²Department of Surgery, Juntendo University Urayasu Hospital, Urayasu, Chiba, and ³Department of Emergency and Critical Care Medicine, University of Tsukuba, Tsukuba, Ibaraki, Japan

Case: We report a rare case of omental herniation through the esophageal hiatus. A 46-year-old man visited our emergency department complaining of epigastralgia. Abdominal examination revealed muscular defense and rebound tenderness in his upper abdomen. A computed tomography scan showed a fat density mass in the posterior mediastinum. A laparoscopic operation was carried out under the diagnosis of omental herniation through the esophageal hiatus.

Outcome: Abdominal pain disappeared dramatically after the operation. The postoperative course was uneventful.

Conclusion: Although a fat density mass in the posterior mediastinum is likely to be diagnosed as a lipomatous tumor, omental herniation through the esophageal hiatus should be taken into consideration as a possible diagnosis for acute abdominal pain in the emergency department.

Key words: CT, laparoscopy, mediastinum, omental herniation, paraesophageal hernia

INTRODUCTION

OMENTAL HERNIATION (OH) through the esophageal hiatus without involving the stomach is rare. To the best of our knowledge, only nine cases have been reported in English published works. Omental herniation through the esophageal hiatus mimics mediastinal lipomatous tumor. When the fat density mass in the posterior mediastinum is recognized, we should take OH into consideration as a differential diagnosis. Here we describe our case that was diagnosed preoperatively and treated successfully by laparoscopic surgery. This is the first report of OH treated by laparoscopic surgery, published with the patient's informed consent.

Corresponding: Koichiro Sueyoshi, MD, PhD, Department of Emergency and Critical Care Medicine, Juntendo University Urayasu Hospital, 2-1-1 Tomioka, Urayasu, Chiba 279-0021, Japan. E-mail: ksueyoshi@juntendo-urayasu.jp.

Received 22 Feb, 2017; accepted 24 Apr, 2017; online publication 6 Jul, 2017

Funding Information

No funding information provided.

CASE

A 46-YEAR-OLD MAN visited our emergency department (ED) complaining of epigastralgia, nausea, and vomiting. At the first visit, the cause of pain was unclear. As his symptoms worsened after going home, he revisited our emergency department the next day.

The patient had a history of diabetes mellitus and diabetic nephropathy. His vital signs were normal. Abdominal examination revealed muscular defense, severe upper abdominal tenderness, and rebound tenderness. Laboratory data showed leukocytosis (white blood cell count 15,000/ μ L) and slight elevation of C-reactive protein (1.4 mg/dL). In addition, azotemia, due to chronic renal failure, was recognized (blood urea nitrogen / creatinine, 69/6.15 mg/dL). Acidosis and hyperlactacidemia were not confirmed. Chest X-ray revealed a large and sharply defined retro-cardiac mass (Fig. 1A). A computed tomography (CT) scan revealed a large fat density mass in the posterior mediastinum (Fig. 1B). An enhanced CT with a contrast medium was not undertaken due to the patient's chronic renal failure. The sagittal and coronal view of the CT scan revealed a fat density mass extending from the abdominal cavity to the mediastinum (Fig. 1C, D), so we suspected the diagnosis was an

OH through the esophageal hiatus. A laparoscopic operation was carried out under general anesthesia on the day of his admission. When the lesser omentum was divided with a harmonic scalpel, the greater omentum appeared under the lesser omentum. As shown in the video (Video S1), the reversed greater omentum entered the omental bursa behind the stomach and herniated into the esophageal hiatus through the omental bursa (Fig. 2). The herniated omentum was pulled out and the esophageal hiatus was repaired by direct suture. The patient restarted a regular diet on postoperative day 4, and was discharged on day 13. His postoperative course was uneventful.

DISCUSSION

OMENTAL HERNIATION THROUGH the esophageal hiatus is rare. To the best of our knowledge, our case is only the 10th reported.^{1–9} All cases have involved relatively young men. Three cases manifested symptoms, such as postprandial pain, difficulty in swallowing, and epigastralgia. In five cases, patients were diagnosed as OH

preoperatively. Eight cases underwent surgery, and two cases were managed conservatively under the diagnosis of OH. The operative procedures of six patients were thoracotomy. In two cases, the operative procedures were not described. The abdominal approach (laparotomy or laparoscopy) has not been reported previously. This is the first case of laparoscopic surgery for OH (Table 1).

As thoracotomies were carried out in other cases, the mechanism of OH in the abdominal cavity is unclear. In our case, we explored the abdominal cavity and elucidated the mechanism of OH. In normal anatomy, the greater omentum develops from the adhesion of the dorsal mesogastrium. However, in this case, the adhesion was not confirmed. Consequently, the greater omentum was reversed and herniated into the esophageal hiatus through the omental bursa. While exploring the abdominal cavity, we could not recognize the abnormality until the lesser omentum was divided and the greater omentum appeared under the lesser omentum. Dissecting the lesser omentum is crucial to identifying the hernial orifice in an abdominal approach.

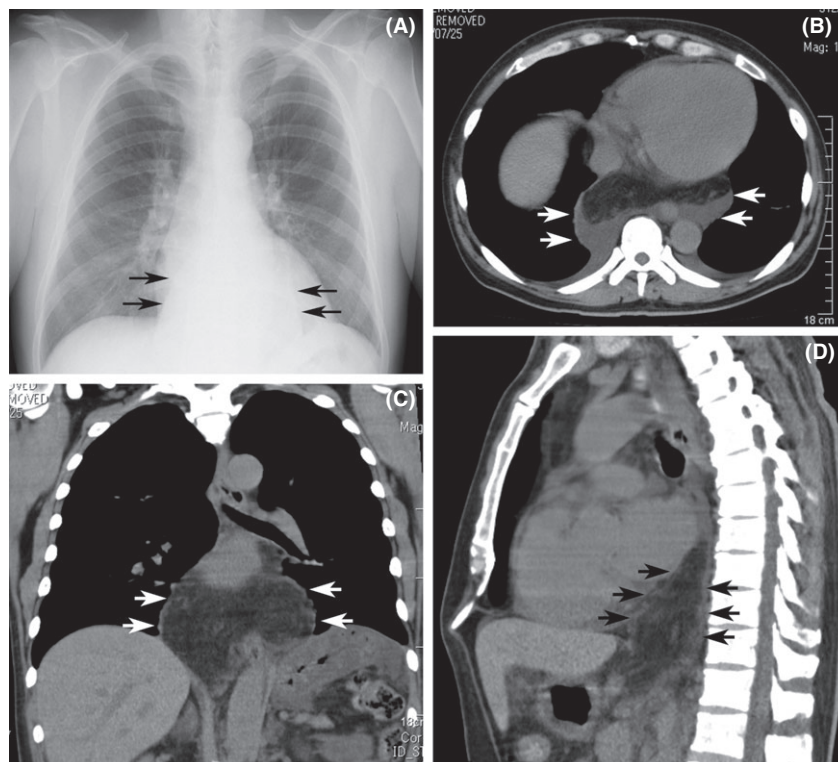


Fig. 1. Radiograph and computed tomography (CT) scans of a 46-year-old man with omental herniation through the esophageal hiatus. A, Chest X-ray shows a large and sharply defined retrocardiac mass (arrows). B, Axial view of CT scan shows a large fat density mass in the posterior mediastinum (arrow). C, D, Sagittal and coronal views of CT scan show a fat density mass extending from the abdominal cavity to the mediastinum (arrow).

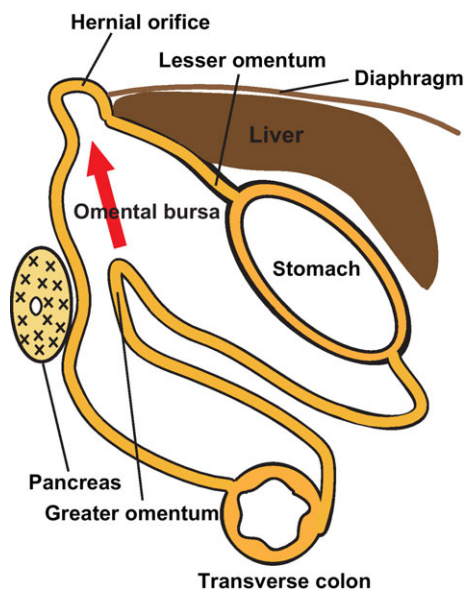


Fig. 2. Diagram of omental herniation through the esophageal hiatus in a 46-year-old man. The reversed greater omentum entered the omental bursa behind the stomach and herniated into the esophageal hiatus through the omental bursa.

When a mass with fat density is recognized in the posterior mediastinum, the possible diagnoses are lipomatous tumor (lipoma or liposarcoma) or OH. Kubota *et al.*⁶ summarized seven previous reports to determine adequate means of diagnosis, suggesting that two factors are needed to differentiate OH from lipomatous tumor. The first evidence is the continuity of the mass on both sides of the diaphragm, which is determined by coronal or sagittal plane magnetic resonance imaging. The second is the omental vessels

passing through the esophageal hiatus, which can be identified through angiography. As recent technical developments in multidetector CT can provide high-resolution multiplanar reconstruction images, multidetector CT could be a diagnostic method for OH. As noted by Yu *et al.*⁹, a contrast-enhanced CT scan is a potential alternative to magnetic resonance imaging and angiography.

The treatment of OH is controversial. Eight patients underwent surgery and only two patients underwent observation. When a diagnosis is difficult, diagnostic operation by laparoscopy could be considered. When diagnosed with OH and patients have symptoms, an operation should be recommended. When no symptoms are present, tight conservative observation could be acceptable.⁶ However, we propose an operation should be considered because OH may induce obstruction, bleeding, and perforation of the stomach, caused by gastric volvuli due to the traction of the greater omentum. Concerning an operative procedure, the abdominal approach, especially by laparoscopic surgery, is preferable as it allows for easy repair of the esophageal hiatus.

CONCLUSION

WE ENCOUNTERED A rare case of OH through the esophageal hiatus, which could be diagnosed preoperatively and treated successfully by laparoscopic surgery.

Regarding treatment of OH, an operation, particularly laparoscopic, could be the first choice.

DISCLOSURE

Conflict of Interest: None declared.

Table 1. Summary of case reports of omental herniation (OH) through the esophageal hiatus

Case	Primary author, year	Age, years/Sex	Symptom	Preoperative diagnosis	Treatment
1	Rohlfing BM, 1977	50/M	Postprandial pain	Unknown	Op
2	Lee MJ, 1990	76/M	None	OH	Conservative
3	Rockoff SD, 1993	67/M	None	OH	Op
4	Kato N, 1999	54/M	None	LT	Op (thoracotomy)
5	Anderson TM, 1999	43/M	Difficulty in swallowing	Unknown	Op (thoracotomy)
6	Kubota K, 2001	74/M	None	OH	Conservative
7	Yunoki J, 2004	61/M	None	LT	Op (thoracotomy)
8	Maruyama R, 2005	20/M	None	LT	Op (thoracotomy)
9	Yu CY, 2013	59/M	None	OH	Op (thoracotomy)
10	Sueyoshi K, 2017	46/M	Epigastralgia	OH	Op (laparoscopy)

LT, lipomatous tumor; M, male; Op, operation.

REFERENCES

- 1 Rohlfing BM, Korobkin M, Hall AD. Computed tomography of intrathoracic omental herniation and other mediastinal fatty masses. *J. Comput. Assist. Tomogr.* 1977; 1: 181–3.
- 2 Lee MJ, Breathnach E. CT and MRI findings in paraesophageal omental herniation. *Clin. Radiol.* 1990; 42: 207–9.
- 3 Rockoff SD, Aaron BL, Black C, Kathuria R, Biben L. Diagnosis of paraesophageal omental hiatal hernia by magnetic resonance imaging. *Chest* 1993; 103: 285–7.
- 4 Kato N, Iwasaki H, Rino Y, Imada T, Amano T, Kondo J. Intrathoracic omental herniation through the esophageal hiatus: report of a case. *Surg. Today* 1999; 29: 347–50.
- 5 Anderson TM, Gibbs JF, Kollmorgen DR, Urschel JD. Paraesophageal omental hernia mimics pleural lipomatous tumor. *J. Cardiovasc. Surg. (Torino)* 1999; 40: 757–9.
- 6 Kubota K, Ohara S, Yoshida S, Nonami Y, Takahashi T. Intrathoracic omental herniation through the esophageal hiatus: a case report. *Radiat. Med.* 2001; 19: 307–11.
- 7 Yunoki J, Ohteki H, Naito K, Hisajima K. Omental herniation through the esophageal hiatus mimics mediastinal lipomatous tumor. *Jpn. J. Thorac. Cardiovasc. Surg.* 2004; 52: 580–2.
- 8 Maruyama R, Miyamoto T, Shoji F, Okamoto T, Miyake T, Ichinose Y. Intrathoracic omental herniation through the esophageal hiatus in a young patient. *Jpn. J. Thorac. Cardiovasc. Surg.* 2005; 53: 452–4.
- 9 Yu CY, Ni YM. Diagnosis and surgical treatment of intrathoracic omental herniation through the esophageal hiatus. *Chin. Med. J. (Engl)* 2013; 126: 194–5.

SUPPORTING INFORMATION

Additional Supporting Information may be found in the online version of this article at the publisher's web-site:

Video S1. Laparoscopic surgery for omental herniation through the esophageal hiatus in a 46-year-old man. The lesser omentum was divided with a harmonic scalpel, then the greater omentum was evident underneath. The reversed greater omentum entered omental bursa under the stomach and herniated into the esophageal hiatus through the omental bursa. The herniated omentum was pulled out.