

## Case Report

DOI: 10.22114/ajem.v0i0.80

## Gender-Based Violence Causing Severe Multiple Injuries; a Case Report

Adalard Falschung\*

Department of Urology, Rechts der Isar Hospital, Haidhausen District of Munich, Germany.

\*Corresponding author: Adalard Falschung; Email: avalard.falschung@gmail.com

Published online: 2018-04-11

## Abstract

**Introduction:** Gender-based violence (GBV) against women has been identified as a global health and development issue. We reported a case of GBV causing severe, multiple injuries in a middle-aged female.

**Case report:** A 47-year-old woman presented to emergency room with disturbed level of consciousness, shortness of breath and multiple patches of skin discoloration. On examination, the patient was semi-conscious, with multiple ecchymosis and bilateral decreased air entry. Computed tomography scan of the neck and chest showed six rib fractures on the left side, and eight rib fractures on the right side, sternal fracture, manubriosternal dislocation, bilateral hemothorax, fracture of body of 11<sup>th</sup> thoracic vertebra, and fracture of cervical spine of 5<sup>th</sup> and 7<sup>th</sup> vertebrae. The patient was intubated and admitted to intensive care unit. She was discharged with good health condition after 23 days of hospital admission.

**Conclusion:** GBV is still a cause of severe trauma that puts the patient's life at risk.

**Key words:** Advanced trauma life support care; Gender-based violence; Intimate partner violence

**Cite this article as:** Falschung A. Gender-Based Violence Causing Severe Multiple Injuries; a Case Report. Adv J Emerg Med. 2018;2(3): e35.

## INTRODUCTION

Gender-based violence (GBV) against women has been identified as a global health and development issue; So a host of policies and public education programs have been undertaken around the world that aim at reducing GBV (1). It has been identified as a global public health and human rights priority that leads to high rates of morbidity and mortality (2). GBV is generally understood to include physical, sexual, and psychological abuse from intimate partners, sexual violence by non-partners, sexual abuse of girls, and acts such as trafficking women for sex (3).

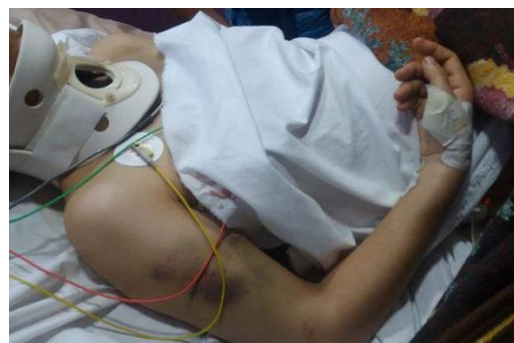Apart from physical injury, GBV increases long-term risk of other complications, including physical disability, chronic pain, depression, and drug and alcohol abuse (4).

There are many fatal and non-fatal conditions, which may occur post violence in women like suicide, homicide, functional impairment, maternal mortality, physical symptoms, chronic pain syndromes, permanent disability, gastrointestinal disorders, fibromyalgia, somatic complaints, post-traumatic stress, anxiety, depression, eating disorders, panic disorder, low self-esteem, sexual dysfunction, substance abuse, smoking, sexual risk-taking, unsafe abortion, and unwanted pregnancy (4). We report a case of GBV causing severe morbidity and multiple serious bone fractures with

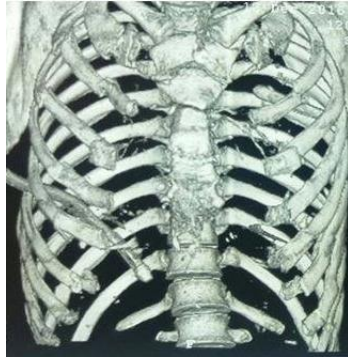three weeks of hospitalization in intensive care unit (ICU).

## CASE PRESENTATION

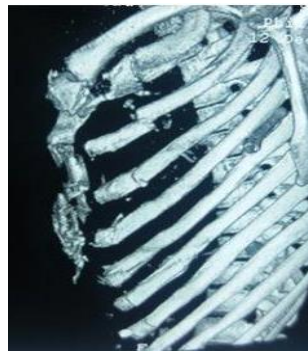A 47-year-old female, mother of 4 children, presented to emergency room (ER) at 2.00<sup>am</sup> with chest pain, disturbed level of consciousness, shortness of breath and multiple patches of skin discoloration. On examination the patient was semi-conscious, multiple ecchymosis was found all over body (figure 1), bilateral good air entry. On arrival vital signs were as follow: blood pressure (BP) = 120/80 mmHg, pulse rate (PR) = 102/min, respiratory rate (RR) = 18/min, and oxygen



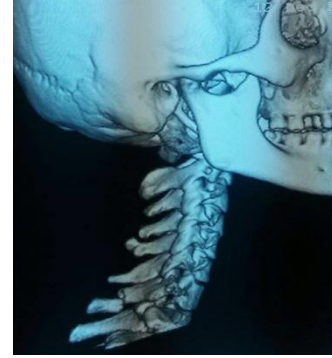
**Figure 1:** Patient's general appearance shows multiple ecchymosis all over the body



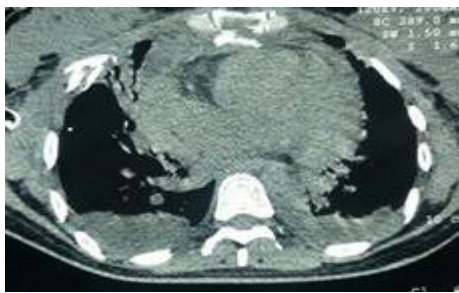
**Figure 2:** 3D computed tomography scan of the patient's chest showing multiple rib fracture on both sides



**Figure 3:** 3D computed tomography scan of the patient's chest showing sternal fracture



**Figure 4:** 3D computed tomography scan of the patient's neck showing 5<sup>th</sup> and 7<sup>th</sup> cervical vertebral spinous process fracture



**Figure 5:** Axial view of computed tomography scan of the patient's chest showing bilateral hemothorax



**Figure 6:** Axial view of computed tomography scan of the patient's chest showing 11<sup>th</sup> thoracic vertebral body fracture

saturation (O<sub>2</sub>sat) = 82% with face mask. On the clinical bases, bilateral thoracostomy drains were inserted. Chest x-ray was inconclusive. Computed tomography scan of the chest and neck showed eight rib fractures on left side, six rib fractures on the right side, sternal dislocation and manubriosternal fracture (figure 2, 3), fracture of 5<sup>th</sup> and 7<sup>th</sup> cervical vertebrae (figure 4), left side hemothorax (figure 5), fracture of body of 11<sup>th</sup> thoracic vertebrae (figure 6). After imaging, the patient was transferred to ICU and intubated as the oxygen saturation decreased. Percutaneous jejunostomy was applied for feeding. Tracheostomy was done eight days after endotracheal intubation. The patient remained in intubated state in ICU for 18 days, four days later the patient was discharged from ICU and she was admitted in ward for one week and discharged from the hospital with good health 23 days after admission.

#### DISCUSSION

Our case remained in hospital for 23 days with 16-day of ICU hospitalization under invasive continues monitoring. In this battle, the male was totally free from injury; he had neither a minor nor a major wound.

Violence erodes women's self-esteem, sapping

their energy, and compromise their physical and psychological health. Aggressive females believe that aggression are a main mean to win an argumentum. Violence against male gender although least recognized, is a wide-spread human rights violation all over the world. But, GBV is less likely to injures male comparison to females (5-7). Nevertheless, perhaps females need to recognizes that although male and female aggressions are not the same, in both of them aggression is regarded as a criminal act (8). Severe and multiple trauma, which were found in our case, confirm that the female was not able to even defend herself. It is reported that bidirectional violence result in more severe injuries in intimate partner violence, especially for the female (9). The only parts our victims played in the violence was disobeying a command by her partners related to a social problem. According to the literature, there are an association between being a rural resident with victimization of girls and GBV. Other reports have shown that there is an association between adolescent dating violence and alcohol and drug abuse, higher numbers of sexual partners and being a gang member (10). Our case was from a rural area at the age of 40 and her husband was a drinker with a single sexual partner.

According to some reports, the positive association

is at its highest level among unmarried females. From this, we can conclude that national data that focus mainly on married females cannot give us the exact picture of the prevalence of intimate partner violence in females' lives.

#### CONCLUSIONS

GBV is still a cause of severe trauma that puts the patient's life at risk. It might cause profound health problems that may need ICU admission.

#### ACKNOWLEDGMENTS

We acknowledge all hospital staff who served the patients.

#### REFERENCES

1. Russo NF, Pirlott A. Gender-based violence: concepts, methods, and findings. *Ann N Y Acad Sci.* 2006;1087:178-205.
2. Shannon K, Kerr T, Strathdee SA, Shoveller J, Montaner JS, Tyndall MW. Prevalence and structural correlates of gender based violence among a prospective cohort of female sex workers. *BMJ.* 2009;339:b2939.
3. Dunkle KL, Jewkes RK, Brown HC, Gray GE, McIntyre JA, Harlow SD. Gender-based violence, relationship power, and risk of HIV infection in women attending antenatal clinics in South Africa. *Lancet.* 2004;363(9419):1415-21.
4. Heise L, Ellsberg M, Gottmoeller M. A global overview of gender-based violence. *Int J Gynaecol Obstet.* 2002;78 Suppl 1:S5-14.
5. Swan SC, Gambone LJ, Caldwell JE, Sullivan TP, Snow DL. A review of research on women's use of violence with male intimate partners. *Violence Vict.* 2008;23(3):301-14.
6. Cano A, Vivian D. Life stressors and husband-to-wife violence. *Aggress Violent Behav.* 2001;6(5):459-80.
7. Campbell J, Jones AS, Dienemann J, Kub J, Schollenberger J, O'Campo P, et al. Intimate partner violence and physical health consequences. *Arch Intern Med.* 2002;162(10):1157-63.
8. Leisring PA. What will happen if I punch him? Expected consequences of female violence against male dating partners. *J Aggress Maltreat Trauma.* 2009;18(7):739-51.
9. Orcutt H, Garcia M, Pickett S. Female-perpetrated intimate partner violence and romantic attachment style in a college student sample. *Violence Vict.* 2005;20(3):287.
10. Rivera-Rivera L, Allen-Leigh B, Rodriguez-Ortega G, Chavez-Ayala R, Lazcano-Ponce E. Prevalence and correlates of adolescent dating violence: baseline study of a cohort of 7,960 male and female Mexican public school students. *Prev Med.* 2007;44(6):477-84.

#### AUTHORS' CONTRIBUTION

Adalard Falschung; Major contribution to the concept and design, writing the manuscript and final revision of the manuscript.

#### CONFLICTS OF INTEREST

None to be declared.

#### FUNDING:

None to be declared.