

A diagnostic challenge: An incidental lung nodule in a 48-year-old nonsmoker

Blake Eric Christianson, Supriya Gupta¹, Shikhar G Vyas², Helena Spartz², Jayanth H Keshavamurthy¹

Medical College of Georgia, Departments of ¹Radiology and ²Pathology, Medical College of Georgia, Augusta, GA, USA

ABSTRACT

A 43-year-old female with a medical history of renal stones, hypertension, diabetes mellitus Type 2, and depression presented to her urologist with bilateral flank pain. She complained of worsening exertional dyspnea over the last several months with recent weight gain. She also endorsed night sweats and intermittent, scant hemoptysis over the past year. She denied fever, chills, nausea, vomiting, diarrhea, constipation, hematuria, or excessive joint or muscle pain. Physical examination was unremarkable. Computed tomography scan of abdomen and pelvis demonstrated bilateral nonobstructing renal stones and a 1.8 cm × 1.7 cm nodular opacity in the right lower lobe of the lung, not present on previous scan 1 year prior. Surgical wedge resection was performed and subsequent pathologic examination demonstrated a 1.2 cm × 0.6 cm × 0.5 cm soft, gelatinous well-demarcated mass in the right lower lobe wedge specimen without gross evidence of necrosis or hemorrhage confirming colloid adenocarcinoma of the lung.

KEY WORDS: Colloid adenocarcinoma of the lung, lung nodule, mucinous adenocarcinoma

Address for correspondence: Dr. Helena Spartz, 1103 Peachtree Road, Augusta, GA 30909, USA. E-mail: HSpartz@augusta.edu

INTRODUCTION

Colloid adenocarcinoma of the lung is an extremely rare diagnosis with an unquantified incidence that resembles mucinous adenocarcinoma of the gastrointestinal tract. Tumor sizes vary ranging from <1 up to 10 cm and are generally described as poorly demarcated mucoid nodules.^[1] Neoplastic cells are usually seen floating within lakes of mucin. In 2004, the WHO revised the classification of colloid adenocarcinoma to include mucinous cystadenoma. Mucinous cystadenoma is defined as a colloid tumor circumscribed by a fibrous capsule filled with cystic and mucinous change. Once the tumor has been determined to invade the lung parenchyma or demonstrates significant atypia, it is classified as a colloid adenocarcinoma.^[2] While studies are limited, due to the rare frequency of the disease, several incidences have been associated with tobacco smoking. In one study, the average age of onset was

57 years of age, with a range of 33–81 years, and the male-to-female ratio was 1.7:1.^[3]

Generally, colloid adenocarcinoma of the lung is asymptomatic and found incidentally on imaging ordered for other purposes. If symptomatic, the patient generally experiences hemoptysis and cough as in our case. They can also present with infections of the lung or respiratory symptoms as the lesion slowly enlarges. As seen in our patient, pulmonary function tests are often normal due to the localized nature of the mass. The neoplasm will continue to grow along the alveolar walls, producing copious amount of mucin within the lung parenchyma.

As with any isolated pulmonary nodule found on routine imaging, confirmation should be performed by means of tissue sampling. A positron emission tomography/computed tomography (PET/CT) scan should also be

This is an open access journal, and articles are distributed under the terms of the Creative Commons Attribution-NonCommercial-ShareAlike 4.0 License, which allows others to remix, tweak, and build upon the work non-commercially, as long as appropriate credit is given and the new creations are licensed under the identical terms.

For reprints contact: reprints@medknow.com

How to cite this article: Christianson BE, Gupta S, Vyas SG, Spartz H, Keshavamurthy JH. A diagnostic challenge: An incidental lung nodule in a 48-year-old nonsmoker. Lung India 2018;35:251-5.

Access this article online	
Quick Response Code: 	Website: www.lungindia.com
	DOI: 10.4103/lungindia.lungindia_212_17

performed to ensure that this is not a metastatic mucinous tumor from the breast, pancreas, ovary, or gastrointestinal tract. The scan would demonstrate diffuse uptake if colloid adenocarcinoma is present in distant organs and is therefore helpful in confirming a primary or metastatic neoplasm. Immunohistochemical markers can be implemented if the diagnosis is still uncertain after imaging.

Complete surgical resection of the neoplasm with wide margins is the first-line treatment for colloid adenocarcinoma of the lung. An anatomic lobectomy is usually the procedure of choice. Although surgery is usually curative, patients who are not surgical candidates can undergo radiation and chemotherapy. There are currently no molecular therapeutic targets for the neoplasm. Generally, the diagnosis of colloid adenocarcinoma carries a favorable prognosis, but studies vary in their findings. In one study, approximately half of the patients demonstrated tumor recurrence or metastases within a period of 2–192 months.^[3] A separate study estimated an 84.6% survival rate with follow-up ranging from 9 to 95 months from diagnosis of Stage 1 disease.^[4] Future studies with larger sample sizes are needed to substantiate this data.

CASE REPORT

A 43-year-old female with a medical history of renal stones presented to her urologist with bilateral flank pain, status postureteral stent placement, and subsequent removal. Her medical history was significant for insulin-dependent diabetes mellitus Type 2, hypertension, depression, and insomnia. She complained of worsening exertional dyspnea over the last several months with recent weight gain. She also endorsed night sweats and intermittent, scant hemoptysis over the past year. She denied fever, chills, nausea, vomiting, diarrhea, constipation, hematuria, or excessive joint or muscle pain. Her physical examination was unremarkable.

The patient underwent CT scan of the abdomen and pelvis which showed bilateral nonobstructing renal stones and a 1.8 cm × 1.7 cm nodular opacity in the right lower lobe, which was not present on a previous scan 1 year prior. We attribute the 1.8 cm growth within 1 year to be due to this copious mucin production. Subsequently, contrast-enhanced CT of the chest was performed which showed a 1.8 cm, mildly spiculated right lower lobe pulmonary nodule with punctate internal calcification and enhancement [Figure 1a-c]. No focal consolidation or additional pulmonary nodules were identified. PET/CT scan found no evidence for distant metastases, mediastinal masses, or other lung nodules [Figure 2a and b]. The standard uptake value (SUV) of the right lower lobe lung nodule was 3.

Thoracic surgery was consulted, and pulmonary function testing demonstrated normal spirometry, lung volumes,

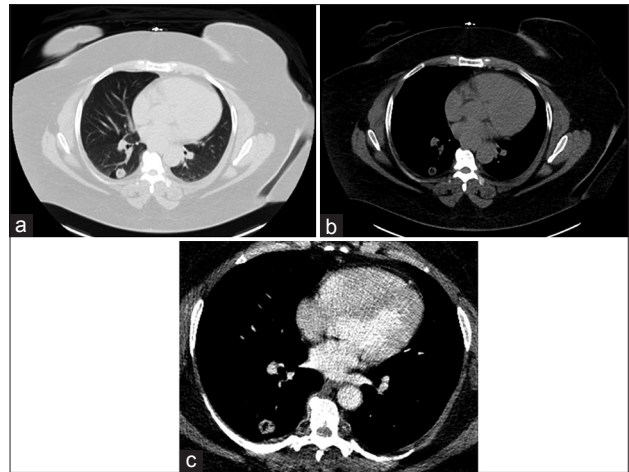


Figure 1: (a) Noncontrast lung window computed tomography image demonstrating a 1.8 cm, mildly spiculated right lower lobe pulmonary nodule. (b) Noncontrast axial computed tomography image demonstrating a 1.8 cm, mildly spiculated right lower lobe pulmonary nodule with punctate internal calcification and septal calcification. (c) Postcontrast administration axial computed tomography image demonstrating enhancement of the 1.8 cm pulmonary nodule in the right lower lobe

and diffusion capacity. After tissue sampling was recommended and options discussed, the patient decided to proceed with surgical wedge resection. While CT-guided needle aspiration and core biopsy can be performed, our patient elected to undergo complete resection before tissue sampling. A diagnostic bronchoscopy demonstrated normal distal trachea and bilateral bronchi. A chest thoracoscopy was used to gain access to the lung nodule and surrounding lymph nodes, and wedge resection was performed with wide margins. Surgical evaluation showed the lesion measured <2 cm, surrounded by lung or visceral pleura, without bronchoscopic evidence of invasion.

Subsequent pathologic examination demonstrated 1.2 cm × 0.6 cm × 0.5 cm soft, gelatinous well-demarcated mass in the right lower lobe wedge specimen, without gross evidence of necrosis or hemorrhage [Figure 3]. The margins of the specimen were not grossly involved. On histology, extensive areas of mucin deposition were noted, with distension and destruction of alveolar walls. While no cystic wall was visualized, the tumor demonstrated cyst-like appearance filled with grayish mucin [Figure 4]. Areas in which the alveolar walls remain intact were focally lined by mucinous epithelium [Figure 5].

DISCUSSION

Radiology discussion

Colloid adenocarcinoma poses a diagnostic and imaging challenge due to its bland radiologic findings.^[5] Radiographically, colloid adenocarcinoma of the lung is most diagnostically sensitive on CT imaging, with contrast administration generally showing subtle enhancement of the lesion. Lesions can present atypically but often

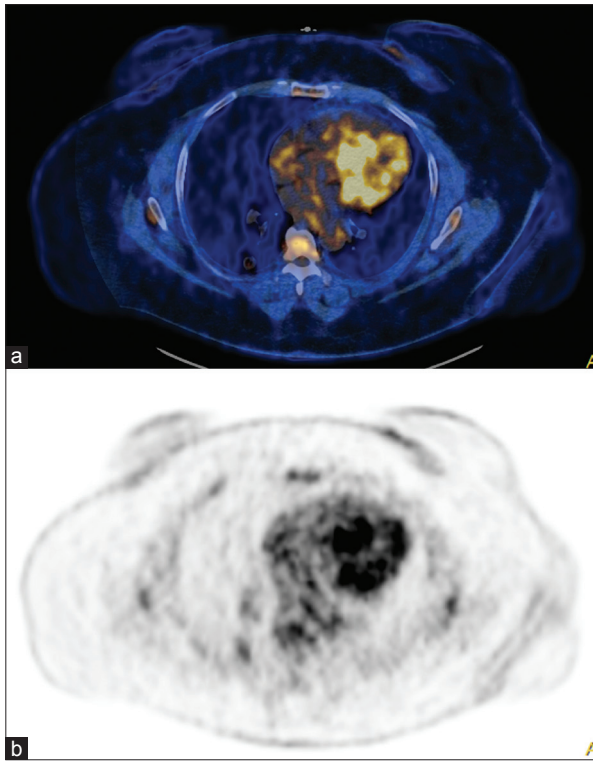


Figure 2: (a) This ^{18}F Fluoro-2-deoxy-D-glucose positron emission tomography/computed tomography scan identifies a circumscribed, mildly active pulmonary lesion in the right lower lobe. (b) ^{18}F Fluoro-2-deoxy-D-glucose positron emission tomography/computed tomography image demonstrating a standard uptake value of 3

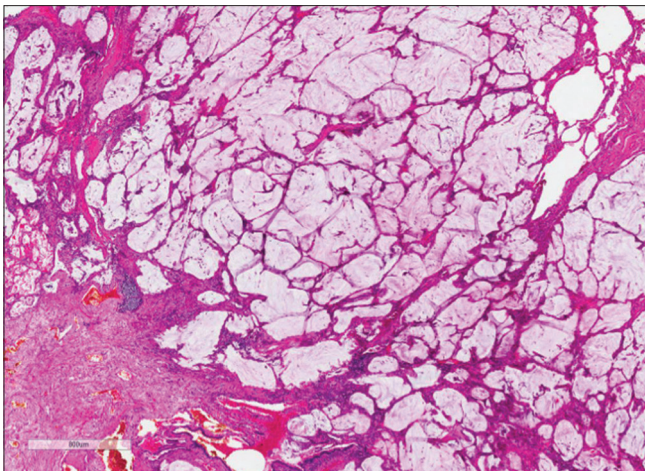


Figure 4: Features of cystic tumor filled with grayish gelatinous mucin

present as ground glass opacities. They can be ill-defined, low-attenuating, cavitary nodules with wall and septal enhancement on CT.^[6,7] Often, calcifications are identified in the septae; however, cases can present with no septal enhancement.^[7] While cystic neoplasms of the lung carry wide differential diagnoses, mucus production can narrow this list.

The enhancement of mucus depends on its protein content. Mucus with a protein level >9000 mg/dL carries

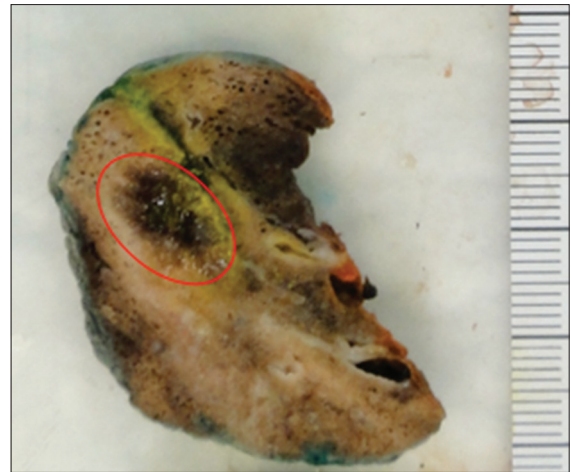

Figure 3: Gross features: Well-defined, soft, gelatinous tumor mass without hemorrhage or necrosis

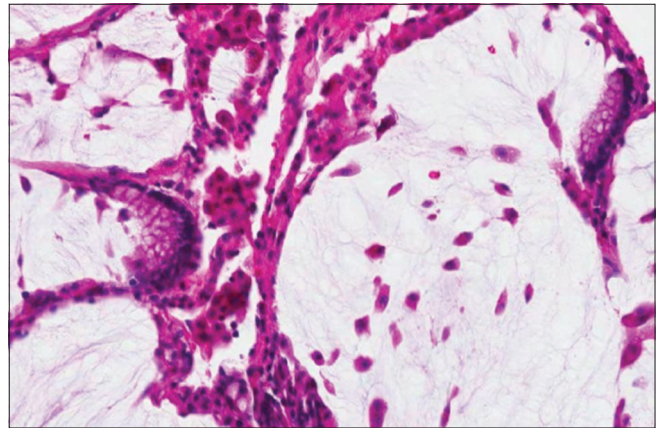


Figure 5: Alveolar walls focally lined by mucinous epithelium

high-signal intensity on T1-weighted gadolinium-enhanced magnetic resonance (MR) imaging, causing a reduction in T1 relaxation time.^[6] On T2-weighted MR imaging, colloid adenocarcinoma demonstrates marked hyperintensity. While mucinous adenocarcinoma can mimic pulmonary mucinous cystadenocarcinoma, it generally does not present with mucoceles or bronchoceles, which can therefore distinguish the two.^[7]

Interestingly, ^{18}F Fluoro-2-deoxy-D-glucose (FDG) uptake varies greatly in colloid adenocarcinoma and does not directly correlate with the aggressiveness of the tumor. Since there is a negative correlation between FDG uptake and mucin production, it is quite likely that a mucinous adenocarcinoma will show little FDG uptake, unlike most other tumors that demonstrate increased glucose uptake due to increased cellularity.^[6] However, FDG uptake has been suggested to correlate the thickness of lung septae, which is most likely the cancer foci, thus showing some application.^[7] One study found that among 11 patients with mucin-producing nonsmall cell lung cancer, only 2 lesions demonstrated positive PET results for SUV of 3.5. In the 9 other lesions not detected, the mean SUV was determined

to be 2.0.^[8] The researchers found no significant correlation between tumor size or stage and SUV, thus limiting its use in detecting mucinous adenocarcinoma.^[8] Another study determined that only 13 of 22 patients with mucinous neoplasm could be correctly identified by FDG PET/CT imaging. Therefore, FDG PET/CT has proven insensitive in the diagnosis of mucinous adenocarcinoma, especially in cases of hypocellular lesions with abundant mucin production. Caution should be used when using PET/CT to evaluate for potential malignancy.^[9]

Pathology discussion

Mucinous or colloid adenocarcinoma is an extremely rare subtype of lung adenocarcinoma and is characterized by pools of mucin-containing spaces with scant epithelium.^[10,11] Previously, these have been designated under various terms, including mucinous cystadenoma, mucinous cystic tumor, multilocular cystic adenocarcinoma, and mucinous cystic tumor of borderline malignancy; however, in the most recent International Association for the Study of Lung Cancer/American Thoracic Society/European Respiratory Society classification, this terminology was discontinued and these tumors were included under the category of colloid adenocarcinoma.^[2] Grossly, these tumors are well-circumscribed, intrapulmonary, lobulated and soft, with a central cavity filled with translucent mucus, ranging in size from 1 to >10 cm.^[10,12] The presence of gelatinous, mucinous material is noted in the gross description of nearly all cases; however, a well-defined cyst wall is not usually seen.^[10,12]

Histologically, abundant mucin is noted, destroying alveolar walls and dissecting through lung parenchyma.^[12] Focally preserved walls are lined by neoplastic epithelium in a single layer of tall, cuboidal to columnar, mucin-secreting cells, and admixed goblet cells.^[11-13] The neoplastic mucinous cells show basally located small nuclei with inconspicuous nucleoli, lack of mitosis, and apically situated mucin as in our case; however, they have been noted with nuclear stratification, papillary epithelial projections, tufting, mild to moderate atypia, and occasional mitosis.^[12] Tumors histologically consistent with colloid adenocarcinoma are difficult to distinguish from metastatic tumors with similar morphology.

Differential diagnoses for colloid adenocarcinoma include metastatic mucinous adenocarcinoma of extrathoracic origin and mucinous variant of adenocarcinoma *in situ*. Immunohistochemical evaluation of these lesions becomes vital in cases where an extrathoracic source is suspected. Specifically, the vast majority of lung colloid adenocarcinomas are goblet cell type and consistently express cytokeratin-7 (CK-7) and are negative for thyroid transcription factor-1 (TTF-1) and napsin-A.^[1,10,14] The less frequent signet ring cell-type colloid adenocarcinoma is immunoreactive for TTF1.^[1] While heterogeneous staining for caudal-related homeobox 2 (CDX2), CK-20, and MUC-2 have been reported in the goblet cell-type colloid adenocarcinoma, CDX2 has been shown to be more specific

and sensitive for metastatic colon adenocarcinoma.^[14,15] The mucinous variant of adenocarcinoma *in situ* is thought to arise from respiratory goblet cells and shows similar histology to lung colloid adenocarcinoma and is generally positive for CK-20 and negative for CDX2.^[15] Other extrathoracic sources of colloid adenocarcinoma include breast and gynecologic origins and can be further worked up with estrogen receptor and Wilms tumor-1 gene and PAX-8, respectively.^[14]

CONCLUSION

Closely following identification of the mildly spiculated right lower lobe pulmonary nodule by CT scan, our patient underwent a right video-assisted thoracoscopic surgery lower lobe wedge resection with mediastinal lymph node dissection. PET/CT imaging proved negative for distant metastasis or adenopathy. The final pathology demonstrated colloid adenocarcinoma and all lymph nodes dissected were negative for metastasis. The tumor (pT1aN0M0 stage IA) was fully resected with negative margins, and no chemotherapy or radiation treatments were indicated at that time. Follow-up surveillance scans were recommended.

Declaration of patient consent

The authors certify that they have obtained all appropriate patient consent forms. In the form the patient(s) has/have given his/her/their consent for his/her/their images and other clinical information to be reported in the journal. The patients understand that their names and initials will not be published and due efforts will be made to conceal their identity, but anonymity cannot be guaranteed.

Financial support and sponsorship

The study was supported by the Medical College of Georgia, Augusta, GA, USA.

Conflicts of interest

There are no conflicts of interest.

REFERENCES

- Noel A. Brownlee, Ryan T. Mott, Annabelle Mahar, and Victor L. Roggli (2005) Mucinous (Colloid) Adenocarcinoma of the Lung. Archives of Pathology and Laboratory Medicine: January 2005;129:pp. 121-122.
- Travis WD, Brambilla E, Nicholson AG, Yatabe Y, Austin JH, Beasley MB, *et al.* The 2015 World Health Organization classification of lung tumors: Impact of genetic, clinical and radiologic advances since the 2004 classification. J Thorac Oncol 2015;10:1243-60.
- Moran CA, Hochholzer L, Fishback N, Travis WD, Koss MN. Mucinous (so-called colloid) carcinomas of lung. Mod Pathol 1992;5:634-8.
- Rossi G, Murer B, Cavazza A, Losi L, Natali P, Marchioni A, *et al.* Primary mucinous (so-called colloid) carcinomas of the lung: A clinicopathologic and immunohistochemical study with special reference to CDX-2 homeobox gene and MUC2 expression. Am J Surg Pathol 2004;28:442-52.
- Moon, Sung Min, *et al.* "Pulmonary Invasive Mucinous Adenocarcinoma in an Asymptomatic 23-Year-Old Male: Presentation with a Large Cavitary Mass." Journal of the Korean Society of Radiology 69.5 (2013): 361-364.
- Efstathiou A, Asteriou C, Barbetakis N, Miliaras D, Kleontas A, Karvelas C,

- et al.* Primary pulmonary mucinous cystadenocarcinoma: A case report. *Case Rep Med* 2011;2011:562026.
7. Choi YA, Lee HY, Han J, Choi JY, Kim J, Kwon OJ, *et al.* Pulmonary mucinous cystadenocarcinoma: Report a case and review of CT findings. *Korean J Radiol* 2013;14:384-8.
 8. Shim SS, Han J. FDG-PET/CT imaging in assessing mucin-producing non-small cell lung cancer with pathologic correlation. *Ann Nucl Med* 2010;24:357-62.
 9. Berger KL, Nicholson SA, Dehdashti F, Siegel BA. FDG PET evaluation of mucinous neoplasms: Correlation of FDG uptake with histopathologic features. *AJR Am J Roentgenol* 2000;174:1005-8.
 10. Zenali MJ, Weissferdt A, Solis LM, Ali S, Tang X, Mehran RJ, *et al.* An update on clinicopathological, immunohistochemical, and molecular profiles of colloid carcinoma of the lung. *Hum Pathol* 2015;46:836-42.
 11. Masai K, Sakurai H, Suzuki S, Asakura K, Nakagawa K, Watanabe S, *et al.* Clinicopathological features of colloid adenocarcinoma of the lung: A report of six cases. *J Surg Oncol* 2016;114:211-5.
 12. Gao ZH, Urbanski SJ. The spectrum of pulmonary mucinous cystic neoplasia: A clinicopathologic and immunohistochemical study of ten cases and review of literature. *Am J Clin Pathol* 2005;124:62-70.
 13. Bacha D, Ayadi-Kaddour A, Smati B, Kilani T, El Mezni F. A pulmonary mucinous cystic tumour of borderline malignancy. *Pathologica* 2008;100:189-91.
 14. Chu PG, Chung L, Weiss LM, Lau SK. Determining the site of origin of mucinous adenocarcinoma: An immunohistochemical study of 175 cases. *Am J Surg Pathol* 2011;35:1830-6.
 15. Saad RS, Cho P, Silverman JF, Liu Y. Usefulness of cdx2 in separating mucinous bronchioloalveolar adenocarcinoma of the lung from metastatic mucinous colorectal adenocarcinoma. *Am J Clin Pathol* 2004;122:421-7.