

Retrospective analysis of cases of intestinal invagination treated and followed-up at our clinic

Bora Barut,¹ Huseyin Yonder,² Kemal Baris Sarici,¹ Fatih Ozdemir,¹ Volkan Ince¹

¹Department of General Surgery, Inonu University Faculty of Medicine, Malatya, Turkey

²Department of General Surgery, Derik State Hospital, Mardin, Turkey

ABSTRACT

OBJECTIVE: The purpose of this study was to present data on the diagnosis, treatment, clinical course, and outcome of cases of intestinal invagination.

METHODS: Data of 11 patients treated for intestinal invagination at one center between June 2009 and July 2015 were analyzed retrospectively in terms of demographic data, etiological factors, anatomical localization of invagination, admission complaints, physical examination findings, diagnostic imaging modalities used, postoperative complications, and hospital stay.

RESULTS: Of the total, 9 (81.8%) patients were female and 2 (18.2%) were male. Nine (81.8%) cases occurred due to benign causes and 2 to malignant causes. One (9%) patient had jejunojejunal invagination, 5 (45.5%) had ileoileal invagination, and 5 (45.5%) had ileocecal invagination. Right hemicolectomy-ileotransversostomy was performed in 5 (45.5%) patients and segmental small bowel resection with end-to-end anastomosis in 6 (54.5%).

CONCLUSION: Intestinal invagination is a rare cause of acute abdomen in adults that may have a variety of etiologies and therefore may present with different clinical pictures. Abdominal pain, nausea, and vomiting are the most common symptoms. The rate of accurate diagnosis is 30% to 35% using ultrasonography and 50% to 80% using computerized tomography. In adults, the preferred treatment is surgery. As malignant pathologies are responsible for some cases of invagination, oncological principles should be strictly observed in surgical treatment. Though a rare cause of acute abdomen and/or ileus in adults, invagination is a clinical condition that must be kept in mind in the differential diagnosis.

Keywords: Acute abdomen; cecum; ileum; invagination; jejunum.

Intestinal invagination occurs when one part of the intestine folds into the proximal segment [1]. It is a relatively frequently seen clinical condition during childhood; however, it constitutes only 1% of all in-

testinal obstructions seen in adults. Ninety percent of the cases in children are idiopathic, while 90% of adult cases are related to an organic lesion caused by benign or malignant tumors [2]. Abdominal pain, nausea,



Received: March 19, 2017 Accepted: May 18, 2017 Online: August 26, 2017

Correspondence: Dr. Bora BARUT. Turgut Ozal Tip Merkezi, Genel Cerrahi Klinigi, 78712 Malatya, Turkey.

Tel: +90 422 - 341 06 60 e-mail: borabarut@mynet.com

© Copyright 2017 by Istanbul Northern Anatolian Association of Public Hospitals - Available online at www.kuzeyklinikleri.com

TABLE 1. Distribution of invagination etiology

Etiology	Subgroup	n	%
Malignant			18.2
	Mucinous adenocarcinoma	1	
	Gastrointestinal stromal tumor	1	
Benign			81.8
	Lipoma	5	
	Polyp	3	
	Hemangioma	1	

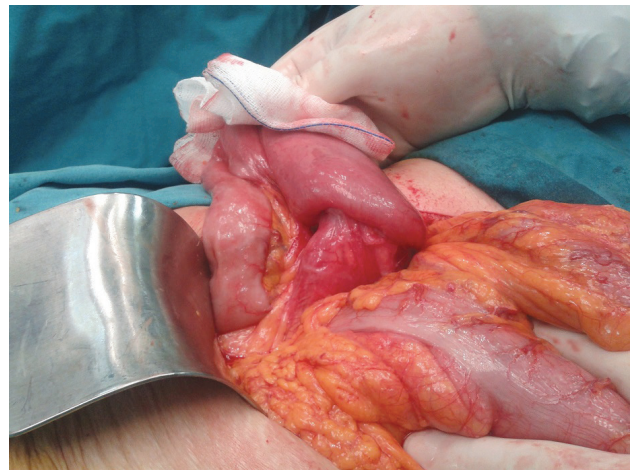
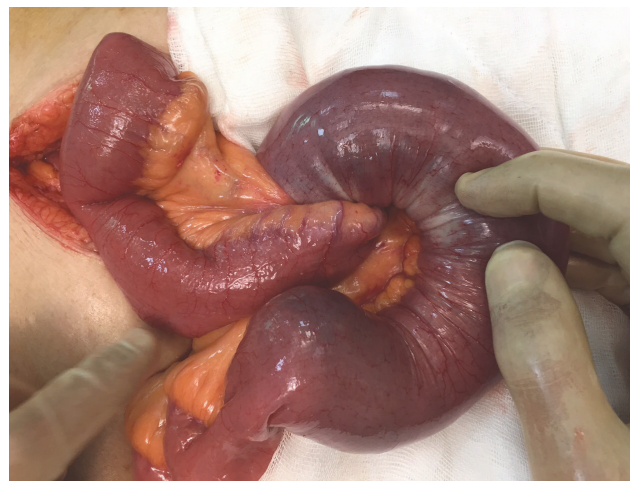and vomiting are the most frequently seen symptoms [3]. The rate of accurate diagnosis of invagination using ultrasonography (US) and computed tomography (CT) ranges between 30% to 35% and 50% to 80%, respectively. The preferred treatment for invagination in the adult age group is surgery [4].

MATERIALS AND METHODS

Demographic data, etiological factors, anatomical location of the invagination, admission complaints, findings of preoperative physical examination, diagnostic imaging modalities used, surgery performed, postoperative complications, and the length of hospital stay of 11 patients treated at one center between June 2009 and July 2015 with the indication of intestinal invagination were retrospectively examined.

RESULTS

The study population consisted of 9 (81.8%) female and 2 (18.2%) male patients with a mean age of 57 years (range: 27–84 years). All of the patients were over 18 years of age. Intestinal invagination developed due to benign (n=9; 81.8%) and malignant (n=2; 18.2%) etiologies. Data regarding the etiology of invagination are summarized in Table 1. Jejunojejunal (n=1; 9%), ileoileal (n=5; 45.5%), and ileocecal (n=5; 45.5%) invaginations were detected in the study patients (Figures 1, 2). The patients were operated on as an emergency (n=9; 81.8%) and on elective (n=2; 18.2%) basis. In 8 (81.8%) of 9 patients who underwent emergency surgery, admis-

**FIGURE 1.** Intraoperative appearance of ileocecal invagination.**FIGURE 2.** Intraoperative appearance of ileoileal invagination.

sion complaints included abdominal pain, nausea, vomiting, and inability to defecate or pass gas, and in remaining patient (10.2%) lower gastrointestinal (GIS) system bleeding was detected. In the 2 patients who were operated on under elective conditions, the primary complaints were abdominal pain, lassitude, and anemia. Diagnosis was established in the 1 (1.9%) patient with lower GIS bleeding using angiography, while 6 (60%) of the remaining 10 patients were diagnosed on the basis of US and/or CT findings (Figure 3). All patients underwent surgery: right hemicolectomy-ileotransversostomy (n=5; 45.5%) or segmental resection of small bowel

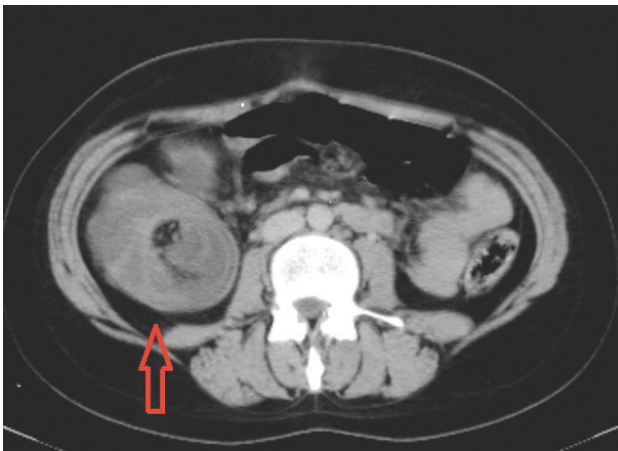


FIGURE 3. Preoperative computed tomography image of a patient with invaginated bowel segment (arrow).

with end-to-end anastomosis (n=6; 54.5 %). Post-operatively, pneumonia (n=1; 9%), wound infection (n=1; 9%), and abdominal evisceration (n=1; 9%) developed. All patients were discharged with full recovery. Mean hospital stay was 8 days. Data of the cases are summarized in Table 2.

DISCUSSION

Intestinal invagination in adults is a clinical condition rarely encountered by surgeons. Although the pathogenetic mechanisms of invagination are not precisely known, an intraluminal lesion or an irritating factor is believed to alter normal peristaltic movements, leading to the initiation of invagination [5]. In adults,

TABLE 2. Data of the cases

Case	Age (years)/gender	Location of the lesion	Preoperative imaging	Type of surgery	Emergency/elective	Pathology	Postoperative complication	Length of hospitalization (days)
1	66/F	Ileoileal	US: Diagnosis (+)	Segmental small bowel resection	Emergency	Mucinous adenocarcinoma	None	7
2	67/F	Ileoileal	CT: Diagnosis (+)	Segmental small bowel resection	Emergency	Lipoma	None	9
3	21/F	Ileocecal	US: Diagnosis (+)	Right hemicolectomy	Emergency	Lipoma	None	5
4	84/F	Ileoileal	CT: Diagnosis (+)	Segmental small bowel resection	Emergency	Inflammatory fibroid polyp	Pneumonia	11
5	60/F	Ileoileal	USG: Normal	Segmental small bowel resection	Emergency	Lipoma	None	7
6	70/M	Ileocecal	CT: Diagnosis (+)	Right hemicolectomy	Elective	Capillary hemangioma	None	8
7	56/F	Ileocecal	US: Normal	Right hemicolectomy	Elective laparoscopic	Polyp	None	5
8	49/M	Ileocecal	CT: Normal	Right hemicolectomy	Emergency	Lipoma	Abdominal evisceration	9
9	74/F	Ileocecal	US: Normal	Right hemicolectomy	Emergency	Lipoma	Wound infection	11
10	27/F	Ileoileal	CT: Diagnosis (+)	Segmental small bowel resection	Emergency	Peutz-Jeghers polyp	None	5
11	54/F	Jejunojejunal	Angiography: Diagnosis (+)	Segmental small bowel resection	Emergency	GIST	None	10

CT: Computed tomography; GIST: Gastrointestinal stromal tumor; F: Female; M: Male; US: Ultrasonography.

90% of invaginations manifest as a result of an organic lesion caused by benign or malignant tumors. Leiomyoma, adenoma, lipoma, Brunner cell hamartoma, hemangioma, adenomyoma, neurofibroma, desmoid tumor, and Meckel's diverticulum are among the benign lesions that can cause invagination. Lymphoma, adenocarcinoma of the small bowel or colon, and metastatic malignant tumor are among the malignant lesions that most frequently cause invagination [6]. In all of our cases, an organic etiology was present, and consistent with the literature, we found malignant tumor in 2 (18.2%) and benign tumor in 9 (81.8%) patients. Invagination is classified as enteroenteric, colocolic, ileocolic, or ileocecal, according to anatomical location [7]. In enteroenteric and colocolic invagination, the affected small bowel and colonic segments telescope into another segment, while in ileocolic invagination, the terminal ileum passes through the ileocecal valve and infolds into the ascending colon. In ileocecal invagination, a segment of the terminal ileum is retained at the level of the ileocecal valve. However, it may be difficult to differentiate between ileocecal and ileocolic invagination intraoperatively. [8]. Abdominal pain, nausea, vomiting, rectal bleeding, alterations in bowel habits, and constipation are the most frequently seen complaints. The imaging modalities most frequently used in the diagnosis of invagination include plain or contrast-enhanced radiograph, abdominal US, and CT. The rate of accurate diagnosis ranges between 30% and 35% for US, while it rises to 50% to 80% when CT is used. [9]. In 10 of 11 patients in this study, US and/or CT were/ was used for preoperative imaging, and in 6 (60%) patients accurate diagnosis was made using radiological imaging modalities. A non-operative reduction procedure is a frequently applied treatment for invagination in children; however, since in most adult cases there is an underlying organic lesion with malignant potential, surgical resection is the primary method of treatment. During the process of reduction, because there is the possibility of seeding tumor cells in other foci and risk of procedural perforation, resection of the affected bowel segment should be conducted in compliance with oncological procedures [10, 11].

In conclusion, intestinal invagination is a rarely seen disease in adults that may manifest due to nu-

merous etiological factors and may display a diverse clinical picture. It can present with manifestations of acute abdomen and/or ileus. In patients who present at emergency service with manifestations of acute abdomen and/or ileus, invagination must be considered in the differential diagnosis. Surgery is the preferred treatment for invagination in adults. Considering that the organic lesion responsible may be a malignant entity, oncological principles should be observed during resection.

Conflict of Interest: None declared.

Financial Disclosure: The authors declared that this study has received no financial support.

Authorship contributions: Concept – B.B, F.O; Desing – H.Y; Supervision – K.B.S; Materials and data collection – B.B, H.Y; Analysis – V.I; Writing – B.B; Literature search – B.B, H.Y; Critical review – K.B.S, V.I.

REFERENCES

1. Chandra N, Campbell S, Gibson M, Reece-Smith H, Mee A. Intussusception caused by a heterotopic pancreas. Case report and literature review. *JOP* 2004;5:476–9.
2. Patrizi G, Di Rocco G, Giannotti D, Casella G, Casella Mariolo JR, Bernieri MG, et al. Double ileo-ceco-colic invagination due to right colon carcinoma: clinical presentation and management. *Eur Rev Med Pharmacol Sci* 2013;17:2267–9.
3. Gonzalez-Hernandez J, Garcia F. Cecal adenocarcinoma presenting as colonic intussusception in adulthood. *Proc (Bayl Univ Med Cent)* 2015;28:180–2.
4. Korkmaz Ö, Yılmaz HG, Taçyıldız İ, Baç B, Çevik S. Erişkinlerde Görülen İnvaginasyon Olgularının Değerlendirilmesi. *Dicle Tıp Dergisi* 2007;34:182–6.
5. Yakan S, Caliskan C, Makay O, Denecli AG, Korkut MA. Intussusception in adults: clinical characteristics, diagnosis and operative strategies. *World J Gastroenterol* 2009;15:1985–9.
6. Toso C, Erne M, Lenzlinger PM, Schmid JF, Büchel H, Melcher G, et al. Intussusception as a cause of bowel obstruction in adults. *Swiss Med Wkly* 2005;135:87–90.
7. Lu T, Chng YM. Adult intussusception. *Perm J* 2015;19:79–81.
8. Azar T, Berger DL. Adult intussusception. *Ann Surg* 1997;226:134–8.
9. Kaya F, Kızıltan R, Şit M, Yılmaz EE. İleoçekal İnvaginasyona Neden Olan İntestinal Non-Hodgkin Lenfoma: Olgu Sunumu. *Abant Tıp Dergisi* 2012;1:162–4.
10. Kannan U, Rahnama-Azar AA, Patel AN, Gaduputi V, Shah AK. Jejunal Intussusception: A Rare Presentation of Carcinoid Tumor. *Case Rep Surg* 2015;2015:260697.
11. Barussaud M, Regenet N, Briennon X, de Kerviler B, Pessaix P, Kohneh-Sharhi N, et al. Clinical spectrum and surgical approach of adult intussusceptions: a multicentric study. *Int J Colorectal Dis* 2006;21:834–9.