

# Ileal perforation caused by a fish bone shortly after drug-eluting stent implantation for acute myocardial infarction

Journal of International Medical Research

2019, Vol. 47(6) 2709–2715

© The Author(s) 2019

Article reuse guidelines:

[sagepub.com/journals-permissions](http://sagepub.com/journals-permissions)

DOI: 10.1177/0300060519842778

[journals.sagepub.com/home/imr](http://journals.sagepub.com/home/imr)

Sheng-Gang Zhao<sup>1</sup> , Jian-Jiang Xu<sup>1</sup>, Li Xu<sup>2</sup>,  
Ji-Feng Zheng<sup>1</sup>, Zhong-Cheng Zhou<sup>3</sup> and  
Li-Qin Jiang<sup>1</sup>

## Abstract

During the past century, the incidence of myocardial infarction has markedly increased worldwide. Percutaneous coronary intervention with stent implantation is often considered as the first-choice treatment, especially in emergency cases. Current guidelines recommend delayed elective noncardiac surgery for such vulnerable patients. However, few suggestions are available regarding the exact treatment strategy for patients who have already undergone percutaneous coronary intervention but suddenly need emergent noncardiac surgery for an unrelated reason. We herein present a case involving a patient with acute myocardial infarction who had undergone implantation of a drug-eluting stent and developed an ileal perforation due to fish bone ingestion 3 days postoperatively. After carefully balancing the risks of stent thrombosis and uncontrollable bleeding, dual antiplatelet therapy and low-molecular-weight heparin were given with close monitoring. Emergency laparotomy and partial small bowel resection surgery were then performed, after which the patient eventually recovered. This case indicates a possible management strategy for patients with acute myocardial infarction complicated by emergency noncardiac surgery.

<sup>1</sup>Department of Cardiology, The Second Affiliated Hospital of Jiaxing University, Jiaxing, Zhejiang Province, China

<sup>2</sup>Department of Radiology, The Second Affiliated Hospital of Jiaxing University, Jiaxing, Zhejiang Province, China

<sup>3</sup>Department of General Surgery, The Second Affiliated Hospital of Jiaxing University, Jiaxing, Zhejiang Province, China

## Corresponding author:

Liqin Jiang, Professor of Cardiology, Department of Cardiology, The Second Affiliated Hospital of Jiaxing University, Huancheng North Road No. 1518, Jiaxing, Zhejiang Province 314000, China.  
Email: 13905737392@163.com



**Keywords**

Acute myocardial infarction, intestinal perforation, drug-eluting stent, emergency noncardiac surgery, complication, case report

Date received: 24 November 2018; accepted: 18 March 2019

**Introduction**

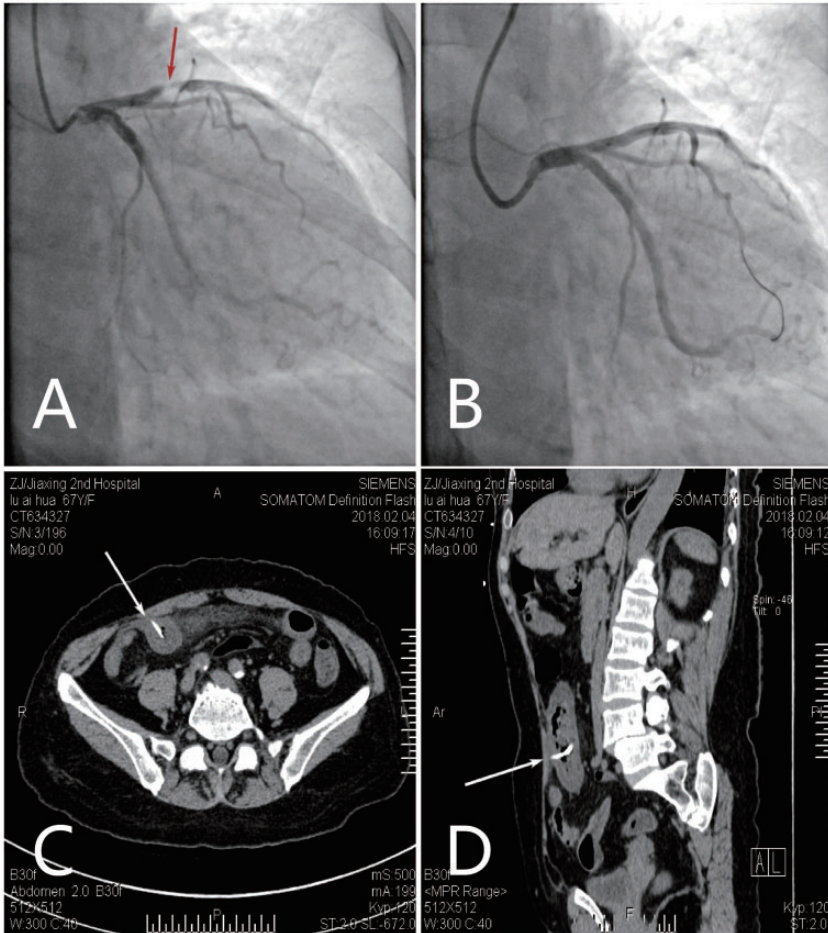
During the past century, the incidence of myocardial infarction has drastically increased worldwide. Percutaneous coronary intervention (PCI) with a stent is currently the most widely performed procedure for treatment of this condition.<sup>1–3</sup> Guidelines recommend that elective noncardiac surgery should be delayed in such patients. However, little data are available regarding the optimal treatment strategy for patients with acute myocardial infarction who have already undergone PCI and then suddenly need emergency noncardiac surgery for an unrelated reason. We herein present a case involving a patient who had undergone implantation of a drug-eluting stent (DES) for acute myocardial infarction and then developed ileal perforation due to fish bone ingestion only 3 days later. Considering the risk of stent thrombosis, we administered dual antiplatelet therapy and low-molecular-weight heparin. The patient then underwent emergency laparotomy and partial small bowel resection and eventually recovered. This case indicates that continuous dual antiplatelet and anticoagulant therapy in the perioperative period and recontinuation of dual antiplatelet therapy soon after surgery might be an effective management strategy.

**Case report**

The patient provided consent for publication of this report and any accompanying images. The case report was approved by the Ethics Committee of the Second

Affiliated Hospital of Jiaxing University. On 20 January 2018, a 68-year-old woman was admitted to our emergency department. She had a 1-month history of refractory chest pain that had become aggravated during the past 7 days. Physical examination revealed no abnormalities. Laboratory test results showed an increased troponin I concentration of 0.38 ng/mL (reference range, 0.0–0.1 ng/mL) and a slightly elevated creatinine concentration of 152  $\mu$ mol/L (reference range, 54–124  $\mu$ mol/L). She had a normal white blood cell count ( $7.35 \times 10^9$  cells/L; reference range,  $3.5$ – $9.5 \times 10^9$  cells/L) and C-reactive protein concentration ( $<0.5$  mg/L; reference range, 0.0–8.0 mg/L). On the basis of these results, she was diagnosed with non-ST elevation myocardial infarction. The patient was treated with aspirin (100 mg/day), clopidogrel (75 mg/day), atorvastatin (20 mg/day), and low-molecular-weight heparin (4000 IU every 12 hours). She refused to undergo coronary angiography.

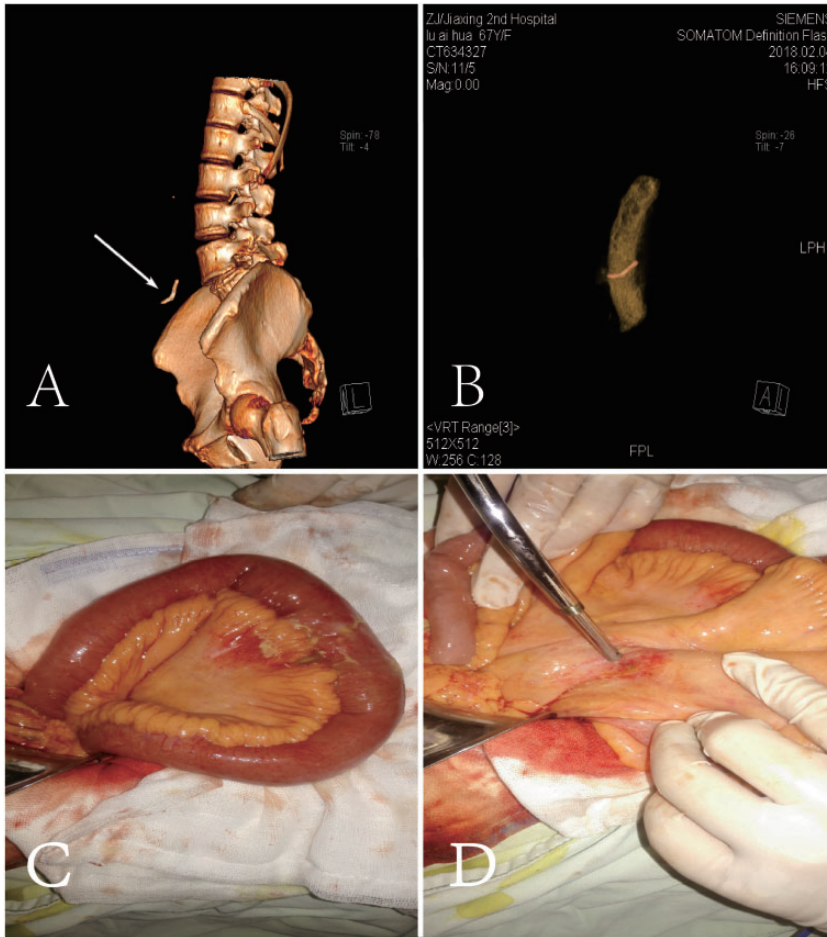
Two days later, on 22 January 2018, her body temperature began to fluctuate from 37.0°C to 39.0°C. She had no cough, congestion, abdominal pain, diarrhea, or symptoms of urinary tract infection. Again, a physical examination revealed no abnormalities. We therefore considered that the patient may have absorption fever caused by myocardial infarction-induced necrotic substances. The fever disappeared until 29 January 2018, at which time the patient agreed to undergo coronary angiography. Coronary angiography was performed on 1 February 2018 and showed 99% stenosis in the left anterior descending



**Figure 1.** Coronary angiography and abdominal computed tomography images. (a) Coronary angiography revealed 99% stenosis (red arrow) in the left anterior descending artery. (b) The stenosis led to stent implantation. (c, d) Abdominal computed tomography showed a radiopaque linear sharp foreign body 30 mm in diameter with the appearance of a fish bone penetrating the bowel wall (white arrow). The surrounding bowel wall was thickened.

artery; all other arteries were normal (Figure 1(a)). Therefore, a 3.5- × 18-mm DES (Endeavor Resolute; Medtronic, Minneapolis, MN, USA) (Figure 1(b)) was implanted. On 4 February 2018, the patient reported acute abdominal pain in the lower right quadrant, chills, and fever. Abdominal examination revealed tenderness in the lower right quadrant without rebound tenderness. Abdominal computed tomography showed that a foreign body

had penetrated the ileal wall, resulting in effusion and focal thickening in the affected area (Figure 1(c), (d)). Three-dimensional computed tomography confirmed this finding (Figure 2(a), (b)). The patient was diagnosed with acute ileal perforation. Considering the potential risk of stent thrombosis, dual antiplatelet therapy and low-molecular-weight heparin were given (aspirin at 100 mg/day plus clopidogrel at 75 mg/day, and low-molecular-weight



**Figure 2.** Three-dimensional reconstruction of the computed tomography images and intraoperative findings. (a, b) Three-dimensional reconstruction of the computed tomography images indicates a foreign body in the abdomen, piercing both sides of the intestinal wall. (c, d) Intraoperative findings showed a fish bone in the ileum that had penetrated the wall at a site approximately 90 cm distal to the ileocecal valve. Local intestinal fluid leakage, pus, and thickening of the surrounding intestinal wall were seen.

heparin at 4000 IU every 12 hours). Furthermore, double antibiotics were given for infection control (piperacillin/tazobactam at 3.375 g every 8 hours). Proton pump inhibitors (omeprazole at 40 mg/day) and somatostatin (3 mg every 12 hours) were also given to inhibit digestive fluid secretion and gastrointestinal decompression, respectively, for 12 hours.

Twelve hours later, the patient's abdominal pain in the lower right quadrant

became aggravated with rebound tenderness along with increased local muscle tone and active bowel sounds. Emergency laparotomy was performed, and a fish bone was found to have penetrated the ileal wall approximately 90 cm distal to the ileocecal valve (Figure 2(c), (d)). Local intestinal fluid leakage, pus accumulation, and thickening of the surrounding intestinal wall were found. Additionally, approximately 50 mL of leaked fluid was detected in both

the abdominal and pelvic cavities. Therefore, partial small bowel resection was performed. One day after surgery, clopidogrel (75 mg/day), aspirin (100 mg/day), and atorvastatin (20 mg/day) were administered until discharge. The patient's condition was normal during follow-up.

## Discussion

The incidence of myocardial infarction has drastically increased during the past century. PCI with stent implantation is currently the most widely performed procedure for treatment of this condition.<sup>3</sup> Dual antiplatelet therapy can reduce the risk of stent thrombosis, but it may increase the risk of bleeding.<sup>4,5</sup> However, the association between dual antiplatelet therapy and the risk of bleeding has not been adequately addressed because of lack of sufficient statistically sound data; most of the currently available data were derived from observational studies. Only one double-blind randomized controlled trial of the perioperative risk of bleeding in patients on aspirin therapy undergoing noncardiac surgery has been performed, and the results did not show a significantly higher incidence of bleeding events in patients taking aspirin than in those who were not on antiplatelet therapy.<sup>6</sup> Thus, current data suggest that the perioperative bleeding risk is related to the surgical procedure rather than to the patient's hemorrhagic profile. Guidelines recommend that aspirin should be continued perioperatively for most surgical operations and that dual antiplatelet therapy should not be withdrawn for surgery that has a low bleeding risk. In patients with a high risk of both bleeding and stent thrombosis, bridging therapy with cangrelor or short-half-life intravenous inhibitors of platelet glycoprotein IIb/IIIa receptors (tirofiban or eptifibatid) in the perioperative phase may be reasonable.<sup>6</sup>

Within 6 months after PCI with DES implantation, our patient had a high

thrombotic risk. Although gastric resection and intestinal resection have a low hemorrhagic risk, our patient underwent an urgent surgery. Some studies have shown that using clopidogrel significantly increases the post-intervention bleeding risk after abdominal surgery but that it does not increase the hemorrhage-associated mortality rate or reintervention rate.<sup>6</sup> This result is also consistent with a study of patients with femoral fracture.<sup>6</sup>

Many patients undergoing surgical procedures are in a hypercoagulable state and have inflammation and stress responses, blood loss, and hemodynamic derangements.<sup>7</sup> All of these factors can contribute to an increased thrombotic risk. Thus, multidisciplinary discussions among cardiologists, anesthesiologists, hematologists, and surgeons generally result in continuation of dual antiplatelet therapy.

The American College of Cardiology/American Heart Association (ACC/AHA) guidelines recommend that elective noncardiac surgery should be delayed for 30 days after implantation of a bare metal stent and for up to 1 year after implantation of a DES (level I). If surgery is absolutely essential, the risk of surgery and the risk of discontinuation of antiplatelet therapy must be weighed (level IIa).<sup>1</sup> However, little data regarding the management of antiplatelet therapy in the perioperative phase are available for patients undergoing semi-elective or urgent surgical procedures.

The second-generation DESs have overcome most of the limitations of the first-generation DESs through improvements in the stent design (thinner struts, more biocompatible polymers, and antiproliferative drugs with more stable and largely predictable release kinetics). These improvements may enhance endothelial coverage and functional recovery, giving second-generation DESs the advantages of a safer profile and lower thrombotic risk. As a result, both the European Society of

Cardiology (ESC) and ACC/AHA guidelines recommend that the duration of dual antiplatelet therapy should be reduced to 6 months for patients with stable coronary atherosclerotic disease after implantation of a second-generation DES when necessary.<sup>6</sup> The latest ESC guidelines suggest that P2Y12 inhibitors could be discontinued earlier (3–6 months) after DES implantation in patients with non-ST-segment elevation acute coronary syndromes who have a high bleeding risk.<sup>8</sup> Saia et al.<sup>9</sup> and Cortese and Danzi<sup>10</sup> concluded that new-generation DESs showed safety similar to that of bare metal stents at any timing of surgery and appeared to be safer when surgery was performed from 0 to 6 months after DES implantation.

## Conclusion

Effective management of patients with acute myocardial infarction complicated by the need for emergency noncardiac surgery is a great challenge for physicians. Carefully continuing dual antiplatelet and anticoagulant therapy in the perioperative period of emergency noncardiac operations in patients with a low bleeding risk and restarting the dual antiplatelet therapy soon after surgery might be beneficial for the recovery of these patients.

## Declaration of conflicting interest

The authors declare that there is no conflict of interest.

## Funding

This work was funded by ZheJiang Provincial Natural Science Foundation of China (LQ19H020003), the Science Technology Department of JiaXing (2016AY23056), and the ZheJiang Provincial Medical Health Science and Technology Program Foundation (2019327710).

## ORCID iD

Sheng-Gang Zhao  <http://orcid.org/0000-0001-6716-2408>

## References

1. Grines CL, Bonow RO, Casey DE Jr, et al. Prevention of premature discontinuation of dual antiplatelet therapy in patients with coronary artery stents: a science advisory from the American Heart Association, American College of Cardiology, Society for Cardiovascular Angiography and Interventions, American College of Surgeons, and American Dental Association, with representation from the American College of Physicians. *Circulation* 2007; 115: 813–818. DOI: 10.1161/CIRCULATIONAHA.106.180944.
2. Fleisher LA, Fleischmann KE, Auerbach AD, et al. 2014 ACC/AHA guideline on perioperative cardiovascular evaluation and management of patients undergoing noncardiac surgery a report of the American College of Cardiology/American Heart Association task force on practice guidelines. *Circulation* 2014; 130: e278–e333. DOI: 10.1161/CIR.0000000000000106.
3. Bhatt DL. Percutaneous coronary intervention in 2018. *JAMA* 2018; 319: 2127–2128. DOI: 10.1001/jama.2018.5281.
4. Fujimoto H, Ishimura R, Tao S, et al. Two cases of acute coronary syndrome that occurred by preoperative discontinuation of antiplatelet therapy in the chronic phase after stent implantation. *J Cardiol* 2009; 54: 470–474. DOI: 10.1016/j.jjcc.2009.02.009.
5. Mohar DS, Seto AH and Kern MJ. Primary percutaneous coronary intervention in patients with ST-Segment-elevation myocardial infarction and concurrent active gastrointestinal bleeding. *Circ Cardiovasc Interv* 2015; 8: e003058. DOI: 10.1161/CIRCINTERVENTIONS.115.003058.
6. Rossini R, Musumeci G, Visconti LO, et al. Perioperative management of antiplatelet therapy in patients with coronary stents undergoing cardiac and non-cardiac surgery: a consensus document from Italian cardiological, surgical and anaesthesiological societies. *EuroIntervention* 2014; 10: 38–46.

7. Saia F. Surgery after drug-eluting stent implantation: it's not all doom and gloom! *J Thorac Dis* 2017; 9: E373–E377.
8. Gulizia MM, Colivicchi F, Abrignani MG, et al. Consensus document ANMCO/ANCE/ARCA/GICR-IACPR/GISE/SICOA: long-term antiplatelet therapy in patients with coronary artery disease. *Eur Heart J Suppl* 2018; 20: F1–F74.
9. Saia F, Belotti LM, Guastaroba P, et al. Surge Risk of adverse cardiac and bleeding events following cardiac and noncardiac surgery in patients with coronary stent: how important is the interplay between stent type and time from stenting to surgery? *Circ Cardiovasc Qual Outcomes* 2016; 9: 39–47.
10. Cortese B and Danzi GB. Optimal dual antiplatelet treatment after drug-eluting stent implantation: it's not the time for weaning. *Am J Cardiol* 2010; 105: 1044–1045.