






## CASE REPORT

# REVISED Case Report: Penetrating Thoracic Trauma by A Gunshot Involving the Heart [version 2; peer review: 2 approved]

Alok Atreya <sup>1</sup>, Ritesh G. Menezes<sup>2</sup>, Ashal Timalisina<sup>3</sup>, Geeta Bashyal <sup>4</sup>, Lokaratna Gyawali <sup>4</sup>, Sushila Gyawali<sup>4</sup>

<sup>1</sup>Department of Forensic Medicine, Lumbini Medical College and Teaching Hospital, Tansen, Palpa, Lumbini, 32500, Nepal

<sup>2</sup>Forensic Medicine Division, Department of Pathology, College of Medicine, Imam Abdulrahman Bin Faisal University, Dammam, Saudi Arabia

<sup>3</sup>Lumbini Medical College and Teaching Hospital, Tansen, Palpa, Lumbini, 32500, Nepal

<sup>4</sup>District Hospital, Tansen, Palpa, Lumbini, 32500, Nepal

**v2** First published: 05 Jul 2021, 10:532  
<https://doi.org/10.12688/f1000research.54428.1>

Latest published: 26 Aug 2021, 10:532  
<https://doi.org/10.12688/f1000research.54428.2>

## Abstract

Firearm-related mortality is not frequently encountered in a country like Nepal where there are stringent laws prohibiting the buying, selling, carrying or storing of firearms. To possess a firearm a person must have a valid license. Wounds produced by firearms have typical characteristics the knowledge of which helps to identify the type of firearm used, range of fire, the position of the victim, and whether the manner of death was homicidal, suicidal, or accidental. The present case is the first autopsy-based study from Nepal which discusses the wounds produced by firearms with an interpretation of such findings for medicolegal purposes. The present case highlights a social problem where the victim, a psychiatric patient, had no access to prescription medication due to coronavirus disease (COVID-19) related lockdown.

## Keywords

entry wound, exit wound, Forensic Pathology, gunshot, hemothorax, Nepal, smooth bore

## Open Peer Review

Reviewer Status  

### Invited Reviewers

	1	2
<b>version 2</b> (revision) 26 Aug 2021	 report	 report
		
<b>version 1</b> 05 Jul 2021	 report	 report

- Panagiotis K. Stefanopoulos** , 401 Army Hospital, Athens, Greece  
Greek Army, Athens, Greece
- Navneet Ateriya** , All India Institute of Medical Sciences, Gorakhpur, Gorakhpur, India

Any reports and responses or comments on the article can be found at the end of the article.

**Corresponding author:** Geeta Bashyal ([geetabashyal6@gmail.com](mailto:geetabashyal6@gmail.com))

**Author roles:** **Atreya A:** Conceptualization, Validation, Visualization, Writing – Original Draft Preparation; **Menezes RG:** Validation, Visualization, Writing – Review & Editing; **Timalsina A:** Validation, Visualization, Writing – Review & Editing; **Bashyal G:** Data Curation, Investigation, Validation, Visualization; **Gyawali L:** Data Curation, Investigation, Validation, Visualization; **Gyawali S:** Data Curation, Investigation, Validation, Visualization

**Competing interests:** No competing interests were disclosed.

**Grant information:** The author(s) declared that no grants were involved in supporting this work.

**Copyright:** © 2021 Atreya A *et al.* This is an open access article distributed under the terms of the [Creative Commons Attribution License](#), which permits unrestricted use, distribution, and reproduction in any medium, provided the original work is properly cited.

**How to cite this article:** Atreya A, Menezes RG, Timalsina A *et al.* **Case Report: Penetrating Thoracic Trauma by A Gunshot Involving the Heart [version 2; peer review: 2 approved]** F1000Research 2021, 10:532 <https://doi.org/10.12688/f1000research.54428.2>

**First published:** 05 Jul 2021, 10:532 <https://doi.org/10.12688/f1000research.54428.1>

**REVISED Amendments from Version 1**

All the comments from the reviewers have been taken into account in the new revision. We have further discussed the entry wound, which showed a muzzle imprint signifying a contact shot. The extensive blackening of the entry wound is also discussed in detail. Some grammatical errors are also corrected in this version.

**Any further responses from the reviewers can be found at the end of the article**

**Introduction**

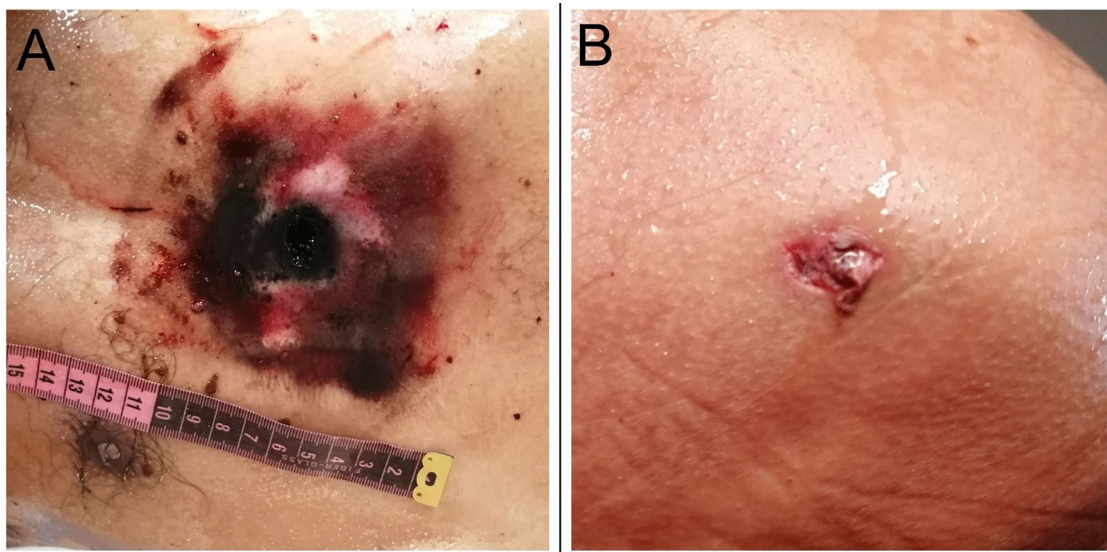
There are stringent laws regarding firearms in Nepal. However, illegal possession of firearms is not uncommon in rural part of this mountainous country. Self-suspension by hanging and consumption of agricultural poisons are the common methods of suicides in Nepal. Use of firearms for committing suicide is rare. We report a case of firearm related fatality from Nepal, where a flint-lock type muzzle loader smooth bore firearm was used to commit suicide and discuss the interpretation of firearm related wounds during a medicolegal examination. The victim in the present case was a schizophrenic patient, who had to discontinue his prescription medication due to coronavirus (COVID-19) related lockdown.

**Case report**

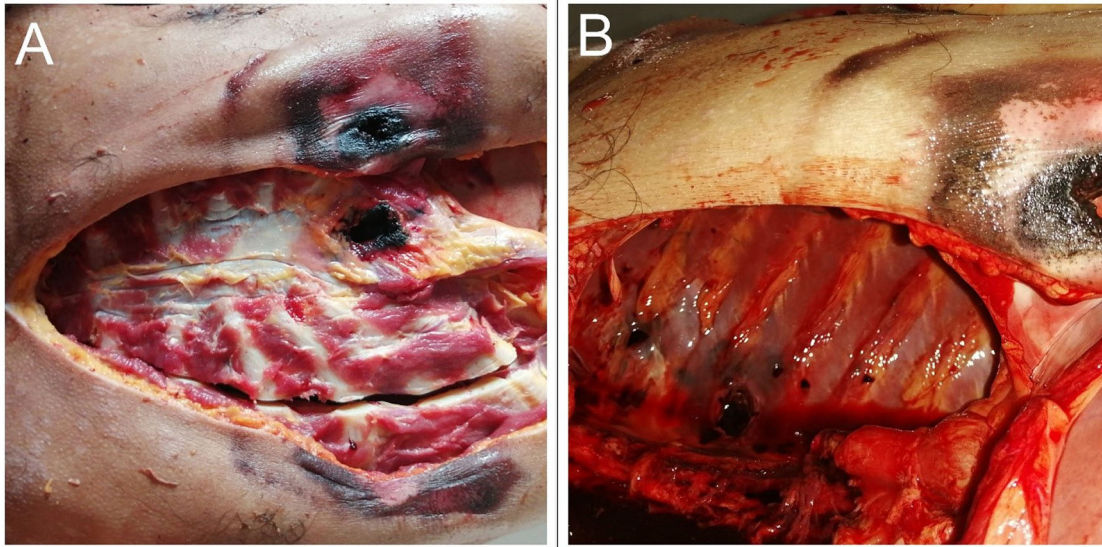
The dead body of 45-year-old male was brought for autopsy. The body was stiff at all the joints. The hands were clenched and the whole body smeared in blood. Post mortem lividity could not be appreciated. A rectangular contusion with muzzle imprint was noted in the front of the chest which measured  $10 \times 8$  cm. An oval perforated lacerated wound (entry wound) having 1.8 cm diameter was present in the middle of the contusion [Figure 1]. The wound was charred, black in color with surrounding blackening of the skin. The perforated wound was 48 cm from the vertex in midline, 115 cm from the sole of the foot and 18 cm from the supra sternal notch. It was 17 cm from the right mid axillary line and 20 cm from the left mid axillary line. A linear slit-like laceration (exit wound) was present on the back in the left side which measured  $0.5 \times 0.2$  cm and was located 25 cm from the vertex, 129 cm from the sole of the foot [Figure 1].

On opening the chest, a perforating fracture was noted in the xiphoid process [Figure 2]. The heart was pulverized [Figure 3] with exsanguination of the blood into pericardial cavity. The clotted blood in the pericardial cavity weighed about 650 gm. When a probe was directed through the heart from the defect, it was noted that the entry point was located on the right side of the anterior interventricular septum and exited through the left ventricle [Figure 3]. The direction was right to left and below upwards. The left lung was completely collapsed and there was a penetrating injury noted at the upper lobe. The rest of the findings were unremarkable.

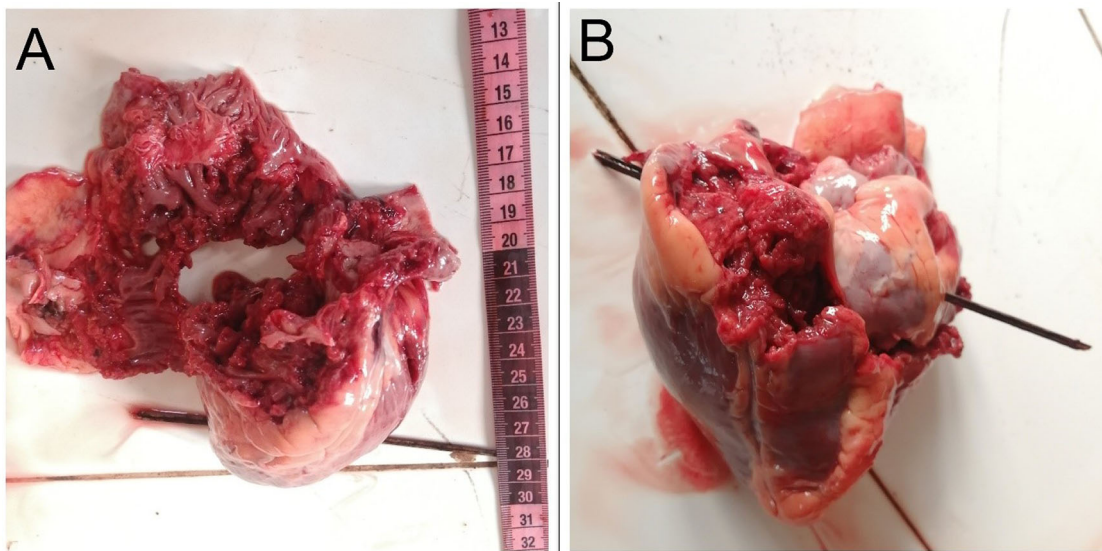
As per the history provided by the victim's brother, the deceased was an unmarried male. He was diagnosed with schizophrenia since adolescence for which he was on the prescription medicine Quetiapine. The medicine was not



**Figure 1.** A, An oval entry wound is present on the front of the chest. B, A linear, slit-like lacerated exit wound on the back.



**Figure 2.** A, A perforating fracture in the xiphoid process. B, Punctured laceration is seen in the posterior chest wall.



**Figure 3.** A, Pulverized heart. B, A wooden probe passed through the defect showing the direction of the projectile.



**Figure 4.** The firearm recovered from the scene of crime.

available at his rural pharmacy and due to the COVID-19 pandemic lockdown, he was unable to visit the tertiary hospital for his regular prescription. The medicine was therefore discontinued for 3 months prior to death. The victim consumed homemade arrack (a distilled alcoholic drink) regularly which they prepared at their home.

The crime scene photograph provided by the investigating officer showed a single barrel, smooth-bored firearm which was a flint lock type muzzle loader [Figure 4].

## Discussion

Shotgun wounds vary in characteristics depending upon type, distance, position and the number of shots. On entering the body cavity, projectiles follow the tissue of least resistance.<sup>1</sup> A shotgun wound in the chest cannot point well towards the manner of death. However, contact shots are more likely to be suicidal than homicidal and are more fatal for single shot.<sup>2</sup>

The entry wound showed some muzzle imprint, signifying a contact shot. The expanding gases that enter the chest cavity cause a bulging out of the skin against the muzzle, resulting in an imprint often significantly larger than the actual diameter of the muzzle.<sup>3</sup> While in hard contact wounds most of the soot is directed into the wound, with little soil of the surrounding skin, in this case the use of black powder in the muzzle loader may have accounted for the extensive blackening of the skin.<sup>3</sup> In the present case as the projectile had exited from the body it could not be ascertained on the type and number of projectiles (pellets). Due to limited resources at the mortuary radiological examination was not done in the present case.

Shots to the heart are very common, with only the head being a more common target.<sup>4</sup> Suicidal victims are aware of the lethality of gunshots to this vital organ and some victims even locate the cardiac impulse before taking the shot. Furthermore, suicidal fire is more likely to be directed right to left with homicidal direction commonly being left to right.<sup>5</sup> There was complete destruction of the heart noted at autopsy which was due to the hydrodynamic pressure generated by the passage of the projectile through the heart that caused blowout of its walls.

The crime scene visit in cases of firearm related mortality is equally important in interpreting the manner of death. In suicides, the offending weapon is usually found at the scene of crime in contrast to homicides where the perpetrator usually carries away the weapon after committing the crime.

In contrast to stab wounds, gunshot cause more exsanguination of blood due to jagged tearing of myocardium. 60 ml to 200 ml of clotted blood is enough to cause death. Penetrating thoracic trauma as a result of gunshot injuries are associated with traumatic hemothorax, hemopneumothorax, or pneumothorax.<sup>6</sup> If the penetrating injury involves the heart, the chances of survival are less than 1%,<sup>6</sup> as seen in our case. There are increased number of suicides from Nepal reported during the COVID-19 pandemic.<sup>7</sup> The patients with underlying psychiatric disorder could not get access to their prescription medication due to the lockdown as all the public transportation was halted and people were afraid to get out of home. Discontinuation of medication in schizophrenic patients has shown to exacerbate the syndrome.<sup>8</sup> This might have been the underlying reason for suicide in the present case. The present case further highlights the social concern the pandemic has brought where patients are restricted of access to their health care needs due to lack of transport in the lockdown.

## Conclusion

Firearm fatalities are medicolegal cases where the autopsy surgeon is required to determine the manner of death based upon the injuries present over the body. Meticulous examination of the wound not only gives clues about the entry and exit wounds but also the range of fire and the weapon used. The manner of death can also be interpreted from the position and characteristics of the wound. A crime scene visit is also mandated in firearm related fatalities which will further help to corroborate the findings.

## Authors' declaration statements

The authors' guarantee that the work is original and does not infringe copyright or other party's property rights. All authors have read and approved this submission and have given appropriate credit to everyone who participated in this work.

## Ethics approval and consent to participate

### Patient consent

Written informed consent was obtained from the deceased's elder brother for publication of this case report.

## Data availability

All data underlying the results are available as part of the article and no additional source data are required.

## References

---

1. Ordog GJ, Wasserberger J, Balasubramaniam S: **Shotgun wound ballistics**. *J Trauma*. 1988; **28**(5): 624–631.  
[PubMed Abstract](#) | [Publisher Full Text](#)
2. Cave R, DiMaio VJ, Molina DK: **Homicide or suicide? Gunshot wound interpretation: a Bayesian approach**. *Am J Forensic Med Pathol*. 2014; **35**(2): 118–123.  
[PubMed Abstract](#) | [Publisher Full Text](#)
3. DiMaio V: *Gunshot wounds: Practical aspects of firearms, ballistics, and forensic techniques*. 3rd Edition. Boca Raton: CRC Press; 2015.
4. Avis SP: **Suicidal gunshot wounds**. *Forensic Sci Int*. 1994; **67**(1): 41–47.  
[PubMed Abstract](#) | [Publisher Full Text](#)
5. Strajina V, Živković V, Nikolić S: **Forensic issues in suicidal single gunshot injuries to the chest: an autopsy study**. *Am J Forensic Med Pathol*. 2012; **33**(4): 373–376.  
[PubMed Abstract](#) | [Publisher Full Text](#)
6. Zeiler J, Idell S, Norwood S, et al.: **Hemothorax: A Review of the Literature**. *Clin Pulm Med*. 2020; **27**(1): 1–12.  
[PubMed Abstract](#) | [Publisher Full Text](#) | [Free Full Text](#)
7. Pokhrel S, Sedhai YR, Atreya A: **An increase in suicides amidst the coronavirus disease 2019 pandemic in Nepal**. *Med Sci Law*. 2021; **61**(2): 161–162.
8. Liu-Seifert H, Adams DH, Kinon BJ: **Discontinuation of treatment of schizophrenic patients is driven by poor symptom response: a pooled post-hoc analysis of four atypical antipsychotic drugs**. *BMC Med*. 2005; **3**: 21.

# Open Peer Review

Current Peer Review Status:  

---

## Version 2

Reviewer Report 02 September 2021

<https://doi.org/10.5256/f1000research.59276.r92855>

© 2021 Ateriya N. This is an open access peer review report distributed under the terms of the [Creative Commons Attribution License](#), which permits unrestricted use, distribution, and reproduction in any medium, provided the original work is properly cited.



**Navneet Ateriya** 

Department of Forensic Medicine and Toxicology, All India Institute of Medical Sciences, Gorakhpur, Gorakhpur, Uttar Pradesh, India

No further comments.

**Competing Interests:** No competing interests were disclosed.

**Reviewer Expertise:** Forensic Pathology, Forensic Ballistics

**I confirm that I have read this submission and believe that I have an appropriate level of expertise to confirm that it is of an acceptable scientific standard.**

Reviewer Report 31 August 2021

<https://doi.org/10.5256/f1000research.59276.r92854>

© 2021 Stefanopoulos P. This is an open access peer review report distributed under the terms of the [Creative Commons Attribution License](#), which permits unrestricted use, distribution, and reproduction in any medium, provided the original work is properly cited.



**Panagiotis K. Stefanopoulos** 

<sup>1</sup> The First Department of Surgery, 401 Army Hospital, Athens, Greece

<sup>2</sup> Military College of Healthcare Administration, Greek Army, Athens, Greece

The authors have successfully and meticulously addressed all comments made by the reviewers. They have also convincingly explained the reasons for not encompassing certain suggestions by giving some additional details about the case. Therefore, I recommend that their article is indexed in its present form.

**Competing Interests:** No competing interests were disclosed.

**Reviewer Expertise:** Maxillofacial surgery, ballistic trauma, chemical warfare

**I confirm that I have read this submission and believe that I have an appropriate level of expertise to confirm that it is of an acceptable scientific standard.**

---

Version 1

Reviewer Report 02 August 2021

<https://doi.org/10.5256/f1000research.57912.r89003>

© 2021 Ateriya N. This is an open access peer review report distributed under the terms of the [Creative Commons Attribution License](#), which permits unrestricted use, distribution, and reproduction in any medium, provided the original work is properly cited.



**Navneet Ateriya** 

Department of Forensic Medicine and Toxicology, All India Institute of Medical Sciences, Gorakhpur, Gorakhpur, Uttar Pradesh, India

The work is presented clearly and accurately by the authors. Flow is good, easy to read and understandable to the readers. There is one one minor correction in Abstract line 1: replace word "us" with "is". Overall, it flows good.

Introduction is sufficient to give background image of article.

Case report - Other findings present on skin surrounding fire arm entry wounds such as blackening, tattooing may also be mentioned if present. Author did not mention whether the deceased was subjected to radiological examination prior to autopsy. Images are very helpful in understanding and correlating the findings.

Discussion part is okay and the conclusions drawn adequately support the findings.

**Is the background of the case's history and progression described in sufficient detail?**

Yes

**Are enough details provided of any physical examination and diagnostic tests, treatment given and outcomes?**

Yes

**Is sufficient discussion included of the importance of the findings and their relevance to future understanding of disease processes, diagnosis or treatment?**

Yes



**Is the case presented with sufficient detail to be useful for other practitioners?**

Yes

**Competing Interests:** No competing interests were disclosed.**Reviewer Expertise:** Forensic Pathology, Forensic Ballistics**I confirm that I have read this submission and believe that I have an appropriate level of expertise to confirm that it is of an acceptable scientific standard, however I have significant reservations, as outlined above.**

Author Response 04 Aug 2021

**Geeta Bashyal**, District Hospital, Tansen, Palpa, Nepal

Dear Reviewer,

We would like to thank you for your valuable comments. We have corrected the manuscript as instructed. Regarding your query about the radiological examination, due to limited resources at the mortuary radiological examination was not done in the present case. This statement has been added to the manuscript text.

**Competing Interests:** No competing interests were disclosed.

Reviewer Report 13 July 2021

<https://doi.org/10.5256/f1000research.57912.r89057>

© 2021 Stefanopoulos P. This is an open access peer review report distributed under the terms of the [Creative Commons Attribution License](#), which permits unrestricted use, distribution, and reproduction in any medium, provided the original work is properly cited.

**Panagiotis K. Stefanopoulos** <sup>1</sup> The First Department of Surgery, 401 Army Hospital, Athens, Greece<sup>2</sup> Military College of Healthcare Administration, Greek Army, Athens, Greece

The article is very well presented with respect to the case reported, with clear photos that help the reader understand the nature of the lethal injury described therein.

However, the authors use in their references an article on shotgun wound ballistics, whereas the wound from the flintlock rifle was most likely produced by a single projectile, such as those normally used by this type of weapon (otherwise the authors should clarify whether there were multiple projectiles such as pellets). On the other hand, the literature on wound ballistics as applied to flintlock rifles is virtually non-existent, which is another reason why this article is interesting.

The entrance wound, in addition to the description given, appears to show some muzzle imprint, which can be expected from a contact shot, since according to DiMaio's *Gunshot Wounds* (3rd ed., CRC Press 2016, p. 115) the expanding gases that enter the chest (or the abdominal) cavity cause a bulging out of the skin against the muzzle, resulting in an imprint often significantly larger than the actual diameter of the muzzle.

While in hard contact wounds most of the soot is directed into the wound, with little soil of the surrounding skin, in this case the use of black powder in the muzzle loader may account for the extensive blackening of the skin. However, the term "tattooing" used by the authors may be inappropriate, since it is used to indicate the marking of the skin from powder particles, not the blackening from the smoke.

An important finding of the autopsy is the complete destruction of the heart. The authors described it simply as pulverized. In my opinion, this is the impressive result of the hydrodynamic pressure generated by the passage of the projectile through the heart, which caused blowout of its walls. I suggest that this is added to their report.

Thank you for giving me the opportunity to review this interesting article.

#### References

1. DiMaio V.J.M.: *Gunshot Wounds: Practical Aspects of Firearms, Ballistics, and Forensic Techniques*. CRC Press. 2016. 115

#### **Is the background of the case's history and progression described in sufficient detail?**

Yes

#### **Are enough details provided of any physical examination and diagnostic tests, treatment given and outcomes?**

Yes

#### **Is sufficient discussion included of the importance of the findings and their relevance to future understanding of disease processes, diagnosis or treatment?**

Partly

#### **Is the case presented with sufficient detail to be useful for other practitioners?**

Yes

**Competing Interests:** No competing interests were disclosed.

**Reviewer Expertise:** Maxillofacial surgery, ballistic trauma

**I confirm that I have read this submission and believe that I have an appropriate level of expertise to confirm that it is of an acceptable scientific standard, however I have significant reservations, as outlined above.**

Author Response 04 Aug 2021

**Geeta Bashyal**, District Hospital, Tansen, Palpa, Nepal

Dear Reviewer,

We would like to thank you for the analysis of this manuscript and your valuable remarks. The manuscript has been corrected according to the comments. All changes you suggested are incorporated as follows:

**Comment:** However, the authors use in their references an article on shotgun wound ballistics, whereas the wound from the flintlock rifle was most likely produced by a single projectile, such as those normally used by this type of weapon (otherwise the authors should clarify whether there were multiple projectiles such as pellets).

**Response:** The following sentence is added to the text "In the present case as the projectile had exited from the body it could not be ascertained on the type and number of projectiles (pellets)."

**Comment:** The entrance wound, in addition to the description given, appears to show some muzzle imprint, which can be expected from a contact shot, since according to DiMaio's Gunshot Wounds (3rd ed., CRC Press 2016, p. 115) the expanding gases that enter the chest (or the abdominal) cavity cause a bulging out of the skin against the muzzle, resulting in an imprint often significantly larger than the actual diameter of the muzzle.

**Response:** As per the reviewer's suggestion we did go through the reference and have detailed the entry wound "The entry wound showed some muzzle imprint, signifying a contact shot. The expanding gases that enter the chest cavity cause a bulging out of the skin against the muzzle, resulting in an imprint often significantly larger than the actual diameter of the muzzle. <sup>3</sup>"

**Comment:** While in hard contact wounds most of the soot is directed into the wound, with little soil of the surrounding skin, in this case the use of black powder in the muzzle loader may account for the extensive blackening of the skin. However, the term "tattooing" used by the authors may be inappropriate, since it is used to indicate the marking of the skin from powder particles, not the blackening from the smoke.

**Response:** We have corrected the manuscript and have deleted the term tattooing.

**Comment:** An important finding of the autopsy is the complete destruction of the heart. The authors described it simply as pulverized. In my opinion, this is the impressive result of the hydrodynamic pressure generated by the passage of the projectile through the heart, which caused blowout of its walls. I suggest that this is added to their report.

**Response:** As per the suggestion the following sentence is added to the manuscript "There was complete destruction of the heart noted at autopsy which was due to the hydrodynamic pressure generated by the passage of the projectile through the heart that caused blowout of its walls."

**Competing Interests:** No competing interests were disclosed.

---

The benefits of publishing with F1000Research:

- Your article is published within days, with no editorial bias
- You can publish traditional articles, null/negative results, case reports, data notes and more
- The peer review process is transparent and collaborative
- Your article is indexed in PubMed after passing peer review
- Dedicated customer support at every stage

For pre-submission enquiries, contact [research@f1000.com](mailto:research@f1000.com)

**F1000Research**