

Case Illustrated

Myositis complicating benzathine penicillin-G injection in a case of rheumatic heart disease



Joshua R. Francis^{a,b,c,*}, Rosemary Wyber^d, Bo Remenyi^c, David Croser^e,
Jonathan Carapetis^{d,f}

^a Department of Paediatrics, Royal Darwin Hospital, Darwin, NT, Australia

^b Northern Territory Medical Program, Flinders University, Darwin, NT, Australia

^c Menzies School of Health Research, Charles Darwin University, Darwin, NT, Australia

^d Telethon Kids Institute, University of Western Australia, Perth, WA, Australia

^e Department of Radiology, Royal Darwin Hospital, Darwin, NT, Australia

^f Department of Paediatric Infectious Diseases, Princess Margaret Hospital for Children, Perth, WA, Australia

ARTICLE INFO

Article history:

Received 25 November 2015

Accepted 1 February 2016

Keywords:

Rheumatic heart disease

Acute rheumatic fever

Penicillin

Adverse drug reaction

ABSTRACT

A 7-year old boy developed myositis secondary to intramuscular injection of benzathine penicillin-G in the context of secondary prophylaxis for rheumatic heart disease. Side effects of intramuscular delivery of benzathine penicillin-G are well described and include injection site pain and inflammation, but myositis, as depicted on magnetic resonance imaging in this case, has not previously been described.

© 2016 The Authors. Published by Elsevier Ltd. This is an open access article under the CC BY-NC-ND license (<http://creativecommons.org/licenses/by-nc-nd/4.0/>).

An Indigenous boy from a remote Australian community had his first episode of acute rheumatic fever (ARF) recognised at age 4 years. He was diagnosed with rheumatic heart disease (RHD) and commenced on 4-weekly intramuscular benzathine penicillin-G (BPG) injections. At age 7 years, he presented with fever, left hip monoarthritis and raised inflammatory markers (c-reactive protein 154 mg/L; erythrocyte sedimentation rate 130 mm/h; white cell count $14.3 \times 10^9 \text{ L}^{-1}$; neutrophil count $10.6 \times 10^9 \text{ L}^{-1}$) 46 days after his most recent BPG injection. On admission, he was administered 900 mg (2.3 ml) intramuscular BPG (Bicillin L-A) to the right gluteal region as a scheduled dose of secondary prophylaxis. Two days later, echocardiography and magnetic resonance imaging (MRI) of the left hip were performed.

MRI revealed a small left hip effusion consistent with acute arthritis, but no evidence of osteomyelitis. An unexpected finding

on MRI was extensive inflammatory change within the right gluteus maximus, corresponding to the site of the BPG injection (Fig. 1). Findings were consistent with myositis, likely secondary to local inflammatory reaction to BPG.

Echocardiography demonstrated carditis with progression of RHD (moderate mitral regurgitation, moderate aortic regurgitation). Left hip pain responded promptly to oral aspirin, but the child had significant injection-site pain and an associated limp for a further 5 days.

Intramuscular BPG is crucial in the management and secondary prevention of ARF and RHD. The injection is painful, and as demonstrated in this case, can result in significant local inflammation. These complications may be influenced by poor injection technique or product quality, but neither of these are likely in our setting. Poor adherence to BPG hampers the success of RHD programmes throughout the world. Further research into the impact of adverse effects would be informative. Improved delivery systems for long-acting prophylactic penicillin in the secondary prevention of RHD are desperately needed.

* Corresponding author at: Department of Paediatrics, Royal Darwin Hospital, 125 Rocklands Drive, Tiwi, NT 0810, Australia. Tel.: +61 423 528 381.

E-mail address: josh.francis@nt.gov.au (J.R. Francis).

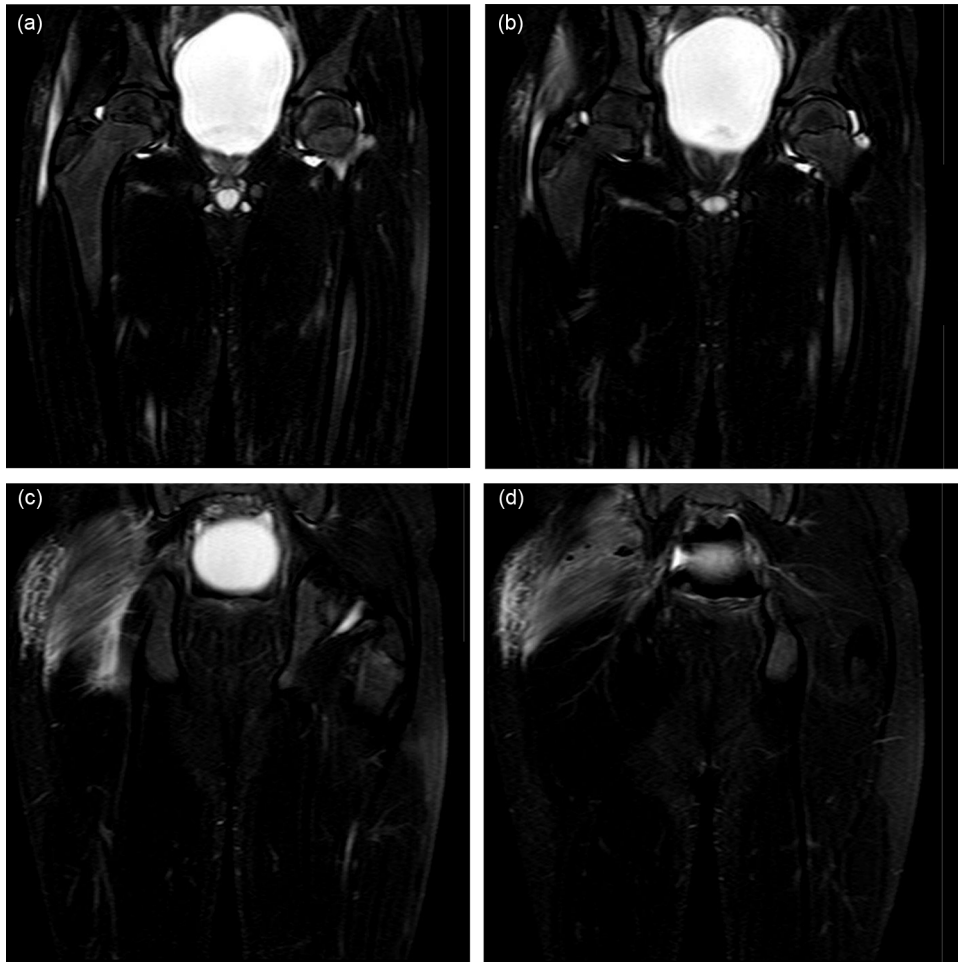


Fig. 1. Coronal T2 fat saturated MRI sequences demonstrating small left hip effusion (a and b), and significant right sided soft tissue oedema affecting subcutaneous and muscle tissue from anterior to the trochanteric region posteriorly to the sacral margin (c and d). Multiple globular low signal foci in muscle (d) represent injection site granulomata, likely resulting from previous intramuscular injections.

Financial disclosure and conflicts of interest

None of the authors have any financial relationships or other conflicts of interest relevant to this article to disclose.