

Case report

Open Access

Fallacies of preoperative lymphoscintigraphy in detecting sentinel node in breast cancer

Manoj Pandey*¹, Surya VS Deo² and R Maharajan³

Address: ¹Surgical Oncology, Jawaharlal Nehru Cancer Hospital and Research Centre, Bhopal, India, ²Surgical Oncology, Institute Rotary Cancer Hospital, All India Institute of Medical Sciences, New Delhi 110 029, India and ³Department of Nuclear Medicine, West fort Hi-tech Hospital Ltd, Punkunnam, Thrissure 680 002, India

Email: Manoj Pandey* - manojpandey@vsnl.com; Surya VS Deo - svsdeo@yahoo.co.in; R Maharajan - oncosurgery@hotmail.com

* Corresponding author

Published: 31 May 2005

Received: 14 April 2005

World Journal of Surgical Oncology 2005, 3:31 doi:10.1186/1477-7819-3-31

Accepted: 31 May 2005

This article is available from: <http://www.wjso.com/content/3/1/31>

© 2005 Pandey et al; licensee BioMed Central Ltd.

This is an Open Access article distributed under the terms of the Creative Commons Attribution License (<http://creativecommons.org/licenses/by/2.0>), which permits unrestricted use, distribution, and reproduction in any medium, provided the original work is properly cited.

Abstract

Background: Preoperative lymphoscintigraphy is one of the three methods of evaluating sentinel nodes in patients with breast cancer; however, it has been reported to have a high false negative rate.

Case presentations: We report here two cases where the preoperative lymphoscintigraphy was found to be fallacious. A 44-year-old female with T2N0 breast cancer underwent preoperative lymphoscintigraphy with Tc⁹⁹ sulfur colloid which failed to show any uptake in axilla or internal mammary chain. Intraoperative scintigraphy with blue dye and hand held gamma probe identified sentinel lymph node in axilla. Another patient with T2N0 lesion underwent preoperative lymphoscintigraphy which showed a sentinel lymph node in axilla and another in supraclavicular fossa. Intraoperative scintigraphy failed to show supraclavicular node however axillary node was correctly identified.

Conclusion: These two cases further strengthen the need to carry out triple test in identification of sentinel lymph node in patients with breast cancer. It also demonstrates the fallacies of preoperative lymphoscintigraphy.

Background

Metastasis to the axillary lymph node is the single most important prognostic factor in breast cancer. The therapeutic decisions are based on the axillary status. However, in recent past sentinel lymph node identification and biopsy (SLNB) is fast emerging as an alternate to axillary dissection as it avoids the complications of axillary dissection like lymphedema, pain, numbness and limitations of shoulder movements [1,2]. SLNB has been found to be highly predictive of axillary lymph node status with false negative results of less than 5% [3-5]. A number of validity

studies have been published however, the question of its oncological safety still awaits the results of randomized clinical trials [6,7].

The sentinel lymph node identification is usually carried out by preoperative localization using Tc⁹⁹ colloid and gamma camera or by intraoperative localization using hand held gamma probe or by dye technique. Majority of the centers use a combination of techniques and it has been reported that the triple method using all of the above gives the best results [8-10].

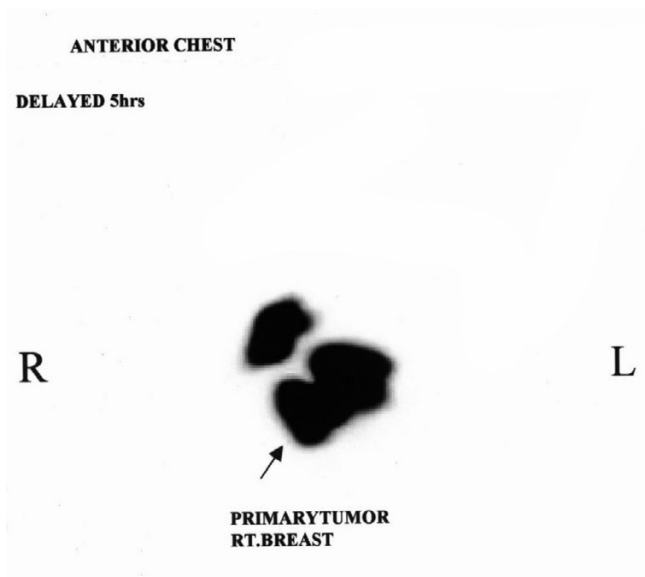


Figure 1

Lymphoscintigraphic scan showing radionuclide uptake in primary tumor, no sentinel node is identified.

Non-visualization of sentinel node at preoperative scintigraphy is a continued problem. Between 3 to 30% of the nodes are reported to be non visualized most of which are subsequently picked up on intraoperative scintigraphy [11-13]. Several factors like age, size of the breast, presence of metastasis, has been proposed to influence the non-visualization [11-17]. We report here two unusual cases of non-visualization or abnormal visualization during preoperative lymphoscintigraphy; both of these cases were subsequently identified and biopsied intraoperatively using a combination of blue dye and hand held gamma probe.

Case presentation

Case 1

A 44-year-old female presented with 2 months history of a progressive lump in right breast. She gave a past history of noncyclic mastalgia of two years duration. There was no other significant past history. Patient had undergone abdominal hysterectomy 4 years back for dysfunction uterine bleeding and was on hormone replacement therapy with estrogen alone for the same duration.

On examination there was 4 × 3 cm lump in upper outer quadrant of the right breast with no fixity to skin or underlying tissue. There were no significant axillary or supraclavicular nodes. Abdominal examination failed to show any organomegaly. Routine hematological, biochemical tests, chest roentgenogram, abdominal ultrasonogram and

bone scans were normal. Fine needle aspiration cytology revealed Infiltrating duct carcinoma.

Patient was planned for sentinel lymph node biopsy follow by mastectomy. 8 ml of Tc⁹⁹ sulfur colloid was injected around the tumor and immunoscintigraphy images (anterior and lateral view) were taken. These images failed to show any lymph node uptake either in axilla or else where (figure 1) at the time of surgery 4 ml of isosulfan blue was injected peritumorally and 20 minutes later axilla was entered. Sentinel node detection was also carried out using a hand held gamma probe (Navigator[®], Auto sutures). Sentinel lymph node was identified by combined technique in level I axilla lying just posterior to the primary tumor. On gross examination most of the node appeared to be replaced by tumor and only a part of it appeared normal this part was stained blue while rest of the node was white. Histopathology of primary tumors was infiltrating duct carcinoma, with involvement of skin. Sentinel lymph node showed metastatic deposit. Other lymph nodes in axillary dissection specimen were also positive.

Case 2

A 42-year-old female presented with lump in left breast of 1-month duration. She was a known case of carcinoma breast and had undergone right modified radical mastectomy 7 years back followed by chest wall radiotherapy and 6 cycles of CMF chemotherapy.

On examination there was a 3 × 2 cm lump located in the retro areolar area of left breast. Scar of right mastectomy was seen. There were no palpable axillary nodes or supraclavicular nodes. Systemic examination was normal. Routine hematological and biochemical investigations chest x-ray, abdominal sonography and bone scans were normal. The treatment options were discuss with the patient and she wanted to conserve this breast and hence a wide excision of mass encompassing nipple areola complex, sentinel node biopsy followed by axillary clearance was planned.

On the morning of the surgery 4 ml of Tc⁹⁹ sulfur colloid was injected peritumorally and scintigraphic images were taken 4 hours later. The scintigraphic image showed one sentinel node in axilla and other in supraclavicular fossa (figure 2). At surgery 4 ml of isosulfan blue was injected peritumorally and sentinel node identification was carried out by combined method. On exploration of axilla the blue and hot sentinel node was identified and removed. However, hand held probe failed to pick a hot spot in supraclavicular fossa axillary dissection was completed.

Histopathology of the resected specimen showed infiltrative duct carcinoma margins of resection were negative.

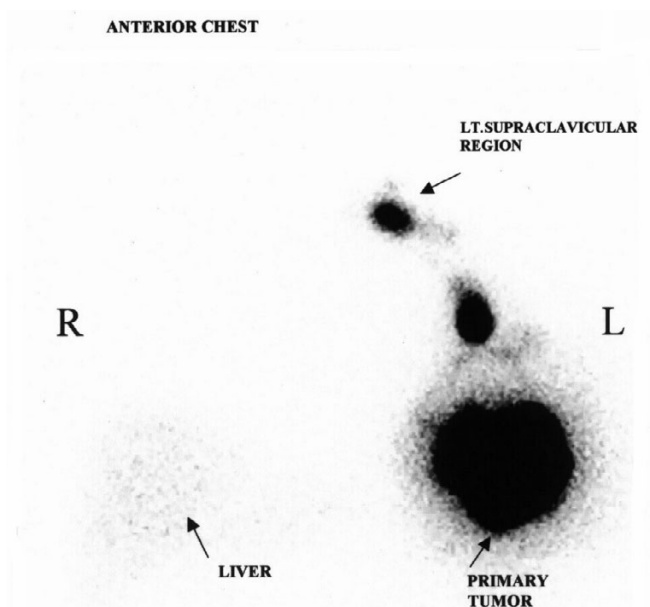


Figure 2
Lymphoscintigraphic scan showing uptake in primary tumor with sentinel node in axilla and in left supra clavicular area.

The sentinel node showed deposits from infiltrating duct carcinoma. Post operative period was uneventful and it is planned to start her on radiotherapy to residual breast with 4 cycles of anthracyclin based chemotherapy.

Discussion

The axillary dissection for axillary nodes from breast cancer is still the standard of care its routine use in node negative breast cancer has been questioned due to morbidity associated with the axillary dissection. SLNB has improved the morbidity in patients with node negative breast cancer, while providing the much needed prognostic information. Although these techniques have been successful, they are still evolving, and SLN biopsy is not yet considered the standard of care in breast cancer.

Preoperative visualization is one of the three methods commonly employed in detection of sentinel node. When radioactive colloid is used, a preoperative lymphoscintigram often is obtained to ease SLN identification further. This has been reported to have a false negative rate of 3–30% in various series [11-13]. Several factors like age, size of the breast, presence of metastasis, neoadjuvant chemotherapy, has been proposed to influence the non-visualization [11-19]. Other authors have found no significant predictor of non visualization [20]. The non-visualization in our first case was due to superimposition of locally

advance tumor in the outer quadrant and hence separation was not achieved on scintigraphy, while the erroneous supra clavicular node in the other was probably due to the spillage of radioactive material at the time of injection, which was subsequently washed off during the part preparation and hence no signal was obtained at intraoperative gamma probe assisted SLNB.

Conclusion

These two cases demonstrate the importance of using the triple technique to maximize the identification of SLN and improve the sensitivity and specificity of SLNB and fallacies of preoperative lymphoscintigraphy. This also raises a question that should preoperative scintigraphy should be carried out in all the cases?

Competing interests

The author(s) declare that they have no competing interests.

Authors' contributions

MP: Conceived the idea, carried out the literature search, prepared the draft manuscript and edited it for publication.

SVSD: helped in preparation of the manuscript and edited the final version

RM: Carried out the preoperative lymphoscintigraphy and helped in preparation of the manuscript.

MP and SVSD carried out the intraoperative scintigraphy and managed the patients.

All authors read and approved the final manuscript.

Acknowledgements

Patient consent was obtained for publication of these case reports.

References

1. Taylor KO: **Morbidity associated with axillary surgery for breast cancer.** *ANZ J Surg* 2004, **74**:314-317.
2. Poole K, Fallowfield LJ: **The psychological impact of post-operative arm morbidity following axillary surgery for breast cancer: a critical review.** *Breast* 2002, **11**:81-87.
3. Veronesi U, Paganelli G, Galimberti V, Viale G, Zurrada S, Bedoni M, Costa A, De CC, Geraghty JG, Luini A, Sacchini V, Veronesi P: **Sentinel-node biopsy to avoid axillary dissection in breast cancer with clinically negative lymph-nodes.** *Lancet* 1997, **349**:1864-1867.
4. Veronesi U, Paganelli G, Viale G, Galimberti V, Luini A, Zurrada S, Robertson C, Sacchini V, Veronesi P, Orvieto E, De CC, Intra M, Tosi G, Scarpa D: **Sentinel lymph node biopsy and axillary dissection in breast cancer: results in a large series.** *J Natl Cancer Inst* 1999, **91**:368-373.
5. Veronesi U, Galimberti V, Zurrada S, Pigatto F, Veronesi P, Robertson C, Paganelli G, Sciascia V, Viale G: **Sentinel lymph node biopsy as an indicator for axillary dissection in early breast cancer.** *Eur J Cancer* 2001, **37**:454-458.
6. Mansel RE, Goyal A: **European studies on breast lymphatic mapping.** *Semin Oncol* 2004, **31**:304-310.

7. Veronesi U, Paganelli G, Viale G, Luini A, Zurrada S, Galimberti V, Intra M, Veronesi P, Robertson C, Maisonneuve P, Renne G, De Cicco C, De Lucia F, Gennari R: **A randomized comparison of sentinel-node biopsy with routine axillary dissection in breast cancer.** *N Engl J Med* 2003, **349**:546-553.
8. Meyer-Rochow GY, Martin RC, Harman CR: **Sentinel node biopsy in breast cancer: validation study and comparison of blue dye alone with triple modality localization.** *ANZ J Surg* 2003, **73**:815-818.
9. Rahusen FD, Pijpers R, van Diest PJ, Bleichrodt RP, Torrengra H, Meijer S: **The implementation of the sentinel node biopsy as a routine procedure for patients with breast cancer.** *Surgery* 2000, **128**:6-12.
10. Goyal A, Newcombe RG, Mansel RE, Chetty U, Ell P, Fallowfield L, Kissin M, Sibbering M: **Role of routine preoperative lymphoscintigraphy in sentinel node biopsy for breast cancer.** *Eur J Cancer* 2005, **41**:238-243.
11. Birdwell RL, Smith KL, Betts BJ, Ikeda DM, Strauss HW, Jeffrey SS: **Breast cancer: variables affecting sentinel lymph node visualization at preoperative lymphoscintigraphy.** *Radiology* 2001, **220**:47-53.
12. Burak WEJ, Walker MJ, Yee LD, Kim JA, Saha S, Hinkle G, Olsen JO, Pozderac R, Farrar WB: **Routine preoperative lymphoscintigraphy is not necessary prior to sentinel node biopsy for breast cancer.** *Am J Surg* 1999, **177**:445-449.
13. Wu CT, Morita ET, Treseler PA, Esserman LJ, Hwang ES, Kuerer HM, Santos CL, Leong SP: **Failure to harvest sentinel lymph nodes identified by preoperative lymphoscintigraphy in breast cancer patients.** *Breast J* 2003, **9**:86-90.
14. Haigh PI, Hansen NM, Giuliano AE, Edwards GK, Ye W, Glass EC: **Factors affecting sentinel node localization during preoperative breast lymphoscintigraphy.** *J Nucl Med* 2000, **41**:1682-1688.
15. Kern KA, Rosenberg RJ: **Preoperative lymphoscintigraphy during lymphatic mapping for breast cancer: improved sentinel node imaging using subareolar injection of technetium 99m sulfur colloid.** *J Am Coll Surg* 2000, **191**:479-489.
16. McMasters KM, Wong SL, Tuttle TM, Carlson DJ, Brown CM, Dirk NR, Glaser RL, Vennekotter DJ, Turk PS, Tate PS, Sardi A, Edwards MJ: **Preoperative lymphoscintigraphy for breast cancer does not improve the ability to identify axillary sentinel lymph nodes.** *Ann Surg* 2000, **231**:724-731.
17. Mudun A, Aslay I, Aygen M, Muslumanoglu M, Bozfakioglu Y, Cantez S: **Can preoperative lymphoscintigraphy be used as a guide in treatment planning of breast cancer?** *Clin Nucl Med* 2001, **26**:405-411.
18. Kang SH, Kim SK, Kwon Y, Kang HS, Kang JH, Ro J, Lee ES: **Decreased identification rate of sentinel lymph node after neoadjuvant chemotherapy.** *World J Surg* 2004, **28**:1019-1024.
19. Xing Y, Cormier JN, Kuerer HM, Hunt KK: **Sentinel lymph node biopsy following neoadjuvant chemotherapy: review of the literature and recommendations for use in patient management.** *Asian J Surg* 2004, **27**:262-267.
20. Rubello D, Zavagno G, Bozza F, Lise M, De Salvo GL, Saladini G, Mariani G, Casara D: **Analysis of technical and clinical variables affecting sentinel node localization in patients with breast cancer after a single intradermal injection of 99mTc nanocolloidal albumin.** *Nucl Med Commun* 2004, **25**:1119-1124.

Publish with **BioMed Central** and every scientist can read your work free of charge

"BioMed Central will be the most significant development for disseminating the results of biomedical research in our lifetime."

Sir Paul Nurse, Cancer Research UK

Your research papers will be:

- available free of charge to the entire biomedical community
- peer reviewed and published immediately upon acceptance
- cited in PubMed and archived on PubMed Central
- yours — you keep the copyright

Submit your manuscript here:
http://www.biomedcentral.com/info/publishing_adv.asp

