

# Visualization of Cardiac Thrombus by Bedside Ultrasound

Erden E Ünlüer, MD\*  
Eylem Kuday, MD\*  
Serdar Bayata, MD†

\* Department of Emergency Medicine, İzmir Katip Çelebi University Ataturk Research and Training Hospital, İzmir, Turkey

† Department of Cardiology, İzmir Katip Çelebi University Ataturk Research and Training Hospital, İzmir, Turkey

Supervising Section Editor: Sean Henderson, MD

Submission History: Submitted May 16, 2013; Accepted June 13, 2013

Electronically published August 17, 2013

Full text available through open access at [http://escholarship.org/uc/uciem\\_westjem](http://escholarship.org/uc/uciem_westjem)

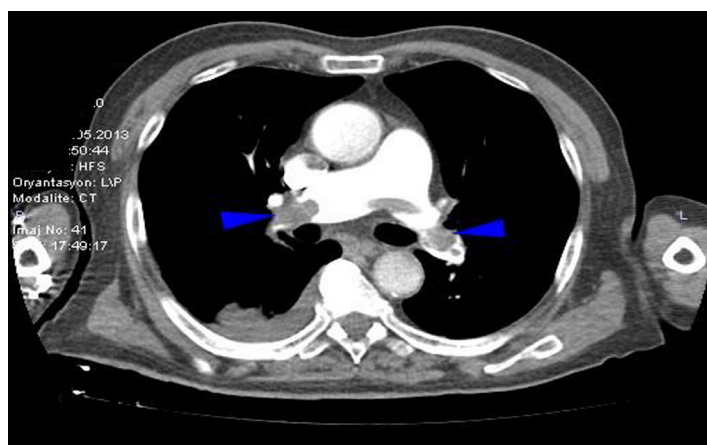
DOI: 10.5811/westjem.2013.6.18199

[West J Emerg Med. 2013;14(6):637.]

A 85-year-old man with sudden onset of dyspnea and chest pain with an history of immobilization due to right tibia plateau fracture after traffic accident 2 months ago was admitted to our emergency department. He was hypotensive (70/50 mmHg), tachycardic (166 beats/minute), tachypneic (26/minute) on admission. A 12-lead electrocardiogram showed atrial fibrillation with rapid ventricular response, arterial blood gas analysis revealed a hypoxic and hypocarbic profile together with an increased alveolar arterial oxygen. His physical examination was unremarkable except cold extremities, delayed capillary refilling time and bilateral decreased breath sounds with rhoncus, abdominal respiration and increased in diameter of right calf 3 cm more than left. Focused cardiac ultrasonography (FOCUS) performed by the emergency physician (EP) using a Mindray M7® model ultrasound machine with a 3.6 MHz microconvex transducer (M7, Mindray Bio-medical Electronics CO., Shenzhen, China) revealed enlarged right ventricle (RV), hypokinetic lateral wall and hyperkinetic apex of RV (McConnell's sign)<sup>1</sup> and also a large, mobile serpentine thrombus in the right atrium. The thrombus also extended into the inferior vena cava and protruded into the RV through the tricuspid valve during diastole (Video). Computerized tomography angiography of the thorax revealed filling defects in both main pulmonary arteries (Figure). The patient received alteplase treatment with a dose of 100 mg over 2 hours in the intensive care unit. The patient was discharged from the intensive care unit with oral anticoagulation after three days with symptomatic relief.

Pulmonary emboli (PE) is one of the crucial considerations in the differential diagnosis of acute dyspnea and hypotension. Multiple prospective studies reveal a low sensitivity (41-70%) of FOCUS for specifically identifying PE.<sup>2,3</sup> As experience with emergency ultrasound grows, EPs will be expected to fully understand and exploit the power of FOCUS to meet the evolving standards of care in emergency medicine.

**Video.** Focused cardiac sonography shows dilated right ventricle and also a mobile thrombus in the right atrium.



**Figure.** Blue arrow heads show filling defects in both main pulmonary arteries in computerized tomographic angiography of the thorax.

*Address for Correspondence:* Erden E Ünlüer, İzmir Ataturk Research and Training Hospital, Department of Emergency Medicine. Email: [erolerdenu@yahoo.com](mailto:erolerdenu@yahoo.com).

*Conflicts of Interest:* By the WestJEM article submission agreement, all authors are required to disclose all affiliations, funding sources and financial or management relationships that could be perceived as potential sources of bias. The authors disclosed none.

## REFERENCES

1. Aguilar D, Bulwer BE: Echocardiography in pulmonary embolism and secondary pulmonary hypertension. In Solomon SD, Bulwer BE, Libby P: Essential echocardiography. Totowa, NJ, 2007:333-347.
2. Torbicki A, Pruszczyk P. The role of echocardiography in suspected and established PE. *Semin Vasc Med.* 2001;1(2):165-174.
3. Miniati M, Monti S, Pratali L, et al. Diagnosis of pulmonary embolism: results of a prospective study in unselected patients. *Am J Med.* 2001;110(7):528-535.