

# Asymptomatic extraperitoneal inguinoscrotal hernia involving ureter: A case presentation and review of the literature

Evangelos Falidas,  
Stavros Gourgiotis,  
George Veloudis,  
Elena Exarchou,  
Konstantinos Vlachos<sup>1</sup>,  
Constantinos Villias

First Surgical Department, 417 NIMTS Military Veterans' Fund Hospital of Athens, Athens, <sup>1</sup>Department of Surgery, University Hospital of Ioannina, Greece

**Address for correspondence:**

Dr. Stavros Gourgiotis, 41 Zakinthinou Street, 15669, Papagou, Athens, Greece.  
E-mail: drgourgiotis@yahoo.gr

## Abstract

An inguinoscrotal hernia is a common disorder that usually contains intraperitoneal organs (small intestine, colon, appendix, ovaries). Extraperitoneal ureteral herniation into an inguinoscrotal hernia is a rare condition and often associated with congenital abnormalities or postoperative anatomic changes. A high index of suspicion is needed in order to avoid intraoperative ureteric injuries. We herein report the case of a ureteric herniation into an inguinoscrotal hernia incidentally found during a scheduled hernia repair.

**Key words:** Hernia repair, inguinoscrotal hernia, management, symptoms, ureter

## INTRODUCTION

An inguinoscrotal hernia is a common disorder that needs surgical treatment. Many organs can be herniated into the scrotum such as small intestine, appendix, colon, and ovaries. Ureteral herniation is extremely rare, usually asymptomatic and is reported as isolated case report or small series.<sup>[1]</sup> We report the case of an 88-year-old man treated for inguinoscrotal hernia where the left ureter was incidentally found in the herniated retroperitoneal fat. Presenting symptoms, diagnostic evaluation, and surgical management are discussed along with a review of the literature.

## CASE REPORT

An 88-year-old man was admitted for a left moderately sized inguinoscrotal hernia. His medical history included hypertension and benign prostatic hyperplasia. Preoperative laboratory examination did not reveal abnormalities.

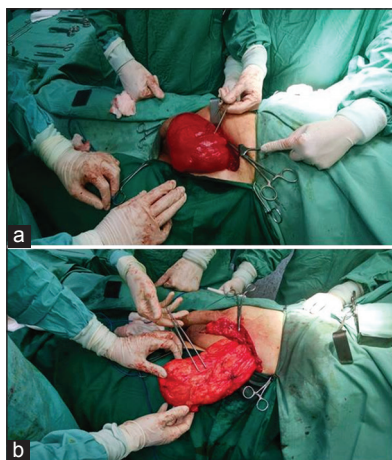
The patient underwent surgery under dural anesthesia. A left inguinal incision was made, and a massive hernia was identified. The herniated parts were dislocated from the scrotum, as well as the testicle, and cord strictures. The cord was separated from the herniated parts and was partially

covered from preperitoneal fat. No clear sac formation or intraabdominal sliding organs were observed. A large amount of retroperitoneal fat surrounded from a sac-like formation was found adjacent to the cordis [Figure 1a and b]. These adhesions, as well as a part of this fat, were excised because of the irreducibility of the mass. During the excision, a whitish peristaltic tubular formation was observed forming a loop in the herniated fat. The diagnosis of ureteric herniation was established [Figure 2]. The retroperitoneal fat and the ureter were returned into the abdomen. Mesh was used for the final repair of the hernia. 24 h later, an abdominal ultrasound was performed to rule out any structural abnormality, which may have been missed preoperatively. The patient was discharged 3 days later.

This is an open access article distributed under the terms of the Creative Commons Attribution-NonCommercial-ShareAlike 3.0 License, which allows others to remix, tweak, and build upon the work non-commercially, as long as the author is credited and the new creations are licensed under the identical terms.

**For reprints contact:** reprints@medknow.com

**How to cite this article:** Falidas E, Gourgiotis S, Veloudis G, Exarchou E, Vlachos K, Villias C. Asymptomatic extraperitoneal inguinoscrotal hernia involving ureter: A case presentation and review of the literature. J Nat Sc Biol Med 2015;6:S153-5.



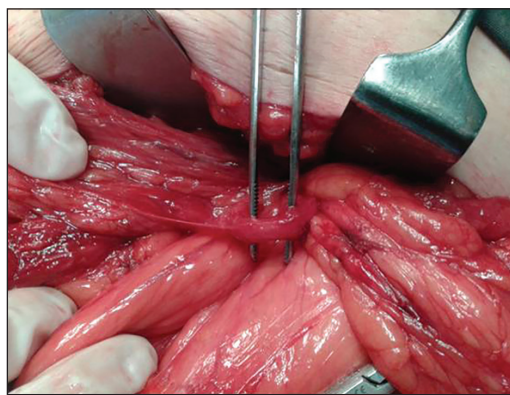
**Figure 1:** (a and b) The left extraperitoneal inguinoscrotal hernia

## DISCUSSION

Ureteral herniation is rare, and approximately 140 cases have been reported in the literature, mainly as isolated case reports or small series.<sup>[1]</sup> Ureteric herniation may be inguinal, femoral, thoracic, and parailiac.<sup>[2,3]</sup> Authors reported that 42% of the cases involved the inguinoscrotal region.<sup>[2]</sup> Ureteric hernia is also reported as spontaneous, postoperative or as a complication of renal transplantation.<sup>[1]</sup> Ureteral herniation presents as a groin mass usually asymptomatic although many cases describe association with dysuria, hematuria, and hydronephrosis.<sup>[4-6]</sup>

Paraperitoneal ureteric hernia constitutes the 80% of inguinoscrotal ureteric hernias. The hernia has the classical aspect of an indirect hernia; it is formed by the sac anteromedially that contain viscera that make up the wall of the sac, and the ureter lying posterolaterally. The ureter slides into the canal drawn by the posterior peritoneum that follows the herniated viscera. Paraperitoneal hernias are more common in men, usually located on the right side, are often large in size, usually reducible and rarely symptomatic. There is not a clear association with kidney or ureteric abnormalities.<sup>[2,3,7]</sup>

On the other hand, extraperitoneal hernias regard the 20% of inguinoscrotal herniation of the ureter.<sup>[6]</sup> No sac exists, and the only organ found is the ureter. The hernia is often accompanied by the large amount of retroperitoneal fat, is often nonreducible, usually small and commonly associated with urinary symptoms. Authors consider this type of hernia congenital and related to developmental abnormalities of differentiation of the ureter from the Wolffian duct.<sup>[2]</sup> The ureter slides along with the testis into the scrotum; a process also favored by adhesions between the ureter and genitoinguinal ligaments. Many extraperitoneal hernias have a congenital association to renal or ureteral malformation such as crossed renal ectopia or nephroptosis.<sup>[7]</sup> However, in our case the hernia



**Figure 2:** The ureter identified into the herniated retroperitoneal fat

was sizable, partially reducible and was no associated with urinary symptoms. No associations with renal or ureteral anatomical malformations were identified as well.

The diagnosis of ureteral hernia is often missed due to lack of urinary symptoms or signs or symptoms that could lead doctors to apply an extended preoperative work up. Although computed tomography may determine the type and the contents of hernias and the intravenous urography may determine abnormalities before surgery, they are not justifiable on every inguinal hernia repair.<sup>[8]</sup>

## CONCLUSION

Considering the fact that ureteric injuries are serious complications and require additional surgical approaches, we emphasize the high index of suspicion needed by surgeons when repairing hernias identifying gross amount of sliding fat and resecting fat trying to reduce hernia into the abdomen. Furthermore, surgeons need to have a heightened awareness of unusual structures in groin hernias.

## Financial support and sponsorship

Nil.

## Conflict of interest

There are no conflicts of interest.

## REFERENCES

1. Odisho AY, Freise CE, Tomlanovich SJ, Vagefi PA. Inguinal herniation of a transplant ureter. *Kidney Int* 2010;78:115.
2. Hwang CM, Miller FH, Dalton DP, Hartz WH. Accidental ureteral ligation during an inguinal hernia repair of patient with crossed fused renal ectopia. *Clin Imaging* 2002;26:306-8.
3. Giglio M, Medica M, Germinale F, Raggio M, Campodonico F, Stubinski R, *et al.* Scrotal extraperitoneal hernia of the ureter: Case report and literature review. *Urol Int* 2001;66:166-8.
4. Golgor E, Stroszczyński C, Froehner M. Extraperitoneal herniation of the ureter: A rare case of recurrence after hernia repair. *Urol Int* 2009;83:113-5.

5. Ansari K, Keramati MR, Rezaei Kalantari K, Jafari M, Godazandeh G, Pakzad M. Gross hematuria as the presentation of an inguinoscrotal hernia: A case report. *J Med Case Rep* 2011;5:561.
6. McKay JP, Organ M, Bagnell S, Gallant C, French C. Inguinoscrotal hernias involving urologic organs: A case series. *Can Urol Assoc J* 2014;8:E429-32.
7. Rocklin MS, Apelgren KN, Slomski CA, Kandzari SJ. Scrotal incarceration of the ureter with crossed renal ectopia: Case report and literature review. *J Urol* 1989;142:366-8.
8. Sharma RK, Murari K, Kumar V, Jain VK. Inguinoscrotal extraperitoneal herniation of a ureter. *Can J Surg* 2009;52:E29-30.

Access this article online	
<b>Quick Response Code:</b>	<b>Website:</b> <a href="http://www.jnsbm.org">www.jnsbm.org</a>
	<b>DOI:</b> 10.4103/0976-9668.166126