



Contents lists available at ScienceDirect

International Journal of Surgery Case Reports

journal homepage: www.casereports.com

A first reported case of metastatic anorectal amelanotic melanoma with a marked response to anti-PD-1 antibody nivolumab: A case report



Katsuji Tokuhara^{a,*}, Kazuyoshi Nakatani^a, Hirotsugu Tanimura^b, Kazuhiko Yoshioka^a, Takahiro Kiyohara^b, Masanori Kon^a

^a Department of Surgery, Kansai Medical University, 10-15 Fumizono, Moriguchi, Osaka, 570-8507, Japan

^b Department of Dermatology, Kansai Medical University, 10-15 Fumizono, Moriguchi, Osaka, 570-8507, Japan

ARTICLE INFO

Article history:

Received 16 December 2016

Received in revised form 13 January 2017

Accepted 14 January 2017

Available online 23 January 2017

Keywords:

Anorectal melanoma

Amelanotic melanoma

Nivolumab

Anti-PD-1 antibody

ABSTRACT

INTRODUCTION: Anorectal amelanotic melanoma (AAMM) is a rare disease with poor prognosis. A standard treatment strategy for AAMM has not been established.

PRESENTATION OF CASE: We report a case of successful treatment of AAMM with nivolumab. A 67-year-old man was referred for colonoscopy which revealed type I tumor in the rectum. AAMM was diagnosed with immunostaining histopathological biopsy findings. Enhanced computed tomography (ECT) revealed the rectal tumor without distant organ metastasis. We performed laparoscopy-assisted abdominoperineal resection. ECT at three months after surgery revealed liver metastases and right ischial bone metastasis. Although we had started dacarbazine monotherapy, black spots that were suspicious of skin metastases had appeared on systemic skin. Therefore, we started nivolumab therapy. ECT at 3 months after initiation of nivolumab showed shrinkage of liver metastasis. We have continued strict follow-up every 2 months and checked no oncologic progression at 17 months after initiation of nivolumab.

DISCUSSION: The anti-PD-1 antibody have improved prognosis of malignant melanoma. However, there are no reports of nivolumab for treatment of AAMM.

CONCLUSIONS: Our patient is the first reported case of AAMM treated with nivolumab. We consider that nivolumab will be effective for non-cutaneous malignant melanoma.

© 2017 The Authors. Published by Elsevier Ltd on behalf of IJS Publishing Group Ltd. This is an open access article under the CC BY-NC-ND license (<http://creativecommons.org/licenses/by-nc-nd/4.0/>).

1. Introduction

Anorectal malignant melanoma (AMM) is a rare disease with poor prognosis because of early hematogenous and lymphatic metastases [1]. Although surgery, chemotherapy and radiotherapy have been performed for AMM, a standard treatment strategy has not been established. Here, we report a case of AMM that recurred in the liver and bone early after laparoscopic abdominoperineal resection (APR) with bilateral pelvic nodes dissection, which was treated with nivolumab, an antibody to programmed death (PD)-1. This case report is compliant with the SCARE Guidelines [2].

2. Presentation of case

A 67-year-old man was referred to our hospital to determine the cause of his bloody stools. Colonoscopy revealed an elevated tumorous lesion that was similar to type 1 tumor located in the lower rectum (Fig. 1a, b). The surface of this tumor was covered by normal rectal mucosa and there was a black spot near the tumor (Fig. 1b, c). Thoracic–abdominal enhanced computed tomography (ECT) showed the wall thickness of the left anterior side of the lower rectum and lymph node swelling suspicious of metastasis in the right side of the lateral pelvic node. T1 weighted imaging (WI) magnetic resonance imaging (MRI) showed the wall thickness with low signal intensity. Positron emission tomography (PET)–CT revealed the hot spot only in the lower rectum and no metastasis in other organs. The blood examination revealed no abnormalities, including level of carcinoembryonic antigen (CEA) and carbohydrate antigen 19-9 (CA19-9).

In histopathological findings, hematoxylin and eosin staining of the biopsy specimen revealed deeply stained polymorphic nuclei and eosinophilic nucleoli without melanin pigments. These findings were indicative of malignancy. Positive immunostaining of the

* Corresponding author.

E-mail addresses: tokuhark@takii.kmu.ac.jp (K. Tokuhara), nakataka@takii.kmu.ac.jp (K. Nakatani), tanimurh@takii.kmu.ac.jp (H. Tanimura), yoshiokk@takii.kmu.ac.jp (K. Yoshioka), kiyohart@takii.kmu.ac.jp (T. Kiyohara), kon@hirakata.kmu.ac.jp (M. Kon).

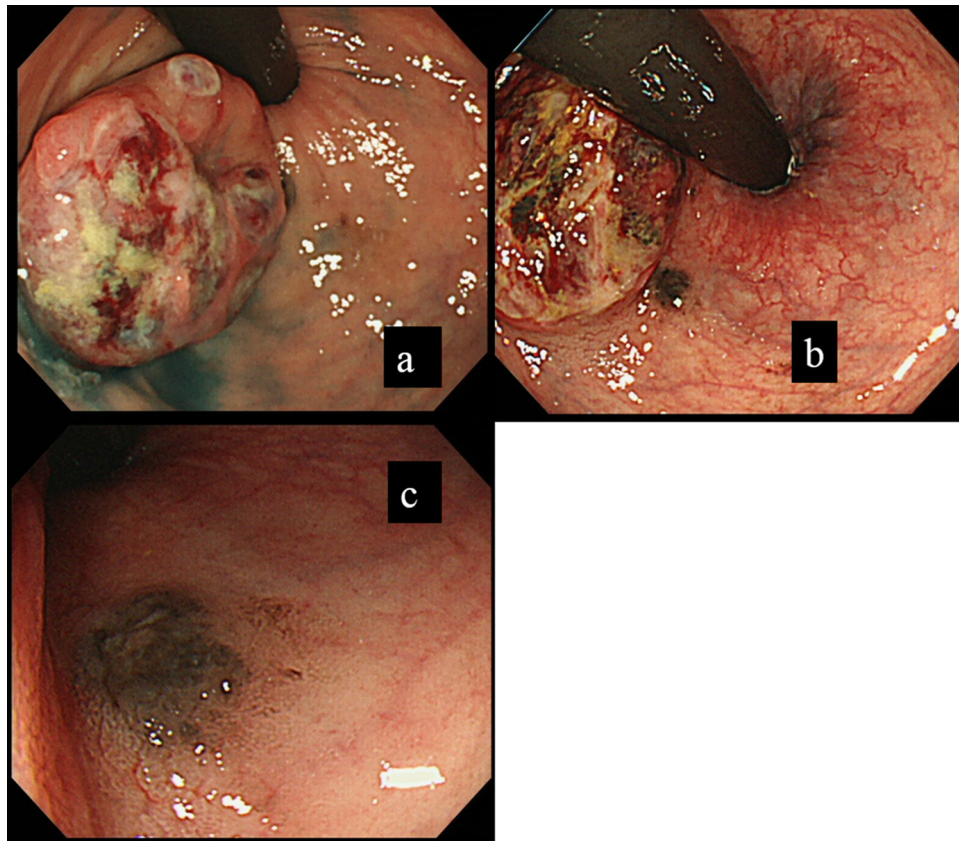


Fig. 1. Endoscopic findings.

Colonoscopy revealed an elevated tumorous lesion that was similar to type 1 tumor located in the lower rectum (Fig. 1a,b). The surface of this tumor was covered by normal rectal mucosa and there was a black spot near the tumor (Fig. 1c).

biopsy specimen for S-100 protein and Melan-A antibody led us to diagnose anorectal amelanotic melanoma (AAMM) in the lower rectum. After diagnosis, we confirmed that there were no lesions suspicious of melanoma in systemic skin. We diagnosed clinical stage IIIb AAMM [cT3,N3 M0(HOPOPULO); by Japanese Society for Cancer of the Colon and Rectum, 8th edition] of the lower rectum and performed laparoscopic APR with bilateral pelvic node dissection. The surgical stage of this tumor was II (sT3, N0, M0).

In the macroscopic findings of the resected specimen, there was type I tumor in the lower rectum and a small, black elevated lesion near this tumor. The histopathological findings showed that the tumor cells were solidly gathered and the boundary of the tumor was clear. The types of cell and nuclear fission were polymorphic, which indicated the proliferative potency of the tumor. There was no melanin pigment granules in the tumor (Fig. 2b). Immunostaining of the tumor was positive for Melan-A antibody (Fig. 2d) and HMB45 antibody (Fig. 2e). From the above findings, we diagnosed AAMM in the lower rectum. The depth of the main tumor was the muscularis propria (Fig. 2a) and there were no metastases of AAMM in the resected lymph nodes. The pathological stage of the main tumor was I [40 × 23 mm, pT2, ly0, v0, N0(0/17), PM0, DM0, RM0]. The black elevated lesion was AAMM and the depth of this tumor was the intraepithelial layer (Tis).

The patient made a smooth recovery and was discharged from our hospital on postoperative day 15. We did not initiate adjuvant chemotherapy because we performed curative surgery for AAMM. Three months after the operation, we performed ECT for postoperative surveillance, which revealed multiple liver metastases and right ischial bone metastasis (Fig. 3a, b). We suspected recurrence of AAMM, and we analyzed the level of 5-S-cysteinyldopa (5-S CD) in the peripheral blood and status of BRAF gene in the resected

specimen. The level of 5-S-CD was 5.5 nmol/L (reference value 1.5–8 nmol/L) and there was no BRAF mutation. Upon diagnosis of recurrent AAMM without BRAF mutation, we started dacarbazine therapy (1 g/m²), however, multiple black skin spots that were suspicious of skin metastasis appeared on the systemic skin. Therefore, we began administration of nivolumab (2 mg/kg), which is an anti-PD-1 antibody as second-line therapy because dacarbazine was not effective. ECT at 3 months after initiation of nivolumab showed shrinkage of liver and right ischial bone metastases (Fig. 3c, d). We are continuing nivolumab therapy because this therapy brings shrinkage of liver metastases and does not complicate adverse events. We have continued strict follow-up every 2 months and checked no oncologic progression at 17 months after initiation of nivolumab.

3. Discussion

AAMM is a malignant tumor of melanocytes and readily forms distant organ metastases. Although these tumors commonly appear in the skin, a few malignant melanomas occur in mucosa, such as eye, anorectum, esophagus, nasal cavity and vagina [3]. The occurrence rate of AAMM in Japan was reported as 4.6% among all systemic malignant melanoma cases and 0.38% among anorectal malignant disease [4]. The surface color of AAMM is often black; however, in a few cases, such as our case of AAMM, the surface color of the tumor is similar to that of the normal mucosa because a level of melanin pigment is low. In Japan, there were only 34 cases of AAMM from 1991 to 2014 [5], and the rate of AAMM was 26.4% among all cases of AMM [5]. The prognosis of AAMM was poor, with a 5-year overall survival (OS) rate of 4.3–17.4% [6,7]. Hamba H, et al. reported that

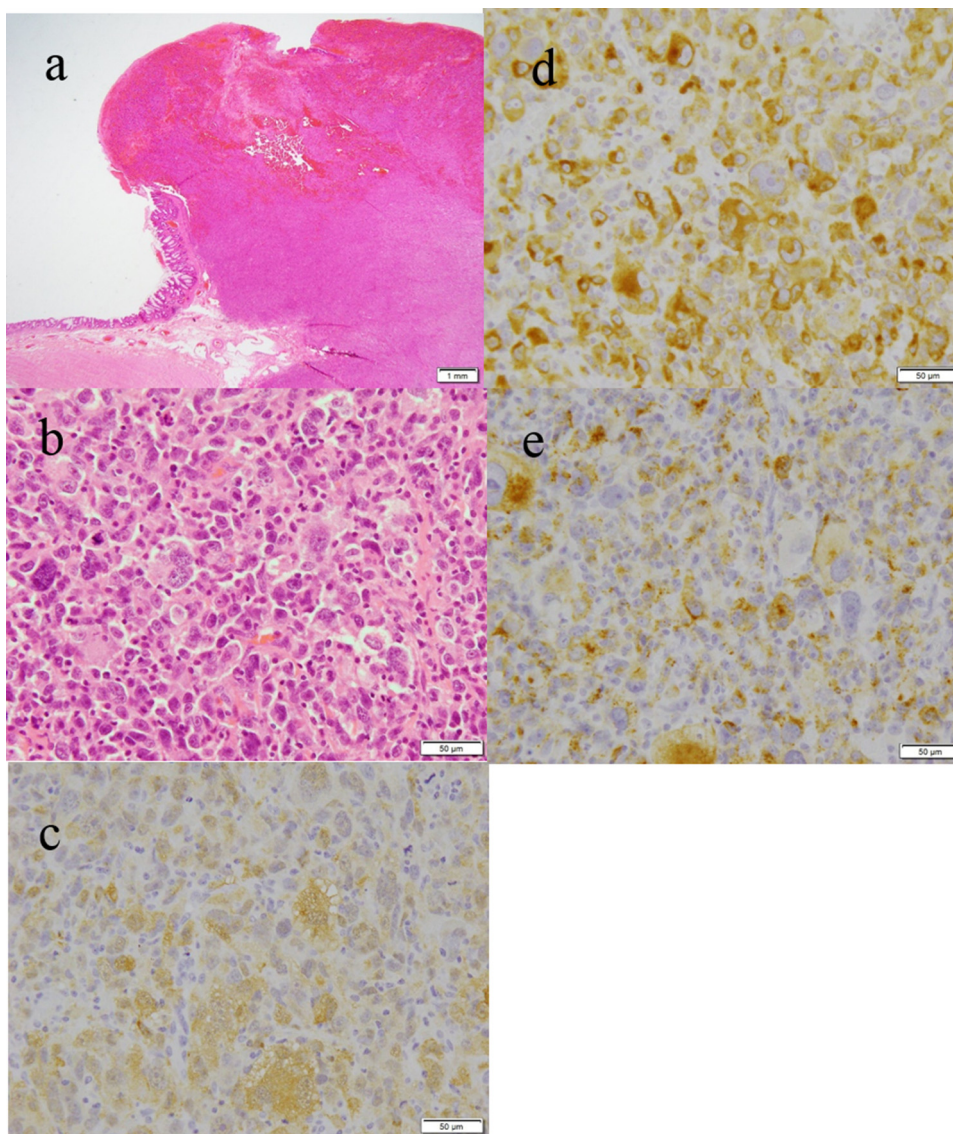


Fig. 2. Histopathological findings.

HE stained (Fig. 2a, $\times 12.5$). The depth of the main tumor was the muscularis propria. HE stained (Fig. 2b, $\times 400$) There was no melanin pigment granules in the tumor. Immunostaining of the tumor was positive for S100 antibody (Fig. 2c, $\times 400$) Melan-A antibody (Fig. 2d, $\times 400$) and HMB45 antibody (Fig. 2e, $\times 400$), so we diagnosed AAMM in the lower rectum.

there is no difference in long-term outcomes such as OS between AMM and AAMM [4].

To diagnose AMM at histopathological findings, it is necessary to find out containing melanin pigments at biopsy specimens. It is difficult to diagnose AAMM correctly because typically there are no melanin pigments such as in AMM. Therefore, pathological immunostaining has not been introduced in many cases of AAMM because the disease was not suspected. If the tumor is suspected of being digestive tract malignant melanoma, we must introduce immunostaining analysis, such as Melan-A antibody and HMB-45 antibody, of biopsy specimens because most malignant melanoma cells are positive for HMB45, Melan A and S100 protein, in spite of the lack of melanin pigments [8].

Conventionally, the standard therapy for AMM is complete surgical resection. As a surgical resection for AMM, APR and wide local excision (WLE) have been performed. David and Perakath recommended WLE when negative margins can be achieved and when this is technically feasible, and APR should be performed for large tumors where WLE is technically impossible because there is no dif-

ference in progression-free survival (PFS) and OS between APR and WLE [9]. In our case, we performed laparoscopic APR with bilateral pelvic node dissection because the right lateral pelvic node was suspected of tumor metastasis, the tumor was too large, and there was a small, black elevated lesion that was suspicious of AMM near the main tumor. There are no reports of laparoscopic lateral pelvic node dissection for AMM in Japan. We should judge the surgical procedure by tumor status, such as tumor size and presence of lymph node metastasis. In the future, we will need to analyze the postoperative outcomes to establish standard surgical procedures for AMM.

Conventionally, cytotoxic agents such as dacarbazine and DAC-Tam (combined dacarbazine, cisplatin, carmustine, and tamoxifen) have been used for metastatic malignant melanoma. However, it is hard to say that these therapies have improved prognosis. Recently, immune-checkpoint inhibitors have been developed and a few of these have been approved for chemotherapy of malignant melanoma. These inhibitors have improved the prognosis of malignant melanoma. Ipilimumab (antibody to cyto-

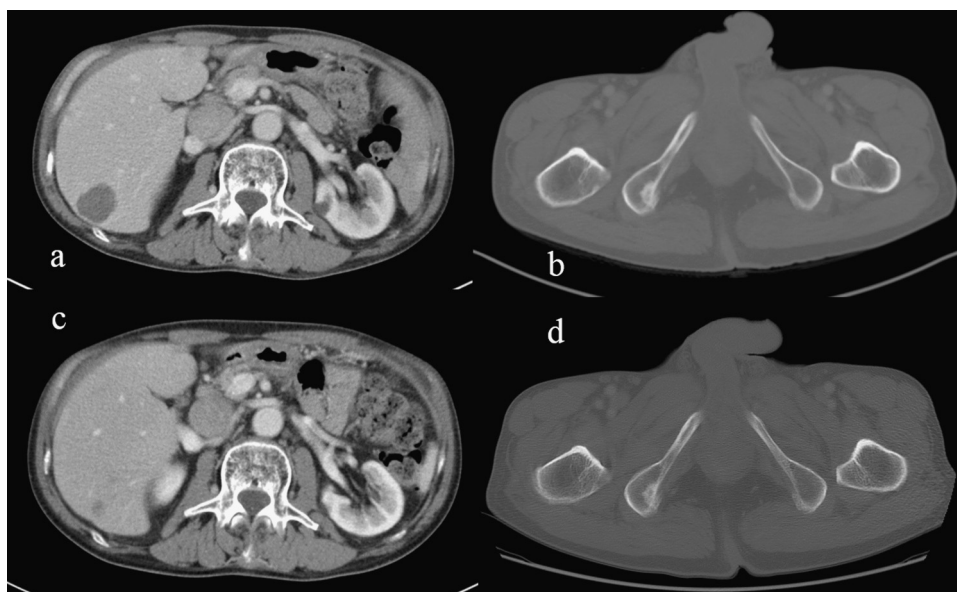


Fig. 3. Enhanced CT.

Three months after the operation, we performed ECT for postoperative surveillance, which revealed multiple liver metastases (Fig. 3a,b) and right ischial bone metastasis (Fig. 3a, b). ECT at 3 months after initiation of nivolumab showed reduction of liver and right ischial bone metastases (Fig. 3c, d).

toxic T-lymphocyte-associated protein-4), vemurafenib (anti-BRAF antibody), vemurafenib (anti-BRAF antibody), trametinib (MEK inhibitor) was approved by US Food and Drug Administration in 2013, and pembrolizumab and nivolumab [10,11] (anti-PD-1 antibodies) were approved in 2014, and can be used for treatment of malignant melanoma in the US. In Japan, nivolumab was approved in July 2014, for the first time worldwide, and vemurafenib was approved in December 2014.

In our case, we administered nivolumab because there was no BRAF mutation in the resected specimen. Robert et al. reported that the 1-year OS rate after nivolumab treatment of malignant melanoma was higher than that of dacarbazine (72.9% vs 42.1%, hazard ratio=0.42) [11]. In spite of dramatic changes in the treatment of malignant melanoma, there is no reported case of nivolumab treatment of AMM. In our case, we administered dacarbazine as first-line therapy, however, 1 month after initiation, multiple black skin spots those were suspicious of skin metastasis appeared. We considered that dacarbazine therapy was not effective, and we started nivolumab as second-line therapy. Nivolumab markedly reduced liver metastasis. Our patient is the first with AMM to be treated by anti-PD-1 antibody, nivolumab, and this therapy was effective in controlling metastatic AAMM.

Our case was rare and important because the anti-tumor effect of anti PD-1 antibody for AMM was confirmed. In the future, multimodal therapy combining immune-checkpoint inhibitors, surgery and radiotherapy could improve the prognosis of AMM.

4. Conclusions

We report the first case of AARM to be treated with anti-PD-1 antibody, nivolumab. We consider that multimodal therapy including nivolumab will be effective for non-cutaneous malignant melanoma.

Conflict of interests

The authors declare that they have no conflict of interests.

Funding

None

Ethical approval

N/A.

Consent

I got written informed consent from the patient for publication of this case report.

Author's contribution

KT made substantial contribution to conception, conducted a literature search and drafted the manuscript. KT, KN and YT made the contribution for acquisition of data. KT, KN and KY performed the operation. KT, KN, YT, KY, and MK reviewed the manuscript and gave final approval for publication. All authors read and approved the final manuscript.

Guarantor

The Guarantors of this manuscript are Katsuji Tokuhara and Prof. Masanori Kon.

References

- [1] H. Zhu, D. Dong, F. Li, et al., Clinicopathologic features and prognostic factors in patients with non-cutaneous malignant melanoma: a single-center retrospective study of 71 cases, *J. Dermatol.* (2015), <http://dx.doi.org/10.1111/ijd.12745> (Epub ahead of print).
- [2] R.A. Agha, A.J. Fowler, A. Saetta, I. Barai, S. Rajmohan, Orgill DP and the SCARE Group. The SCARE Statement: Consensus-based surgical case report guidelines, *Int. J. Surg.* 34 (2016) 180–186.
- [3] A.E. Chang, L.H. Karnell, H.R. Menck, The National Cancer Data Base report on cutaneous and non-cutaneous melanoma: a summary of 84,836 cases from the past decade, *Am. Coll. Surg. Comm. Cancer Am. Cancer Soc. Cancer* 83 (1998) 1664–1678.
- [4] H. Hamba, M. Higashino, M. Hai, et al., Report of a case of Malignant Melanoma of the Anorectum, and Review of 154 cases in Japan, *Nippon Rinsyo Geka Igakukai Zassi* 53 (1992) 154–158 (in Japanese).

- [5] G. Kuwata, K. Koizumi, H. Egashira, et al., A case report of ulcerated primary amelanotic anorectal melanoma, *I to Cho*. 47 (2012) 403–412 (in Japanese).
- [6] K. Shimada, W. Igarashi, Y. Horino, et al., Investigative analysis of case studies of digestive tract malignant melanoma in Japan, *Geka Shinryo* 80 (1999) 1213–1222 (in Japanese).
- [7] T. Nakamura, H. Ide, Malignant melanoma of the alimentary tract, *Gan To Kagaku Ryoho* 30 (2003) 619–625 (in Japanese).
- [8] Jinfeng Zheng, Haiying Mo, Shufang Ma, et al., Clinicopathological findings of primary esophageal malignant melanoma: report of six cases and review of literature, *Int. J. Clin. Exp. Pathol.* 7 (2014) 7230–7235.
- [9] A.W. David, B. Perakath, Management of anorectal melanomas: a 10-year review, *Trop. Gastroenterol.* 28 (2007) 76–78.
- [10] S.L. Topalian, M. Sznol, D.F. McDermott, et al., Survival, durable tumor remission, and long-term safety in patients with advanced melanoma receiving nivolumab, *J. Clin. Oncol.* 32 (2014) 1020–1030.
- [11] C. Robert, G.V. Long, B. Brady, et al., Nivolumab in previously untreated melanoma without BRAF mutation, *N. Engl. J. Med.* 372 (2015) 320–330.

Open Access

This article is published Open Access at [sciencedirect.com](https://www.sciencedirect.com). It is distributed under the [IJSCR Supplemental terms and conditions](#), which permits unrestricted non commercial use, distribution, and reproduction in any medium, provided the original authors and source are credited.