



ELSEVIER

Contents lists available at [ScienceDirect](https://www.sciencedirect.com)

Trauma Case Reports

journal homepage: www.elsevier.com/locate/tcr

Case Report

Compartment syndrome after transtibial anterior cruciate ligament reconstruction: A case report

Tsuneari Takahashi^{a,*}, Mikiko Handa^a, Katsushi Takeshita^b^a Department of Orthopedic Surgery, Ishibashi General Hospital, Shimotsuke, Japan^b Department of Orthopedic Surgery, School of Medicine, Jichi Medical University, Shimotsuke, Japan

ARTICLE INFO

Keywords:

Anterior cruciate ligament reconstruction
 Compartment syndrome
 Debridement
 Fasciotomy
 Negative-pressure wound therapy

ABSTRACT

Compartment syndrome is a rare complication after anterior cruciate ligament (ACL) reconstruction. This is one of the most devastating complications after surgery of the lower limb, with certain risks of renal failure, shock, and even death. We report a case of compartment syndrome that occurred 12 h after ACL reconstruction. A healthy 67-year-old male who underwent transtibial ACL reconstruction using autogenous hamstring tendon graft complained of progressive intense pain, paresthesia, and paresis. He had a pallid aspect and taut, shiny skin with several blisters around the medial aspect of the lower limb. Computed tomography revealed a hematoma that originated from the tibial bone tunnel. The patient was immediately referred for an urgent decompression fasciotomy. Hematoma debridement, medial fasciotomy, and negative-pressure wound therapy were performed. The patient recovered well and received routine postoperative physiotherapy.

Introduction

Despite its technical evolution, anterior cruciate ligament (ACL) reconstruction surgery still presents some potential complications. The most common reported complications are re-injury, anterior knee pain, and postoperative residual laxity. Compartment syndrome is rare after ACL reconstruction and one of the most devastating complications after surgery of the lower limb, with certain risks of renal failure, shock, and even death [1]. A recent literature search showed only a few relevant case reports [2,3], and pneumatic tourniquet pressure and anesthetic nerve blocks might have been responsible in those cases. We report a case of compartment syndrome after transtibial ACL reconstruction performed with the patient under general anesthesia without pneumatic tourniquet application. The patient exhibited progressive pain and symptoms of possible compartment syndrome 12 h after surgery, which necessitated urgent surgical intervention for debridement of a hematoma and a fasciotomy followed by application of negative-pressure wound therapy (NPWT) [4].

Case presentation

A healthy 67-year-old male presented to the Knee Sports Traumatology clinic of our hospital with complaints of chronic pain and knee instability when descending stairs. ACL deficiency was diagnosed on clinical findings, including a positive Lachman test result

* Corresponding author at: Department of Orthopedic Surgery, Ishibashi General Hospital, Shimotsuke, 1-15-4 Shimokoyama, 329-0502, Japan.
 E-mail address: tsuneari9@jichi.ac.jp (T. Takahashi).

<https://doi.org/10.1016/j.tcr.2021.100603>

Accepted 30 December 2021

Available online 3 January 2022

2352-6440/© 2022 The Authors. Published by Elsevier Ltd. This is an open access article under the CC BY-NC-ND license

(<http://creativecommons.org/licenses/by-nc-nd/4.0/>).

and positive finding of rotatory instability by the first author. Magnetic resonance imaging findings revealed a loose bundle of ACL and a degenerated posterior portion of the medial meniscus.

Surgical procedure of transtibial behind ridge-ACL reconstruction

The patient was positioned supine, and the operative knee was held in the leg-drop position with 90° of flexion with the patient under general anesthesia without application of a pneumatic tourniquet. Standard anterolateral and anteromedial portals were made. The ipsilateral semitendinosus tendon was extracted and used for the graft. A femoral bone tunnel was created behind the resident ridge [5], and remnant tissue was preserved as much as possible. The graft was fixed to the femoral cortex by flipping the suspensory fixation device, and a turnbuckle stapling graft fixation technique was used [6]. Medial and lateral meniscus repairs using double vertical stacked sutures and all inside devices were performed [7]. No intra-articular massive bleeding suspected of being related to vascular injury was observed during the surgery.

The patient complained of progressive intense pain, paresthesia, and paresis, and he exhibited a pallid aspect and taut shiny skin with several blisters around the medial aspect of the lower limb in the orthopedic ward 12 h after surgery. Enhanced computed tomography revealed that the hematoma originated from a tibial bone tunnel, which had compressed the medial calf compartment (Fig. 1), indicating possible compartment syndrome. The patient was immediately referred for an urgent decompression fasciotomy.

Urgent decompression fasciotomy surgical procedure

Under intubated general anesthesia, a medial longitudinal skin incision was made, a subcutaneous hematoma of ≤ 250 g (Fig. 2) was extracted, and a medial fasciotomy was performed to release the medial leg compartment (Fig. 3). No massive bleeding was observed, and primary wound closure with application of NPWT (PICO 7, Smith and Nephew Wound Management, Japan) was performed.

Postoperative management

The patient's intense pain, paresthesia, paresis, pallid aspect, and taut and shiny skin all recovered immediately after surgery. Postoperative rehabilitation resumed the day after surgery, and the wound healed uneventfully within 2 weeks after surgery (Fig. 4). A knee brace was applied at 10° fixed knee flexion for 12 weeks postoperatively. Partial weight bearing was permitted for 2 weeks postoperatively and was allowed to gradually increase to full weight bearing at 4 weeks postoperatively. Jogging was permitted at 3 months postoperatively after the patient had recovered adequate muscle strength relative to that of the uninjured knee [8]. The patient continued to have some altered sensation at the incision. At the time of the latest follow-up 4 months after surgery, sensation at the incision had returned to normal.

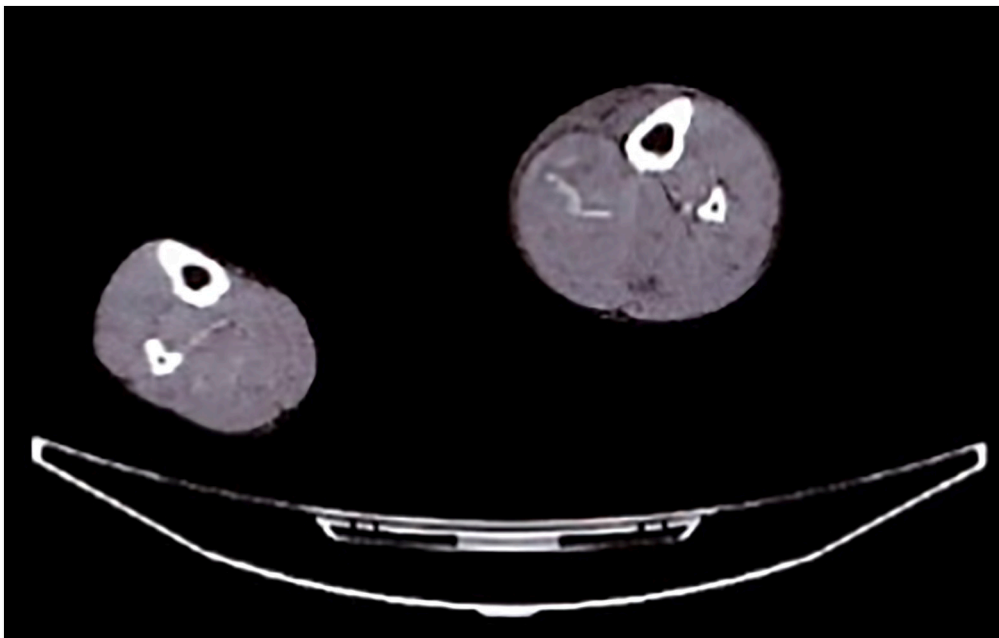


Fig. 1. Enhanced computed tomography showing a hematoma originated from the tibial bone tunnel that is compressing the medial calf compartment.



Fig. 2. Subcutaneous hematoma taken from the medial compartment.

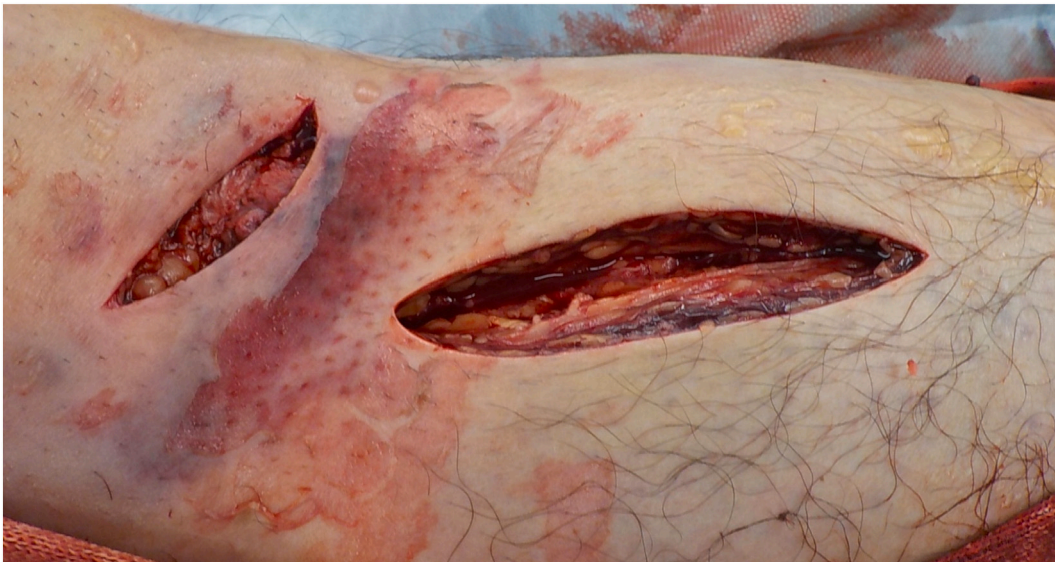

Fig. 3. Medial fasciotomy to release the medial leg compartment.

Discussion

This case showed that compartment syndrome occurred 12 h after ACL reconstruction even though the surgery did not use a pneumatic tourniquet or regional anesthesia. Urgent debridement of hematoma and medial fasciotomy followed by application of NPWT led to uneventful wound healing and favorable clinical outcome. Injury to popliteal artery or anterior tibial artery may occur when creating femoral bone tunnel in transtibial ACL reconstruction. Early recognition of compartment syndrome and intervention are crucial to prevent serious damage. Obstructive or semi-obstructive arterial disorder should be considered as differential diagnoses because these cause similar complaints [9]. Acute compartment syndrome is usually suspected from its classical presentation with the six P's: pain, pulselessness, pallor, paresthesia paralysis, and poikilothermia. These signs and symptoms are caused by rising intra-compartmental pressure and are time-dependent [10]. A monitoring device for intra-compartmental pressure was not available in our hospital, but diagnosis was mainly based on clinical observations, so intra-compartmental pressure was not required [10]. Therefore, we could treat the patient immediately after onset. Compartment syndrome is a rare complication after ACL reconstruction,

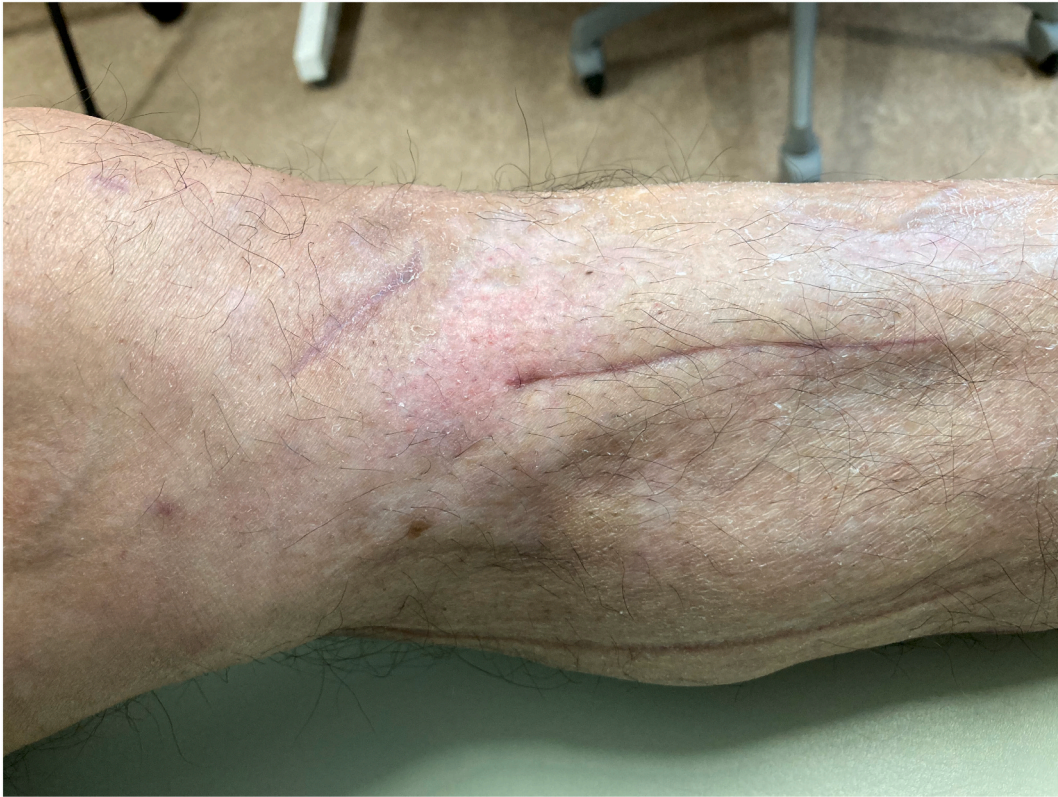

Fig. 4. Postoperative wound 2 weeks after surgery.

especially when a pneumatic tourniquet is not applied and the patient is placed under general anesthesia. Despite its rarity, surgeons should consider compartment syndrome as a differential diagnosis for patients with symptoms matching the 6Ps after ACL reconstruction.

Declaration of competing interest

None.

Acknowledgments

None.

References

- [1] N.P. Sheth, B. Sennett, J.S. Berns, Rhabdomyolysis and acute renal failure following arthroscopic knee surgery in a college football player taking creatine supplements, *Clin. Nephrol.* 65 (2006) 134–137.
- [2] J.S. Filho, L.A. Ramos, J. Sayum, et al., Leg's compartment syndrome after reconstruction of the anterior cruciate ligament: case report, *Rev. Bras. Ortop.* 46 (2011) 730–732.
- [3] B.J. Kindle, N. Murthy, K. Stolp, Compartment syndrome with mononeuropathies after anterior cruciate ligament reconstruction, *Am. J. Phys. Med. Rehabil.* 94 (2015) e37–e41.
- [4] M.E. Hake, J. Etscheidt, V.P. Chadayammuri, J.M. Kirsch, C. Mauffrey, Age and dressing type as independent predictors of post-operative infection in patients with acute compartment syndrome of the lower leg, *Int. Orthop.* 41 (2017) 2591–2596.
- [5] T. Takahashi, T. Saito, T. Kubo, et al., Evaluation of tibial tunnel location with the femoral tunnel created behind the resident's ridge in transtibial anterior cruciate ligament reconstruction, *J. Knee Surg. (Jan 22.)* (2021), <https://doi.org/10.1055/s-0040-1722568> [Online ahead of print].
- [6] T. Takahashi, M. Kimura, K. Hagiwara, T. Ohsawa, K. Takeshita, The effect of remnant tissue preservation in anatomic double-bundle acl reconstruction on knee stability and graft maturation, *J. Knee Surg.* 32 (2019) 565–576.
- [7] T. Takahashi, M. Kimura, K. Takeshita, All- inside arthroscopic meniscal stacked suture repair for hypermobile lateral meniscus with FASTFIX 360, *Arthrosc. Tech.* 10 (2021) e1757–e1761.
- [8] T. Ohsawa, M. Kimura, Y. Kobayashi, K. Hagiwara, H. Yorifuji, K. Takagishi, Arthroscopic evaluation of preserved ligament remnant after selective anteromedial or posterolateral bundle anterior cruciate ligament reconstruction, *Arthroscopy* 28 (2012) 807–817.
- [9] D. Kane, P.V. Balint, R. Gibney, B. Bresnihan, R.D. Sturrock, Differential diagnosis of calf pain with musculoskeletal ultrasound imaging, *Ann. Rheum. Dis.* 63 (2004) 11–14.
- [10] S. Bandapaati, R.N. Mitrakrishnan, Idiopathic spontaneous compartment syndrome of the right lower limb: a case report, *J. Med. Case Rep.* 15 (2021) 100.