



A Rare Case of COVID-19-Associated Solitary *Aspergillus* Brain Abscess

Rajeev Mandaka Parambil¹ Binoy Damodar Thavara¹ Saji Francis² Poornima Mankara Valsan³
 Byjo Valiyaveetil Jose¹ Vishal Mangla¹ Harikrishnan Sreenivasan¹ Shanavas Cholakkal¹

¹Department of Neurosurgery, Government Medical College, Kozhikode, Kerala, India

²Department of Pathology, Government Medical College, Kozhikode, Kerala, India

³Department of Microbiology, Baby Memorial Hospital, Kozhikode, Kerala, India

Address for correspondence Binoy Damodar Thavara, MRCS, MCh, Department of Neurosurgery, Government Medical College, Kozhikode, 673008, Kerala, India (e-mail: drbinoytd@gmail.com).

AJNS 2023;18:336–341.

Abstract

Surgically operated case of solitary *Aspergillus* brain abscess caused by *Aspergillus fumigatus* in coronavirus disease 2019 (COVID-19) patient is not reported. The authors report a case of 33-year-old diabetic female patient presented with generalized seizure followed by left hemiparesis. Patient was treated with steroids for COVID-19 pneumonia. Initial imaging revealed a right frontal lobe infarct that later confirmed as a case of frontal lobe abscess. Patient underwent craniotomy and thick yellow pus was drained. Abscess wall was excised. Postoperatively patient improved with Glasgow coma scale 15/15 and Medical Research Committee grade 5 power of all limbs. Microbiological examination of pus was done. The gram stain showed numerous pus cells with acute angle branching hyphae. Gomori methenamine silver (GMS) preparation showed filamentous black colored hyphae. Mycelial colonies appeared on chocolate agar after 48 hours of incubation. Cellophane tape mount from the plate showed conical shaped vesicle with conidia arising from the upper third of vesicle. Light green velvety colonies appeared on Sabouraud Dextrose Agar that later turned into smoky green. The isolate was identified as *Aspergillus fumigatus*. The hematoxylin and eosin stain of abscess wall section showed extensive areas of necrosis with few fungal hyphae. GMS stain of abscess wall showed fungal hyphae that are septate and showing acute angled branching which are consistent with *Aspergillus* species. Patient was treated with voriconazole. Imaging done after 8 months of surgery revealed no residue. Surgical excision of life-threatening solitary *Aspergillus* brain abscess along with antifungal medication voriconazole carries good result. The authors believe that decreased immunity in patient has contributed to the development of this rare disease. This is a rarest case of surgically operated solitary brain abscess caused by *Aspergillus fumigatus* in COVID-19 patient.

Keywords

- ▶ *Aspergillus fumigatus*
- ▶ brain abscess
- ▶ COVID-19
- ▶ diabetes
- ▶ fungal infection

article published online
June 6, 2023

DOI <https://doi.org/10.1055/s-0043-1768570>.
ISSN 2248-9614.

© 2023. Asian Congress of Neurological Surgeons. All rights reserved.

This is an open access article published by Thieme under the terms of the Creative Commons Attribution-NonDerivative-NonCommercial-License, permitting copying and reproduction so long as the original work is given appropriate credit. Contents may not be used for commercial purposes, or adapted, remixed, transformed or built upon. (<https://creativecommons.org/licenses/by-nc-nd/4.0/>)

Thieme Medical and Scientific Publishers Pvt. Ltd., A-12, 2nd Floor, Sector 2, Noida-201301 UP, India

Introduction

Cerebral aspergillosis is the most lethal manifestation of infection due to *Aspergillus* species that arises most commonly as hematogenous dissemination from a pulmonary focus, direct extension from paranasal sinus infection, or direct inoculation through trauma and surgery of the central nervous system (CNS).¹

Twenty-six patients with autopsy-proven CNS aspergillosis were reviewed. The most common presenting clinical symptoms of CNS aspergillosis were fever and a stroke-like syndrome. Risk factors for developing CNS aspergillosis included neutropenia, immunosuppressive therapy, low CD4 counts, and retransplantation. Spinal fluid findings were nondiagnostic. Computed tomography (CT) and magnetic resonance imaging (MRI) scans of the head showed low-density lesions or hemorrhagic infarctions. Most aspergillosis cases occurred in the setting of widely disseminated disease commonly arising from the lung. Pathologically, multiple areas of necrosis throughout the brain were seen. *Aspergillus* invasion of blood vessel walls was seen microscopically.² Voriconazole is currently considered the standard of treatment of CNS aspergillosis with liposomal amphotericin B being the next best alternative. Neurosurgical resection of infected cerebral tissue in addition to antifungal therapy is frequently performed in patients with CNS aspergillosis to prevent neurological deficits and improve outcome.¹

The authors report a case of frontal lobe *Aspergillus* brain abscess in a 33-year-old diabetic female patient treated for coronavirus disease 2019 (COVID-19) pneumonia. Surgically operated solitary brain abscess caused by *Aspergillus fumigatus* is not reported in COVID-19 patient. Surgical excision of life-threatening *Aspergillus* brain abscess along with anti-fungal drug voriconazole carries good outcome.

Case Report

A 33-year-old diabetic female patient presented to another hospital with a history of fever and cough of 10 days duration. She also had breathing difficulty of 8 days duration. She was tested positive for COVID-19 virus. She was diagnosed as having COVID-19 pneumonia. She had uncontrolled diabetes with random blood sugar of 316 mg/dL. She was treated with oxygen therapy, ceftriaxone, dexamethasone, heparin, favipiravir, and insulin. Her symptoms were improved and discharged after 2 weeks of admission. Two days later she developed generalized seizure and admitted to our center. Examination revealed normal Glasgow coma scale (GCS) and Medical Research Committee (MRC) grade 5 power of all limbs. Plain CT head (►Fig. 1) showed hypodense lesion in right frontal lobe suggestive of infarct. MRI brain taken after 3 days showed a well-defined intra-axial lesion (4.7 × 3.1 × 3.4 cm) in the right frontal lobe. It was heterogeneously hypointense on T1 (►Fig. 2A), heterogeneously hyperintense on T2 (►Fig. 2B) with peripheral irregular incomplete rim enhancement on contrast MRI (►Fig. 3A–C). Diffusion restriction was noted in diffusion-

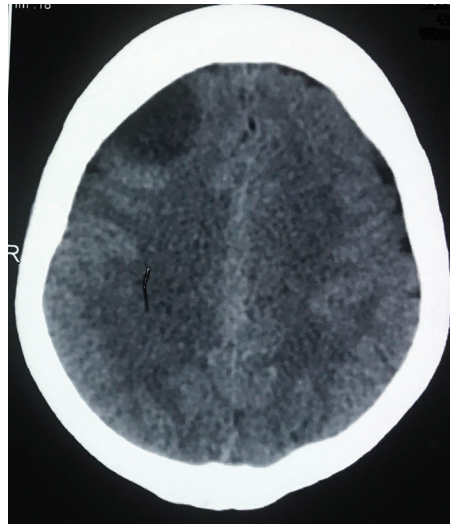


Fig. 1 Plain computed tomography head showing hypodensity in right frontal lobe.

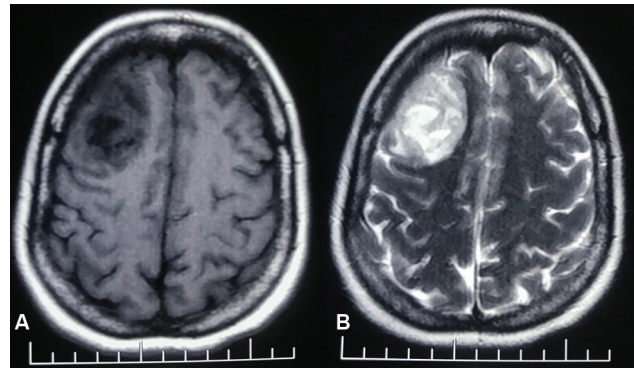


Fig. 2 (A) T1-weighted magnetic resonance imaging (MRI) brain showing heterogeneously hypointense lesion in right frontal lobe. (B) T2-weighted MRI brain showing heterogeneously hyperintense lesion in right frontal lobe.

weighted image. MR venogram was normal. At 1 week of admission, patient developed headache followed by left-sided weakness (MRC grade 4 power of left upper and lower limbs). Following this, contrast CT head (►Fig. 4A,B) was taken that showed right frontal 4.1 × 5.2 × 4.5 cm hypodense area with peripheral rim enhancement, suggestive of abscess. Contrast-enhanced CT thorax (►Fig. 5) showed bilateral ground glass opacities, consolidative changes, and interlobular septal thickening predominantly in the peripheries of the lung suggestive of viral pneumonia likely post-COVID-19. Patient underwent right frontoparietal craniotomy. Abscess wall was opened and thick yellow pus was drained. Abscess wall was excised. Patient was treated with antibiotics and antiepileptics. Postoperatively patient improved with GCS 15/15 and grade 5 power (MRC) of all limbs. Postoperative contrast CT head (►Fig. 4C) showed excision of right frontal lobe abscess. CT of paranasal sinuses was normal (►Fig. 6). Contrast MRI brain taken 8 months after surgery showed only gliotic changes in right frontal lobe without recurrence (►Fig. 7).

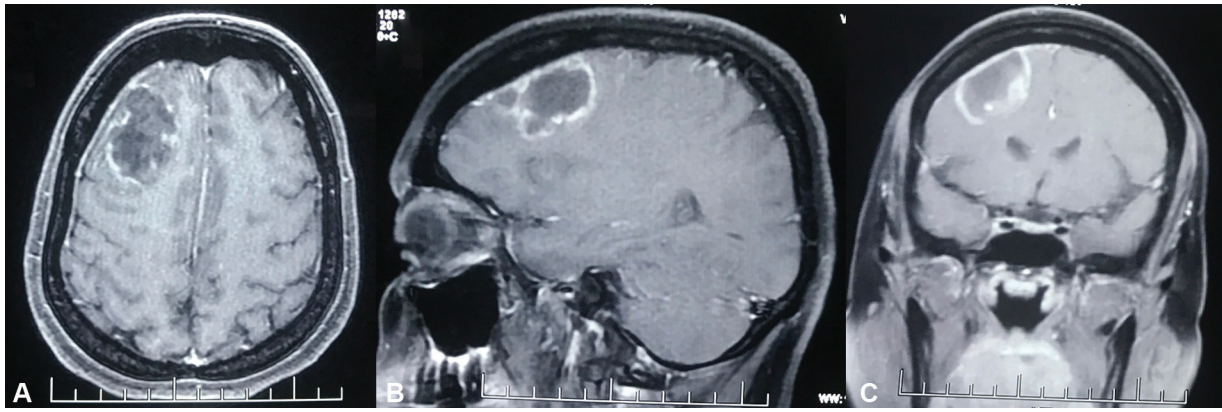


Fig. 3 Axial (A), sagittal (B), and coronal (C) contrast magnetic resonance imaging brain showing peripheral irregular incomplete rim enhancing right frontal lobe lesion.

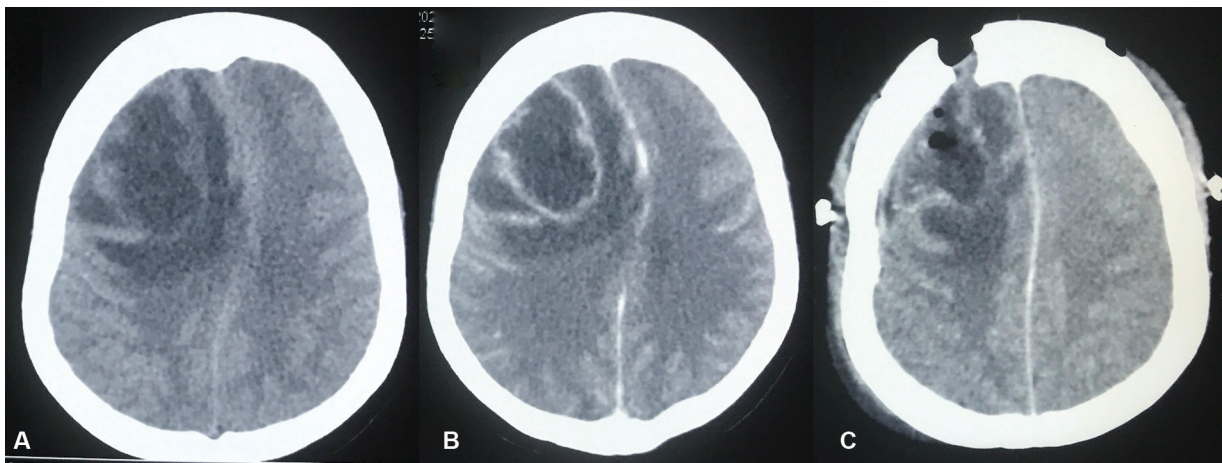


Fig. 4 (A) Plain computed tomography (CT) head showing right frontal hypodense area with peripheral isodense rim. (B) Contrast CT head showing right frontal hypodense area with peripheral rim enhancement suggestive of abscess. (C) Postoperative contrast CT head showing excision of right frontal lobe abscess with postoperative changes.

Microbiological Examination of Pus

The microscopic examination of the gram stain showed numerous pus cells with acute angle branching hyphae (►Fig. 8A). Gomori methenamine silver (GMS) preparation also highlighted filamentous black colored hyphae

(►Fig. 8B). A part of the pus sample was cultured on Sabouraud Dextrose Agar (SDA) containing chloramphenicol (0.05 g/L), 5% sheep blood agar, chocolate agar, and MacConkey agar. Mycelial colonies appeared on chocolate agar after 48 hours of incubation (►Fig. 8C). Cellophane tape mount from the plate showed conical-shaped vesicle with conidia arising from the upper third of vesicle. The isolate was identified as *Aspergillus fumigatus*. A slide culture was performed for species confirmation (►Fig. 8D). On third day, light green velvety colonies appeared on SDA that later

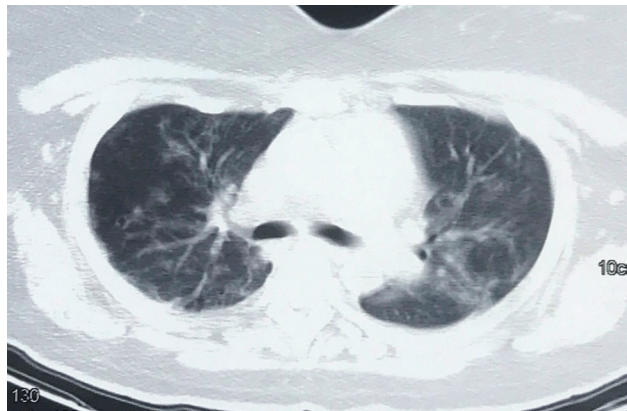

Fig. 5 Contrast computed tomography thorax showing bilateral ground glass opacities and consolidative changes.

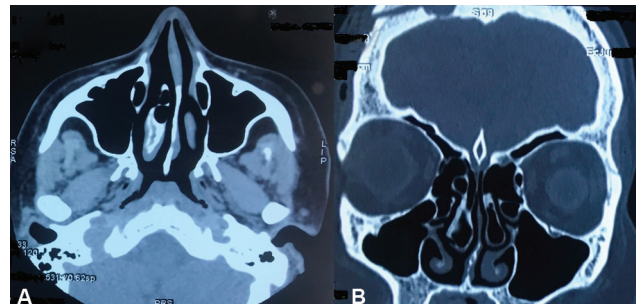


Fig. 6 Axial (A) and coronal (B) computed tomography showing no abnormality in paranasal sinuses..

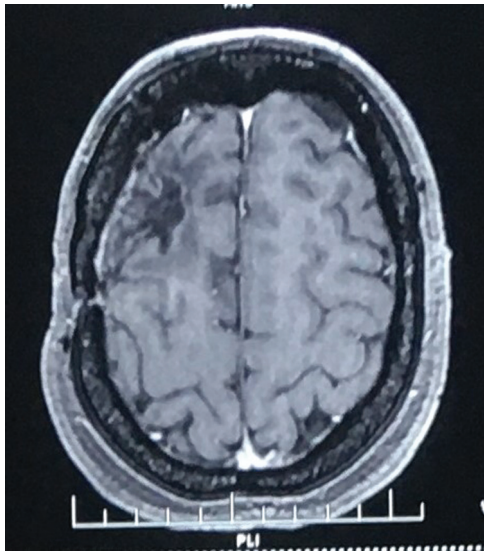


Fig. 7 Axial contrast magnetic resonance imaging brain taken 8 months after surgery showing gliotic changes in right frontal lobe.

turned into smoky green (►**Fig. 9**). Microbiological examination of pus confirmed *Aspergillus fumigatus*. Blood culture and sputum culture did not grow *Aspergillus*.

Histopathology of Brain Abscess Wall

Microscopic examination of hematoxylin and eosin stained sections (►**Fig. 10A, B**) showed brain abscess with extensive areas of necrosis, foreign body giant cell reaction, and a few fungal hyphae that was more apparent with special stains. GMS stain (►**Fig. 10C**) showed septate, slender fungal hyphae with acute angle branching that are consistent with *Aspergillus* species.

This case was diagnosed as a case of fungal brain abscess in right frontal lobe caused by *Aspergillus fumigatus*. Patient was treated with injection voriconazole 400 mg (mg) two doses for 1 day, followed by injection voriconazole 200 mg twice daily. Thereafter, voriconazole was continued as oral tablet of 200 mg twice daily.

Majority of the reported CNS aspergillosis were presented as multiple brain lesions or as posterior fossa lesion. Solitary *Aspergillus* brain abscess in frontal lobe is rare. The authors

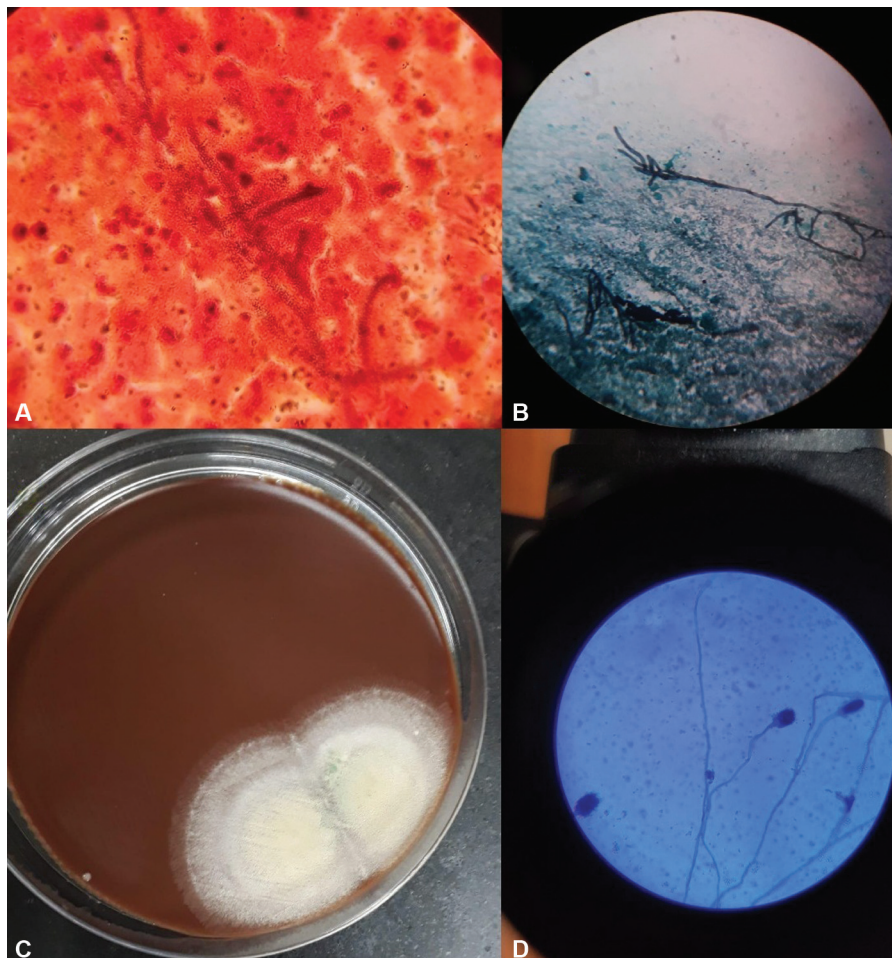


Fig. 8 (A) Gram stain (100 ×) of pus showing numerous pus cells and gram-positive acute angle branching fungal hyphae. (B) Gomori methenamine silver stain (40 ×) of pus showing filamentous black colored hyphae. (C) Mycelial colonies grown on chocolate agar medium after 48 hours of incubation. (D) Lactophenol cotton blue of the slide culture showing conical-shaped vesicle with conidia arising from the upper third of vesicle suggesting *Aspergillus fumigatus*.



Fig. 9 Sabouraud Dextrose Agar (SDA) demonstrating smoky green colored velvety colonies grown on SDA that is characteristic of *Aspergillus fumigatus*.

believe that decreased immunity due to COVID-19 pneumonia, corticosteroid therapy, and diabetes has contributed to the development of this rare disease. Initial imaging of *Aspergillus* brain abscess can mimic like infarct. This is a rarest case of surgically operated solitary brain abscess caused by *Aspergillus fumigatus* in COVID-19 patient.

Discussion

Fungal infections of the CNS are almost always a clinical surprise. Aspergillosis should be considered in cases manifesting with acute onset of focal neurologic deficits resulting from a suspected vascular or space-occupying lesion especially in immunocompromised hosts. Infection reaches the brain directly from the nasal sinuses via vascular channels or

is blood borne from the lungs and gastrointestinal tract. Single or multiple abscess formation with blood vessel invasion leading to thrombosis is a characteristic feature of aspergillosis on neuropathologic examination. Aspergillosis is diagnosed on direct examinations and culture; however, the diagnosis of aspergillosis of the CNS is difficult. Aggressive neurosurgical intervention for surgical removal of *Aspergillus* abscesses, granulomas, and focally infarcted brain; correction of underlying risk factors; amphotericin B combined with flucytosine; and treatment of the source of infection should form the mainstay of the management.³

El-Kholy et al did a prospective longitudinal study including patients diagnosed with acute invasive fungal rhinosinusitis after a recent COVID-19 infection. A total of 36 patients with a mean age of 52.92 years old were included. Histopathological evaluation of mucosal biopsies confirmed that the main causative fungi were *Mucor* species in 77.8% and *Aspergillus fumigatus* in 30.6%, while three patients (8.3%) were infected with both. Among 10 (27.8%) patients with intracranial extension, one case had temporal lobe abscess with occlusion of the internal carotid artery. Neurosurgery was consulted for operative intervention in the case complicated by temporal lobe abscess.⁴ In this study, there is no mention about which fungus has caused the temporal lobe abscess.

Aspergillus abscesses are due to infection of cavities by fungi of the genus *Aspergillus*. Chen et al reported the first case of multiple *Aspergillus* cerebellar abscesses in a 46-year-old female after one mastoidectomy, two craniectomies, and extended use of antibiotics. There is need for alert about multiple *Aspergillus* abscesses in immunosuppressed and immunocompetent patients.⁵

Khera et al reported a case of 7-year-old female child presented with a left superior parietal lobe abscess. She was a known case of pulmonary alveolar proteinosis and was on treatment with corticosteroids. She underwent craniotomy and abscess drainage with abscess wall excision. Histopathology revealed a suppurative lesion with neutrophils and mononuclear cells. Amidst the necrotic material were seen delicate septate hyphae with acute angle branching. The hyphae were highlighted by GMS and periodic acid-Schiff stains. *Aspergillus fumigatus* was isolated on culture from the pus. Culture of sputum and bronchoalveolar lavage was

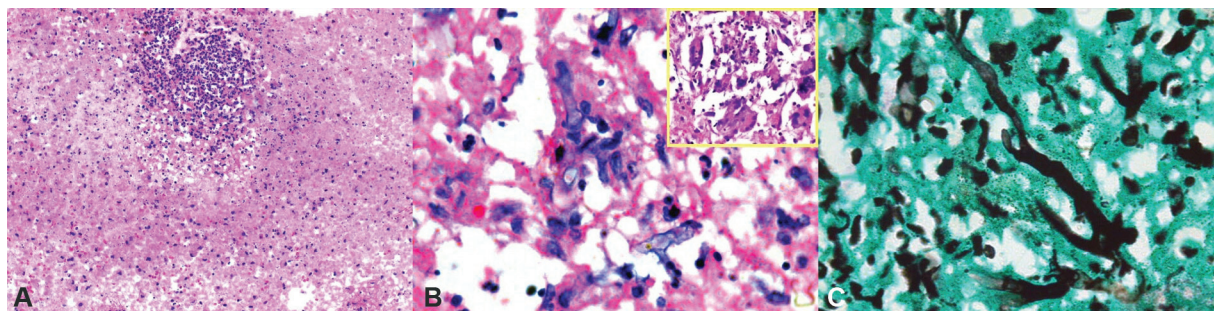


Fig. 10 (A) Hematoxylin and eosin (H&E) stain (200 ×) of brain abscess showing extensive areas of necrosis and foreign body giant cell reaction. (B) H&E stain (1,000 ×) of abscess wall showing extensive areas of necrosis with a few fungal hyphae. Inset showing foreign body giant cell reaction. (C) Gomori methenamine silver stain (1,000 ×) of abscess wall showing septate, slender fungal hyphae with acute angle branching that are consistent with *Aspergillus* species.

negative. The patient was treated with voriconazole with uneventful follow-up till date.⁶

De Villiers De La Noue V et al reported a 20 mm left parietal corticosubcortical cerebral abscess associated with severe acute respiratory syndrome coronavirus 2 (SARS-CoV-2). Stereotaxic brain biopsy revealed the presence of *Aspergillus fumigatus*. The patient was treated by voriconazole for 6 weeks as recommended.⁷

Recent studies have indicated that SARS-CoV-2 might increase the risk of invasive pulmonary aspergillosis (IPA). Hakamifard et al reported the first case of *Aspergillus ochraceus* in a SARS-CoV-2 positive immunocompetent patient, which is complicated by pulmonary and brain infections. The molecular results confirmed the mycological diagnosis of the disease as disseminated aspergillosis due to *Aspergillus ochraceus*. Brain MRI revealed an abscess in the left cerebellar peduncle. The testing for the incidence of *Aspergillus* species in lower respiratory secretions and targeted antifungal therapy based on the primary clinical suspicion of IPA is highly recommended. The authors noted that cerebellar abscess was not operated in this study.⁸

COVID-19 infection may represent a worsening factor for people with diabetes, as it can precipitate acute metabolic complications through direct negative effects on β -cell function. These effects on β -cell function might also cause diabetic ketoacidosis in individuals with diabetes, hyperglycemia at hospital admission in individuals with unknown history of diabetes, and potentially new-onset diabetes.⁹

Cerebral aspergillosis was associated with an almost fatal outcome in the past, but recent data indicate that voriconazole treatment could result in responses and survival in around a third of these high-risk patients. The penetration of voriconazole into infected and noninfected areas of the CNS is superior compared with other available antifungal agents, which likely is a key factor contributing to these advances in the medical management of this otherwise nearly always fatal disease. In addition, neurosurgical management has also an impact on survival in patients with cerebral aspergillosis.¹⁰

Conclusion

High index of suspicion for *Aspergillus* fungal infection should be kept in mind in COVID-19 patients presenting with brain abscess. Brain abscess caused by *Aspergillus fumigatus* occurs due to impaired immunity in COVID-19 patients. Initial imaging of *Aspergillus* brain abscess can mimic like an infarct. Radiological evaluation with MRI brain is important in COVID-19 patients presenting with seizure or focal neurological deficit. Surgical excision of life-threatening solitary *Aspergillus* brain abscess along with antifungal medication voriconazole carries good result.

Informed Consent

The authors certify that they have obtained all appropriate patient consent forms. In the form, the patient has given her consent for her images and other clinical information to be reported in the journal. The patient understands that her name and initial will not be published and due efforts will be made to conceal her identity, but anonymity cannot be guaranteed.

Conflict of Interest

None declared.

Acknowledgment

The study was done with the support from the Departments of Neurosurgery and Pathology of Government Medical College, Kozhikode, Kerala, India. The study was also done with the support from the Department of Microbiology, Baby Memorial Hospital, Kozhikode, Kerala, India.

References

- 1 Hoenigl M, Krause R. Antifungal therapy of aspergillosis of the central nervous system and aspergillus endophthalmitis. *Curr Pharm Des* 2013;19(20):3648–3668
- 2 Boes B, Bashir R, Boes C, Hahn F, McConnell JR, McComb R. Central nervous system aspergillosis. Analysis of 26 patients. *J Neuroimaging* 1994;4(03):123–129
- 3 Nadkarni T, Goel A. Aspergilloma of the brain: an overview. *J Postgrad Med* 2005;51(Suppl 1):S37–S41
- 4 El-Kholy NA, El-Fattah AMA, Khafagy YW. Invasive fungal sinusitis in post COVID-19 patients: a new clinical entity. *Laryngoscope* 2021;131(12):2652–2658; Epub ahead of print. Doi: 10.1002/lary.29632
- 5 Chen S, Pu JL, Yu J, Zhang JM. Multiple *Aspergillus* cerebellar abscesses in a middle-aged female: case report and literature review. *Int J Med Sci* 2011;8(07):635–639
- 6 Khera R, Rao V, Pasam MK, Tagore R, Murthy SS, Sundaram C. Isolated cerebral aspergillus abscess as a complication of pulmonary alveolar proteinosis in a child. *Chin Neurosurg J* 2019;5:17. Doi: 10.1186/s41016-019-0165-8
- 7 De Villiers De La Noue V, Dobanton B, Rosman J, Mateu P. Intracerebral *Aspergillus fumigatus* abscess and SARS-CoV-2. *Intensive Care Med* 2021;47(09):1032–1033
- 8 Hakamifard A, Hashemi M, Fakhim H, Aboutalebian S, Hajiahmadi S, Mohammadi R. Fatal disseminated aspergillosis in an immunocompetent patient with COVID-19 due to *Aspergillus ochraceus*. *J Mycol Med* 2021;31(02):101124; Epub ahead of print. Doi: 10.1016/j.mycmed.2021.101124
- 9 Apicella M, Campopiano MC, Mantuano M, Mazoni L, Coppelli A, Del Prato S. COVID-19 in people with diabetes: understanding the reasons for worse outcomes. *Lancet Diabetes Endocrinol* 2020;8(09):782–792. Doi: 10.1016/S2213-8587(20)30238-2. Erratum in: *Lancet Diabetes Endocrinol*. 2020 Oct;8(10):e5. Erratum in: *Lancet Diabetes Endocrinol*. 2020 Nov;8(11):e6. PMID: 32687793; PMCID: PMC7367664
- 10 Schwartz S, Thiel E. Cerebral aspergillosis: tissue penetration is the key. *Med Mycol* 2009;47(Suppl 1):S387–S393