



## CASE REPORT

# Surgical considerations and management of bilateral labially impacted canines



Yu-Shan Huang<sup>a,b,c</sup>, Yi-Chun Lin<sup>b,c</sup>, Cheng-Yuan Hung<sup>a,b,c</sup>,  
Yu-Lin Lai<sup>b,c\*</sup>

<sup>a</sup> Dentistry Division, National Yang-Ming University Hospital, Ilan, Taiwan

<sup>b</sup> Department of Dentistry, School of Dentistry, National Yang-Ming University, Taipei, Taiwan

<sup>c</sup> Department of Stomatology, Taipei Veterans General Hospital, Taipei, Taiwan

Received 20 January 2011; Final revision received 16 March 2011

Available online 4 April 2013

### KEYWORDS

canine impaction;  
mucogingival surgery;  
surgical exposure

**Abstract** Canines are among the most commonly impacted teeth. When a canine is positioned labially, the untoward soft-tissue responses following surgical exposure may cause unfavorable esthetic outcomes. Therefore, decision making as to the choice of a proper surgical technique to uncover labially impacted teeth is critical. This case presentation describes two different surgical approaches for two maxillary impacted canines in a 12-year-old girl. A sequential approach included a first stage of surgical exposure using apically positioned flaps and orthodontic extrusion of both impacted teeth. A successive laterally positioned flap was used for the left maxillary canine to achieve a harmonious soft-tissue contour. In this case, close monitoring and cooperation during the various treatment phases led to proper canine positioning and a successful esthetic result, with good periodontal health and functional occlusion.

Copyright © 2013, Association for Dental Sciences of the Republic of China. Published by Elsevier Taiwan LLC. This is an open access article under the CC BY-NC-ND license (<http://creativecommons.org/licenses/by-nc-nd/4.0/>).

## Introduction

Maxillary canines are the most commonly impacted teeth after third molars. The prevalence is 0.92–2.2% with a tendency toward females.<sup>1,2</sup> Untreated canines may cause tooth malalignment, root resorption of adjacent teeth, infections, and cystic changes. An impacted canine may be positioned labially or palatally. About one-third of

\* Corresponding author. Department of Stomatology, Taipei Veterans General Hospital, 201 Shih-Pai Road, Section 2, Taipei 112, Taiwan.

E-mail address: [yllai@vghtpe.gov.tw](mailto:yllai@vghtpe.gov.tw) (Y.-L. Lai).

impacted maxillary canines are positioned labially or within the alveolus, while two-thirds are located palatally.<sup>3</sup> The location of an impacted canine will determine access to surgical uncovering. Labial canine impaction is usually difficult to approach because esthetic outcomes of final soft-tissue healing are a challenge. An inappropriate surgical technique or flap design may lead to compromised esthetic results.<sup>4</sup>

Window excision of soft tissue, an apically positioned flap, and a closed eruption technique are the three main surgical techniques for exposing labially impacted canines.<sup>5</sup> Each approach has its clinical indications. Window excision of soft tissue to expose the crown structure is a simple excision technique. However, this method sacrifices the keratinized tissue but might not be applicable in highly impacted cases. The closed eruption technique includes bracket bonding to the exposed tooth, followed by repositioning of the mucosal flap. The challenge of this method is uncontrollable orthodontic forces on the nonvisible tooth during orthodontic extrusion.

The purpose of this article was to present a case with bilaterally impacted canines uncovered by two different surgical interventions.

## Case report

A 12-year-old Taiwanese girl, who presented to the Orthodontic Department of Taipei Veterans General Hospital, Taiwan with her parents in February 2006, complained of delayed eruption of the bilateral canines. According to her parents' statements, the girl's primary canines were extracted at a local dental clinic 6 months prior to this visit. However, the succeeding teeth did not erupt. Her medical history was not contributory. Clinical examinations revealed that neither maxillary canine had erupted. Her upper dental midline had shifted 1 mm to the left side, while her lower dental midline coincided with the facial midline. Her molar relationships were end-on Class II on both sides. A tooth-like structure at the central level of the maxillary right canine area was palpable, whereas the maxillary left canine was neither visible nor palpable. Edentulous spaces over the maxillary right and left canines were 9 mm and 6 mm, respectively (Fig. 1).

Periapical radiographs showed that the crown of her maxillary right canine was positioned between the lateral incisor and first premolar. The maxillary left canine was highly impacted at the apical level of the lateral incisor

(Fig. 2). Considering that the cemento-enamel junction of the right maxillary canine was located apical to the mucogingival junction (MGJ), an apically positioned flap was chosen. For the highly impacted left canine, staged approaches combined with surgical exposure with an apically positioned flap and periodontal plastic surgery on the second visit were scheduled.

Following local anesthesia, horizontal incisions in the bilateral maxillary canine regions coronal to the MGJ were made. In addition, two vertical incisions were extended beyond the MGJ for the purpose of flap relief. The full- and partial-thickness flaps were elevated, and both canine crowns were exposed. An orthodontic button with ligature wire was attached to the buccal surface of both canines. The flaps were then positioned apically and closed with 4-0 Vicryl sutures (Polyglactin 910; Ethicon Inc., Somerville, NJ, USA; Fig. 3).

Analgesic syrup (acetaminophen) was prescribed post-operatively for pain control. Stitches were removed 1 week later. The healing was uneventful, and the patient was referred back for further orthodontic treatment. After 5 months of forced eruption, both canines were placed in occlusion. There was 3 mm of keratinized gingiva on the buccal side of the maxillary right canine; however, only limited keratinized gingiva with an irregular configuration existed on the mesiobuccal side of the left canine. A laterally positioned flap was therefore used to improve the soft-tissue condition of the left canine. To prepare the recipient bed, 6 mm wide of the irregular, nonkeratinized epithelium was removed around the mesial side of the left canine. A partial-thickness flap from the buccal side of the left central and lateral incisors was dissected and laterally rotated to cover the recipient bed over the left lateral incisor and canine region. The flap was fixed with 4-0 Vicryl sutures (Fig. 4). Following completion of orthodontic treatment, both canines were properly aligned, and the gingival margins of these teeth were identical to those of the adjacent teeth. There were 3–4 mm buccal keratinized gingiva around both maxillary canines. The soft-tissue contour in the anterior esthetic region was harmonious (Fig. 5).

## Discussion

The cause of canine impaction is still being debated; genetic factors, tooth size-arch length discrepancies, anomalies of the lateral incisors, prolonged retention or early loss of the deciduous canine, trauma, ankylosis, cyst

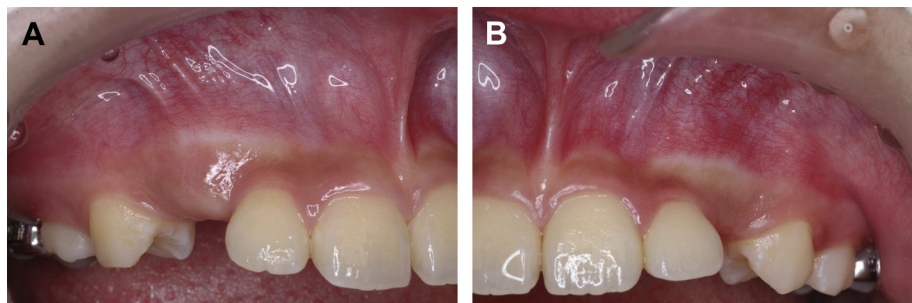
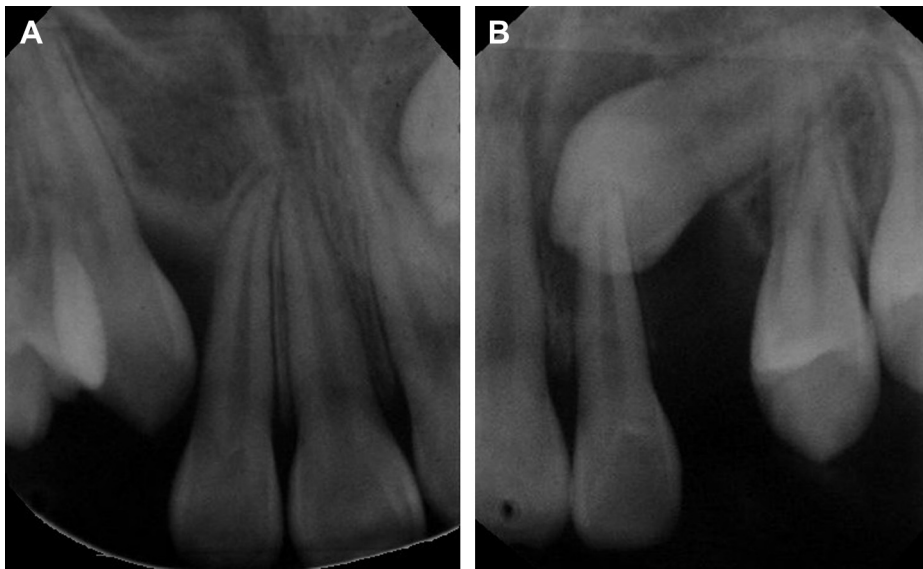


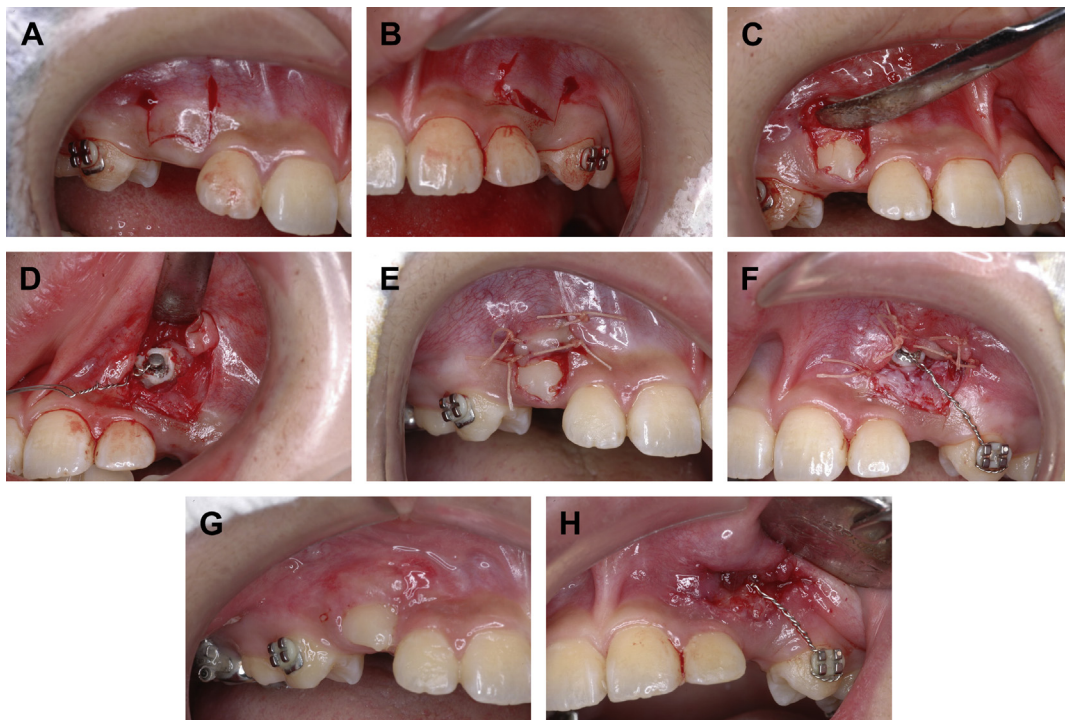
Figure 1 Pretreatment view showing that the bilateral maxillary canines have not erupted.



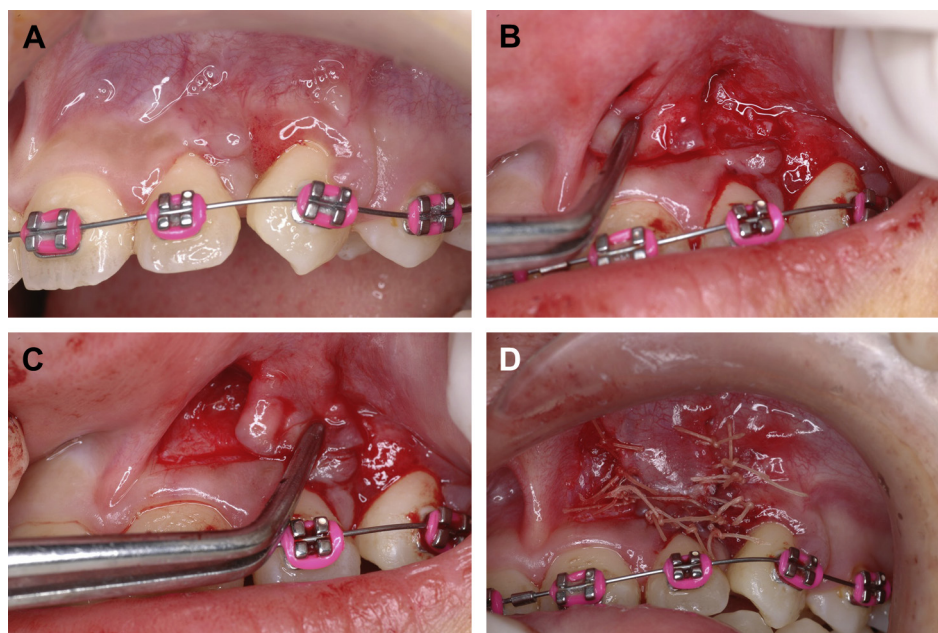
**Figure 2** Periapical radiographs indicating two impacted canines at different levels and angulations. (A) The maxillary right canine crown is positioned in the middle of the edentulous ridge. (B) The left canine crown is located near the apex of the maxillary left central incisor.

formation, an abnormal position of the tooth bud, dilaceration of the root, supernumerary teeth, and odontoma are considered to be related.<sup>6</sup> Impacted canines can be positioned labially or palatally. The incidence of palatal impaction is greater than labial impaction by a ratio of 2:1–3:1.<sup>7</sup> During the process of uncovering a labially

impacted maxillary canine, mucogingival problems, such as an immersed clinical crown, limited keratinized gingiva, gingival recession, and scarring, may occur if an inappropriate surgical intervention is employed.<sup>8</sup> In addition, the vertical and horizontal locations of the impacted canine also greatly impact orthodontic tooth movements and the



**Figure 3** Surgical exposure of both impacted canines. (A, B) Horizontal incisions on the keratinized gingiva with two vertical incisions were designed. (C) The flap was elevated, and the right maxillary canine was exposed. (D) The left canine crown was exposed following removal of the labial bone. (E, F) After bonding with an orthodontic button on the labial surface of the left canine, the flaps were positioned apically and sutured bilaterally. (G, H) The stitches were removed 1 week postoperatively.



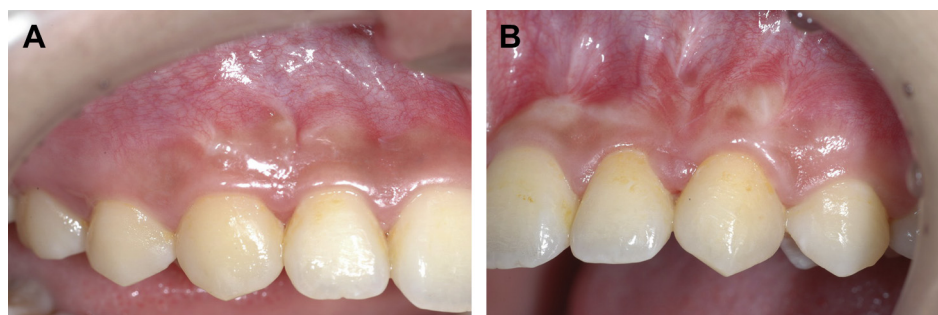
**Figure 4** Mucogingival surgery over the left canine area. (A) Preoperative view indicating minimal keratinized tissue with an irregular appearance over the left lateral incisor and canine region. (B) A partial-thickness flap was dissected from the labial surface of the left incisors. (C) The flap was laterally positioned to the lateral incisor and canine area following preparation of the recipient bed. (D) The pedicle flap was sutured with 4-0 Vicryl.

soft-tissue response. When the impacted canine deviates a long distance from its natural position, orthodontic movement might be hampered by neighboring roots or anatomic structures. Establishing sufficient keratinized gingiva and a harmonious soft-tissue contour surrounding the exposed tooth might not be applicable.

There are three techniques for exposing a labially impacted canine: window excision of the soft tissue, an apically positioned flap, and the closed eruption technique. Selecting among these methods depends on the amount of keratinized tissue in the area of the impacted tooth, the vertical position of the impaction relative to the MGJ, and the mesiodistal position of the canine crown. In cases when the canine crown is coronal to the MGJ, a simple excision procedure is applicable if the amount of keratinized gingiva is sufficient. An apically positioned flap is more predictable to increase the keratinized tissue width if there is insufficient gingiva. When a patient has a highly impacted canine and the crown tip is properly aligned mesiodistally, a closed

eruption technique can be considered. Once a maxillary canine is highly impacted and its crown protrudes labially or its cusp tip is displaced mesially, two-stage approaches may be indicated in which exposure is carried out first and mucogingival surgery is performed at a later stage.

In the present case, the cementoenamel junction of the right canine was just apical to the MGJ, while most of its crown was coronal to the MGJ vertically. In order to preserve the keratinized tissue, an apically positioned flap, instead of window excision of the soft tissue was used. At the end of the following period, 3–4 mm of keratinized gingiva on the labial side of the right canine was achieved. The crown of the impacted left canine was apical to the MGJ, and its crown tip was located on the mesial side of the left lateral incisor. Although an apically positioned flap for uncovering was adapted with an effort, minimal keratinized tissue and an irregular soft-tissue contour over the mesio-buccal side were still noted following tooth eruption. For highly impacted teeth, a second soft-tissue correction such



**Figure 5** One year after orthodontic debonding, the canines were both positioned properly. Harmonious soft tissue and an adequate zone of keratinized gingiva were present.

as keratinized tissue augmentation or gingivoplasty may be necessary. Vermette et al<sup>9</sup> also reported that highly impacted maxillary anterior teeth uncovered with an apically positioned flap have more unesthetic sequelae. In order to achieve optimal esthetic results in this area, a laterally positioned flap for augmentation of the gingival tissue and correction of the soft-tissue contour was considered.

A laterally sliding flap provides additional keratinized tissue with natural color and consistency at the recipient site, which is harmonious in such an esthetically sensitive zone. However, a laterally positioned flap can only be used in a situation in which there is adequate donor tissue laterally. In this case, the labial gingiva of the lateral incisor was thin. To prevent postoperative gingival recession of this tooth, a pedicle flap was dissected from both the central and lateral incisor areas to transfer to cover the recipient bed over the left lateral incisor and canine area. Final results demonstrated that there was 3–4 mm of keratinized gingiva at the labial surface of the left canine area, and the lateral incisor still maintained a normal gingival contour. In this case, multidisciplinary cooperation with a careful evaluation and staged treatment protocol yielded favorable soft-tissue esthetics.

## References

1. Dachi SF, Howell FV. A survey of 3874 routine full mouth radiographs: II. A study of impacted teeth. *Oral Surg Oral Med Oral Pathol* 1961;14:1165–9.
2. Thilander B, Myberg N. The prevalence of malocclusion in Swedish school children. *Scand J Dent Res* 1971;81:12–20.
3. Johnston WD. Treatment of palatally impacted canine teeth. *Am J Orthod* 1969;56:589–96.
4. Kokich VG. Surgical and orthodontic management of impacted maxillary canines. *Am J Orthod Dentofac Orthop* 2004;126:278–83.
5. Kokich VG, Mathews DP. Surgical and orthodontic management of impacted teeth. *Dent Clin North Am* 1993;37:181–204.
6. Jacoby H. The etiology of maxillary canine impactions. *Am J Orthod* 1983;84:125–32.
7. Fournier A, Turcotte JY, Bernard C. Orthodontic considerations in the treatment of maxillary impacted canines. *Am J Orthod* 1982;81:236–9.
8. Bishara SE. Impacted maxillary canines: a review. *Am J Orthod Dentofac Orthop* 1992;101:159–71.
9. Vermette ME, Kokich VG, Kennedy DB. Uncovering labially impacted teeth: apically positioned flap and closed-eruption techniques. *Angle Orthod* 1995;65:23–33.