



# Patient-controlled sedation using remimazolam during third molar extraction: a case report

Kyung Nam Park, Myong-Hwan Karm, Kwang-Suk Seo, Hyun Jeong Kim, Seung-Hwa Ryoo

Department of Dental Anesthesiology, School of Dentistry, Seoul National University, Seoul, Republic of Korea

Dental sedation plays a pivotal role in alleviating patient anxiety during various procedures. Remimazolam, a benzodiazepine derivative, stands out for its distinctive attributes, particularly its rapid onset of sedation coupled with a brief duration, making it an invaluable option for dental applications. The patient was admitted for the extraction of impacted third molars via patient-controlled sedation and not only demonstrated stable vital signs but also expressed a high level of satisfaction with the procedure. An in-depth analysis of plasma remimazolam concentrations and changes in the Patient State Index revealed negative correlation patterns, highlighting the inherent potential of remimazolam in achieving effective sedation. This expanded research scope aims to provide a more nuanced understanding of the pharmacological responses to remimazolam in dental sedation scenarios. This case report offers valuable insights into the evolving landscape of dental sedation methodologies and paves the way for a more informed and evidence-based approach to the use of remimazolam in patient-controlled sedation.

**Keywords:** Dental Anxiety; Intravenous Anesthesia; Patient-Controlled; Remimazolam; Sedation; Tooth Extraction.



This is an Open Access article distributed under the terms of the Creative Commons Attribution Non-Commercial License (<http://creativecommons.org/licenses/by-nc/4.0/>) which permits unrestricted non-commercial use, distribution, and reproduction in any medium, provided the original work is properly cited.



## INTRODUCTION

Dental sedation effectively mitigates patient anxiety and enhances treatment outcomes [1]. However, conventional methods may induce unconsciousness and pose cardiovascular and respiratory risks. Patient-controlled sedation (PCS), employed for three decades, allows for self-administration through a button mechanism, ensuring anxiety reduction without deep sedation [2,3]. Patients can modulate their pain response by pressing a button, with built-in safeguards against excessive sedation through predetermined dosages and lockout times [4].

Remimazolam exerts rapid sedative effects by acting on GABAA receptors, ensuring a short duration, fast recovery, and minimal side effects [5]. Notably, remimazolam, an ester-based benzodiazepine, undergoes swift degradation to an inactive carboxylic acid metabolite by liver esterase [6]. Due to its shorter half-life compared to midazolam, remimazolam allows for prompt recovery of cognitive function, thereby enhancing safety [6-9].

In our hospital, we employ PCS with midazolam, dexmedetomidine, and propofol for patients with dental phobia. This case report evaluates the safety and efficacy of PCS with remimazolam, aiming to provide insights and guidance for potential future applications based on the findings of this study.

Received: January 2, 2024 • Revised: January 14, 2024 • Accepted: January 16, 2024

Corresponding Author: Seung-Hwa Ryoo, Department of Dental Anesthesiology, School of Dentistry, Seoul National University, 101, Daehak-ro, Jongno-gu, Seoul 03080, Republic of Korea

Tel: +82-2-6256-3302 Fax: +82-2-766-9427 E-mail: ryooes00@snu.ac.kr

Copyright© 2024 Journal of Dental Anesthesia and Pain Medicine

## CASE REPORT

A<sup>1</sup>) 57-year-old male, measuring 168 cm in height and weighing 72 kg (body mass index 25.51 kg/m<sup>2</sup>), presented without significant medical history for the extraction of impacted four third molars and excision of a dentigerous cyst surrounding the lower left third molar. Preoperative blood tests revealed no abnormalities. Although sinus bradycardia with a heart rate of 57 beats per minute was noted on electrocardiography, the patient reported no cardiac symptoms, and his functional capacity > 4 METs. Chest radiography showed no active lung lesions, and airway evaluation indicated no limitations in mouth opening or neck extension, with a Mallampati classification of I. Despite intense dental phobia, the

numeric rating scale (NRS) score for surgical site pain was 0. Consequently, the dental anesthesiologist and oral surgeon concurred that performing the surgery under PCS

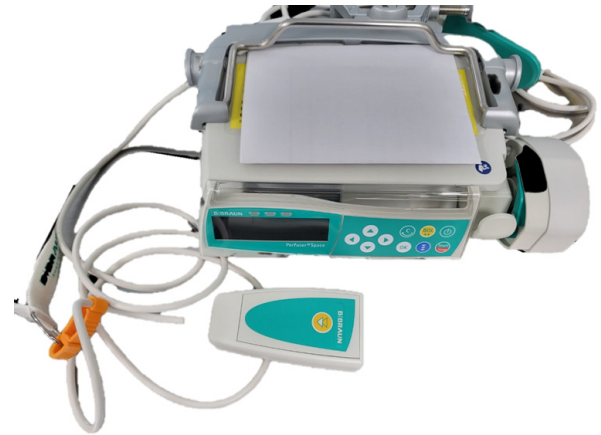

Fig. 1. A patient-controlled sedation device used for remimazolam infusion (Perfusor Space, B.Braun Mesungen AG, Germany).

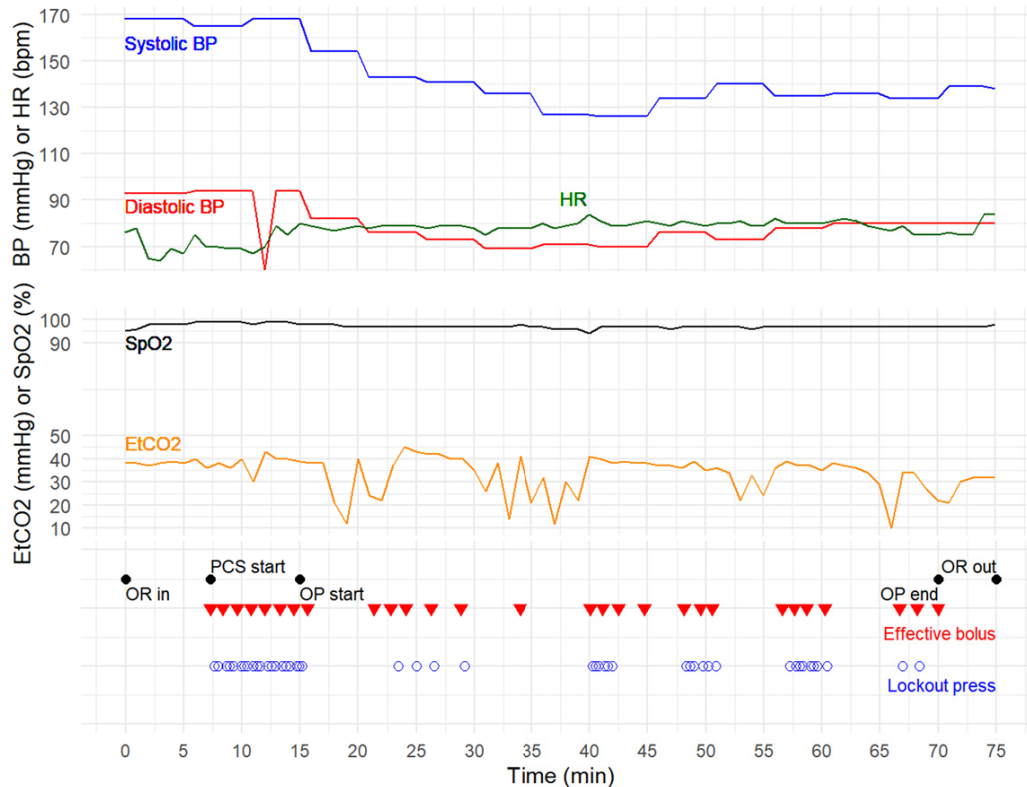
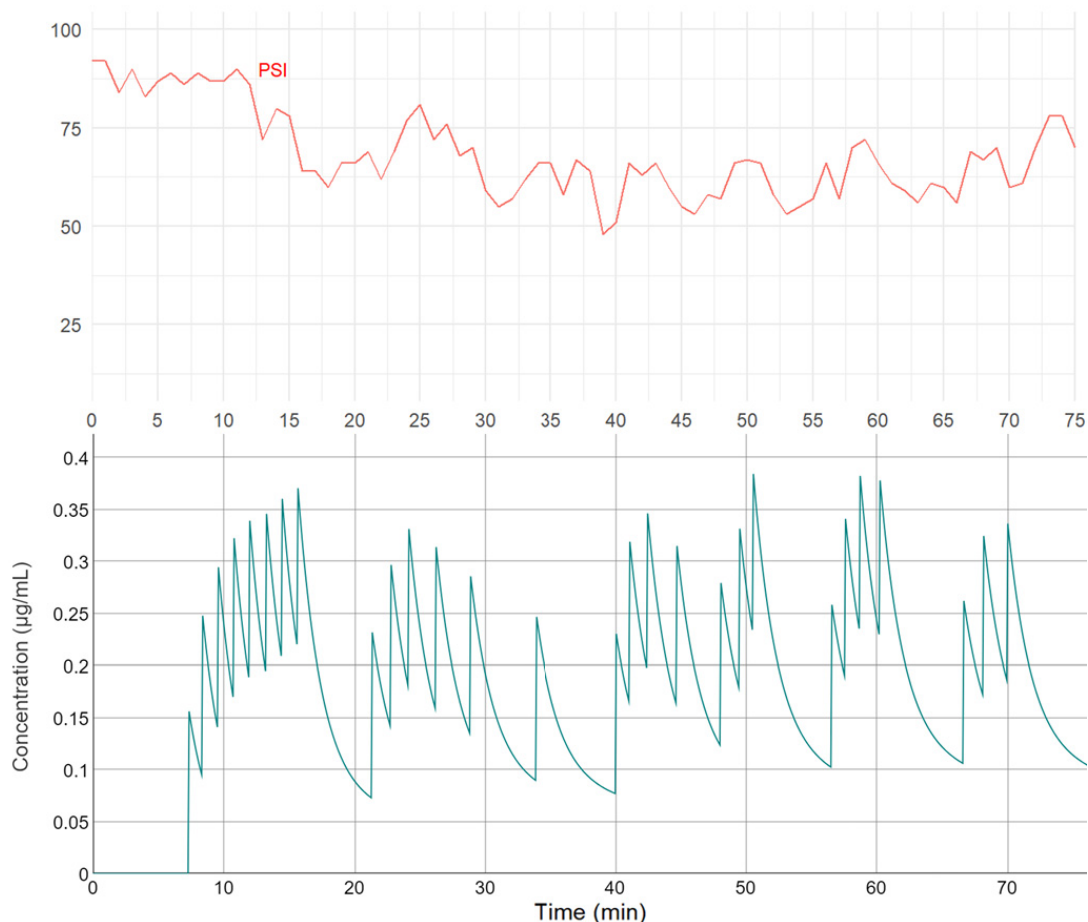


Fig. 2. Alterations in cardiovascular and respiratory parameters during the perioperative phase, along with the timing of the administration of an effective bolus dose through the patient-controlled sedation device. Blue solid line represents systolic blood pressure (Systolic BP, mmHg); red solid line, diastolic blood pressure (Diastolic BP, mmHg); green solid line, heart rate (HR, bpm); black solid line, oxygen saturation (SpO<sub>2</sub>, %); orange solid line, end-tidal CO<sub>2</sub> (EtCO<sub>2</sub>, mmHg). Key events include entry into the operating room (OR in), initiation of patient-controlled sedation (PCS start), commencement of surgery (OP start), end of the surgery (OP end), and exit from the operating room (OR out). Red triangles indicate the time of effective bolus administration, and blue circles represent the time when the button was pressed during the lockout time.

1) This report was presented after receiving approval from the IRB (IRB No. ERI 24002).



**Fig. 3.** Alterations in the Patient State Index (PSI, red solid line) — an assessment of sedation depth utilizing electroencephalography — throughout the perioperative phase, along with fluctuations in plasma remimazolam concentration (green solid line,  $\mu\text{g}/\text{ml}$ ) following bolus dose administration.

would be the preferable approach for this patient.

The PCS utilized remimazolam at a concentration of 0.5 mg/ml, prepared by dilution in normal saline. Sedative administration was facilitated through a PCS device (Perfusor Space, B.Braun Mesungen AG, Germany) as illustrated in Fig. 1. The system parameters were configured to administer a bolus dose of 0.01 mg/kg (0.02 ml/kg) at an injection speed of 1500 ml/h. The patient triggered the administration by pressing a button, and a lockout time of 1 minute was implemented, with no basal infusion dose. Patients were instructed to activate the button whenever additional sedation or analgesia was required.

Upon entering the operating room, the patient exhibited the following vital signs: blood pressure of 168/93 mmHg, heart rate of 76 beats per minute, oxygen saturation ( $\text{SpO}_2$ ) at 95%, end-tidal carbon dioxide

( $\text{EtCO}_2$ ) level of 38 mmHg, and respiratory rate of 11 breaths per minute. The Patient State Index (PSI), quantifying the level of sedation through electroencephalographic (EEG) analysis, was measured at 92 out of 100.

Fig. 2 illustrates the time of remimazolam bolus administration during surgery, concurrently depicting changes in cardiovascular and respiratory parameters. The patient pressed buttons a total of 74 times, with 46 presses during the lockout period and 28 presses, resulting in 40.32 ml (equivalent to 20.16 mg) of effective remimazolam delivery. Vital signs remained stable within normal limits throughout the procedure, and the surgery concluded without complications, such as nausea, vomiting, or adverse reactions. No supplementary sedatives were administered during surgery. Fig. 3

presents correlations between continuous bolus doses, changes in plasma concentration calculated based on pharmacokinetic parameters [10], and alterations in the depth of patient sedation analyzed using PSI.

The patient successfully recovered in the post-anesthesia care unit (PACU) within an hour. Vital signs remained stable, and no further interventions were required. Pain at the surgical site was initially rated as NRS 1 upon PACU entry, while the level of sedation, assessed using the Modified Observer's Alertness/Sedation Scale (MOAA/S), was 5. Both pain and sedation levels remained stable at NRS 0 and MOAA/S 5, respectively, at 30 minutes and 1 hour post-entry. No additional analgesics were administered during the recovery period, and the patient reported no nausea, vomiting, or adverse reactions to the medication. The patient expressed high satisfaction, providing a rating of 5 out of 5 on the PCS for dental procedures (on a scale of 0-5, with higher values indicating increased satisfaction). This assessment was obtained through a survey conducted immediately before the patient's departure from the PACU. Additionally, the patient conveyed a willingness to undergo the same sedation method for future dental procedures.

## DISCUSSION

Remimazolam is widely used in dental surgery. Since its approval for use in South Korea in 2021, remimazolam has become the predominant sedative across various hospitals, indicating its appropriateness and widespread acceptance within the dental field [5,11-13].

An extensive examination of intravenous sedation employing remimazolam for dental procedures, as highlighted in a comprehensive review paper [5], reveals an onset time ranging from 1.5 to 6.4 minutes, showing a swifter induction compared to midazolam. The use of remimazolam for sedation and general anesthesia in medical procedures has demonstrated a reduced incidence of adverse effects, including hypotension, hypoxia, and

injection pain, compared with propofol [14,15]. While there is no universally accepted gold standard for EEG monitoring to verify sedation levels, studies have suggested a noticeable impact of remimazolam administration on the beta wave region. This implies a potential assessment using conventional EEG-based depth of anesthesia devices [14].

The surgical intervention, as illustrated in Fig. 2, maintained stable vital signs with a slight decrease in blood pressure, yet no significant hypotensive episodes (systolic blood pressure < 100 mmHg) were observed. Throughout the procedure, neither hypoxemia nor respiratory depression occurred, as indicated by SpO<sub>2</sub> consistently at or above 94%. Noteworthy fluctuations in EtCO<sub>2</sub> occurred at 18–22, 31–40, 53–56, and 65–71 minutes, but respiratory rates remained within the range of 10–16 breaths per minute. The average respiratory rate during the surgery was approximately 14 breaths/min, reflecting no substantial respiratory depression. The absence of significant changes in cardiovascular vital signs and stable respiratory indicators suggests a low likelihood of notable respiratory suppression or airway obstruction. Repositioning of the nasal prong, leading to suboptimal CO<sub>2</sub> sampling, raises the possibility of a temporary measurement error. However, since this event transpired when the PCS button was not pressed, signifying appropriate sedation, it is challenging to entirely rule out mild partial airway obstruction causing relatively small changes in the respiratory rate.

Considering the previously reported short onset time and brief duration of action, approximately 10 minutes for remimazolam [5], our study results closely align. Analysis of the button press pattern in our case (Fig. 2) revealed clusters of effective presses. Correspondingly, plasma remimazolam concentrations fluctuated in response to this button press pattern (Fig. 3). After consecutive button presses, the patient tended to pause until the plasma concentration of remimazolam decreased to approximately 0.1 µg/ml or below. This temporary cessation was followed by a decrease in plasma concentration, prompting the patient to resume pressing

the button. Examination of the PSI changes in response to this pattern revealed a consistent trend. After the last button-press cluster, PSI consistently decreased, reaching its lowest point, indicating the presence of lag time. Following the lowest point, PSI gradually increased during the time interval without button presses. Subsequently, with the initiation of a new button-press cluster and the last button-press within that cluster, PSI exhibited a decreasing trend, reaching its lowest point. Therefore, in this case report, we confirmed the association between remimazolam administration via the PCS method and decreases in blood pressure and PSI.

While remimazolam, similar to other sedatives, poses the risk of dose-dependent complications, including hypoxemia and cardiovascular depression, the present case underscores the potential of PCS in ensuring an optimal level of sedation. This approach helps avoid excessive sedation and its associated adverse effects. Sedation was judiciously and effectively achieved through PCS with remimazolam in a patient with dental phobia.

Given the limited previous research findings regarding the use of remimazolam in dental procedures involving PCS, further investigations are warranted. Prospective randomized controlled trials comparing remimazolam with other commonly utilized agents are imperative to comprehensively assess factors, including vital signs, side effects, patient cooperation, and satisfaction. Additionally, a more detailed pharmacokinetic and pharmacodynamic assessment is necessary to elucidate the causality between bolus dose administration and alterations in vital signs, sedation depth, and EEG patterns. Instead of relying solely on PSI values, as illustrated in this case, conducting research that analyzes changes in a broader spectrum of EEG could provide valuable insights.

In conclusion, remimazolam demonstrated effective and safe outcomes in PCS for dental procedures, highlighting its rapid onset, short duration, and minimal side effects, ensuring optimal sedation. The patient reported high satisfaction, and vital signs remained stable.

Although promising, further research is required to establish comparative efficacy and safety, particularly in specific dental practices.

#### AUTHOR ORCID

**Kyung Nam Park:** <https://orcid.org/0000-0002-2665-6548>

**Myong-Hwan Karm:** <https://orcid.org/0000-0002-7494-4747>

**Kwang-Suk Seo:** <https://orcid.org/0000-0001-5906-0639>

**Hyun Jeong Kim:** <https://orcid.org/0000-0002-9265-7549>

**Seung-Hwa Ryou:** <https://orcid.org/0000-0002-7442-8531>

#### AUTHOR CONTRIBUTIONS

**Kyung Nam Park:** Conceptualization, Data curation, Formal analysis, Visualization, Writing – original draft

**Myong-Hwan Karm:** Conceptualization, Methodology, Writing – review & editing

**Kwang-Suk Seo:** Data curation, Formal analysis, Methodology, Writing – review & editing

**Hyun Jeong Kim:** Conceptualization, Visualization, Writing – review & editing

**Seung-Hwa Ryou:** Conceptualization, Data curation, Formal analysis, Supervision, Writing – review & editing

**PREVIOUS PRESENTATION IN CONFERENCES:** None

#### REFERENCES

1. Southerland JH, Brown LR. Conscious intravenous sedation in dentistry: a review of current therapy. *Dent Clin North Am* 2016; 60: 309-46.
2. Rodrigo MR, Tong CK. A comparison of patient and anaesthetist controlled midazolam sedation for dental surgery. *Anaesthesia* 1994; 49: 241-4.
3. Seo KS, Lee K. Smart syringe pumps for drug infusion during dental intravenous sedation. *J Dent Anesth Pain Med* 2016; 16: 165-73.
4. Girdler NM, Rynn D, Lyne JP, Wilson KE. A prospective randomised controlled study of patient-controlled propofol sedation in phobic dental patients. *Anaesthesia* 2000; 55: 327-33.
5. Oka S, Satomi H, Sekino R, Taguchi K, Kajiwara M, Oi

- Y, Kobayashi R. Sedation outcomes for remimazolam, a new benzodiazepine. *J Oral Sci* 2021; 63: 209-11.
6. Rogers WK, McDowell TS. Remimazolam, a short-acting gaba(a) receptor agonist for intravenous sedation and/or anesthesia in day-case surgical and non-surgical procedures. *IDrugs* 2010; 13: 929-37.
  7. Antonik LJ, Goldwater DR, Kilpatrick GJ, Tilbrook GS, Borkett KM. A placebo- and midazolam-controlled phase i single ascending-dose study evaluating the safety, pharmacokinetics, and pharmacodynamics of remimazolam (cns 7056): Part i. Safety, efficacy, and basic pharmacokinetics. *Anesth Analg* 2012; 115: 274-83.
  8. Pastis NJ, Yarmus LB, Schippers F, Ostroff R, Chen A, Akulian J, et al. Safety and efficacy of remimazolam compared with placebo and midazolam for moderate sedation during bronchoscopy. *Chest* 2019; 155: 137-46.
  9. Wiltshire HR, Kilpatrick GJ, Tilbrook GS, Borkett KM. A placebo- and midazolam-controlled phase i single ascending-dose study evaluating the safety, pharmacokinetics, and pharmacodynamics of remimazolam (cns 7056): Part ii. Population pharmacokinetic and pharmacodynamic modeling and simulation. *Anesth Analg* 2012; 115: 284-96.
  10. Kim KM, Bang JY, Lee JM, Yang HS, Choi BM, Noh GJ. Effect-site concentration of remimazolam at loss and recovery of responsiveness during general anesthesia: a simulation study. *Anesth Pain Med (Seoul)* 2022; 17: 262-70.
  11. Masui K. Remimazolam besilate, a benzodiazepine, has been approved for general anesthesia!! *J Anesth* 2020; 34: 479-82.
  12. Oue K, Oda A, Shimizu Y, Takahashi T, Kamio H, Sasaki U, et al. Efficacy and safety of remimazolam besilate for sedation in outpatients undergoing impacted third molar extraction: a prospective exploratory study. *BMC Oral Health* 2023; 23: 774.
  13. Swart R, Maes SSA, Cavanaugh D, Mason KP. Remimazolam pilot for office-based dental sedation: adverse events, awareness and outcomes. *J Clin Med* 2023; 12: 7308.
  14. Morimoto Y. Efficacy and safety profile of remimazolam for sedation in adults undergoing short surgical procedures. *Ther Clin Risk Manag* 2022; 18: 95-100.
  15. Zhang J, Cairen Z, Shi L, Pang S, Shao Y, Wang Y, et al. Remimazolam versus propofol for procedural sedation and anesthesia: a systemic review and meta-analysis. *Minerva Anesthesiol* 2022; 88: 1035-42.