

## ORIGINAL ARTICLE

# *Candida* and calcofluor white: Study in precancer and cancer

Rashmi Santosh Kumar, Ganvir SM<sup>1</sup>, VK Hazarey<sup>1</sup>

Department of Oral and Maxillofacial Pathology and Microbiology, Kamineni Institute of Dental Sciences, Marketpalli - 508254, Andhra Pradesh, <sup>1</sup>Department of Oral and Maxillofacial Pathology and Microbiology, GDC and H Nagpur, Maharashtra, India

**Address for correspondence:**

Dr. Rashmi Santosh Kumar,  
Department of Oral and Maxillofacial Pathology  
and Microbiology, Kamineni Institute of Dental  
Sciences, Marketpalli - 508 254,  
Andhra Pradesh, India.  
E-mail: rashmi\_bhavasar@rediffmail.com

**ABSTRACT**

**Background:** The interest in oral candidosis has waxed and waned from the period of Hippocrates. The acquired immune deficiency syndrome (AIDS) epidemic has certainly bolstered these figures on oral candidosis, with diabetes and oral cancer being no exception. A need for rapid detection of *Candida* is made possible by the use of Calcofluor - White (CFW) stain when examined under a fluorescence microscope. The present study was aimed at assessing the efficacy of CFW is compared to Gram stain and periodic acid Schiff (PAS) in detection of *Candida* in oral precancer and cancer.

**Materials and Methods:** The study group consisted of patients with precancer (n = 45), cancer (n = 45), and control group (n = 45). Presence of *Candida* was confirmed by culture inoculation along with a germ tube and carbohydrate fermentation test. The cytopathological smears were analyzed by papanicolaou - CFW and Gram staining, whereas, tissue sections were stained by PAS and CFW staining.

**Results:** *Candida albicans* was the predominant species identified. A highly significant association of *Candida* was seen more often in cancer than in precancer. Both in cytology and histopathology *Candida* detection by CFW was higher. In precancer it was 48.88% in smears and 40% in tissue sections, whereas, in cancer 60% in smears and 55.55% in histopathology.

**Conclusion:** Among the various diagnostic tools used in the present study, the use of CFW is seen to be a simple, effective, rapid, and reliable method, both in cytopathology and histopathology.

**Key words:** Cancer, *Candida*, calcofluor white, precancer

DOI: 10.4103/0973-029X.44575

**INTRODUCTION**

Mycotic infections have become a major cause of morbidity and mortality in clinically debilitated or immunocompromised patients.<sup>[1]</sup> The co-existence of *Candida* species within humans either as commensals or pathogens has been a subject of interest, among physicians.<sup>[2]</sup> Also the association of *Candida* with various precancer and cancer lesions has been reported as a causative agent.<sup>[3-6]</sup>

With the increasing importance of candidosis, there is a need for a practical method for identification of fungus. A new technique for the rapid identification of fungi in tissues has been described by Monheit and co-workers.<sup>[7-9]</sup>

Calcofluor White (CFW) is a disodium salt of 4,4'-bis-[4anilino-bis-diethyl-amino-S-tri-azin-2-ylamino]-2,2'-stilbene-disulfonic acid, a colorless dye that is used in the textile and paper industries as a whitening agent.<sup>[7,10,11]</sup>

It has the ability to bind to  $\beta$  1-3,  $\beta$  1-4 polysaccharides

(i.e., cellulose and chitin), and exhibits fluorescence when exposed to long - wavelength ultraviolet and short - wavelength visible light. It has been used as a biological marker to stain the cell walls of plants, and is therefore valuable in delineating fungal elements.<sup>[12]</sup>

The use of CFW in clinical mycology was first described by Hageage and Harrington,<sup>[12]</sup> and has found extensive use in this area for rapid detection of microorganisms. CFW is a nonspecific fluorochrome stain that binds to fungi, and depending upon the filter system employed, fluoresces either an apple green or blue white color when exposed to ultraviolet light.<sup>[10,11,13]</sup> It can be used on fresh, frozen, fixed, paraffin embedded, and clinical specimens.<sup>[7]</sup>

CFW has also been incorporated in the Papanicolaou stain procedure, to enhance the recognition of yeasts in smears.<sup>[9]</sup>

The study was planned with the following aims and objectives:

1. To determine the presence of *Candida* in oral precancer

and cancer patients, using various laboratory tests, such as culture, germ tube (GT) test, and carbohydrate fermentation test.

2. To detect *Candida* in oral precancer and cancer lesions by using CFW staining in cytopathology and in histopathology under a fluorescence microscope.
3. To compare the diagnostic efficacy of a cytopathological smear with that of the histological sections.
4. To investigate the diagnostic efficacy of the fluorescence microscopic evaluation of a CFW stain used in direct smears and tissue sections.
5. To evaluate the sensitivity and specificity of CFW staining in cytopathology and histopathology, in the detection of *Candida* as compared to Gram staining and periodic acid schiff (PAS) staining.

## MATERIALS AND METHODS

The sample for the present clinical study comprised of a total of 135 patients of both sexes. The patients were selected from among those visiting the Outpatient Department of Oral Pathology, Government Dental College and Hospital, Nagpur.

The study group comprised of 90 cases of oral precancer and cancer, diagnosed on the basis of clinical and histological features, were selected. The precancer group comprised of oral leukoplakia (OL), oral lichen planus (OLP), and oral submucous fibrosis (OSF). The control group comprised of 45 cases of normal patients. The distribution of study group and controls are tabulated in Table 1.

A complete medical history was obtained including accompanying systemic conditions, ongoing medication, and prescribed therapy for their lesions.

**Specimen collection:** Culture inoculation was done for each patient by the swab method. Smears were prepared by scrape cytology using a wooden stick moistened in normal saline. For histopathological examination, a tissue was obtained by using a 7 mm punch.

**Method of identification:** Swabs were inoculated immediately on the Sabouraud's slope. The growth was subcultured on a new slope of Sabouraud's agar and the pure colony was subjected to the GT test and carbohydrate fermentation test [Figure 1, Figure 2].

**Table 1: Distribution of study group and controls**

Type of lesions	Number
Precancer	
Oral leukoplakia	15
Oral lichen planus	06
Oral submucous fibrosis	24
Oral cancer	45
Control	45

For each patient, two smears were prepared on the center of the slide. For the study group, smears were prepared from the lesional site, and for the control group, smears were obtained from the tongue and buccal mucosa of normal healthy individuals.

One of the two smears was air-dried by passing through the flame, two to three times, and was Gram stained and observed under a light microscope where *Candida* was seen as dark blue colored hyphae and yeasts [Figure 3, Figure 4]. Another smear was wet-fixed by dipping the slide in 95% ethyl alcohol for one hour and was subsequently stained with papanicolaou (PAP)-CFW staining [Table 2].<sup>[9]</sup>

The CFW solution consisted of a 0.1% (w/v), distilled water solution of (disodium salt of 4,4'-bis-[4-anilino-bis-diethyl-amino-s-triazin-2ylamino]-2,2'-stilbene-disulfonic acid). During incorporation of CFW into the PAP-stain sequence, CFW was introduced after acid eosin, as was determined by Monheit in 1986.<sup>[9]</sup> When observed under the fluorescence microscope, Candidal hyphae appeared apple green in color, with a dark orange background [Figure 5, Figure 6].

Clinical photographs were taken in selected cases prior to contemplating the biopsy procedure. Anesthesia was achieved by infiltration / block technique; given away from the biopsy site. Punch biopsies were obtained by using a 7 mm punch. For the control group, only one biopsy could be obtained as it was not ethically possible to obtain biopsy from all the 45 normal subjects.

**Table 2: Papanicolaou - calcofluor - white staining**

Agent	Staining time
Running water	1 min
Harris hematoxylin	6 min
Running water	1 min
Aqueous HCL solution	6 dips
Running water	1 min
Lithium carbonate	2 min
50% ethanol	10 dips
95% ethanol	6-8 dips
95% ethanol	6-8 dips
Orange G - 6	1.5 min
95% ethanol	Rinse gently
95% ethanol	Rinse gently
Acid - Eosin 50	1.5 min
95% ethanol	Rinse gently
50% ethanol	Rinse gently
CFW (0.1%)	1 min
50% ethanol	Rinse gently
95% ethanol	Rinse gently
95% ethanol	Rinse gently
100% ethanol	6-8 dips
100% ethanol	6-8 dips
Xylene	6-8 dips
Xylene	6-8 dips
Mount in DPX	-

Tissues were processed to obtain the paraffin embedded sections both for PAS and CFW staining. Sections of 5 µm were cut from each block, deparaffinized, hydrated to water, and stained with PAS, and observed under light microscope [Table 3]. Candida could be seen in the superficial layer of the epithelium as magenta, red-colored hyphae penetrating the epithelium both vertically and horizontally [Figure 7].

Additional 5 µm sections were cut from each block, deparaffinized, hydrated to water, and coverslipped with a solution of 0.1% (w/v) CFW in distilled water containing 0.05% Evans blue as a counter stain to suppress the background fluorescence.<sup>[7]</sup> One or two drops of 0.1% CFW was placed on tissue sections on the slides for 1 min and then coverslipped and examined microscopically [Table 4],<sup>[7]</sup> although the solution was relatively stable it was kept in actinic (red) glassware to prevent photoisomerization and degradation. The procedure was performed under fluorescent room lighting, and slides were immediately placed in cardboard slide holders. All section were examined with a Olympus Fluorescent Microscope equipped with plan achromatic lenses, episcopic-fluorescence attachment BX-FLA, a high-pressure mercury light source and a UV filter cassette containing a

330 to 380 nm excitation filter, a 400 nm dichroic mirror, and a 420 nm absorption filter. Candidal hyphae were seen as green to yellow in colour against a background of dark orange background [Figure 8].

Sensitivity, specificity, positive predictive value, and negative predictive values were calculated according to the following formulae: Sensitivity =  $[a / (a + c)] \times 100$ ; specificity =  $[d / (b + d)] \times 100$ ; positive predictive value =  $[a / (a + b)] \times 100$ ; and negative predictive value =  $[d / (c + d)] \times 100$ ; where a is the number of true positives, b is the number of false positives, c is the number of false negatives, and d is the number of true negative samples.<sup>[14]</sup>

Correlation between the staining procedures was determined by the Kappa test.<sup>[14]</sup> The interpretation of results was as follows: If  $K < 0$  No agreement; 0–0.19 Poor agreement; 0.20–0.39 Fair agreement; 0.40–0.59 Moderate agreement; 0.60–0.79 Substantial agreement; 0.80–1.00 Almost perfect.

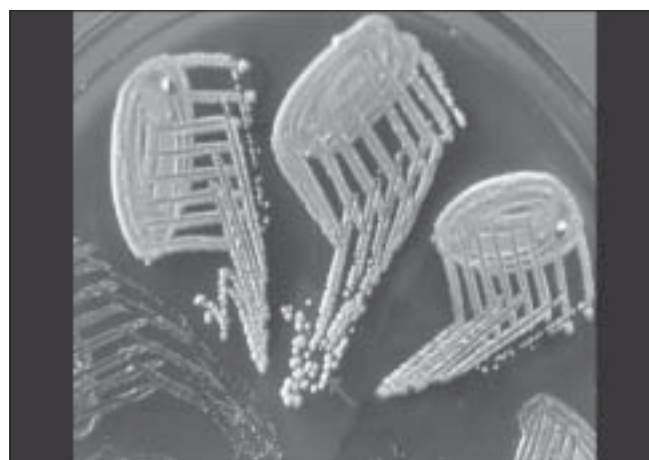
The Z-test evaluated the difference in proportion of cytological smears of Gram and PAP-CFW staining and histopathological

**Table 3: Periodic - acid - Schiff staining**

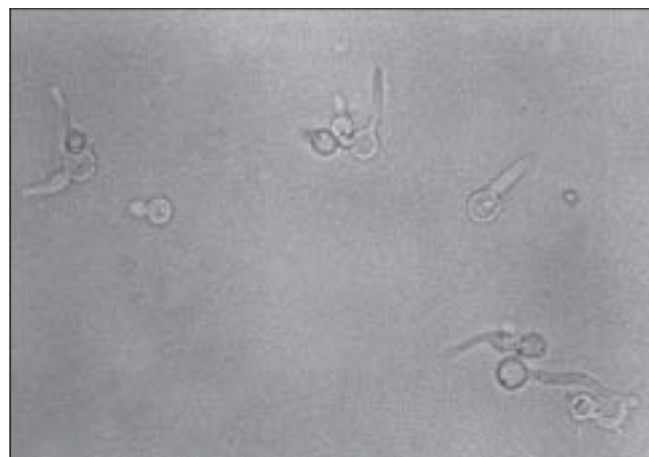Agent	Staining time
Deparaffinize the sections with Xylene	
Absolute alcohol	5 min
Running water	5 min
Poured 0.2% periodic acid - 5 min or 0.5 % periodic acid	2 min
Running water	5 min
Schiff's reagent solution	45 min at 37°C
Running water	5 min
Pouring of sulfurous vapors solution	5 min to remove excess Schiff's reagent
Running water	5 min
Pouring of 0.2% solution of light green on the slide	5–10 min
Washed with absolute alcohol	-
Dehydrated and cleaned with Xylene	-
Slide mounted with DPX	-

**Table 4: Calcofluor white staining**

Commercially available CFW powder was dissolved in distilled water to produce 0.1% solution of CFW  
Sections of 5 µm were cut from each block  
Sections were deparaffinized with xylene and hydrated to water  
One or two drops of the working solution were placed on freshly prepared unstained paraffin embedded sections and allowed to stand for 1 min  
Followed by a tap water rinse  
Counterstained for 1 min with a dilute solution of Evans Blue to minimize background fluorescence  
Slides were mounted by DPX mounting medium and were followed by cover slip placement

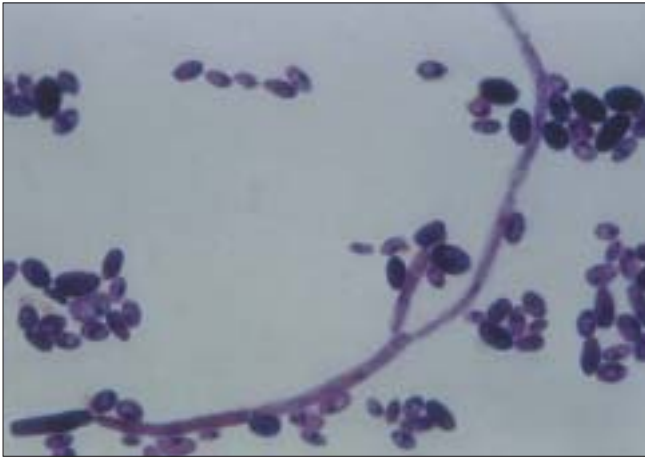

**Figure 1:** Candidal colonies appear as smooth, shiny, convex, creamy white on Sabouraud's dextrose agar

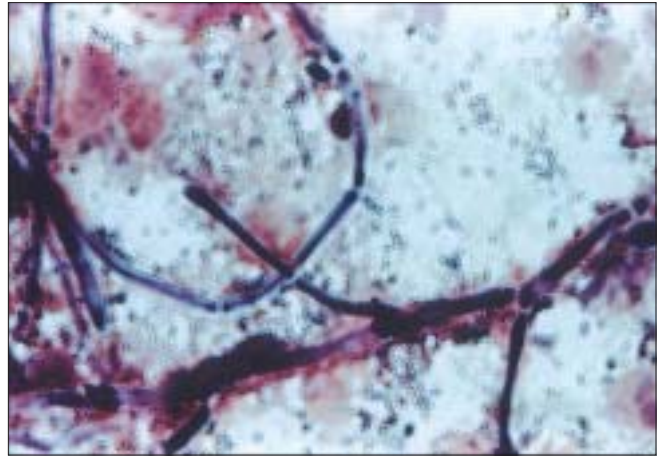


**Figure 2:** Germ tube of candida seen under a light microscope

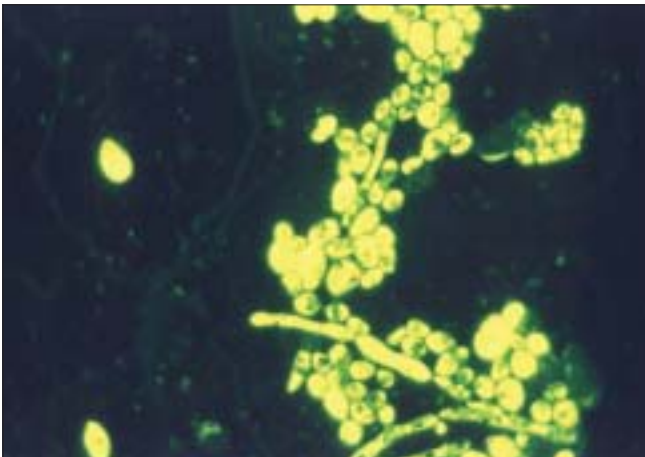




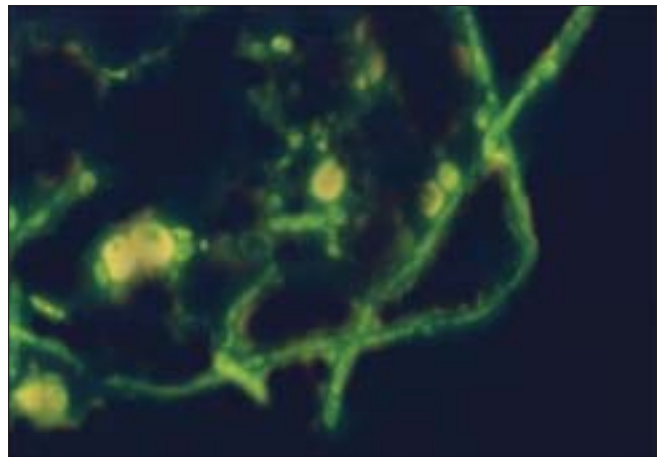
**Figure 3:** Photomicrograph showing yeast forms of candida in cytopathology (Gram stain, 100x)



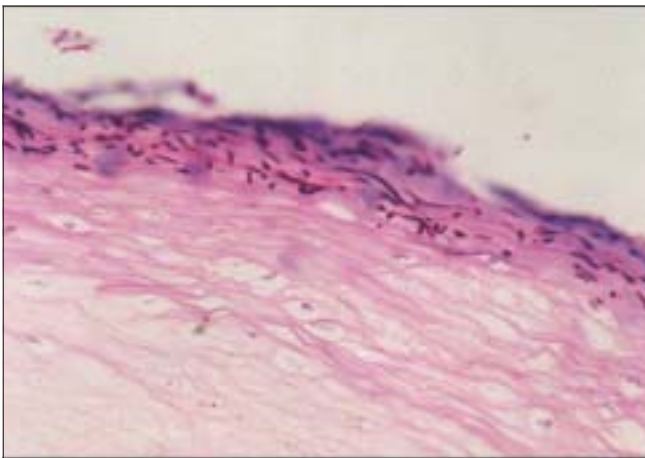
**Figure 4:** Photomicrograph showing hyphal forms of candida in cytopathology (Gram stain, 100x)



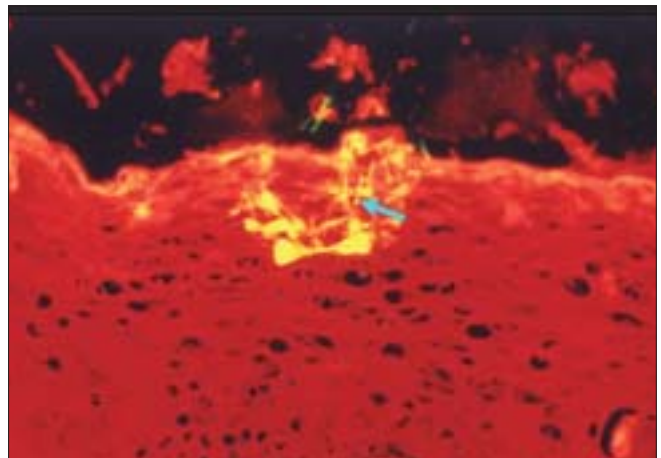
**Figure 5:** Photomicrograph showing yeast forms of candida in cytopathology (PAP-CFW, 100x)



**Figure 6:** Photomicrograph showing hyphal forms of candida in cytopathology (PAP-CFW, 100x)



**Figure 7:** Candidal colonization in superficial keratin (PAS, 20x)



**Figure 8:** Candidal colonization in superficial keratin (CFW, 20x)

staining of PAS and CFW stain. Chi square ( $\chi^2$ ) test was applied to assess the association between Candida and oral precancer and oral cancer.

## RESULTS

Distribution of males and females among the study and control groups are tabulated in Table 5. The mean age of males in the oral precancer and oral cancer groups were lower than that of females [Table 5].

Candidal growth was observed from the primary culture medium of Sabouraud's dextrose agar as smooth, shiny or dull, cream-colored colonies at room temperature, that is, at 37°C [Figure 1]. Among the 90 samples of study groups, 45 samples (50%) showed Candidal colonies, fulfilling all the diagnostic criteria, whereas, only two samples (4.44%) from the control group were positive for Candidal growth [Table 6].

Among the 45 culture-positive samples of the study group, 39 (86.66%) samples and both culture-positive samples of the control group were GT test positive. By using the carbohydrate fermentation test and GT test, the species identified was predominantly *Candida albicans*, whereas, the remaining six cases belonged to *Candida tropicalis*.

Evaluation of cytological smears showed that among that PAP-CFW was more effective in detection of *Candida*

compared to Gram stain [Table 6]. Similarly evaluation of the histopathological sections showed a higher detection rate of *Candida* by CFW compared to PAS [Table 6].

PAP-CFW staining showed high sensitivity (85.10%) with a high specificity (88.63%) [Figure 9], and a positive predictive value of 80% and negative predictive value of 91.76%. Kappa test ( $K = 0.7266$ ) suggested substantial agreement of PAP-CFW with culture. Z test ( $Z = 3.1504$ ) showed a highly significant probability of detection of *Candida* by PAP-CFW procedure; and K test ( $k = 0.5138$ ) suggested a moderate agreement between two staining methods.

Sensitivity evaluated by PAS was low (i.e., 66.66%) compared to CFW, but showed a higher specificity (91.11%) [Figure 10], with positive and negative predictive values of 88.23% and 73.21% respectively. K test ( $k = 0.5777$ ) suggested a substantial agreement of PAS with culture. Sensitivity of CFW was high (82.22%) with a specificity of 86.66% and positive predictive value of 86.04% and negative predictive value of 82.97%. Kappa test ( $K = 0.6888$ ) suggested substantial agreement of CFW with culture. But Z test ( $Z = 1.0585$ ) suggested the equivalence of PAS and CFW procedures. K test ( $K = 0.7519$ ) showed the substantial agreement of both detection methods. Chi square test showed a highly significant association of *Candida* in both oral precancer ( $\chi^2 = 17.386$ ;  $P < 0.001$ ) and oral cancer ( $\chi^2 = 25.608$ ;  $P < 0.001$ ).

## DISCUSSION

With the increasing importance of candidosis, there is a need for identification of *Candida*. The various species can be identified with the help of a germ tube test, identifying characteristic morphology on cornmeal Tween 80 agar and sugar fermentation reactions. But, today there is a need for a rapid detection of *Candida*, which is made possible by the use of Calcofluor-White under a fluorescence microscope.<sup>[7-9]</sup> In the present study, the diagnostic efficacy of CFW in detection of *Candida* both in cytological smears and histopathological sections as compared to Gram stain and PAS.

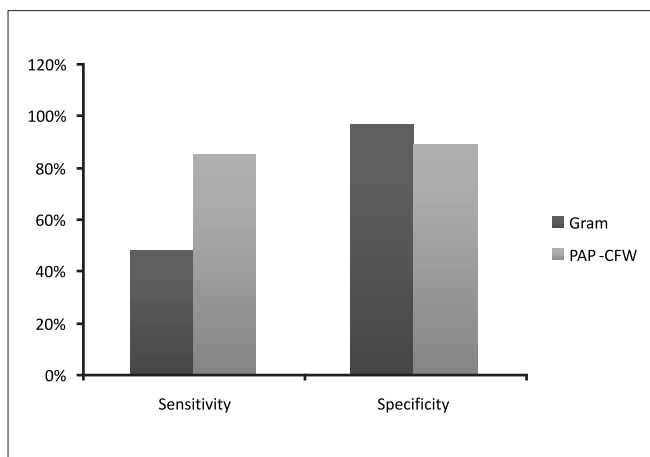
In the present study, Candidal colonies were identified on Sabouraud's dextrose agar and species identified using germ tube and carbohydrate fermentation tests. In combination of morphological and biochemical observations, the species

**Table 5: Age and gender distribution**

	Age (in years)			Mean $\pm$ SD
	0-25	26-50	51 and above	
Controls				
Males	1	10	14	55.36 $\pm$ 21.27
Females	2	8	10	52.3 $\pm$ 19.84
Total	3	18	24	58.53 $\pm$ 20.55
Oral precancer				
Males	13	19	7	36.27 $\pm$ 15.13
Females	2	2	2	42.80 $\pm$ 17.8
Total	15	21	9	39.53 $\pm$ 16.50
Oral cancer				
Males	0	6	20	56.80 $\pm$ 11.12
Females	0	2	17	60.26 $\pm$ 11.55
Total	0	8	37	58.53 $\pm$ 11.33

**Table 6: Candidal detection by various methods**

	Total	Culture positive	Germ tube test positive	Cytology		Histopathology	
				Gram stain positive	PAP-CFW positive	PAS positive	CFW positive
Oral precancer							
Oral leukoplakia	15	12	10	7	8	7	8
Oral lichen planus	6	1	1	0	1	0	1
Oral sub mucous fibrosis	24	7	7	8	13	8	9
Oral cancer	45	45	21	11	27	19	25
Control	45	2	2	1	1	-	-
Total	135	67	41	27	50	34	43



**Figure 9:** Comparison of sensitivity and specificity of Gram and PAP-CFW staining procedures

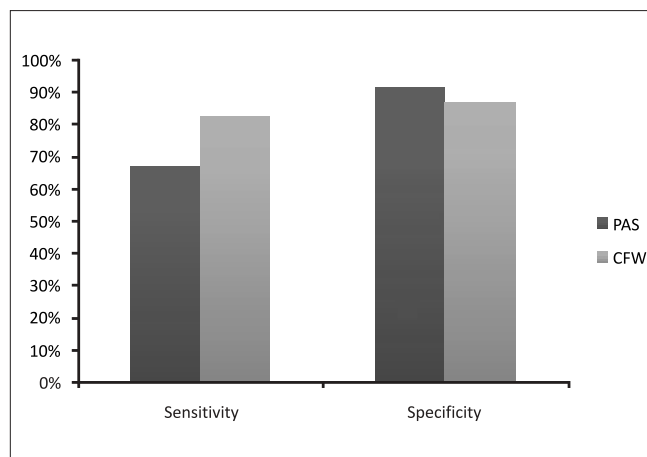
identified were predominantly *C. albicans*. The results were compatible with those of Krogh *et al.*,<sup>[15]</sup> who found *C. albicans* to be the dominating species in oral leukoplakia and lichen planus.

Seto (1986)<sup>[16]</sup> and Lamey *et al.*,<sup>[17]</sup> have used Gram stain as a basic stain for microbial identification of *Candida*. Monheit<sup>[9]</sup> introduced the addition of CFW to PAP stain, without altering or destroying the diagnostic cytopathological features, while still allowing the fungi to be identified. The ability to use CFW in this manner allowed pathologists to confirm the presence of fungi without delay. In the present study, CFW was incorporated into the PAP stain after acid eosin and was observed under the fluorescence microscope. PAP-CFW staining showed a sensitivity and specificity of 85.10% and 88.63%, respectively, with positive and negative predictive values of 80% and 91.76%, respectively. Also, higher percentage of *Candida* was detected with the use of PAP-CFW stain in oral precancer and oral cancer, when compared with that of Gram stain.

Many studies, such as those by Seto,<sup>[16]</sup> Fotos *et al.*,<sup>[18]</sup> and Barrett *et al.*<sup>[19]</sup> recommended the use of PAS stain for the detection of fungi. Cawson<sup>[20]</sup> and Cawson and Lehner<sup>[2]</sup> demonstrated the presence of *Candida* in oral Candidal leukoplakia by using PAS was investigated. In the present study, PAS showed a high specificity (91.11%), and a low sensitivity (66.66%) towards detection of *Candida*.

Darken<sup>[21]</sup> reported that CFW stains fungi. Hageage and Harrington<sup>[13]</sup> used CFW to demonstrate hyphae and yeasts in the paraffin-embedded tissues of mycotic lesions and disclosed that CFW, rapidly stains fungi. In the present study, it was observed that CFW had a higher Candidal detection capacity than PAS.

Renstrup<sup>[22]</sup> reported 32% of homogenous leukoplakia with no atypia were positive for *Candida*, whereas, 60% of speckled



**Figure 10:** Comparison of sensitivity and specificity of PAS and CFW staining procedures.

leukoplakia showed *Candida* hyphae with cellular atypia. In the present study, although 12 cases of leukoplakia were positive by culture, Gram stain and PAP-CFW stain could detect only seven and eight cases respectively, in cytopathology. Similarly PAS and CFW identified seven and eight cases respectively, in histopathology.

In the present study, culture was positive only in one case of lichen planus for *Candida*, but Gram stain and PAS were negative for *Candida* in the same case. However, PAP-CFW and CFW staining of the same case showed the presence of *Candida*. Although, seven of 24 (29.16%) cases of OSMF cases were culture positive for *Candida* growth, Gram staining and PAP-CFW staining was positive for *Candida* in 8 (33.33%) and 13 (54.16%) cases respectively. Similarly, in histopathology, 8 (33.33%) and 9 (37.5) cases were positive for *Candida* by PAS and CFW staining respectively. The lack of published data on the occurrence of *Candida* in oral submucous fibrosis makes comparison of our data with other studies difficult.

A statistically significant association has been found between *Candida* and precancer in the present study ( $\chi^2 = 17.386$ , where  $P < 0.001$ ). Similarly Candidal association in oral cancer was statistically significant ( $P < 0.001$ ). Horstein *et al.*,<sup>[23]</sup> investigated the presence of *Candida* in oral cancer by mycological culture and found the incidence of oral fungi in 71.5% of oral carcinoma cases. In the present study, 55.55% of oral cancer cases were culture positive, whereas, cytopathology using PAP-CFW revealed the presence of *Candida* in 60% of oral cancer cases. In tissue microscopy, CFW and PAS revealed the presence of *Candida* in 55.55% and 42.22% of cases. Association of *Candida* with leukoplakia has been noted in earlier studies, but its association with oral submucous fibrosis has not been declared in many studies. It needs to be establish the role of *Candida* in the causation of precancer and oral cancer.

The use of Calcofluor-White stain in Candidal detection, not

only has a myriad of advantages like rapid detection, higher sensitivity, and specificity over Gram and PAS staining, but is also a unique stain that can detect *Candida* both in smears and tissues, without disturbing the cellular details, under the fluorescence microscope.

## CONCLUSION

As arriving at the diagnosis of *Candida* is a complex subject, this study evaluates the utility of the Calcofluor-White fluorescence method for easy and rapid diagnosis of *Candida*, both in cytopathology and histopathology in precancer and cancer. Calcofluor White staining has a number of advantages over traditional methods. The technique is extremely rapid, requiring less than 30 seconds from preparation of hydrated specimen to viewing of the slide. No specific techniques are required other than routine histological processing and it does not disturb the cellular details. CFW staining also does not interfere with the subsequent Gram or PAS staining when required.

However, further study is definitely required to grade the *Candida* in tissue sections and to find the correlation between presence of *Candida* and epithelial dysplasia in precancer and cancer cases, as also to determine the nature of *Candida*; whether it is one of the causal factors or is it a sole etiological agent for precancer and cancer patients.

## REFERENCES

1. Wiesner SM, Bendel CM, Hess DJ, Erlandsen SL, Wells CL. Adherence of yeast and filamentous forms of *Candida albicans* to cultured enterocytes. *Crit Care Med* 2002;30:677–83.
2. Samarnayake LP, MacFarlane TW. *Oral candidosis*. Butterworth and Co Publishers Ltd; 1990.
3. Field EA, Field JK, Martin MV. Does *Candida* have a role in Oral epithelial neoplasia? *J Med Vet Mycol* 1989;27:277–94.
4. Gerson SJ. Oral Cancer. *Crit Rev Oral Biol Med* 1990;13:153–66.
5. Gold JW. Opportunistic fungal in fungal infections in patients with neoplastic disease. *Am J Med* 1984;76:458–63.
6. Meunier-Carpentier F. Treatment of mycoses in cancer patients. *Am J Med* 1983;74:74–9.
7. Lynch DP, Gibson DK. The use of Calcofluor white in the histopathologic diagnosis of oral candidiasis. *Oral Surg Oral Med Oral Pathol* 1987;63:698–703.
8. Monheit JE, Cowan DF, Moore DG. Rapid detection of fungi in tissues using calcofluor white and fluorescence microscopy. *Arch Pathol Lab Med* 1984;108:616–8.
9. Monheit JG, Brown G, Kott MM, Schmidt WA, Moore DG. Calcofluor white detection of fungi in cytopathology. *Am J Clin Pathol* 1986;85:222–5.
10. Maeda H, Ishida N. Specificity of binding of hexopyranosyl polysaccharids with fluorescent brightness. *J Biochem (Tokyo)* 1967;62:267–78.
11. Harrington BJ, Rasper KB. Use of fluorescent brightener to demonstrate ellulose in ther cellular slime molds. *Appl microbial* 1968;16;106–13.
12. Hageage GJ, Harrington BJ. Use of calcofluor white in clinical mycology. *Lab Med* 1984;15;109–12.
13. Harrington BJ, Hageage GJ. Calcofluor white: Tips for improving its use. *Clin Microbial News* 1991;13:3–5.
14. Mahajan BK. *Methods in Biostastics*. 4<sup>th</sup> ed. Smt. Indu Mahajan Publications; 1984.
15. Krogh P, Homstrup P, Thorn JJ, Vedtofte P, Pindberg JJ. Yeast species and biotypes associated with oral leukoplakia and lichen planus. *Oral Surg Oral Med Oral Pathol* 1987;63:48–54.
16. Seto BG, Tsutsui P. Invasive *Candida albicans* infections of the oral cavity in Immunocomprised Patients. *J Oral Med* 1986;41: 9–13.
17. Lamey PJ, Darwazeh AM, Muirhead J, Rennie JS, Samaranayake LP, MacFarlane TW. Chronic hyperplastic candidosis and secretor status. *J Oral Pathol Med* 1991;20:64–7.
18. Fotos PG, Vincent SD, Hellstein JW. Oral candidosis. *Oral Surg Oral Med Oral Pathol* 1992;74:41–9.
19. Barrett AW, Kingsmill VJ, Speight PM. The frequency of infection in biopsies of oral mucosal lesions. *Oral Dis* 1998;4: 26–31.
20. Cawson RA. Chronic oral candidiasis and leukoplakia. *Oral Surg Oral Med Oral Pathol* 1966;22:582–91.
21. Darken MA. Absorption and transport of fluorescent brightners by microorganisms. *Appl Microbiol* 1962;10:387–93.
22. Rajendran R, Sivapathasundharam R, editor, Shafer's textbook of Oral Pathology. 5<sup>th</sup> ed. New Delhi; Elsevier A division of Reed Elsevier India Private Limited; 2006.
23. Horstein OP, Grassel R, Schirner E, Schell H. Oral candidiasis in leukoplakia and carcinoma of the oral cavity. *Dtsch Med Wochenschr* 1979;104:1033–6.

Source of Support: Nil, Conflict of Interest: None declared.