

Periprosthetic fractures of the proximal femur within first year of the index hip prosthesis

Mauro Spina, Andrea Scalvi

Azienda Ospedaliera Universitaria Integrata of Verona, Department of Orthopedics and Traumatology, Verona, Italy

Summary. *Introduction:* Periprosthetic fractures are a serious complication of implants prosthetic. The aim of this review is to analyze incidence and predisposing factors of periprosthetic fractures of the proximal femur within first year of the index hip prosthesis. *Materials and methods:* Between 1998 and 2017 we have performed 4240 hip replacements (F 2661, M 1579): 2877 total hip arthroplasties (67,9%) and 1363 hemiarthroplasties (32,1%). Hip replacements with cemented stem were 2173 (51,2%), while cementless ones were 2067 (48,8%). In the same period we admitted 121 hip periprosthetic fractures, 26 of which (0,6%) within the first year of the index surgery. We examined the medical and radiographic records of this last cohort of patients (F 19, M 7) following the Vancouver System, Dorr Classification and Stem Size Index. *Results:* The cause was a low-energy trauma in 25 cases (96.1%); the primary diagnosis was hip fracture in 20 patients (76.9%); 8 patients were taking chronic osteoporosis medication (30.7%); 14 patients were affected by neuropsychiatric disease (53.8%); cementless stems were found in 18 cases, 12 of which were oversized (SSI < 0,8). According to Vancouver System, fractures were classified as follows: 10 type B1, 14 type B2 and 2 type C. As far as the proximal femoral shape, 2 cases were Dorr type A, 7 Dorr type B and 17 Dorr type C. *Conclusions:* The incidence of periprosthetic fractures in the aftermath of stem implant is twice as high with uncemented stems. The Vancouver type B1/B2 is the most common. Predisposing factors are: female sex, hip fracture, chronic osteoporosis medication, neuropsychiatric disease and oversized uncemented stem (SSI < 0.8). The evidence level is IV. (www.actabiomedica.it)

Key words: periprosthetic hip fracture, oversize uncemented stem, Stem Size Index, osteoporosis, neuropsychiatric disease

Introduction

Periprosthetic proximal femoral fractures represent the fourth cause of early failure of hip prosthesis after infection, aseptic loosening and dislocation and this incidence is constantly increasing (1-3).

This is a well-known complication of hemi- and arthroplasty, and of primary prosthesis and revision prosthesis which can be both intra- and post-operative (2).

This complication is particularly serious after total hip arthroplasty because the treatment has a high mor-

tality rate: it is also expensive and is associated with low results due to an often incomplete functional recovery (2).

Several studies show how the mortality rates, during the following 12 months, are comparable to those of hip fracture (4,5). Extending the indications of bone fixation also to some B2 fractures may explain lower mortality rates (6).

The aim of this study is to analyse the incidence of determinant predisposing factors and to identify these factors in periprosthetic fractures of the proximal femur within first year of the index hip prosthesis.

Materials and Methods

Between 1998 and 2017 we have performed 4240 hip replacements (F 2661, M 1579): 2877 total hip arthroplasties (THA) (67,9%) and 1363 hemiarthroplasties (HA) (32,1%). Hip replacements with cemented stem were 2173 (51,2%), while cementless ones were 2067 (48,8%). Among THA (F 1829, M 1048) the stem was cemented in 886 cases (30,8%) and cementless in 1991 cases (69,2%). In the HA group (F832, M 531) the stem was cemented in 1287 cases (94,4%) and cementless in 76 cases (5,6%).

In the same period we admitted 121 patients (94 F, 27 M) with a diagnosis of periprosthetic proximal femoral fracture with surgical indication (mean age at fracture was 79.5 years; from 46 to 92) to the Department of Orthopaedics and Traumatology A of the Integrated University Hospital in Verona (Italy).

According to the Vancouver Classification, fractures were classified as follows: 1 type A, 37 type B1, 39 type B2, 18 type B3 e 26 type C.

Melvin JS et al. (1) consider early complications as those that arise in the first 5 years of prosthesis implant, and we selected 61 cases for our case study (50.4% of the overall series). Of these, one case was an intra-operative fracture and 26 occurred within the first postoperative year [Figure 1].

We retrospectively analysed medical and radiographic records of these 26 patients, namely 7 males and 19 females (21.5% of the overall series) with a mean age at fracture of 74.3 years. The data were collected and analysed in compliance with the procedures and policies of the Helsinki Declaration, and all patients gave their informed consent for use of their data.

In 21 cases, trauma was caused by an accidental fall, while in 5 cases there was no apparent trauma for

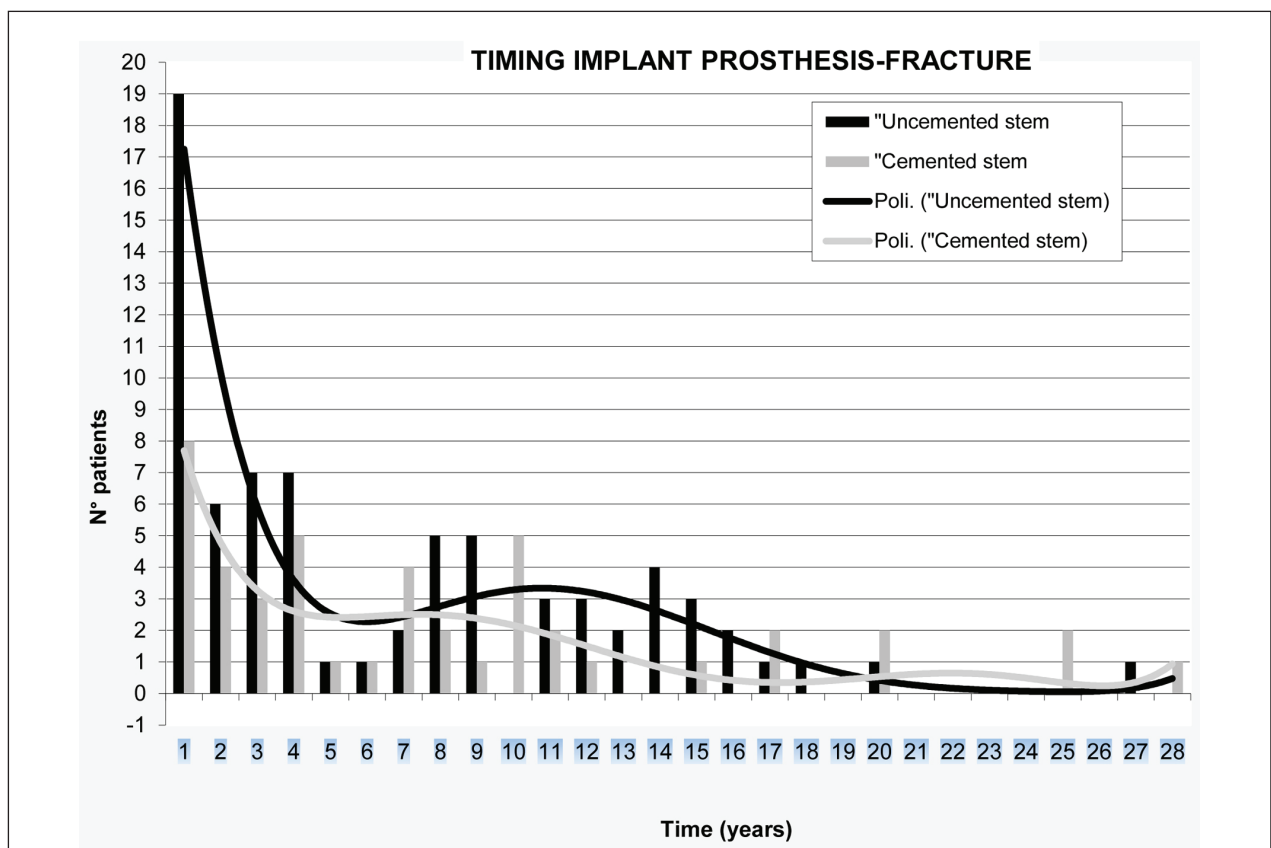


Figure 1.

lower limb failure; as per ASA classification, 13 cases were ASA 2 and 13 were ASA 3. The average waiting time for intervention was 5.7 days (min 0 – max 26). General anaesthesia was employed in 19 cases and in 2 cases general and spinal anaesthesia was used, while in 5 cases spinal anaesthesia alone. Surgical treatment in 22 cases involved fixation with plates and screws, in 2 cases fixation with plates and revision of the stem, in one case simple revision of the stem, and in another case Girdlestone's method was necessary (an autologous bone graft was used in only one case)(7,8).

All fractures occurred on primary prosthetic stems: 23 THA (88.5%) and 3 HA (11.5%), 18 on uncemented stems (69.2%) and 8 on cemented stems (30.8%). 10 fractures were classified as Vancouver type B1, 14 type B2 and 2 type C.

According to the Dorr classification, the proximal femur characteristics were: 2 type A, 7 type B and 17 type C (9). Given the prevalence of fractures on uncemented stems, we defined an index that correlates the morphological characteristics of the proximal femur with the size of the prosthetic stem and we called it Stem Size Index (SSI = A-C/B): diameter of the femur (A) minus diameter of the prosthetic stem (C) / diameter of the intramedullary canal (B), calculated at a distance from the base of the lesser trochanter which is equal to the intramedullary diameter at that specific

point. All parameters were measured on standard anteroposterior radiographs [Figure 2 and 3].

SSI (Stem Size Index)= A-C/B:

A: femoral diameter

B: stem diameter

C: intramedullary canal diameter

Results

An analysis of fractures within the first year of the implant demonstrated that the female sex was the most affected (73.1%); primary diagnosis was a hip fracture in 20 cases (76.9%) and arthritis in 6 cases (23.1%). The cause of periprosthetic fracture was a low-energy trauma in 25 cases (96.1%); 8 cases had received pharmacological treatment for osteoporosis with bone resorption inhibitors for several years (30.7% vs 7.5% in the overall case series of periprosthetic fractures). Lastly, 14 patients (54%) were affected by neuropsychiatric diseases (4 cases of anxiety-depressive syndrome, 2 cases of Parkinson's disease, 1 case of Schizophrenia, 2 cases Alzheimer's disease, 1 case of severe cognitive impairment, 4 cases of stroke-related hemiparesis). According to the Dorr classification we found the following distribution of stem fixation techniques: type A femur, one uncemented stem and one cemented

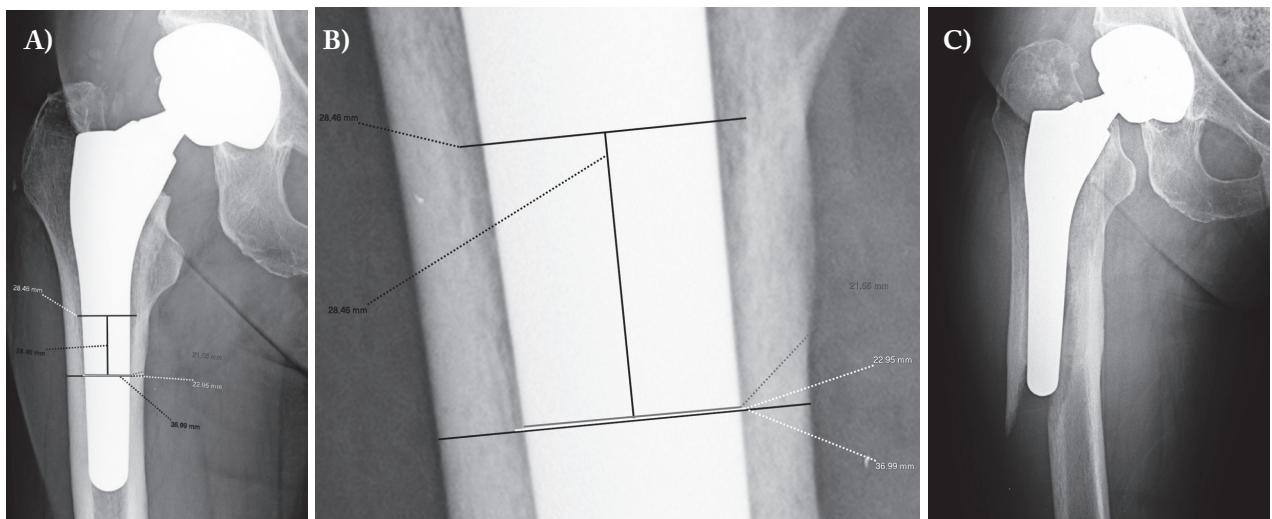


Figure 2.

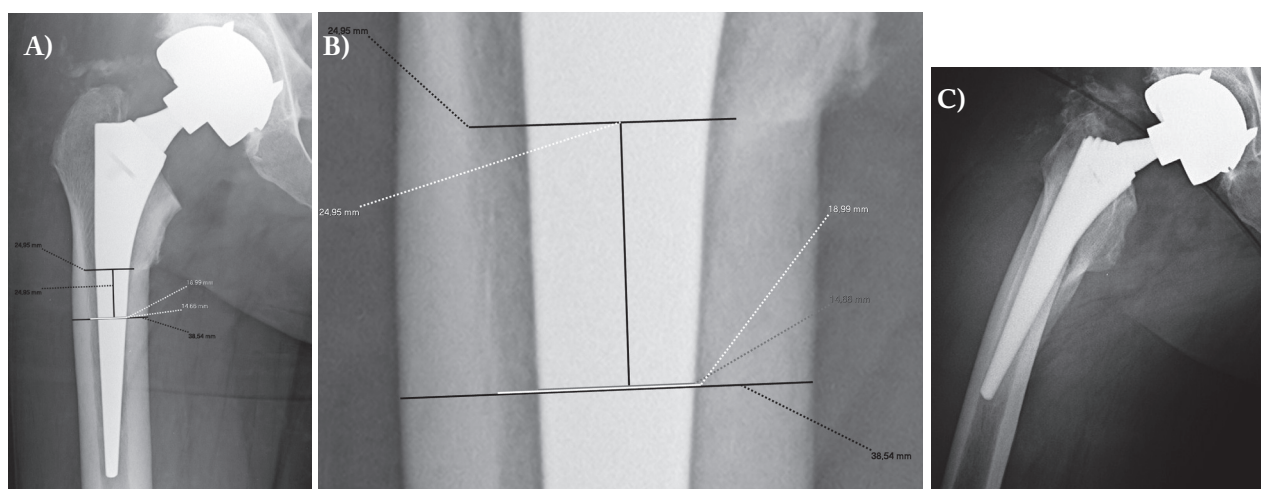


Figure 3.

stem (a patient with pathological fracture of the femoral neck); type B femur, 6 uncemented stems and one cemented stem; type C femur, 11 uncemented stems and 6 cemented stems. The most common fracture was around the stem (Vancouver type B) with 24 cases (10 Vancouver B1 and 14 Vancouver B2). Vancouver Type B fractures on uncemented stems were 18 (69.2%). In 12 cases (4 fractures Vancouver type B1 and 8 type B2) we found an oversizing of the stem (9 straight stems and 3 anatomic stems) with a SSI less than 0.8 [Figure 2]. In one case there was an undersizing of the stem with a SSI of 1.33 [Figure 3] (Vancouver B2 fracture with straight stem) and in the remaining 5 cases there was a stem size which was appropriate to the morphological characteristics of the proximal femur with a SSI between 0.8 and 1.1 [Table 1].

Discussion

The incidence of intra- and post-operative periprosthetic hip fractures, both early and late, is higher on uncemented than on cemented stems (2,10). Moreover in our series, the incidence of early periprosthetic fracture was higher on uncemented stems, more than double within the first year from the implant [Figure 1].

There is lack of evidence in the literature of a minimum time for integration of an uncemented prosthet-

ic stem into the femoral canal. Some authors believe that most of the bone remodelling around the femoral stem occurs during the first 6-12 months from the implant, while others believe that the changes continue over the year (11).

In fact, Brodner W et. al conclude that bone mineral density changes in the proximal femur after an uncemented stem continue up to 5 years from the implant and that both the design and prosthesis material are probably the most important factors that affect bone remodelling (11).

Beals RK and Tower SS assert that uncemented implants do not have a stable mantle around the stem as they do not immediately become fully osseointegrated into host bone, and may initially act as “stress risers”. Thus, periprosthetic fractures around uncemented femoral stems commonly occur only 6 months after insertion, compared with 6.6 years for cemented implants (12).

After bone ongrowth around the stem, the implant is more fixed and periprosthetic fractures should be less frequent (13). Fleischman AN et al argue that successful stem osseointegration precludes the risk of periprosthetic fracture (14).

Associating the above-mentioned considerations with the higher incidence of uncemented periprosthetic fractures occurring within the first year [Figure 1], we can also assert that as long as the uncemented stem is not completely osseointegrated, traumatic

Table 1. Summary table

Patient	Age (years)	Sex	Side	Primary diagnosis	Type prosthesis	Type stem	SSI (Stem Size Index)	Type Dorr	Time prosthesis-fracture	Type Vancouver
1	81	F	DX	AO	THA uncem	Straight	0.68	C	2 months	B1
2	62	F	SX	HF	THA cem	Straight		C	12 months	B1
3	77	F	SX	HF	THA uncem	Anatomic	0.88	B	3 months	B1
4	74	F	SX	HF	THA cem	Straight		C	2 months	B1
5	67	M	SX	AO	THA uncem	Anatomic	0.67	C	8 months	B1
6	65	F	SX	HF	THA ibrid (stem uncem)	Anatomic	0.76	B	2 months	B1
7	46	F	SX	HF	THA cem	Straight		A	7 months	B1
8	76	F	SX	HF	HH cem	Straight		B	2 months	B1
9	85	F	DX	HF	THA uncem	Straight	0.59	B	8 months	B1
10	84	F	DX	HF	THA uncem	Straight	0.82	C	7 months	B1
11	81	M	DX	HF	THA uncem	Straight	0.75	A	1 month	B2
12	64	M	DX	AO	THA uncem	Straight	0.62	C	1 month	B2
13	85	F	DX	AO	THA uncem	Straight	I.F.	A	I.F.	B2
14	66	F	DX	AO	THA uncem	Straight	1.33	B	3 months	B2
15	77	F	DX	HF	THA uncem	Straight	0.74	C	21 days	B2
16	73	M	SX	HF	THA uncem	Anatomic	1.00	B	11 months	B2
17	80	F	DX	HF	THA uncem	Straight	0.65	C	8 months	B2
18	69	F	SX	AO	THA uncem	Straight	0.69	C	12 months	B2
19	70	F	DX	HF	THA uncem	Anatomic	0.65	C	12 months	B2
20	91	F	SX	HF	THA cem	Straight		C	11 months	B2
21	72	M	SX	HF	THA uncem	Straight	0.78	C	2 months	B2 with dislocation
22	92	F	SX	HF	HH cem	Straight		C	5 months	B2
23	84	F	DX	HF	THA uncem	Straight	0.83	C	2 months	B2
24	54	M	SX	HF	THA uncem	Straight	0.75	C	2 months	B2 with dislocation
25	83	F	DX	AO	THA cem	Straight		C	3 months	C
26	92	F	SX	HF	HH cem	Straight		C	3 months	C
27	66	M	SX	HF	THA uncem	Straight	0.83	B	10 days	B2

HF Hip Fracture; AO Osteoarthritis; THA Total Hip Athroplasty; HH Hip Hemiarthroplasty; IF Intraoperative fracture

events can cause fractures around the stem with a much higher frequency than in cemented stems. The risk of fracture is inversely proportional to time from implant and stem osseointegration.

Yoon et al. studied the incidence of periprosthetic fractures after implantation of uncemented bipolar endoprosthesis in a series of 1,563 elderly patients (mean age 79.6 years) and found that 2/3 of fractures (67%) occurred within one year after the implant and most of those which occurred within 2 years were Vancouver type B (15). In a recent study by Taunton et al., most periprosthetic early fractures within 90 days of the primary uncemented total hip arthroplasty implant were Vancouver type B (16). In our series of periprosthetic fractures within one year from the implant 92.3%

(24/26) were also Vancouver type B, 18 of which on uncemented stem.

The choice of stem fixation should rely on bone quality and morphological features of the proximal femur. Dorr et al. classified the conformation of the proximal femur in types A, B, C based on the thickness of bone cortex and on the shape of the intramedullary canal (9). Cemented femoral components are the most commonly used in total hip arthroplasty on patients with C-type femur, having a low bone quality and enlarged conformation of the proximal femur (17). Some authors, instead, indicate the use of uncemented femoral component in young patients with type A and B femur (17). A retrospective analysis of our cases of periprosthetic fractures within the year from the im-

plant revealed an excessive use of uncemented stems in femur type C (11/17). To achieve immediate primary stability, through maximum press-fit/fit-fill, we used stems of large diameter in large femoral canals with often thin bone cortices. Since there are no parameters in the literature to define the correct size of the stem, we associated the morphological features of the proximal femur with stem size and obtained a parameter that we defined as Stem Size Index (SSI). This parameter correlates the thickness of the femoral cortex and the diameter of the stem at a distance from the base of the lesser trochanter which is equal to the intramedullary diameter at that specific point.

When thickness of the cortices decreased, the diameter of the intramedullary canal and of the prosthetic stem increased, and the SSI was less than 0.8 and the stem was oversized.

Conversely, when the thickness of the cortices increased and the diameter of the stem decreased, the SSI was greater than 1.1 and the stem was undersized.

The implantation of a rigid orthopaedic device, such as the prosthetic stem, inside the canal of a long bone generates an area of high stress concentration defined as a "stress riser". Biomechanical studies showed that the "stress riser" effect is clearly dependent on cortical density; in fact, the stress peak increases as the cortical thickness decreases. Beals RK and Tower SS consider that a femur with a cementless stem prosthesis appears to be more prone to an early fracture, due to cortical stress risers and defects created by the reaming and broaching of the femoral canal (12).

Therefore the cementless stem prosthesis generates a concentration of cortical stress to the surrounding femur that is much higher as the cortical thickness decreases and the stem diameter increases. In the presence of a prosthetic stem that is not yet fully integrated and high cortical stress, a traumatic event increases the risk of periprosthetic fracture.

There are several radiographic indices in the literature that establish bone quality and the risk of femoral fracture but they only consider morphological features of the proximal femur: Morphological Cortical Index (MCI), Canal Bone Ratio (CBR) and Canal-Flare Index (CFI) (18). Stem Size Index (SSI) correlates morphological features of the proximal femur with the size of the implanted uncemented stem.

This index can be a predictive factor of femoral fracture for a not fully integrated stem. The lower SSI is under 0.8, the greater the risk of periprosthetic fracture in the immediate postoperative period.

Most of the traumatic events that cause a periprosthetic fracture are a low energy traumas (19,20). The Swedish register reports that 75% of periprosthetic fractures are due to low energy trauma. In our series within one year from the implant, a low-energy trauma event is present in over 96% of cases.

Osteoporosis is generally accepted as a risk factor for late periprosthetic femoral fractures (PFF) (21). In our series 8 patients (30.8%) who reported a PFF within the first year from the implant took chronic medications with bisphosphonates and vitamin D (an incidence that is significantly higher than 7.5% in the overall series) and 6 of these patients had an uncemented stem. Bone tissue undergoing long-term pharmacological therapy with bone resorption inhibitors shows a hyper-accumulation of minerals that makes it harder and less elastic (22); the bone becomes more fragile and more susceptible to atypical fractures, for example, femoral shaft fractures. When a not fully integrated uncemented stem is subject to trauma, the atypical femoral fracture could become complete around the stem (23).

As far as gender is concerned, most series in the literature consider the female sex as being at a greater risk of PFF, with rates ranging from 52% to 70% (24). The Nordic Register, regarding the risk of periprosthetic fracture of the hip, reports that the use of uncemented stem should be avoided in older patients, females and patients with an initial diagnosis of femoral neck fracture (25). In our series of PFFs within the first year from the implant, the female sex (73.1%) and the primary diagnosis of femoral neck fracture (76.9%) are clearly prevalent. The significance of female sex prevalence is probably multifactorial, instead the prevalence of femoral neck fracture is attributable to the association of osteoporosis with a particular bone structure.

Lastly, PFFs are more frequent in patients with neuropsychiatric diseases (Parkinson's disease, Alzheimer's disease, anxiety-depression disease) (21,25). In our study, more than half of the patients were affected by neuropsychiatric diseases: 14 patients, of which 9

had an uncemented stem. Thien TM et al. believe that until the uncemented stem does not have a complete biological fixation, and the femur that hosts it may be more prone to fracture in the presence of a hip trauma (25). As these patients are unreliable and more at risk of trauma (as a result of more frequent falls), PFFs are a serious complication in the period immediately after surgery.

The strength of this study is the possibility to analyze the risk factors of periprosthetic fracture of the proximal femur within the first year of index prosthesis

[Table 2], where the incidence of fracture in our series was significantly high, but presents a great limitation in the small number of cases, which prevents a statistical analysis.

Conclusions

Although this study examines a small number of patients, from the analysis of the data we can conclude that the risk of Vancouver type B1/B2 PFFs within the

Table 2. Review of the literature on risk factors for periprosthetic fracture of the proximal femur

First author	Publication year	Country	Case	Age (years)	Type prosthesis	Follow Up	Significant risk factors
Meek et al (26)	2011	United Kingdom	508	73.9	Total Hip Replacemnt	>5 years	Female, older age and post-revision arthroplasty
Singh et al (27)	2013	United States	305	>60	Total Hip Artroplasty	6.3 years	Female, Deyo-Charlson comorbidity score of 2, ASA score of 2 or higher and cemented implant
Berend et al (28)	2006	United States	59	67.1	Total Hip Artroplasty	6.8 years	Anterolateral approach, uncemented femoral fixation, and female sex
Servilinna et al (29)	2004	Finland	31	71	Total Hip Artroplasty	not reported	Primary diagnosis of fracture
Cook et al (30)	2008	United Kingdom	124	67.1	Total Hip Artroplasty	Up to 17 years	Older age, cemented arthroplasties
Servilinna et al (31)	2005	Finland	16	80	Hip Arthroplasty	not reported	Low age at the time of the hip fracture operation and polished wedge type of prosthesis
Zhang (32)	2012	China	26	50.6	Total Hip Replacement	not reported	Cemented arthroplasties, revision, osteoporosis, history of trauma
Wu et al (33)	1999	China	16	65.6	Hip arthroplasty	3 years	Old age, osteoporosis, low flare index
Spina et al	2020	Italy	26	74.3	Total Hip Arthroplasty and Hip Hemiarthroplasty	1 year	Uncemented stem, sex female, primary diagnosis of hip fracture, osteoporosis, neuropsychiatric disease and oversized uncemented stem (Stem Size Index < 0.8)

first year from the implant is much higher in patients with uncemented stem.

The overall incidence of periprosthetic hip fracture was twice as high in uncemented stems as in cemented stems within the first year. Predisposing factors of periprosthetic fracture in the immediate post-operative implant are: female sex, femoral neck fracture, chronic osteoporosis medication, neuropsychiatric disease and oversizing of uncemented stem with SSI < 0.8.

Patient consent: All the patients provided informed consent before being enrolled.

Open Access: This article is distributed under the terms of the Creative Commons Attribution 4.0 International License (<http://creativecommons.org/licenses/by/4.0/>), which permits unrestricted use, distribution, and reproduction in any medium, provided you give appropriate credit to the original author(s) and the source, provide a link to the Creative Commons license, and indicate if changes were made.

Conflict of interest: Each author declares that he or she has no commercial associations (e.g. consultancies, stock ownership, equity interest, patent/licensing arrangement etc.) that might pose a conflict of interest in connection with the submitted article

References

- Melvin JS, Karthikeyan T, Cope R, Fehring TK. Early failures in total hip arthroplasty – a changing paradigm. *J Arthroplasty*. 2014 ; 29(6):1285-8.
- Sidler-Maier CC, Waddell JP. Incidence and predisposing factors of periprosthetic proximal femoral fractures: a literature review. *International Orthopaedics*. 2015 ; 39(9):1673-82.
- Zhang T, Zheng C, Ma H, Sun C. Causes of early failure after total hip arthroplasty. *Zhonghua Yi Xue Za Zhi*. 2014 ; 94(48):3836-8.
- Young SW, Walker CG, Pitto RP. Functional outcome of femoral periprosthetic fracture and revision hip arthroplasty: a matched-pair study from the New Zealand Registry. *Acta Orthop*. 2008 ; 79(4):483-488.
- Bhattacharyya T, Chang D, Meigs JB, Estok DM 2nd, Malchau H. Mortality after periprosthetic fracture of the femur. *J Bone Joint Surg (Am)*. 2007 ; 89(12):2658-62.
- Spina M, Rocca G, Canella A, Scalvi A. Causes of failure in periprosthetic fractures of the hip at 1- to 14-year follow-up. *Injury*. 2014 Dec;45 Suppl 6:S85-92.
- Khan T, Grindlay D, Ollivier BJ, Scammell BE, Manktelow AR, Pearson RG. A systematic review of Vancouver B2 and B3 periprosthetic femoral fractures. *Bone Joint J*. 2017 Apr;99-B(4 Supple B):17-25.
- Spina M, Scalvi A. Vancouver B2 periprosthetic femoral fractures: a comparative study of stem revision versus internal fixation with plate. *Eur J Orthop Surg Traumatol*. 2018 Aug;28(6):1133-1142.
- Dorr LD, Faugere MC, Mackel AM, Gruen TA, Bogner B, Malluche HH. Structural and cellular assessment of bone quality of proximal femur. *Bone*. 1993 ; 14(3):231-42.
- Lindahl H. Epidemiology of periprosthetic femur fracture around a total hip arthroplasty. *Injury*. 2007 ; 38(6):651-654.
- Brodner W, Bitzan P, Lomoschitz F, Krepler P, Jankovsky R, Lehr S, et al. Changes in bone mineral density in the proximal femur after cementless total hip arthroplasty. A five-year longitudinal study. *J Bone Joint Surg Br*. 2004 ;86(1):20-6.
- Beals RK, Tower SS. Periprosthetic fractures of the femur. An analysis of 93 fractures. *Clin Orthop Relat Res*. 1996 ;(327):238-46.
- Iesaka K, Kummer FJ, Di Cesare PE. Stress risers between two ipsilateral intramedullary stems: a finite-element and biomechanical analysis. *J Arthroplasty*. 2005 ;20(3):386-91.
- Fleischman AN, Chen AF. Periprosthetic fractures around the femoral stem: overcoming challenges and avoiding pitfalls. *Ann Transl Med*. 2015 ;3(16):234.
- Yoon BH, Lee YK, Jo WL, Ha YC, Choi DH, Koo KH. Incidence and Risk period of periprosthetic femoral fracture after cementless bipolar hemiarthroplasty in elderly patients. *J Arthroplasty*. 2016 ; 31(6):1326-30.
- Taunton MJ, Dorr LD, Long WT, Dastane MR, Berry DJ. Early postoperative femur fracture after uncemented collarless primary total hip arthroplasty: characterization and results of treatment. *J Arthroplasty*. 2015 ; 30(11):2008-11.
- Lachiewicz PF. Cement fixation of the femoral component in older patients. *Instr Course Lect*. 2008; 57:261-5
- Yeung Y, Chiu KY, Yau WP, Tang WM, Cheung WY, Ng TP. Assessment of the Proximal Femoral Morphology using Plain Radiograph – Can it predict the bone quality? *J Arthroplasty*. 2006 ; 21(4):508-13.
- Lindahl H, Malchau H, Herberts P, Garellick G. Periprosthetic femoral fractures classification and demographics of 1049 periprosthetic femoral fractures from the Swedish National Hip Arthroplasty Register. *J Arthroplasty*. 2005 ; 20(7):857-65.
- Valentini R, Martino M, De Fabrizio G, Fancellu G. Periprosthetic fractures of the femur: our experience. *Acta Biomed*. 2014 May 9; 85(1):35-43.
- Haddad FS, Masri BA, Garbuz DS, Duncan CP. The prevention of periprosthetic fractures in total hip and knee arthroplasty. *Orthop Clin North Am*. 1999 ; 30(2):191-207.
- Odvin CV, Zerwekh JE, Rao DS, Maalouf N, Gottschalk FA, Pak CY. Severely suppressed bone turnover: a potential complication of alendronate therapy. *J Clin Endocrinol Metab*. 2005 ; 90(3):1294-1301.
- Woo SB, Choi ST, Chan WL. Atypical periprosthetic femoral fracture: a case report. *J Orthop Surg*. 2016 ; 24(2):269-72.
- Franklin J, Malchau H. Risk factors for periprosthetic femoral fracture. *Injury*. 2007 ;38(6):655-60.

25. Thien TM, Chatziagorou G, Garellick G, Furnes O, Havelin LI, Mäkelä K, et al. Periprosthetic femoral fracture within two years after total hip replacement: analysis of 437,629 operations in the Nordic Arthroplasty Register Association Database. *J Bone Joint Surg Am.* 2014 ; 96(19):e167.
26. Meek R, Norwood T, Smith R, Brenkel IJ, Howie CR. The risk of peri-prosthetic fracture after primary and revision total hip and knee replacement. *J Bone Joint Surg Am.* 2011;93:96–101.
27. Singh JA, Jensen MR, Harmsen SW, Lewallen DG. Are gender, comorbidity, and obesity risk factors for postoperative periprosthetic fractures after primary total hip arthroplasty? *J Arthroplasty.* 2013;28:126–131.
28. Berend ME, Smith A, Meding JB, Ritter MA, Lynch T, Davis K. Long-term outcome and risk factors of proximal femoral fracture in uncemented and cemented total hip arthroplasty in 2551 hips. *J Arthroplasty.* 2006;21:53–59.
29. Sarvilinna R, Huhtala H, Sovelius, Halonen PJ, Nevalainen JK, Pajamäki KJ. Factors predisposing to periprosthetic fracture after hip arthroplasty: A case (n = 31)-control study. *Acta Orthop Scand.* 2004;75:16–20.
30. Cook R, Jenkins P, Walmsley P, Patton JT, Robinson CM. Risk factors for periprosthetic fractures of the hip: A survivorship analysis. *Clin Orthop Relat Res.* 2008;466:1652–1656.
31. Sarvilinna R, Huhtala H, Pajamäki J. Young age and wedgedesign are risk factors for periprosthetic fracture after arthroplasty due to hip fracture: A case-control study. *Acta Orthop.* 2005;76:56–60.
32. Zhang C. Analysis on relevant factors of around prosthesis fracture after total replacement. *Mod Prev Med.* 2012;39:3961–3963.
33. Wu CC, Au MK, Wu SS, Lin LC. Risk factors for postoperative femoral fracture in cementless hip arthroplasty. *J Formos Med Assoc.* 1999 Mar;98(3):190–4.

Received: 1 May 2020

Accepted: 15 May 2020

Correspondence:

Mauro Spina

Azienda Ospedaliero Universitaria Integrata of Verona

Department of Orthopedics and Traumatology

Piazzale A. Stefani n. 1 - 37126, Verona, Italia

Tel. 3495307080-0458122465

Fax 0458123536

E-mail: spina.mauro@gmail.com