

Benefit of “transparent soft-short-hood on the scope” for colonoscopy among experienced gastroenterologists and gastroenterologist trainee: a randomized, controlled trial

Varayu Prachayakul · Pitulak Aswakul · Julajak Limsrivilai ·
Soros Anuchapreeda · Patommatat Bhanthumkomol ·
Pimsiri Sripongpun · Tanyawat Prangboonyarat · Udom Kachintorn

Received: 15 June 2011 / Accepted: 21 September 2011 / Published online: 1 November 2011
© The Author(s) 2011. This article is published with open access at Springerlink.com

Abstract

Background The attachment of a transparent hood to the colonoscope tip has been reported to offer some benefits, such as enabling the endoscopist to perform the colonoscopy more easily and to save time. However, there have been no randomized, controlled trials concerning these benefits, nor have any reports been published regarding the use of hoods for the purpose of training colonoscopists. Therefore, we conducted this study to evaluate the possible benefits of the transparent soft short hood when used by both experienced and trainee endoscopist groups.

Methods This randomized, controlled trial to assess the results of using a transparent soft short hood attached to the tip of the colonoscope was undertaken by two groups of investigators: experienced endoscopists and gastroenterologist trainees. The cecal and ileal intubation times, as well as the doses of sedative medication required, were analyzed.

Results A total of 112 patients, 65 of whom were female, underwent colonoscopy by 2 endoscopists and 5 gastroenterologist trainees. Colonoscopy was complete in 100% of the patients. The study showed significant shortening of the cecal intubation time when using the soft short hood, in both the endoscopist and gastroenterologist trainee groups (6.8/4.61 min, $P = 0.006$; and 9.36/7.36 min, $P = 0.03$).

The ileal intubation time had a trend to be significantly less when using the transparent hood in the trainee group (126.4/52.9 s), although this was not statistically significant ($P = 0.08$). The average dose of propofol, when using the transparent hood, was significantly lower in the endoscopist group (180/120 mg, $P = 0.001$). No significant complications occurred in the hood or non-hood groups.

Conclusions The transparent soft short hood shortened the cecal intubation time in both the experienced endoscopist and gastroenterologist trainee groups, as well as reducing the dose of sedative medication required in the experienced endoscopist group. Interestingly, it also reduced the trainee ileal intubation time. The attachment of this type of hood enabled both the experienced endoscopists and gastroenterological trainees to perform colonoscopy more quickly and easily, without any complications.

Keywords Transparent hood · Colonoscopy · Cecal intubation time · Ileal intubation time

Colonoscopy is one of the most common endoscopic procedures and is undertaken for many reasons. Recent recommendations regarding colon cancer screening have led to an upsurge in requests. However, this can be a lengthy and difficult procedure to perform, especially for inexperienced colonoscopists. There also is concern regarding the risk of serious complications. Another factor is that the longer the average time taken to perform colonoscopy, the longer the time spent by patients on the waiting list becomes, which can result in delayed definitive diagnosis, potentially adversely affecting those with serious illness.

Auxiliary devices and techniques that improve skill levels are therefore to be welcomed. Recent studies have

V. Prachayakul · J. Limsrivilai · S. Anuchapreeda ·
P. Bhanthumkomol · P. Sripongpun · T. Prangboonyarat ·
U. Kachintorn

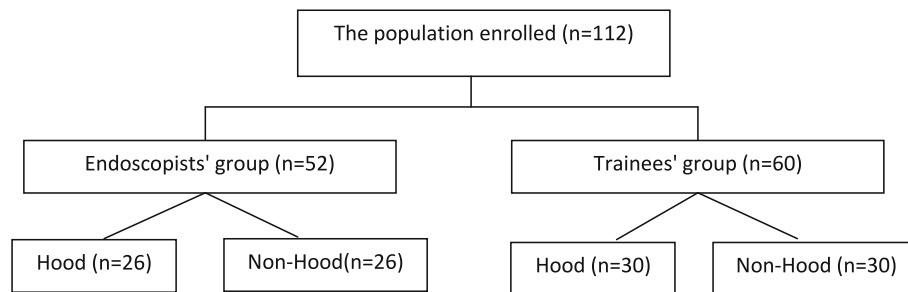
Division of Gastroenterology, Department of Internal Medicine,
Siriraj Hospital, Mahidol University, Bangkok, Thailand

V. Prachayakul · P. Aswakul (✉) · U. Kachintorn
Siriraj Endoscopy Center, Siriraj Hospital, Mahidol University,
Bangkok, Thailand
e-mail: asawakul@gmail.com; apitulak@gmail.com

reported on the use of devices attached to the colonoscope to allow endoscopists to perform this procedure more easily. Harada et al. [1] described the apparent benefit of transparent hoods (hard and long) in shortening the cecal intubation time, even though this was without statistical significance. A reduction in patient discomfort also was noted. Kondo et al. [2] reported that a soft hood reduced the cecal intubation time and enhanced the success rate of colonoscopy, especially for trainee endoscopists.

We conducted this study to identify the potential benefits of this specific type of the hood in terms of cecal

whether the hood will benefit both experienced and inexperienced performers. We used the stratified randomization method by the status of the performers, such as the flow chart below. First, the patients were randomized to undergo the procedure by one of the two endoscopists who had performed more than 1,500 colonoscopies or by one of the five GI fellowship trainees with experience of more than 150 cases. Then, the patients were randomized to be in the “with hood” or “without hood” group via the web-based program, www.randomization.com, using the block randomization.



intubation time, ileal intubation time, colonoscopy success rate, complications, and amount of sedative medication required. In addition, we wished to establish whether this device could improve colonoscopy training.

Materials and methods

From August 2010 to October 2010, the patients in the age range 18–90 years, who were scheduled for elective colonoscopy based on a wide variety of indications, were invited to participate in this study at our center. Those who expressed interest received an oral and written explanation of the purpose and procedures of the trial and were asked to give their written, informed consent. Computerized random number assignment to the different groups was employed.

We excluded the patients who had previously undergone colon resection or any kind of pelvic surgery, due to the risk of complications related to postoperative adhesions. All of the study population had colon preparation before the procedure, with sodium phosphate solution or polyethylene glycol. The bowel preparation quality, which potentially could have an effect on the cecal intubation time, was classified into four groups: (1) excellent—clear fluid, no solid content; (2) good—turbid fluid, no solid content; (3) fair—less than 20% of solid content; and (4) poor—more than 20% of solid content.

Regarding the authors' concern that the performer's experience would have some impact on the result of the study, we would like to focus on the research question of

In our study, we used the soft-short-hood colonoscopic cap (D-201-11304, Olympus, Tokyo, Japan) as shown in Fig. 1. For ethical reasons, if the GI fellow trainee could not approach the cecum within 30 min, the procedure would be performed by an experienced endoscopist and that case would be recorded as a “failed cecal intubation.” The cecal intubation time was recorded in minutes, and the ileal intubation time in seconds. The cecal intubation time was calculated from the start of anal intubation until the tip of the scope was inserted beyond the ileocecal valve, following identification of the appendiceal orifice and the ileocecal valve. The ileal intubation time began from the moment that the endoscopist was ready to commence ileal intubation and finished when the scope tip was steady in the ileum. The doses of sedative medication were recorded in milligrams, and the endoscopist or the trainee who performed the colonoscopy recorded a score (from 1 to 5) for visibility and ease of cecal and ileal intubation in each case in the hood group. The endoscopic findings were recorded in the details, with a note made of any polyps detected.

Statistics

Descriptive statistics were used to summarize baseline demographic, clinical characteristics, and radiographic data. Continuous variables were reported as mean (with median). The compared data was analyzed using χ^2 or Fisher exact test. A value of $P < 0.05$ was regarded to be significant. All statistical evaluation was performed by using SPSS version 11.3 software.

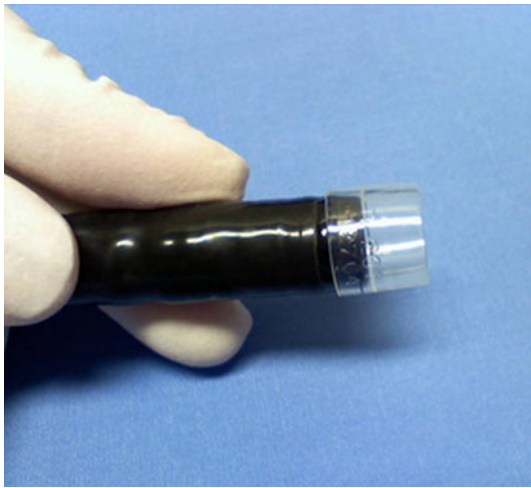


Fig. 1 Soft-short-hood (D-201-11304, Olympus, Tokyo, Japan)

Results

Overall, 112 cases were included in this study. The patients' baseline characteristics are shown in Table 1. The mean age of the study population was 55.9 years in the endoscopist group, 54.6 years in the trainee group,

55.3 years in the hood group, and 55.2 years in non-hood group respectively. There were no statistical differences in the patients' baseline characteristics between these two stratified groups.

The baseline characteristics of the hood and non-hood groups for both endoscopist and trainee groups are shown in Table 2. There were no statistically significant differences between the hood and non-hood groups.

A comparison of the data and endoscopic findings in the hood and non-hood groups, which was stratified by the performer's status, is shown in Table 3.

There was a significant shortening of the cecal intubation time when using the hood in the endoscopist group: from 6.8 to 4.6 min ($P = 0.006$), and the dose of propofol was significantly lower in the hood arm as well. The cecal intubation time also was shorter in the trainees' group when the hood was attached: from 9.4 to 7.4 min ($P = 0.03$). The ileal intubation time trended to be shorter in the hood group for the trainees, even though it was not statistically significant. We assessed reductions in the cecal intubation time by setting separate time thresholds for each investigator group using the ROC curve. For the endoscopist group, more than 60% of the hood cases were performed in less than 5 min compared with only 20% of the

Table 1 Baseline characteristics of the hood/non-hood group and the endoscopist and trainee groups

Details	Hood	Non-hood	<i>P</i> value	Endoscopists' group (<i>n</i> = 52)	Trainee's group (<i>n</i> = 60)	<i>P</i> value
Age (years)	55.2 (27–90)	55.3 (26–83)	NS	55.9 (27–81)	54.6 (26–90)	NS
Male:female ratio	21:35	26:30	NS	23:29	24:36	NS
Weight (kg)	61.4 (41–109)	60.9 (38–97)	NS	61.2 (45–82)	61.0 (38–109)	NS
Height (cm)	161 (143–177)	162 (161–174)	NS	160 (149–177)	161 (143–175)	NS
Body mass index (BMI)	23.6 ± 4.3	23 ± 4	NS	23.33 ± 3.3	23.4 ± 4.9	NS
Indications for colonoscopy (%)			NS			NS
Screening	26.8	21.4		23	25	
Lower GI bleeding	14.3	12.5		11.5	15	
Chronic diarrhea	10.7	10.7		5.8	15	
Suspicious for malignancy	30.4	28.6		36	23	
Constipation	7.1	5.4		7.7	5	
Abdominal pain	5.4	4.7		13.5	3	
Follow-up	3.6	1.8		0	3	
Others	1.8	8.9		0	10	
Bowel preparation quality (%)			NS			NS
Excellent	25	33.9		42	18.7	
Good	41.1	33.9		35	40	
Fair	26.8	23.2		13	35	
Poor	7.1	8.9		10	6.7	
Sedative techniques (%)			NS			NS
Total IV anesthesia	100	96.4		100	96.7	
Conscious sedation	0	3.6		0	3.3	

NS not significant

non-hood cases. For the trainee group, 70% of the hood cases, but only 40% of the non-hood cases, achieved a cecal intubation time of less than 9 min (Fig. 2).

We also evaluated the user satisfaction by employing a scoring system. The results were classified as satisfactory (score 4–5) or unsatisfactory (score 1–3). More than 80% of the investigators in both the endoscopist and trainee groups considered the hood to be satisfactory. The results are summarized as Fig. 3.

Discussion

Colonoscopy currently remains the most popular, reliable, and accurate investigation for the detection and diagnosis of colorectal lesions. However, incomplete colonoscopy has been reported in approximately 5–10% of patients examined, even in the hands of experienced endoscopists. In addition, inexperienced endoscopists usually take longer to complete this procedure. To solve these problems, the use of variable-stiffness colonoscopes, the water

immersion technique, shape-locking over tubes, and balloon-assisted colonoscopy have been reported to be useful.

The transparent cap attached to the tip of the colonoscope has been reported to shorten the cecal intubation time and increase the polyp detection rate, particularly by inexperienced endoscopists, but only limited data are available to confirm these benefits [2, 3]. Our study confirmed shorter cecal intubation times for both experienced and trainee endoscopists. This type of hood made it easier to find the lumen while rotating the colonoscope by stretching the mucosal folds, thereby reducing resistance to manipulation of the tip of the scope over the mucosal wall until the colonic lumen could be clearly visualized. As a result, the angles between the sigmoid, descending colon, splenic, and hepatic flexures were straightened out more quickly. Although ileal intubation is not a difficult technique for experienced endoscopists, the transparent cap was shown to help inexperienced endoscopists to identify and stabilize the IC valve and open it up more easily. This resulted in faster ileal intubation, which has never been previously reported. In our study, there was a trend that this device might shorten trainees' ileal intubation times, even

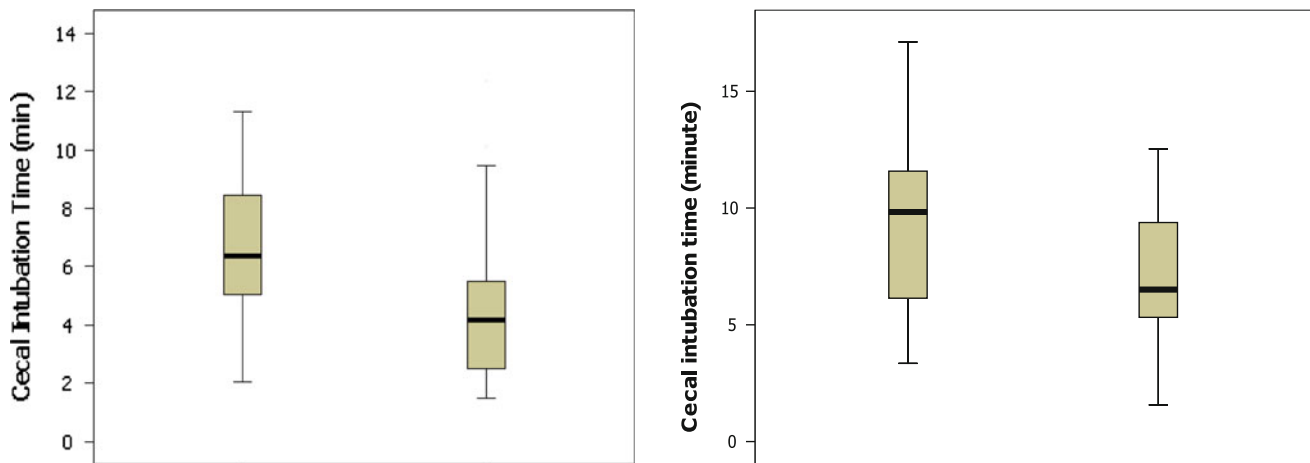
Table 2 Baseline characteristics of the hood and non-hood groups stratified by the performers

Details	Endoscopists' group			Trainees' group		
	Hood (n = 26)	Non-hood (n = 26)	P value	Hood (n = 30)	Non-hood (n = 30)	P value
Age (years)	55.8 ± 12.2	56 ± 12.5	NS	54.43 ± 16.5	54.87 ± 14.2	NS
Male:female ratio	9:17	14:12	NS	12:18	12:18	NS
Weight (kg)	61 ± 9.5	61.5 ± 10.4	NS	61.7 ± 16.1	60.3 ± 14	NS
Height (cm)	161.5 ± 6.8	162.3 ± 7.6	NS	160.2 ± 8.1	162 ± 7	NS
Body mass index (BMI)	23.3 ± 3.3	23.2 ± 3.2	NS	23.9 ± 5.1	22.8 ± 4.7	NS
Indications for colonoscopy (%)			NS			NS
Screening	19.2	26.9		26.4	23.1	
Lower GI bleeding	11.5	11.5		16.5	13.2	
Chronic diarrhea	3.8	7.6		13.2	16.5	
Suspicious for cancer (altered bowel habit, tenesmus, FOB+)	34.6	38.4		23.1	23.1	
Constipation	3.8	11.5		3.3	6.7	
Abdominal pain	23	3.8		6.7	0	
Follow-up	3.8	0		6.7	0	
Others	0	0		3.3	16.5	
Bowel preparation quality (%)			NS			NS
Excellent	34.6	50		20	16.7	
Good	42.3	26.9		40	40	
Fair	15.4	11.5		33.3	36.7	
Poor	7	11.3		6.7	6.7	
Sedative techniques (%)			NS			NS
Total IV anesthesia	100	100		100	93.3	
Conscious sedation	0	0		0	6.7	

NS not significant

Table 3 Data of the hood and non-hood groups

Details	Endoscopist group			Trainee group		
	Hood (<i>n</i> = 26)	Non-hood (<i>n</i> = 26)	<i>P</i> value	Hood (<i>n</i> = 30)	Non-hood (<i>n</i> = 30)	<i>P</i> value
Success rate (%)	100	100		100	100	
Cecal intubation time (min)	4.61 ± 2.8	6.8 ± 2.7	0.006	7.36 ± 3.3	9.36 ± 3.7	0.03
Ileal intubation time (s)	41.7 ± 68.3	59.2 ± 71.2	NS	52.9 ± 81.9	126.4 ± 213.2	0.08
Withdrawal time (min)	6 ± 2.6	6.9 ± 2.8	NS	7.84 ± 4.1	8.13 ± 2.8	NS
Endoscopic finding (%)			NS			NS
Normal	73.1	57.7		56.7	50	
Polyp	26.9	26.9		33.3	43.3	
Cancer	0	3.8		3.3	0	
Ulcer	0	3.8		0	0	
Others	0	7.7		6.7	6.7	
Sedative medications (mg)						
Propofol	127.3 ± 33.2	184 ± 68.1	0.001	194.8 ± 104	187.5 ± 91.4	NS
Midazolam	0.9 ± 0.5	1 ± 0.4	NS	1.2 ± 0.7	0.9 ± 0.6	NS
Fentanyl	47.3 ± 12.2	46.2 ± 11.6	NS	49.2 ± 18.4	45.5 ± 16.2	NS

**Fig. 2** The cecal intubation time of endoscopists' group (*left*) and trainees' group (*right*)

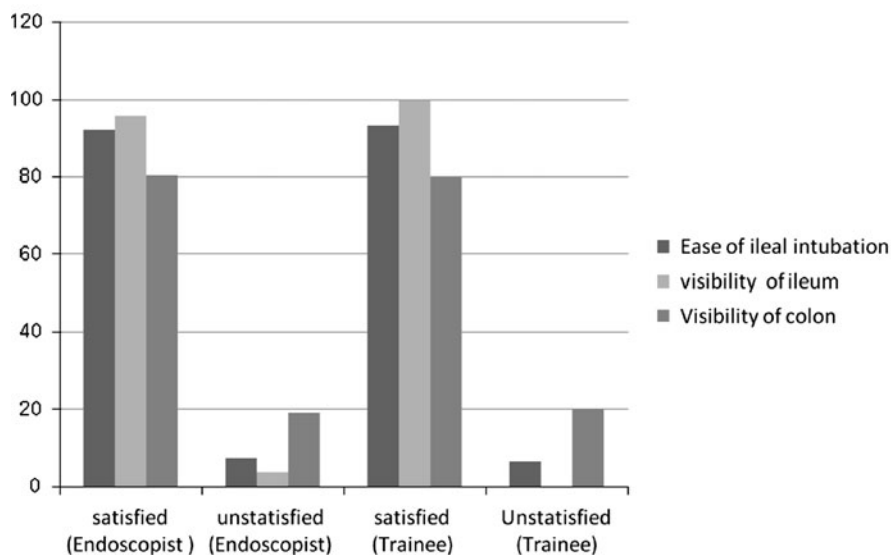
though this finding was not statistically significant. The benefits of attaching a soft short hood to the colonoscope's tip have been reported in some studies [1–5], but our study is the first, to our knowledge, to confirm the usefulness of this device for colonoscopy training. The benefit of shortening the cecal intubation time in this study, only 1.2 and 2.0 min in the endoscopists' and trainee's group respectively, might not be clinically benefit for saving the time for just one procedure, although it might be beneficial for the center that has a lot of procedures each day. Some studies have reported that this device reduces patient discomfort. At our center, we always use propofol for anesthesia in colonoscopy cases to avoid patient discomfort. Other centers have reported using different sedation procedures in their studies. As a result of the faster cecal intubation times in the endoscopist group, the dosage of

sedative medication required was reduced, leading to lower total costs for the procedure.

Although the polyp detection rate (or adenoma miss rate) was shown to be better in the hood group in some studies [4], this positive finding could not be confirmed in our study (polyp detection rate of 26–43%) this might be inferred from a small sample size. There were no differences in the bowel preparation quality or the standard colonoscopy withdrawal time between the hood and non-hood groups.

Even though the present study was the randomized, controlled trial, there were some limitations, such as small numbers of patients and bias of the procedure performers, especially evaluation of the satisfaction of using the device because of the study design, which could not be the "double-blind method."

Fig. 3 Percent of satisfaction about using hood during colonoscopy in both groups



Conclusions

Our study showed that, in a randomized control trial, this type of soft short hood attached to the colonoscope's tip reduced the cecal intubation time for both experienced and inexperienced endoscopists, without compromising the polyp detection rate or increasing the rate of procedure-related complications. The device was shown to reduce the dose of sedative medications required in the endoscopist group, resulting in cost savings for patients. We also can conclude that this hood has the potential to aid colonoscopy training in the future.

Acknowledgment This study is supported by Siriraj Research Development Fund (Managed by Routine to Research: R2R).

Disclosures Dr. Varayu Prachayakul, Dr. Pitulak Aswakul, Dr. Julajak Limsrivilai, Dr. Soros Anuchapreeda, Dr. Patommatat Bhanthumkomol, Dr. Pimsiri Sripongpun, Dr. Tanyawat Prangboonyarat, and Dr. Udom Kachintorn have no conflicts of interest or financial ties to disclose.

Open Access This article is distributed under the terms of the Creative Commons Attribution Noncommercial License which permits any noncommercial use, distribution, and reproduction in any medium, provided the original author(s) and source are credited.

References

- Harada Y, Hirasawa D, Fujit N, Noda Y, Kobayashi G, Ishida K, Yonechi M, Ito K, Suziki T, Sugawara T, Horaguchi J, Takasawa O, Obana T, Oohira T, Onochi K, Kanno Y, Kuroha M, Iwai W (2009) Impact of a transparent hood on the performance of total colonoscopy: a randomized controlled trial. *Gastrointest Endosc* 69:637–644
- Kondo S, Yamaji Y, Watabe H, Yamada A, Sugimoto T, Ohta M, Ogura K, Okamoto M, Yoshida H, Kawabe T, Omata M (2007) A randomized controlled trial evaluating the usefulness of a transparent hood attached to the tip of the colonoscope. *Am J Gastroenterol Hepatol* 102:75–81
- Shida T, Kutsuura Y, Teramoto O, Kaiho M, Takano S, Yoshidome H, Miyazaki M (2008) Transparent hood attached to the colonoscope: does it really work for all types of colonoscopes? *Surg Endosc* 22:2654–2658
- David GH, Douglas KR (2010) Cap-fitted colonoscopy: a randomized, tandem colonoscopy study of adenoma miss rates. *Gastrointest Endosc* 72(4):775–781
- Dai J, Feng N, Lu H, Li XB, Yang CH, Ge ZZ (2010) Transparent cap improves patients' tolerance of colonoscopy and shortens examination time by inexperienced endoscopists. *J Dig Dis* 11: 364–368