

## RESEARCH ARTICLE

# The diagnostic performance of PET/CT scans for the detection of para-aortic metastatic lymph nodes in patients with cervical cancer: A meta-analysis

Weiying Yu<sup>1</sup>, Changgui Kou<sup>1</sup>, Wei Bai<sup>1</sup>, Xiao Yu<sup>1</sup>, Ruixin Duan<sup>1</sup>, Bo Zhu<sup>1</sup>, Yuanyuan Li<sup>1</sup>, Wanqing Hua<sup>1</sup>, Xiaojun Ren<sup>2</sup>, Yanming Yang<sup>1,2\*</sup>

**1** Department of Epidemiology and Biostatistics, School of Public Health, Jilin University, Changchun, Jilin, China, **2** Department of Radiotherapy, Second Hospital of Jilin University, Changchun, Jilin, China

\* [yym180@163.com](mailto:yym180@163.com)



## Abstract

### Objective

We performed a meta-analysis to evaluate the diagnostic value of positron emission tomography/computed tomography (PET/CT) in the detection of para-aortic lymph node metastasis in cervical cancer.

### Methods

We searched the PubMed, Embase, Web of Science, Cochrane Library, Chinese Biological Medicine (CBM), Chinese National Knowledge Infrastructure (CNKI), Wanfang and VIP databases in all languages from their inception to September 2018. Stat15.0 software was used to obtain pooled estimates of sensitivity (SEN), specificity (SPE), positive likelihood ratio (PLR), and negative likelihood ratio (NLR) as well as a summary receiver operating characteristic (SROC) curves. Deek's funnel plot was used to assess publication bias. QUADAS-2 was used to evaluate the quality of the studies. The protocol for this meta-analysis is registered in PROSPERO (CRD42019115330).

### Results

We obtained 14 studies, and the pooled estimates for sensitivity and specificity of PET/CT were 0.71 (95% confidence interval (CI) = 0.54–0.83) and 0.97 (95% CI = 0.93–0.98), respectively. Pooled PLR and NLR were 21.53 and 0.30, respectively. The diagnostic odds ratio (DOR) was 70.59, and the area under the curve (AUC) was 0.95.

### Conclusion

PET/CT is an effective and important imaging method for the diagnosis of para-aortic lymph node metastasis in early cervical cancer.

## OPEN ACCESS

**Citation:** Yu W, Kou C, Bai W, Yu X, Duan R, Zhu B, et al. (2019) The diagnostic performance of PET/CT scans for the detection of para-aortic metastatic lymph nodes in patients with cervical cancer: A meta-analysis. *PLoS ONE* 14(7): e0220080. <https://doi.org/10.1371/journal.pone.0220080>

**Editor:** Anthony F. Shields, Karmanos Cancer Institute, UNITED STATES

**Received:** March 27, 2019

**Accepted:** July 7, 2019

**Published:** July 18, 2019

**Copyright:** © 2019 Yu et al. This is an open access article distributed under the terms of the [Creative Commons Attribution License](https://creativecommons.org/licenses/by/4.0/), which permits unrestricted use, distribution, and reproduction in any medium, provided the original author and source are credited.

**Data Availability Statement:** All relevant data are within the manuscript and its Supporting Information files.

**Funding:** The authors received no specific funding for this work.

**Competing interests:** The authors have declared that no competing interests exist.

## Introduction

Cervical cancer is a major gynecological cancer; it is the fourth most common cancer in women, and the seventh most common cancer overall [1]. At the global level, between 1990 and 2013, the incidence rate of cervical cancer increased to 9% with an estimated 485,000 new cases and 236,000 deaths worldwide in 2013 [2]. In 2015, 526,000 women were diagnosed with cervical cancer worldwide, resulting in 239,000 deaths [3]. Cervical cancer accounts for 7 million Disability-Adjusted Life-Years (DALYs), with 96% coming from years of life lost (YLLs) and 4% from years lived with disability (YLDs).

Although early detection of cervical cancer results in a higher cure rate, this disease is also prone to recurrence [4–6]. Recurrent cervical cancer has a poor prognosis because once the primary treatment fails, the likelihood of a cure for recurrent disease is low [4, 7, 8]. Earlier intervention leads to a better prognosis. The presence of metastasis in pelvic and para-aortic lymph nodes is one of the most important prognostic and high-risk factors for recurrence in cervical cancer [9–13]. In 2018, clinical staging was revised by the International Federation of Gynecology and Obstetrics (FIGO) Committee, and the major change to the current staging system was the incorporation of nodal status into stage III disease staging. This new staging system clearly reflects the importance of lymph node metastasis as a major prognostic factor in cervical cancer [14, 15]. One study suggested that survival rates were significantly lower in patients with nodal metastases than in patients without metastases to lymph nodes, especially para-aortic lymph nodes [16–18], which was reflected by unfavorable overall 3-year survival rates. The three-year survival rate was 94% for patients with negative nodes compared to 64% for patients with positive pelvic nodes and 35% for patients with positive para-aortic nodes [16]. Therefore, detection of the para-aortic lymph node status is essential to ensure appropriate treatment planning and prediction of prognosis for cervical cancer patients.

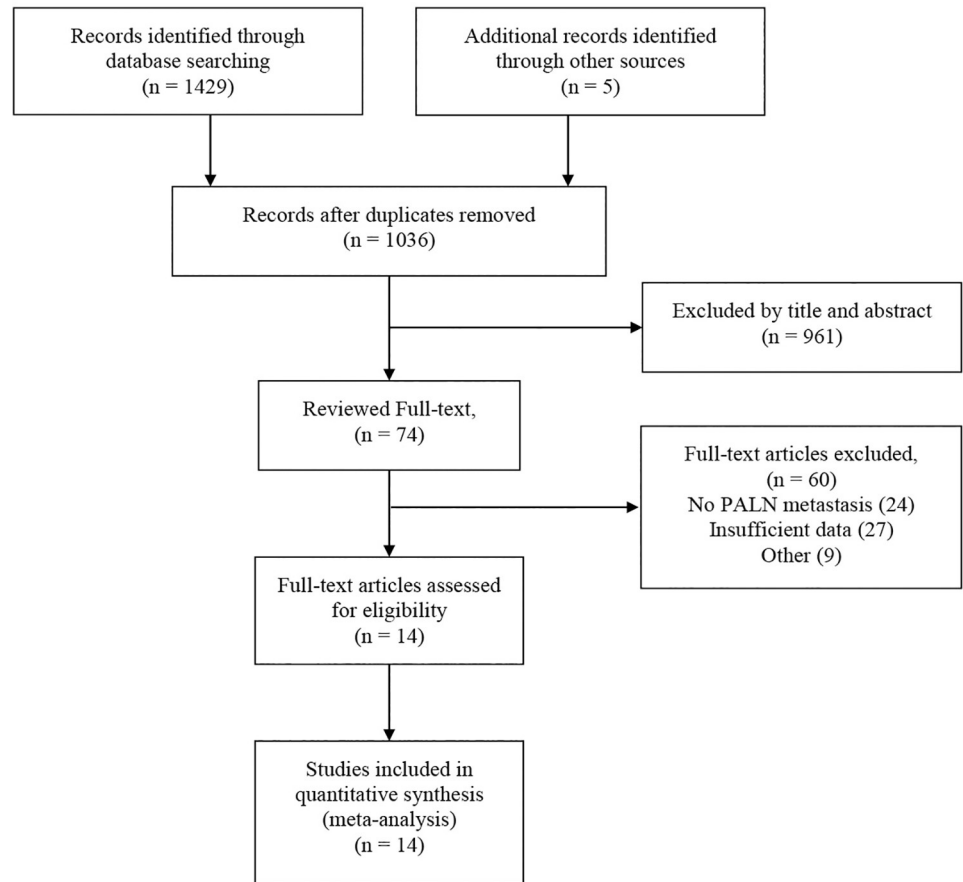
Another major change in the current staging system is to use imaging and pathological findings, where available, to assign the stage [15]. This also illustrates the necessity of using imaging methods to examine the status of lymph nodes. Currently, positron emission tomography/computed tomography (PET/CT) is widely used in the clinical evaluation of cancers [19–21]. Some studies indicate that PET/CT with 2-[<sup>18</sup>F] fluoro-2-deoxy-d-glucose (<sup>18</sup>F-FDG) exploits the increased utilization of glucose by malignant cells and thereby high uptake of glucose, showing relatively higher diagnostic value.

Previous meta-analyses have investigated the performance of PET/CT in detecting lymph node metastases in cervical cancer patients, but no study has evaluated para-aortic lymph node metastasis. Therefore, we systematically reviewed all available studies in the literature to objectively evaluate the diagnostic value of PET/CT in the detection of para-aortic lymph node metastasis in cervical cancer.

## Materials and methods

### Data sources and keywords

We searched PubMed, Embase, Web of Science, Cochrane Library, Chinese Biological Medicine (CBM), Chinese National Knowledge Infrastructure (CNKI), Wanfang and VIP databases in all languages from their inception to September 2018. We used a combination of medical subject headings (MeSH) terms and keyword searches. We used the latter to identify relevant papers where the MeSH terms had not been assigned. For the MeSH search, we specified the terms “Uterine Cervical Neoplasms [MeSH]” AND “Positron Emission Tomography Computed Tomography [MeSH]” AND “Lymphatic Metastasis [MeSH]”. These terms were expanded in the search builder to “Uterine Cervical Neoplasms” OR “Cervical Neoplasm,



**Fig 1. Flow diagram for the selection of studies in this meta-analysis.** Abbreviations: PALN, para-aortic lymph nodes.

<https://doi.org/10.1371/journal.pone.0220080.g001>

Uterine” OR “Cervical Neoplasms, Uterine” OR “Neoplasm, Uterine Cervical” OR “Neoplasms, Uterine Cervical” OR “Uterine Cervical Neoplasm” OR “Neoplasms, Cervical” OR “Cervical Neoplasms” OR “Cervical Neoplasm” OR “Neoplasm, Cervical” OR “Neoplasms, Cervix” OR “Cervix Neoplasms” OR “Cervix Neoplasm” OR “Neoplasm, Cervix” OR “Cancer of the Uterine Cervix” OR “Cancer of the Cervix” OR “Cervical Cancer” OR “Uterine Cervical Cancer” OR “Cancer, Uterine Cervical” OR “Cancers, Uterine Cervical” OR “Cervical Cancer, Uterine” OR “Cervical Cancers, Uterine” OR “Uterine Cervical Cancers” OR “Cancer of Cervix” OR “Cervix Cancer” OR “Cancer, Cervix” OR “Cancers, Cervix” AND “Positron Emission Tomography Computed Tomography” OR “PET-CT Scan” OR “PET-CT Scans” OR “Scan, PET-CT” OR “Scans, PET-CT” OR “PET CT Scan” OR “CT Scan, PET” OR “CT Scans, PET” OR “PET CT Scans” OR “Scan, PET CT” OR “Scans, PET CT” OR “CT PET” OR “CT PETs” OR “PET, CT” OR “PETs, CT” OR “Positron Emission Tomography-Computed Tomography” OR “PET-CT” OR “CT PET Scan” OR “CT PET Scans” OR “PET Scan, CT” OR “PET Scans, CT” OR “Scan, CT PET” OR “Scans, CT PET” AND “lymph node metastases” OR “Lymphatic Metastasis” OR “Lymphatic Metastases” OR “Metastases, Lymphatic” OR “Metastasis, Lymphatic”. Meanwhile, references from the retrieved papers were checked for additional relevant studies. Potentially relevant articles were identified based on the title and abstract and predefined inclusion and exclusion criteria. The flow diagram of the retrieval process is shown in Fig 1. The protocol for this meta-analysis is registered in PROSPERO (CRD42019115330).

## Inclusion and exclusion criteria

Studies were eligible according to the following criteria: (1) A sample size was at least 10 patients. (2) PET/CT or PET was used to detect para-aortic lymph node metastasis in patients with cervical cancer. (3) Histopathologic findings were the “gold standard”. (4) The provided data included true positives (TP), false positives (FP), false negatives (FN) and true negatives (TN).

Studies were excluded according to the following criteria: (1) Reviews, letters, case reports, nonclinical studies; (2) Insufficient data (2×2 tables could not be constructed); (3) Para-aortic lymph node metastasis was not confirmed by pathology; and (4) Studies with duplicate data.

## Data extraction

Two authors independently extracted the data from each relevant article. Any disagreement between the authors over the eligibility of particular studies was resolved through discussion with a third reviewer. For each included study, we recorded the name of the first author, year of publication, number of eligible patients, comparison methods (patient-based and region-based), true positive (TP), false positive (FP), false negative (FN), true negative (TN) and information for the assessment of the risk of bias. Missing data were requested from the study authors.

## Statistical analyses

Stata 15.0 was utilized to analyze the data. A bivariate random effects model was performed to adjust for the within and between-study variance in sensitivity and specificity. We extracted the data from diagnostic 2×2 tables in the study to calculate pooled estimates of sensitivity (SEN), specificity (SPE), positive-likelihood ratios (PLR), negative-likelihood ratios (NLR), and the diagnostic odds ratio (DOR) with 95% confidence interval (CI). We plotted a summary receiver operating characteristic (SROC) curves, obtained the area under the curve (AUC), and constructed a forestplot. The diagnostic value was better when the AUC was closer to 1. We assessed the threshold effect using Spearman’s correlation coefficients and evaluated heterogeneity based on the *I*-square ( $I^2$ ) values. The possibility of publication bias was assessed by a Deek’s funnel plot [22], a symmetric shape of the funnel plot indicates that there is no publication bias, because visual inspection is subjective, and it is necessary to quantify the evidence for asymmetry.  $P > 0.05$  was considered to be indicative of no publication bias.

## Quality assessment

Two reviewers independently assessed the risk of bias and the applicability of diagnostic accuracy in the studies using the QUADAS-2 method [23] which consists of four main domains: (1) patient selection, (2) index test, (3) reference test, and (4) flow and timing. Each domain was assessed in terms of the risk of bias (high, low or unclear), and the first 3 domains were also assessed in terms of concerns regarding applicability. Disagreements were resolved by discussion with a third review when necessary.

## Results

### Eligible studies and quality assessment

The initial search yielded 1429 studies (PubMed: 430; Embase: 329; Web of Science: 587; Cochrane Library: 7; Chinese Biological Medicine (CBM): 13; Chinese National Knowledge Infrastructure (CNKI): 39; Wanfang: 9; VIP: 15), and another 5 articles were found by manual searching. A total of 398 articles were excluded based on duplication, and 962 studies were

**Table 1. The general characteristics of the included studies.**

Studies	Sample	TP	FP	FN	TN	SEN (%)	SPE (%)	PPV (%)	NPV (%)
Rose1999[24]	32	6	2	2	22	75.00	91.67	75.00	91.67
Narayan2001[25]	24	4	1	3	16	57.14	94.12	80.00	84.21
Yeh2002[26]	42	10	1	2	29	83.33	96.67	90.91	93.55
Lin2003[27]	50	12	2	2	34	85.71	94.44	85.71	94.44
Ryu2003[28]	249	3	0	1	245	75.00	100.00	100.00	99.59
Wright2005[29]	45	1	1	3	40	25.00	97.56	50.00	93.02
Loft2007[30]	119	15	1	0	103	100.00	99.04	93.75	100.00
Kitajima2008[31]	52	10	0	2	40	83.33	100.00	100.00	95.24
Yildirim2008[32]	16	2	2	2	10	50.00	83.33	50.00	83.33
Monteil2011[33]	27	5	5	0	17	100.00	77.27	50.00	100.00
Leblanc2011[34]	125	7	6	14	98	33.33	94.23	53.85	87.50
Ramirez2011[35]	60	5	2	9	44	35.71	95.65	71.43	83.02
Chen2013[36]	45	2	1	3	39	40.00	97.50	66.67	92.86
Ge2015[37]	26	7	1	2	16	77.78	94.12	87.50	88.89

Abbreviations:TP,true positive; FP,false positive; FN,false negative; TN,true negative; SEN,sensitivity; SPE,specificity; PPV,positive predictive value; NPV,negative predictive value

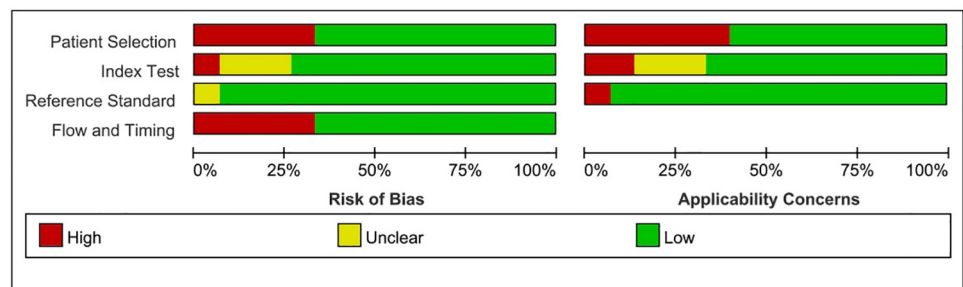
<https://doi.org/10.1371/journal.pone.0220080.t001>

excluded based on the title or abstract. After that, we reviewed the remaining 74 full-text articles. Finally, 14 studies remained and were eligible for this meta-analysis. The flow diagram of the retrieval process is shown in Fig 1, and the characteristics of the 14 studies are shown in Table 1. We assessed the quality of the 14 articles according to the QUADAS-2 assessment tool (Fig 2).

### Effect of PET/CT on diagnosis

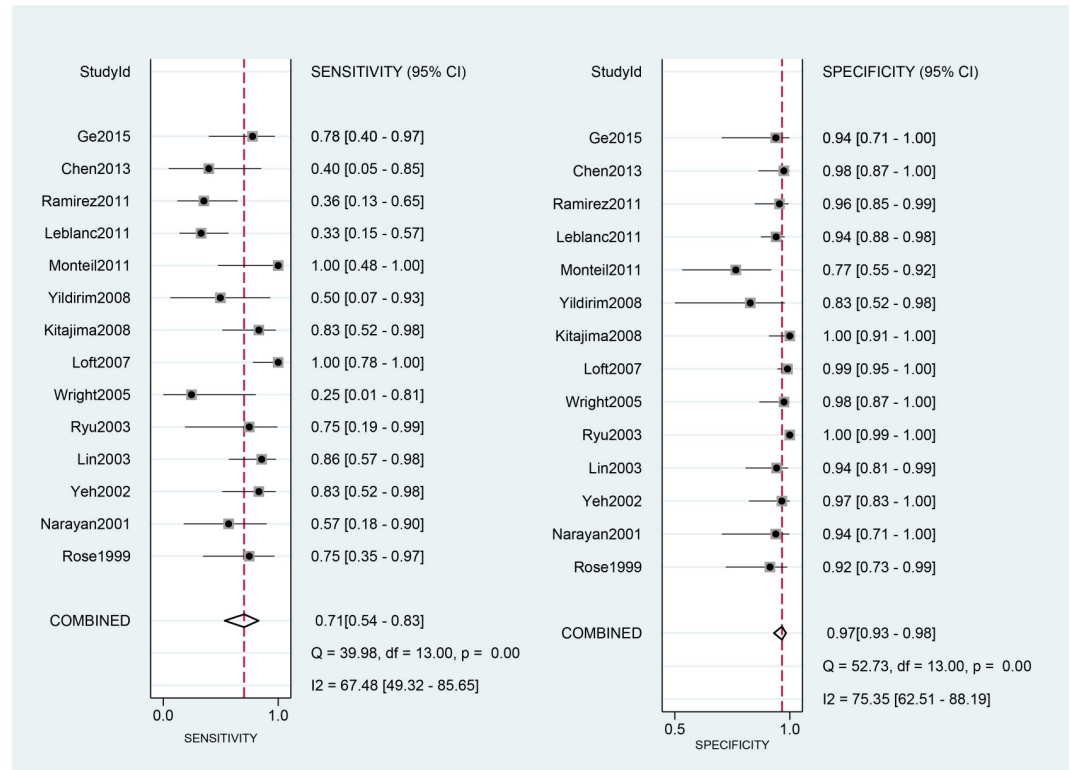
The 14 eligible studies were pooled for the meta-analysis of diagnostic test. As moderate heterogeneity among the 14 studies was observed ( $I^2 = 68$ , 95% CI: 28–100). Fig 3 shows the forest plots of sensitivity, ranging from 0.25 to 1.00 (pooled 0.71; 95% CI: 0.54–0.83), and specificity, ranging from 0.77 to 1.00 (pooled 0.97; 95% CI: 0.93–0.98). The pooled positive-likelihood ratio (PLR) was 21.53, and the pooled negative-likelihood ratio (NLR) was 0.30 (Fig 4).

Fig 5 shows the diagnostic odds ratio (DOR) ranging from 5.00 to 2139.00 (pooled 70.59; 95% CI: 23.61–211.07). The area under the curve (AUC) for PET/CT was 0.95 (0.93–0.97).



**Fig 2. Methodological quality of the studies included in this meta-analysis.**

<https://doi.org/10.1371/journal.pone.0220080.g002>



**Fig 3. Forest plots for sensitivity and specificity.** Abbreviations: CI, confidence interval; df, degrees of freedom.

<https://doi.org/10.1371/journal.pone.0220080.g003>

### Publication bias

Publication bias was evaluated by a Deek’s funnel plot (Fig 6), reflected by the symmetric shape of the funnel plot. The P value was 0.60, which indicated a low probability of publication bias.

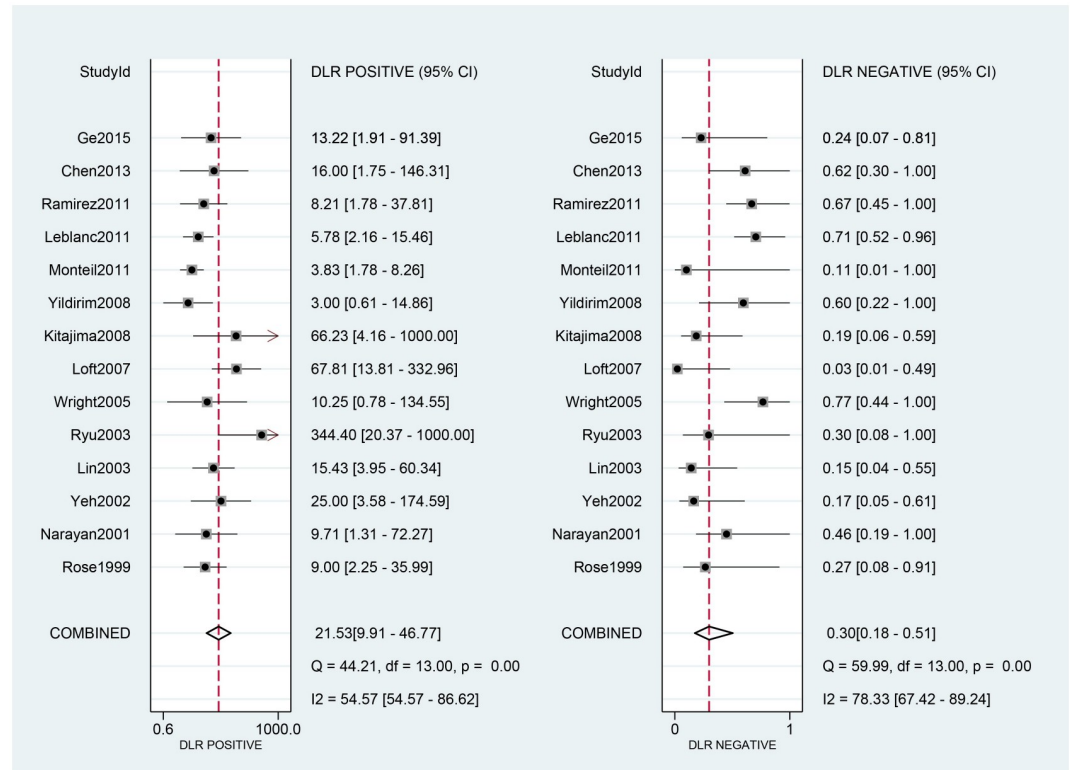
### Discussion

Cervical cancer is the most commonly diagnosed cancer for women in 11 countries, and the most common cause of cancer deaths for women in 50 countries [3]. Para-aortic lymph node metastases are associated with an unfavorable prognosis in cervical cancer patients. In the new FIGO clinical staging guidelines, lymph node status is included [15]. Para-aortic lymph node metastasis must be detected accurately to plan appropriate treatment for cervical cancer patients.

In this meta-analysis, a total of 14 original studies were included. Since each study has a limited number of cases, this meta-analysis was performed to integrate more data and provide more reliable results. Some meta-analyses have been published on lymph node metastasis in cervical cancer, but our meta-analysis is the first to evaluate the diagnostic performance of PET/CT for detecting para-aortic lymph node metastases in cervical cancer patients. We performed a meta-analysis and strictly followed the inclusion and exclusion criteria to guarantee the quality of all included studies. We also examined the methodological quality of the studies using the validated QUADAS-2 tool.

Histopathologic findings are the “gold standard” to determine the lymph node status; however, the benefits of lymphadenectomy are controversial. In this scenario, different imaging



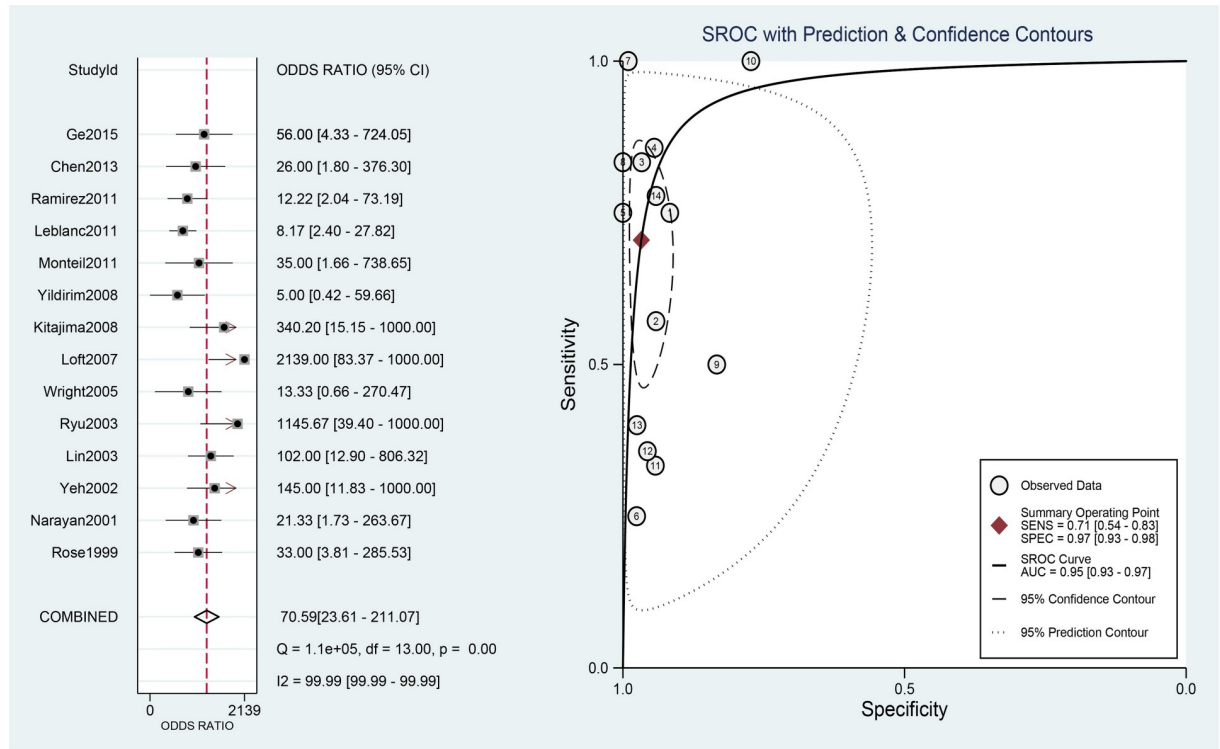


**Fig 4. Forest plots for positive and negative LRs.** Abbreviations: CI, confidence interval; df, degrees of freedom; LR, likelihood ratio.

<https://doi.org/10.1371/journal.pone.0220080.g004>

modalities have been used to study the presence of lymph node metastasis by a noninvasive approach. Various imaging methods such as computed tomography (CT) [38] and magnetic resonance imaging (MRI) [39, 40] have traditionally been used to detect the lymph node status in cervical cancer. Nevertheless, the use of CT and MRI techniques to detect metastasis to lymph nodes remains difficult and it reflected in the low sensitivity values of CT and MRI in the detection of nodal metastasis [38, 41]. Some studies have also evaluated the role of PET/CT in the clinical evaluation of cancers. PET/CT has been indicated to be superior to conventional imaging modalities in the detection of lymph node metastasis [42].

We investigated the diagnostic performance of PET/CT for the detection of para-aortic lymph node metastases in cervical cancer patients with surgical pathology as a reference standard. A previous meta-analysis showed that PET/CT had moderate sensitivity and good specificity in detecting lymph node metastasis of cancer [43–45]. In a study by Atri et al [46], PET/CT was demonstrated to have a good effect on the diagnosis of abdominal lymph node metastasis in patients with cervical cancer, and the ACRIN6671/GOG0233 trial was one of the reasons for moving toward the adoption of the new FIGO staging system, which clearly proposes the use of imaging and pathological findings, where available, to assign the stage [15]. The pooled estimates for sensitivity and specificity of PET/CT were 0.71 (95% CI = 0.54–0.83) and 0.97 (95% CI = 0.93–0.98), respectively. Thus, PET/CT has moderate sensitivity and high specificity, but the rate of missed diagnosis is 29% and the misdiagnosis rate is 3%. We found similar SPE and SEN to the meta-analysis of PET/CT for lymph node metastasis in cervical cancer patients performed by Ruan et al [47], but we found higher SEN and lower SPE than the values obtained in their subgroup analysis of para-aortic lymph node metastasis. The overall results



**Fig 5. Forest plots for the DOR and the SROC curve.** Abbreviations: CI, confidence interval; df, degrees of freedom; DOR, diagnostic odds ratio; AUC, area under the curve; SROC, summary receiver operating characteristic.

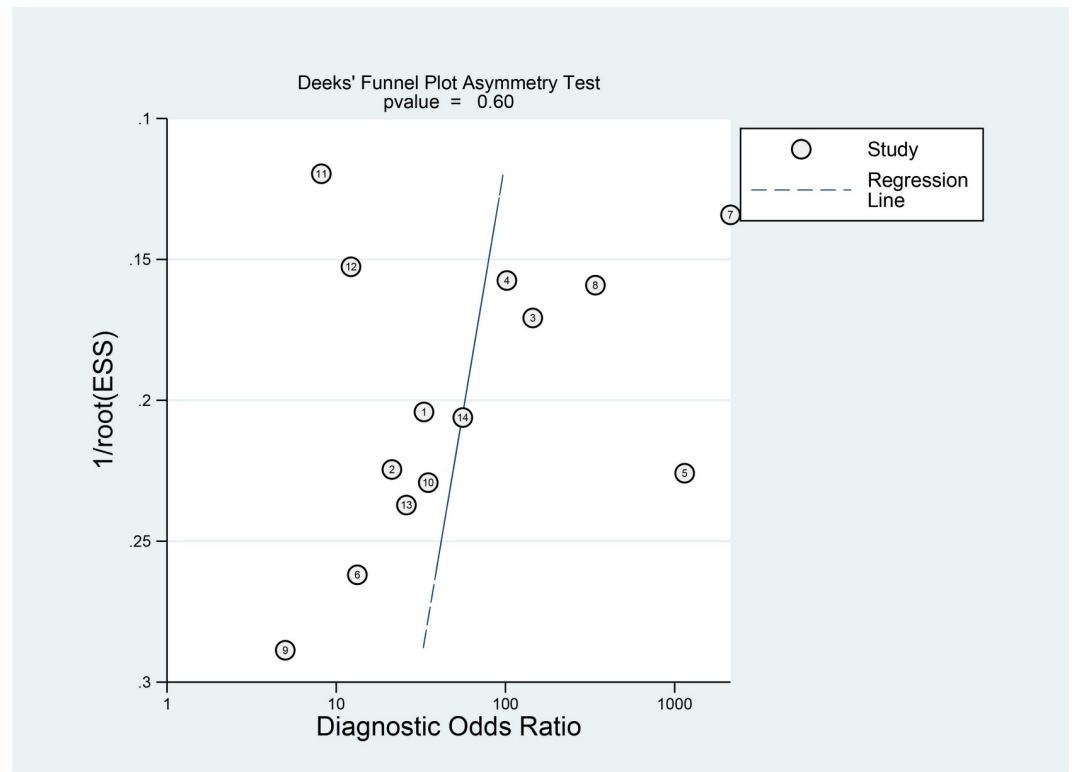
<https://doi.org/10.1371/journal.pone.0220080.g005>

in the study by Liu et al [48] are similar to those in the subgroup analysis, and have lower SEN that and similar SPE to our results. The difference in overall results may be due to the inclusion of pelvic lymph node metastasis in the other studies. Although they performed subgroup analyses, they included fewer studies of para-aortic lymph node metastasis, which may have accounted for the differences in results.

The DOR in this study 70.59. DOR has the advantage of accuracy as a single indicator and combines the strengths of SEN and SPE. The DOR ranges from 0 to infinity, with higher values indicating better discriminatory performance [49–51]; however, the DOR is difficult to apply directly to clinical practice [52]. Since likelihood ratios (LR) are considered more clinically meaningful, we also calculated both PLR and NLR and used them as measures of diagnostic accuracy. In this meta-analysis, the pooled PLR and NLR were 21.53 and 0.30, respectively. Positive and negative likelihood ratios describe the discriminatory properties of positive and negative test results, respectively. Positive likelihood ratios above 10 and negative likelihood ratios below 0.1 have been noted to provide convincing diagnostic evidence [51]. In this study, the positive likelihood ratio was greater than 10, and could be used for effective diagnosis, but the negative likelihood ratio was not lower than 0.1, and could not be used to directly exclude the disease. The area under the SROC curve was 0.95, and the value was close to 1. These data showed that PET/CT can be used as an effective diagnostic method to detect para-aortic lymph node metastasis in cervical cancer patients. The  $I^2$  value was 68 (CI = 20–100), indicating moderate heterogeneity. Nevertheless, because of incomplete data, we could not perform subgroup analyses, and we could not present the exact reasons for heterogeneity.

This meta-analysis had several limitations. First, not all studies in this meta-analysis reported the specific technology utilized. Some scanning parameters may have affected the





**Fig 6. Funnel plot of the diagnostic value of PET/CT.**

<https://doi.org/10.1371/journal.pone.0220080.g006>

accuracy of PET/CT. Second, most of the studies were retrospective and did not use a blinded method to obtain results, which may have influenced the quality of the studies. Third, although a low probability of publication bias, the number of articles included was small, and the lack of studies from recent years may have caused bias. Last, the number of patients included in the studies was relatively small, which might have caused bias in the final results.

In summary, despite these limitations, PET/CT showed good diagnostic performance for the detection of para-aortic lymph node metastasis in patients with cervical cancer. As an effective and important imaging method for the discovery of para-aortic lymph node metastasis to make an early diagnosis of cervical cancer, PET/CT can be used to ensure appropriate treatment planning and preoperative assessment.

## Conclusion

Our meta-analysis shows that PET/CT is an effective and important imaging method for the diagnosis of para-aortic lymph node metastasis in early cervical cancer. Therefore, the application of PET/CT in the clinic will be beneficial for the treatment and prognostic assessment of cervical cancer patients.

## Supporting information

**S1 File. PRISMA checklist.**  
(DOCX)

## Acknowledgments

We would like to thank all the authors of the studies included in our meta-analysis.

## Author Contributions

**Conceptualization:** Changgui Kou, Yanming Yang.

**Data curation:** Weiyong Yu, Wei Bai.

**Investigation:** Weiyong Yu, Wei Bai, Xiao Yu.

**Methodology:** Weiyong Yu, Ruixin Duan, Bo Zhu.

**Project administration:** Changgui Kou, Yanming Yang.

**Software:** Weiyong Yu, Xiao Yu, Yuanyuan Li, Wanqing Hua.

**Supervision:** Changgui Kou, Xiaojun Ren, Yanming Yang.

**Writing – original draft:** Weiyong Yu, Changgui Kou, Wei Bai.

**Writing – review & editing:** Xiao Yu, Ruixin Duan, Bo Zhu, Yuanyuan Li, Wanqing Hua, Xiaojun Ren, Yanming Yang.

## References

1. Ferlay J, Soerjomataram I, Dikshit R, Eser S, Mathers C, Rebelo M, et al. Cancer incidence and mortality worldwide: sources, methods and major patterns in GLOBOCAN 2012. *Int J Cancer*. 2015; 136(5): E359–86. Epub 2014/09/16. <https://doi.org/10.1002/ijc.29210> PMID: 25220842.
2. Fitzmaurice C, Dicker D, Pain A, Hamavid H, Moradi-Lakeh M, MacIntyre MF, et al. The Global Burden of Cancer 2013. *JAMA Oncol*. 2015; 1(4):505–27. Epub 2015/07/17. <https://doi.org/10.1001/jamaoncol.2015.0735> PMID: 26181261.
3. Fitzmaurice C, Allen C, Barber RM, Barregard L, Bhutta ZA, Brenner H, et al. Global, Regional, and National Cancer Incidence, Mortality, Years of Life Lost, Years Lived With Disability, and Disability-Adjusted Life-years for 32 Cancer Groups, 1990 to 2015: A Systematic Analysis for the Global Burden of Disease Study. *JAMA Oncol*. 2017; 3(4):524–48. Epub 2016/12/06. <https://doi.org/10.1001/jamaoncol.2016.5688> PMID: 27918777.
4. Waggoner SE. Cervical cancer. *Lancet*. 2003; 361(9376):2217–25. Epub 2003/07/05. [https://doi.org/10.1016/S0140-6736\(03\)13778-6](https://doi.org/10.1016/S0140-6736(03)13778-6) PMID: 12842378.
5. Wang H, Zhu L, Lu W, Xu H, Yu Y, Yang Y. Clinicopathological risk factors for recurrence after neoadjuvant chemotherapy and radical hysterectomy in cervical cancer. *World J Surg Oncol*. 2013; 11:301. Epub 2013/11/26. <https://doi.org/10.1186/1477-7819-11-301> PMID: 24266990.
6. Ahn HK, Shin JW, Ahn HY, Park CY, Lee NW, Lee JK, et al. Metabolic components and recurrence in early-stage cervical cancer. *Tumour Biol*. 2015; 36(3):2201–7. Epub 2014/11/16. <https://doi.org/10.1007/s13277-014-2831-y> PMID: 25398694.
7. Bodurka-Bevers D, Morris M, Eifel PJ, Levenback C, Bevers MW, Lucas KR, et al. Posttherapy surveillance of women with cervical cancer: an outcomes analysis. *Gynecol Oncol*. 2000; 78(2):187–93. Epub 2000/08/06. <https://doi.org/10.1006/gyno.2000.5860> PMID: 10926801.
8. Sun L, Jiang R, Li J, Wang B, Ma C, Lv Y, et al. MicoRNA-425-5p is a potential prognostic biomarker for cervical cancer. *Ann Clin Biochem*. 2017; 54(1):127–33. Epub 2016/05/12. <https://doi.org/10.1177/0004563216649377> PMID: 27166306.
9. Takeshima N, Yanoh K, Tabata T, Nagai K, Hirai Y, Hasumi K. Assessment of the revised International Federation of Gynecology and obstetrics staging for early invasive squamous cervical cancer. *Gynecol Oncol*. 1999; 74(2):165–9. Epub 1999/07/27. <https://doi.org/10.1006/gyno.1999.5473> PMID: 10419727.
10. Grigsby PW, Perez CA, Chao KS, Herzog T, Mutch DG, Rader J. Radiation therapy for carcinoma of the cervix with biopsy-proven positive para-aortic lymph nodes. *Int J Radiat Oncol Biol Phys*. 2001; 49(3):733–8. Epub 2001/02/15. [https://doi.org/10.1016/s0360-3016\(00\)00806-3](https://doi.org/10.1016/s0360-3016(00)00806-3) PMID: 11172956.
11. Leblanc E, Narducci F, Frumovitz M, Lesoin A, Castelain B, Baranzelli MC, et al. Therapeutic value of pretherapeutic extraperitoneal laparoscopic staging of locally advanced cervical carcinoma. *Gynecol*

- Oncol. 2007; 105(2):304–11. Epub 2007/01/30. <https://doi.org/10.1016/j.ygyno.2006.12.012> PMID: 17258799.
12. Hou T, Liang D, Xu L, Huang X, Huang Y, Zhang Y. Atypical chemokine receptors predict lymph node metastasis and prognosis in patients with cervical squamous cell cancer. *Gynecol Oncol.* 2013; 130(1):181–7. Epub 2013/04/23. <https://doi.org/10.1016/j.ygyno.2013.04.015> PMID: 23603371.
  13. Asano H, Todo Y, Watari H. Adjuvant chemotherapy for early-stage cervical cancer. *Chin J Cancer Res.* 2016; 28(2):228–34. Epub 2016/05/21. <https://doi.org/10.21147/j.issn.1000-9604.2016.02.12> PMID: 27199521.
  14. Matsuo K, Machida H, Mandelbaum RS, Konishi I, Mikami M. Validation of the 2018 FIGO cervical cancer staging system. *Gynecol Oncol.* 2019; 152(1):87–93. Epub 2018/11/06. <https://doi.org/10.1016/j.ygyno.2018.10.026> PMID: 30389105.
  15. Bhatla N, Aoki D, Sharma DN, Sankaranarayanan R. Cancer of the cervix uteri. *Int J Gynaecol Obstet.* 2018; 143 Suppl 2:22–36. Epub 2018/10/12. <https://doi.org/10.1002/ijgo.12611> PMID: 30306584.
  16. Morice P, Castaigne D, Pautier P, Rey A, Haie-Meder C, Leblanc M, et al. Interest of pelvic and para-aortic lymphadenectomy in patients with stage IB and II cervical carcinoma. *Gynecol Oncol.* 1999; 73(1):106–10. Epub 1999/03/30. <https://doi.org/10.1006/gyno.1998.5308> PMID: 10094889.
  17. Peters WA 3rd, Liu PY, Barrett RJ 2nd, Stock RJ, Monk BJ, Berek JS, et al. Concurrent chemotherapy and pelvic radiation therapy compared with pelvic radiation therapy alone as adjuvant therapy after radical surgery in high-risk early-stage cancer of the cervix. *J Clin Oncol.* 2000; 18(8):1606–13. Epub 2000/04/14. <https://doi.org/10.1200/JCO.2000.18.8.1606> PMID: 10764420.
  18. Son SH, Jeong SY, Chong GO, Lee YH, Park SH, Lee CH, et al. Prognostic Value of Pretreatment Metabolic PET Parameters in Cervical Cancer Patients With Metabolic Complete Response After Concurrent Chemoradiotherapy. *Clin Nucl Med.* 2018; 43(9):e296–e303. Epub 2018/07/24. <https://doi.org/10.1097/RLU.0000000000002188> PMID: 30036243.
  19. Caresia Aroztegui AP, Garcia Vicente AM, Alvarez Ruiz S, Delgado Bolton RC, Orcajo Rincon J, Garcia Garzon JR, et al. 18F-FDG PET/CT in breast cancer: Evidence-based recommendations in initial staging. *Tumour Biol.* 2017; 39(10):1010428317728285. Epub 2017/10/14. <https://doi.org/10.1177/1010428317728285> PMID: 29025377.
  20. Orsaria P, Chiaravalloti A, Caredda E, Marchese PV, Titka B, Anemona L, et al. Evaluation of the Usefulness of FDG-PET/CT for Nodal Staging of Breast Cancer. *Anticancer Res.* 2018; 38(12):6639–52. Epub 2018/12/07. <https://doi.org/10.21873/anticancerres.13031> PMID: 30504372.
  21. Taralli S, Scolozzi V, Foti M, Ricciardi S, Forcione AR, Cardillo G, et al. (18)F-FDG PET/CT diagnostic performance in solitary and multiple pulmonary nodules detected in patients with previous cancer history: reports of 182 nodules. *Eur J Nucl Med Mol Imaging.* 2018. Epub 2018/12/12. <https://doi.org/10.1007/s00259-018-4226-6> PMID: 30535767.
  22. Deeks JJ, Macaskill P, Irwig L. The performance of tests of publication bias and other sample size effects in systematic reviews of diagnostic test accuracy was assessed. *J Clin Epidemiol.* 2005; 58(9):882–93. Epub 2005/08/09. <https://doi.org/10.1016/j.jclinepi.2005.01.016> PMID: 16085191.
  23. Whiting PF, Rutjes AW, Westwood ME, Mallett S, Deeks JJ, Reitsma JB, et al. QUADAS-2: a revised tool for the quality assessment of diagnostic accuracy studies. *Ann Intern Med.* 2011; 155(8):529–36. Epub 2011/10/19. <https://doi.org/10.7326/0003-4819-155-8-201110180-00009> PMID: 22007046.
  24. Rose PG, Adler LP, Rodriguez M, Faulhaber PF, Abdul-Karim FW, Miraldi F. Positron emission tomography for evaluating para-aortic nodal metastasis in locally advanced cervical cancer before surgical staging: a surgicopathologic study. *J Clin Oncol.* 1999; 17(1):41–5. Epub 1999/08/24. <https://doi.org/10.1200/JCO.1999.17.1.41> PMID: 10458216.
  25. Narayan K, Hicks RJ, Jobling T, Bernshaw D, McKenzie AF. A comparison of MRI and PET scanning in surgically staged loco-regionally advanced cervical cancer: Potential impact on treatment. *Int J Gynecol Cancer.* 2001; 11(4):263–71 PMID: 11520363
  26. Yeh LS, Hung YC, Shen YY, Kao CH, Lin CC, Lee CC. Detecting para-aortic lymph nodal metastasis by positron emission tomography of 18F-fluorodeoxyglucose in advanced cervical cancer with negative magnetic resonance imaging findings. *Oncol Rep.* 2002; 9(6):1289–92. Epub 2002/10/11. PMID: 12375036.
  27. Lin WC, Hung YC, Yeh LS, Kao CH, Yen RF, Shen YY. Usefulness of F-18-fluorodeoxyglucose positron emission tomography to detect para-aortic lymph nodal metastasis in advanced cervical cancer with negative computed tomography findings. *Gynecol Oncol.* 2003; 89(1):73–6. [https://doi.org/10.1016/s0090-8258\(03\)00058-1](https://doi.org/10.1016/s0090-8258(03)00058-1) PMID: 12694656
  28. Ryu SY, Kim MH, Choi SC, Choi CW, Lee KH. Detection of early recurrence with F-18-FDG PET in patients with cervical cancer. *J Nucl Med.* 2003; 44(3):347–52. PMID: 12620999
  29. Wright JD, Dehdashti F, Herzog TJ, Mutch DG, Huettner PC, Rader JS, et al. Preoperative lymph node staging of early-stage cervical carcinoma by F-18 -fluoro-2-deoxy-D-glucose-positron emission tomography. *Cancer.* 2005; 104(11):2484–91. <https://doi.org/10.1002/cncr.21527> PMID: 16270319

30. Loft A, Berthelsen AK, Roed H, Ottosen C, Lundvall L, Knudsen J, et al. The diagnostic value of PET/CT scanning in patients with cervical cancer: A prospective study. *Gynecol Oncol.* 2007; 106(1):29–34. <https://doi.org/10.1016/j.ygyno.2007.03.027> PMID: 17482666
31. Kitajima K, Murakami K, Yamasaki E, Domeki Y, Kaji Y, Sugimura K. Performance of FDG-PET/CT for diagnosis of recurrent uterine cervical cancer. *Eur Radiol.* 2008; 18(10):2040–7. <https://doi.org/10.1007/s00330-008-0979-9> PMID: 18425518
32. Yildirim Y, Sehirali S, Avci ME, Yilmaz C, Ertopcu K, Tinar S, et al. Integrated PET/CT for the evaluation of para-aortic nodal metastasis in locally advanced cervical cancer patients with negative conventional CT findings. *Gynecol Oncol.* 2008; 108(1):154–9. <https://doi.org/10.1016/j.ygyno.2007.09.011> PMID: 17945337
33. Monteil J, Maubon A, Leobon S, Roux S, Marin B, Renaudie J, et al. Lymph node assessment with (18)F-FDG-PET and MRI in uterine cervical cancer. *Anticancer Res.* 2011; 31(11):3865–71. Epub 2011/11/24. PMID: 22110211.
34. Leblanc E, Gauthier H, Querleu D, Ferron G, Zerdoud S, Morice P, et al. Accuracy of 18-Fluoro-2-deoxy-d-glucose positron emission tomography in the pretherapeutic detection of occult para-aortic node involvement in patients with a locally advanced cervical carcinoma. *Ann Surg Oncol.* 2011; 18(8):2302–9. <https://doi.org/10.1245/s10434-011-1583-9> PMID: 21347790
35. Ramirez PT, Jhingran A, Macapinlac HA, Euscher ED, Munsell MF, Coleman RL, et al. Laparoscopic extraperitoneal para-aortic lymphadenectomy in locally advanced cervical cancer: a prospective correlation of surgical findings with positron emission tomography/computed tomography findings. *Cancer.* 2011; 117(9):1928–34. Epub 2011/04/22. <https://doi.org/10.1002/cncr.25739> PMID: 21509770.
36. Chen YH, Wang DB, Li YN, Jiao L, Sun XD. Diagnostic Value of PET-CT in Detection of Lymph Node Metastasis in Early-stage Cervical Carcinoma. *Journal of China Medical University.* 2013; 42(4):351–4.
37. Ge HY, Zhou JD, Wu JC. Evaluation of 18F-FDG PET/CT for the paraaortic nodal spread in patients with cervical carcinoma. *Journal of Nantong University.* 2015;(3):202–4.
38. Bellomi M, Bonomo G, Landoni F, Villa G, Leon ME, Boccione L, et al. Accuracy of computed tomography and magnetic resonance imaging in the detection of lymph node involvement in cervix carcinoma. *Eur Radiol.* 2005; 15(12):2469–74. Epub 2005/07/07. <https://doi.org/10.1007/s00330-005-2847-1> PMID: 15999213.
39. Choi HJ, Roh JW, Seo SS, Lee S, Kim JY, Kim SK, et al. Comparison of the accuracy of magnetic resonance imaging and positron emission tomography/computed tomography in the presurgical detection of lymph node metastases in patients with uterine cervical carcinoma: a prospective study. *Cancer.* 2006; 106(4):914–22. Epub 2006/01/18. <https://doi.org/10.1002/cncr.21641> PMID: 16411226.
40. Sahdev A, Sohaib SA, Wenaden AE, Shepherd JH, Reznick RH. The performance of magnetic resonance imaging in early cervical carcinoma: a long-term experience. *Int J Gynecol Cancer.* 2007; 17(3):629–36. Epub 2007/02/21. PMID: 17309561.
41. Hertel H, Kohler C, Elhawary T, Michels W, Possover M, Schneider A. Laparoscopic staging compared with imaging techniques in the staging of advanced cervical cancer. *Gynecol Oncol.* 2002; 87(1):46–51. Epub 2002/12/07. PMID: 12468341.
42. Mayoral M, Paredes P, Domenech B, Fuste P, Vidal-Sicart S, Tapias A, et al. F-18-FDG PET/CT and sentinel lymph node biopsy in the staging of patients with cervical and endometrial cancer. Role of dual-time-point imaging. *Revista Espanola De Medicina Nuclear E Imagen Molecular.* 2017; 36(1):20–6. <https://doi.org/10.1016/j.rem.2016.07.003> PMID: 27667001
43. Chang MC, Chen JH, Liang JA, Yang KT, Cheng KY, Kao CH. 18F-FDG PET or PET/CT for detection of metastatic lymph nodes in patients with endometrial cancer: a systematic review and meta-analysis. *Eur J Radiol.* 2012; 81(11):3511–7. Epub 2012/02/07. <https://doi.org/10.1016/j.ejrad.2012.01.024> PMID: 22305013.
44. Yuan Y, Gu ZX, Tao XF, Liu SY. Computer tomography, magnetic resonance imaging, and positron emission tomography or positron emission tomography/computer tomography for detection of metastatic lymph nodes in patients with ovarian cancer: a meta-analysis. *Eur J Radiol.* 2012; 81(5):1002–6. Epub 2011/02/26. <https://doi.org/10.1016/j.ejrad.2011.01.112> PMID: 21349672.
45. Bollineni VR, Ytre-Hauge S, Bollineni-Balabay O, Salvesen HB, Haldorsen IS. High Diagnostic Value of 18F-FDG PET/CT in Endometrial Cancer: Systematic Review and Meta-Analysis of the Literature. *J Nucl Med.* 2016; 57(6):879–85. Epub 2016/01/30. <https://doi.org/10.2967/jnumed.115.170597> PMID: 26823564.
46. Atri M, Zhang Z, Dehdashti F, Lee SI, Ali S, Marques H, et al. Utility of PET-CT to evaluate retroperitoneal lymph node metastasis in advanced cervical cancer: Results of ACRIN6671/GOG0233 trial. *Gynecol Oncol.* 2016; 142(3):413–9. Epub 2016/05/15. <https://doi.org/10.1016/j.ygyno.2016.05.002> PMID: 27178725.

47. Ruan J, Zhang Y, Ren H. Meta-analysis of PET/CT Detect Lymph Nodes Metastases of Cervical Cancer. *Open Med (Wars)*. 2018; 13:436–42. Epub 2018/09/29. <https://doi.org/10.1515/med-2018-0065> PMID: 30263970.
48. Liu B, Gao S, Li S. A Comprehensive Comparison of CT, MRI, Positron Emission Tomography or Positron Emission Tomography/CT, and Diffusion Weighted Imaging-MRI for Detecting the Lymph Nodes Metastases in Patients with Cervical Cancer: A Meta-Analysis Based on 67 Studies. *Gynecol Obstet Invest*. 2017; 82(3):209–22. Epub 2017/02/10. <https://doi.org/10.1159/000456006> PMID: 28183074.
49. Glas AS, Lijmer JG, Prins MH, Bossel GJ, Bossuyt PM. The diagnostic odds ratio: a single indicator of test performance. *J Clin Epidemiol*. 2003; 56(11):1129–35. Epub 2003/11/15. PMID: 14615004.
50. Cleophas TJ, Zwinderman AH. Meta-analyses of diagnostic studies. *Clin Chem Lab Med*. 2009; 47(11):1351–4. Epub 2009/10/13. <https://doi.org/10.1515/CCLM.2009.317> PMID: 19817647.
51. Bohning D, Holling H, Patilea V. A limitation of the diagnostic-odds ratio in determining an optimal cut-off value for a continuous diagnostic test. *Stat Methods Med Res*. 2011; 20(5):541–50. Epub 2010/07/20. <https://doi.org/10.1177/0962280210374532> PMID: 20639268.
52. Deeks JJ. Systematic reviews in health care: Systematic reviews of evaluations of diagnostic and screening tests. *BMJ*. 2001; 323(7305):157–62. Epub 2001/07/21. <https://doi.org/10.1136/bmj.323.7305.157> PMID: 11463691.