

Repetition of Examination Due to Motion Artifacts in Horizontal Cone Beam CT: Comparison among Three Different Kinds of Head Support

Cosimo Nardi, Gian Giacomo Taliani, Alessandro Castellani, Luisa De Falco, Valeria Selvi, Linda Calistri

Department of Experimental and Clinical Biomedical Sciences, Radiodiagnostic Unit n. 2, University of Florence - Azienda Ospedaliero-Universitaria Careggi, Florence, Italy

ABSTRACT

Aims and Objectives: The aim of this study was to evaluate the repetition rate of examination due to motion artifacts in horizontal cone beam computed tomography, using three different kinds of head support, with reference to the patient's age. Further purpose was to evaluate how comfortable head supports were.

Materials and Methods: Seven hundred and fifty patients underwent a maxillofacial/dental arches volumetric imaging scan. They were divided into three groups depending on the head support used: foam headrest, foam headrest with head strap, and head restraint helmet. Each group was subdivided into three age groups: ≤ 18 -year-old, 19–65-year-old, and ≥ 66 -year-old patients. A severity index of motion artifacts, divided into four tiers from absence to remarkable artifacts, was adopted. Finally, each patient gave their judgment about the head support comfort by a questionnaire including ten yes/no questions. A three-score scale (insufficient, sufficient, and good) was used to judge the comfort. Collected data were analyzed using the SPSS® version 23.0 statistical analysis software.

Results: Forty-one patients (5.4%) repeated the examination. In 16 (2.1%), 15 (2.0%), and 10 (1.3%) of them, foam headrest, foam headrest with head strap, and head restraint helmet were used, respectively. Examination was repeated in 5.3%, 3.8%, and 10.6% in ≤ 18 -year-old, 19–65-year-old, and ≥ 66 -year-old patients, respectively. Patients almost always judged good the comfort for each kind of support. The lowest percentage of satisfaction was observed for the headrest with head strap and was judged good in 78% of the cases.

Conclusions: The repetition rate of examination showed similar values among the foam headrest, foam headrest with head strap, and head restraint helmet in under 66-year-old patients. In over 65-year-old patients, the head restraint helmet obviously decreased the repetition rate of examination. All three head supports were good comfort, especially the foam headrest.

KEYWORDS: Cone beam computed tomography, head support, means of immobilization/stabilization/fixation/restraint, motion artifacts, patient movement

Received : 13-01-17.

Accepted : 19-06-17

Published : 31-07-17.

INTRODUCTION

Cone beam computed tomography (CBCT) is an excellent imaging technique in dentomaxillofacial volumetric study.^[1] Long acquisition time (5.4–40 s)^[2] increases the risk of head movement and consequently artifacts. They are actually a frequent occurrence (from about 21% to 42% of the examinations) even if not all

Address for correspondence: Dr. Cosimo Nardi,

Department of Experimental and Clinical Biomedical Sciences, Radiodiagnostic Unit n. 2, University of Florence - Azienda Ospedaliero-Universitaria Careggi, Largo Brambilla 3, Firenze 50134, Italy.

E-mail: cosimo.nardi@unifi.it

This is an open access article distributed under the terms of the Creative Commons Attribution-NonCommercial-ShareAlike 3.0 License, which allows others to remix, tweak, and build upon the work non-commercially, as long as the author is credited and the new creations are licensed under the identical terms.

For reprints contact: reprints@medknow.com

How to cite this article: Nardi C, Taliani GG, Castellani A, De Falco L, Selvi V, Calistri L. Repetition of examination due to motion artifacts in horizontal cone beam CT: Comparison among three different kinds of head support. J Int Soc Prevent Communit Dent 2017;7:208-13.

Access this article online

Quick Response Code:



Website: www.jispcd.org

DOI: 10.4103/jispcd.JISPCD_17_17

movements cause artifacts.^[3] However, only <2% of the CBCT examinations is repeated since the image quality is compromised.^[4,5] This is a key point for the patient undergoing CBCT examination because the X-ray dose to the patient doubles when a reexposure is needed. In addition, a good image quality is required by surgeon during the planning of the implant/orthognathic treatment, especially for software-guided planning surgery.^[1]

Many factors can be related to the movement of the patient's head during CBCT examination. They are represented by head position, chin position, presence/absence of cotton rolls to stabilize patient's jaws, CBCT unit arm touching patient's hair, open or shut patient's eyes, and patient's age.^[5,6]

The different kinds of head movement (nodding, tilting, rolling, tremor, and translation) were evaluated by various systems including visual assessment, video recording, accelerometer-gyroscope registration, and automated approach based on optical flow theory.^[4,5,7,8] These showed that keeping a correct position of the head during the whole scan time is essential to achieve an optimal image acquisition.^[9] Horizontal CBCT units use a head support to ensure a better patient stability. Nevertheless, until now, no head support has been tested to reduce patient movement. Further knowledge on head support is relevant for optimizing the head position/stabilization to avoid or minimize motion artifacts.

On this background, the main purpose of our study was to evaluate the repetition rate of examination due to motion artifacts in horizontal CBCT, using three different kinds of head support, with reference to the patient's age. The secondary purpose was to evaluate how comfortable head supports were.

MATERIALS AND METHODS

Independently from gender, disease, treatment, and clinical query, from June 1, 2016 to November 28, 2016, maxillofacial/dental arches of 750 patients (age range 6–83 years) were examined in Florence, Italy, through NewTom 5G CBCT (QR, Verona, Italy). This horizontal unit was chosen because of its very small focal spot (0.3 mm), isotropic voxel (minimum 0.075 mm), large field of view including the entire skull and cervical spine (maximum 18 cm × 16 cm), and SafeBeam™ technology which automatically adjusts the radiation dosage according to the patient's size. This study was approved by the Research Ethics Committee and informed written consent was obtained from each patient.

With reference to previously papers carried out on a large sample size,^[4,10] the patients were divided into three groups of 250 each, in relation to the head support used:

1. Foam headrest [Figure 1]
2. Foam headrest with 5 cm large Velcro head strap [Figure 2]
3. Carbon head restraint helmet covered by foam [Figure 3].

Each patient used only one kind of head support. The patients were consecutively enrolled until expected number was attained. Criteria for allocating the patients in the three different groups were to adopt only one head support cyclically selected in each daily session. Each group was subdivided into three groups in relation to the age:




Figure 1: (a and b) Foam headrest



Figure 2: Foam headrest with Velcro head strap




Figure 3: (a and b) Carbon head restraint helmet covered by foam

- Fifty patients ≤ 18 -year-old (18 s scan time)
- One hundred and fifty patients from 19 to 65-year-old (26 or 36 s scan time)
- Fifty patients ≥ 66 -year-old (36 s scan time).

The choice of the scan time was due to clinical and protectionist reasons.

A bigger number of middle age patients was recruited because this group had a wider age range and two different scan times.

Immediately before the scan, all patients laid down on the table were ordered to keep still to breath slowly and not to swallow. A cotton roll was positioned between the two dental arches in 627 patients to avoid crowns overlapping. Conversely, a cotton roll was not set in 123 patients – dental examinations carried out with prosthesis and occlusal key for software-guided planning surgery, maxillofacial examinations with a large field of view carried out in habitual occlusion for orthognathic purpose, and dental/maxillofacial examinations in toothless jaws – as requested by clinicians.

At the end of the scan time, before the patient got off the CBCT-unit, axial, coronal, and sagittal images were simultaneously examined by two skilled dentomaxillofacial radiologists (21 and 9 years of experience, respectively). They evaluated, in consensus, the presence of motion artifacts, and finally, if the examination had to be repeated in relation to the clinical query.

The following severity index, divided into four tiers, was adopted.

- Degree 0 (G0): Absence of artifacts. No examination repeated
- Degree 1 (G1): No significant artifacts. An excellent image analysis is achievable. No examination repeated
- Degree 2 (G2): Significant artifacts. A diagnostic image analysis is possible. Examination sometimes repeated in relation to the clinical query
- Degree 3 (G3): Remarkable artifacts. A reliable opinion cannot be formulated. Examination always repeated.

The re-exposure always occurred with the same scan time and head support, without cotton roll, changing the masticatory muscles contraction. The result of the second scan was evaluated separately. A third scan was never performed.

At the end of the examination, each patient gave their judgment about the comfort of the head support in relation to their subjective perception. They filled out a questionnaire representing their degree of satisfaction with the head support comfort. The questionnaire was

made up of ten questions [Figure 4]. All the questions answered yes or no. The judgment was insufficient, sufficient, or good when the positive answers were 9–10, 7–8, or 0–6, respectively.

Collected data were analyzed using the SPSS® version 23.0 statistical analysis software (IBM Corp., New York, NY, USA; formerly SPSS Inc., Chicago, IL, USA).

RESULTS

On the whole, 361 patients (48.2%) showed motion artifacts (G1 + G2 + G3), which drove us to repeat the examination in 41 cases (5.4%) [Table 1]. The presence of artifacts happened in two-third, one-third, and four-fifth of the cases in ≤ 18 -year-old, 19–65-year-old, and ≥ 66 -year-old patients, respectively. The repetition rate of the examination of the three different kinds of head support depending on the three age groups was reported in Figure 5. The repetition of the examination occurred in 5.3%, 3.8%, and 10.6% in ≤ 18 -year-old, 19–65-year-old, and ≥ 66 -year-old patients, respectively. Only as regards the repeated examinations [Table 1], G2 and G3 did not show significant difference in the middle age patients, but G3 was 90% and 75% in young and old patients, respectively.

It should be underlined that, within the young group, 6 out of 8 repeated examinations (75%) occurred in 6–9-year-old patients, whereas into the old group, 11 out of 16 repeated examinations (68.7%) occurred in 76–83-year-old patients.

As for the 41 repetitions, i.e., examinations carried out without cotton roll during the second scan, 37 patients used cotton roll in the first scan. After the second scan, 15 out of 41 were considered satisfactory to express a radiological response. About the above-mentioned 15 patients, cotton roll was used in 14 patients in the first scan, whereas it was never used in an only one patient.

As regards the head supports [Table 2], the foam headrest and the foam headrest with head strap showed very similar severity index where G0 was less than half of the

1. Was the head support soft enough?
2. Did you have any difficulty breathing?
3. Did you have a headache?
4. Did you feel any head tightness?
5. Did you have any problem with your eyesight?
6. Did you have any problem with your hearing?
7. Did you feel any bad smell?
8. Did you feel any bad taste?
9. Did you feel any pain or discomfort in your cervical spine?
10. Did you have any problem with the head support material?

Figure 4: Questionnaire on the head supports comfort

cases. The helmet clearly decreased patient movement producing highest G0 (two-thirds of the cases) and lowest G3 (around one-third less than the other two head supports).

Comfort was never insufficient. It was good in 95%, 78%, and 83% for the foam headrest, foam headrest with head strap, and helmet, respectively [Figure 6]. The foam headrest with head strap was the less accepted head support at all ages. The main complaint was the feeling of head tightness due to the large Velcro head strap covering the full forehead. In all patients under 66-year-old, the foam headrest and helmet were well accepted, while in old patients, the stiffness – no soft enough – of the helmet was a source of annoyance.

DISCUSSION

Repetition of examination due to motion artifacts was correlated both to head support and age. The absence of artifacts was higher than the presence of artifacts

only in 19–65-year-old patients. In younger and under 66-year-old patients, the three different kinds of head support did not show obvious differences in motion artifacts. In old people, the helmet evidently reduced the presence of artifacts probably because reduced micromovements caused by essential tremors.

The total amount of repeated examinations was 5.4%, which was clearly higher in comparison to previous papers performed by Nardi *et al.*^[4] (1.9%) who investigated Southern European patients through horizontal CBCT, Spin-Neto *et al.* (0.5%),^[5] and Donaldson *et al.* (0.4%),^[10] who both investigated Northern European patients through vertical CBCT. The time when operators decided that examination needed to be repeated was not described in the three above-mentioned papers.

High repetition rate of examination in the present study (5.4%) might be due to immediate and simultaneously assessment of the images carried out by

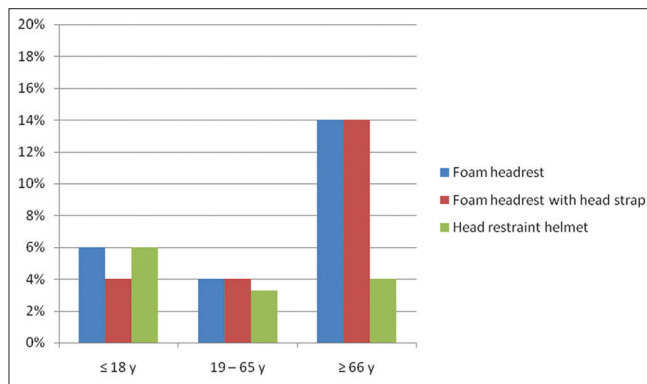


Figure 5: Repetition rate of the examination of the three different kinds of head support relating to the three age groups. The values were expressed as a percentage

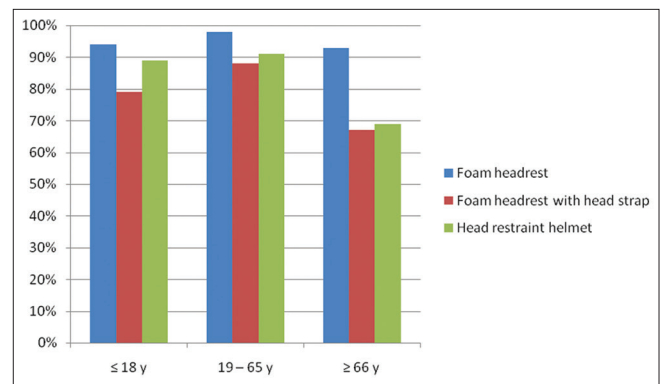


Figure 6: Comfort of the three different kinds of head support, as far as responses were judged as good, relating to the three age groups. The values were expressed as a percentage

Table 1: Artifacts prevalence, by severity index, relating to the patients' age

Severity index	≤18 years (%)	19-65 years (%)	≥66 years (%)	Total (%)
Degree 0	58/150 (38.6)	301/450 (66.9)	30/150 (20.0)	389/750 (51.8)
Degree 1	68/150 (45.5)	62/450 (13.8)	77/150 (51.4)	207/750 (27.6)
Degree 2	17/150 (11.3)	77/450 (17.1)	31/150 (20.6)	125/750 (16.7)
Degree 3	7/150 (4.6)	10/450 (2.2)	12/150 (8.0)	29/750 (3.9)
Total	150/150 (100)	450/450 (100)	150/150 (100)	750/750 (100)

Degree 2 examinations were repeated in 1 (0.7%), 7 (1.6%), and 4 (2.6%) in ≤18-, 19-65-, and over 65-year-old patients, respectively

Table 2: Artifacts prevalence, by severity index, relating to the head support

Severity index	Foam headrest (%)	Foam headrest with head strap (%)	Head restraint helmet (%)	Total (%)
Degree 0	107/250 (42.8)	114/250 (45.6)	168/250 (67.2)	389/750 (51.8)
Degree 1	84/250 (33.6)	77/250 (30.8)	46/250 (18.4)	207/750 (27.6)
Degree 2	47/250 (18.8)	49/250 (19.6)	29/250 (11.6)	125/750 (16.7)
Degree 3	12/250 (4.8)	10/250 (4.0)	7/250 (2.8)	29/750 (3.9)
Total	250/250 (100)	250/250 (100)	250/250 (100)	750/750 (100)

Degree 2 examinations were repeated in 4 (1.6%), 5 (2.0%), and 3 (1.2%) in foam headrest, foam headrest with head strap, and head restraint helmet, respectively

the two radiologists before the patient got off the CBCT unit. Nevertheless, the repetition rate was at upper limits to that recommended by the current European guidelines, stating that a maximum of 5% of all CBCT examinations could be considered diagnostically unacceptable and require a repetition.^[11]

In over 65-year-old patients, motion artifacts needing a repetition of the examination were twice the one performed in ≤ 18 -year-old patients and about triple in comparison to those done in 19–65-year-old patients. It confirmed what previous papers reported in which motion artifacts heavily depended on the patient's age.^[4,5,10,12] The repetition of the examination was almost always caused by remarkable artifacts in young and old patients, while significant and remarkable artifacts showed similar values in under 66-year-old adults. This was because the choice to repeat the examination was closely linked to the clinical query. In our series, many examinations carried out in middle age patients were required by clinicians for software-guided planning surgery with possible stereolithography model reconstruction. This technique needed very high image quality with no motion artifacts.

We noted that the majority of the repeated examinations occurred in borderline ages, from 6 to 9 and from 75 to 83-year-old patients. This might prove that there was a different ability in keeping a head and neck muscular control, and as for children in following the operator's instructions too. However, according to Spin-Neto *et al.*^[5] and Hanzelka *et al.*,^[6] it is basic to give right instructions to patient before scan to achieve a correct examination performance.

Despite scan time was evidently lower in young (18 s) than middle age patients (26 or 36 s), motion artifacts and consequently repetition of examination was higher in young patients. In fact, independently from age, in CBCT, motion artifacts are related to the ratio between patient movement time and scan time, i.e., motion artifacts depend on the number of the images acquired during the patient movement with respect to the total number of the images.^[3] Therefore, to reduce the scan time does not automatically mean to reduce motion artifacts and/or repetition of CBCT examinations.

Around one-third of the repeated examinations after the second scan resulted to be adequate for a diagnostic judgment. We supposed that cotton roll could be one of the reasons of the mouth movement. This was for the trouble due to the contact of the cotton with oral mucosa and for the difficulty in keeping a steady and continuous masticatory muscles contraction as stated by Spin-Neto *et al.*^[5]

As regards head supports, the foam headrest was the most comfortable in all ages and showed the highest

motion artifacts and repetition rate of examination. This was because the foam headrest left the face exposed and the patient head rested only on the occipital area. The addition of the head strap at the foam headrest did not give substantial improvement in the reduction of motion artifacts and repetition rate of examination. The foam headrest with head strap was the most uncomfortable in all ages because of its 5 cm width covering forehead and sometimes part of eyes and/or hair; one more reason was the frontooccipital head compression that caused head tightness feeling. The helmet showed the lowest motion artifacts and repetition rate of examination since fixed the head on three sides with more laterally compression, leaving the forehead relatively free. Nevertheless, the helmet tightness sharply decreased the comfort in old patients who more frequently suffered from cervical pain with kyphosis and osteoarthritis.

We chose to use a low dose volumetric imaging technique as NewTom 5G CBCT^[13] because it was the first time that head supports were tested to decrease motion artifacts in an horizontal CBCT-unit. Furthermore, this kind of unit allows various novel non-dental diagnostic options that could take advantage of specific and suitable means of immobilization, such as the study of ear, paranasal sinuses, orbit, cervical spine, and extremities.^[14,15] The same devices of restraint could be also used in multislice spiral computed tomography since patient takes an equal position during the examination.

Controversy might arise from the subjective method for assessing motion artifacts using a severity index. However, this is what commonly happens in the clinical practice when a choice to (non-) repeat CBCT examination has to be taken since guidelines are still not drawn up on how to deal in case the patient moves.

A weakness of our study was not to have an uniform sample on clinical query, which was a key factor in deciding whether or not to repeat the examination. Furthermore, we did not consider the movement of the mandible alone, which is the only independently mobile bone of the maxillofacial complex. One more limit was not to test the most common vertical CBCT units in which patient is seated or stands up.

To reduce motion artifacts and repetition of examination, further studies should investigate the interaction between patient position (supine, sitting, and standing) and patient movement using various means of head/chin/mouth/jaws immobilization. Additional studies should be directed to develop software for mathematical algorithms that correct images acquired during patient movement.

We hope manufactures will produce better and more performing head supports in the next future, especially for

children under 10-year-old and adults over 75-year-old patients. That might ensure a better image quality with high definition of the anatomical structures and accurate two-dimensional or three-dimensional measurements to achieve a safer surgical/medical approach.

CONCLUSIONS

In ≤18-year-old and 19–65-year-old patients, repetition rate of examination did not show substantial differences among the foam headrest, foam headrest with head strap, and head restraint helmet even though the latter was the most performing. In over 65-year-old patients, the head restraint helmet clearly decreased both motion artifacts and repetition of examination. All three head supports were good comfortable, especially the foam headrest.

FINANCIAL SUPPORT AND SPONSORSHIP

Nil.

CONFLICTS OF INTEREST

There are no conflicts of interest.

REFERENCES

- Liang X, Jacobs R, Hassan B, Li L, Pauwels R, Corpas L, *et al.* A comparative evaluation of cone beam computed tomography (CBCT) and multi-slice CT (MSCCT) Part I. On subjective image quality. *Eur J Radiol* 2010;75:265-9.
- Nemtoi A, Czink C, Haba D, Gahleitner A. Cone beam CT: A current overview of devices. *Dentomaxillofac Radiol* 2013;42:20120443.
- Nardi C, Molteni R, Lorini C, Taliani GG, Matteuzzi B, Mazzoni E, *et al.* Motion artefacts in cone beam CT: An *in vitro* study about the effects on the images. *Br J Radiol* 2016;89:20150687.
- Nardi C, Borri C, Regini F, Calistri L, Castellani A, Lorini C, *et al.* Metal and motion artifacts by cone beam computed tomography (CBCT) in dental and maxillofacial study. *Radiol Med* 2015;120:618-26.
- Spin-Neto R, Matzen LH, Schropp L, Gotfredsen E, Wenzel A. Factors affecting patient movement and re-exposure in cone beam computed tomography examination. *Oral Surg Oral Med Oral Pathol Oral Radiol* 2015;119:572-8.
- Hanzelka T, Dusek J, Ocacek F, Kucera J, Sedy J, Benes J, *et al.* Movement of the patient and the cone beam computed tomography scanner: Objectives and possible solutions. *Oral Surg Oral Med Oral Pathol Oral Radiol* 2013;116:769-73.
- Schulze RK, Michel M, Schwanecke U. Automated detection of patient movement during a CBCT scan based on the projection data. *Oral Surg Oral Med Oral Pathol Oral Radiol* 2015;119:468-72.
- Spin-Neto R, Matzen LH, Schropp L, Gotfredsen E, Wenzel A. Detection of patient movement during CBCT examination using video observation compared with an accelerometer-gyroscope tracking system. *Dentomaxillofac Radiol* 2017;46:20160289.
- Spin-Neto R, Wenzel A. Patient movement and motion artefacts in cone beam computed tomography of the dentomaxillofacial region: A systematic literature review. *Oral Surg Oral Med Oral Pathol Oral Radiol* 2016;121:425-33.
- Donaldson K, O'Connor S, Heath N. Dental cone beam CT image quality possibly reduced by patient movement. *Dentomaxillofac Radiol* 2013;42:91866873.
- SEDENTEXCT Project. Radiation Protection No. 172: Cone Beam CT for Dental and Maxillofacial Radiology. Luxembourg: European Commission Directorate-General for Energy; 2012.
- Spin-Neto R, Matzen LH, Schropp L, Gotfredsen E, Wenzel A. Movement characteristics in young patients and the impact on CBCT image quality. *Dentomaxillofac Radiol* 2016;45:20150426.
- Nardi C, Talamonti C, Pallotta S, Saletti P, Calistri L, Cordopatri C, *et al.* Head and neck effective dose and quantitative assessment of image quality: a study to compare Cone Beam CT and Multislice Spiral CT. *Dentomaxillofac Radiol* 2017;46:20170030.
- Carrino JA, Al Muhit A, Zbijewski W, Thawait GK, Stayman JW, Packard N, *et al.* Dedicated cone-beam CT system for extremity imaging. *Radiology* 2014;270:816-824.
- Nardi C, Buzzi R, Molteni R, Cossi C, Lorini C, Calistri L, *et al.* The role of Cone Beam CT in the study of symptomatic total knee arthroplasty (TKA): a 20 cases report. *Br J Radiol* 2017;90:20160925.