

# Medial Plantar Artery Perforator Flap: Experience with Soft-tissue Coverage of Heel

Fahad Hanif Khan, MBBS  
Mirza Shehab Afzal Beg, FRCS  
Obaid-ur-Rahman, FCPS

**Background:** Soft-tissue coverage is a challenge to the ankle and foot reconstructive surgeon due to its unique requirement of simultaneously withstanding body weight and to provide sensory feedback. We share our experience of medial plantar artery perforator (MPAP) flap, which provides a robust sensate coverage to heel defects.

**Methods:** Three-year retrospective study, which included soft-tissue injury to heel. All patients underwent MPAP flap for the coverage of the defect. Patients' demographic, mode of injury, defect size, flap size and survival, time to start weight bearing, return of protective sensations, and comparative 2-point discrimination with opposite heel were studied.

**Results:** We studied 16 cases with heel soft-tissue injuries. Fifteen had motor vehicle accident, and 1 had chronic diabetic wound. Mean surface area of flap was 4×5 cm. Except 1 flap, 15 flaps had complete survival and provided reliable wound coverage with comparable normal sensation as on other foot.

**Conclusion:** We suggest that MPAP flap, when available, is a good local tissue for heel wounds coverage. (*Plast Reconstr Surg Glob Open* 2018;6:e1991; doi: 10.1097/GOX.0000000000001991; Published online 14 December 2018.)

## INTRODUCTION

Soft-tissue injury of heel is a great challenge to deal with because of limited reconstructive options and the unique local area demand. The loss of adherent and thick glabrous skin of sole makes it hard for regional and distant flaps to withstand the demand of significant body weight. A limited number of local, regional, and free flaps<sup>1</sup> are available, which aim to cover the defect with minimal donor-site morbidity and to tolerate the transmitted body weight. In 1990, Masquelet and Romana<sup>2</sup> described medial plantar artery flap to reconstruct heel with the most closely matched skin surface and with lesser donor-site morbidity. Since then, there had been studies using medial artery perforator flap as a pedicle flap for local coverage.<sup>3,4</sup>

There had been study from our country comparing 2 fasciocutaneous flaps for coverage of heel defects,<sup>4</sup> concluding medial plantar artery flap to be superior to reverse sural artery flap, but the former has long learning curve to master the art as compared with latter which needs approximately twice as long to be able to fully bear body weight and is a nonsensate flap, thus carries a continuous

threat of trauma or ulceration. Through this study, we aim to share our experience with medial plantar artery flap for reconstructing soft-tissue defects of heel.

## METHODS

This was a retrospective study spanning over a period of 3 years, from January 2015 to January 2018, conducted at the Department of Plastic Surgery at a tertiary care hospital in Karachi. This hospital is a private sector teaching hospital equipped with multidisciplinary teams and specialized equipments. It has not only played a central role in treating patients of Afghan war, but has produced health care professionals who are serving at key posts in other hospitals. As a teaching hospital, we inform and take written consent from our patients for possible use of data for research purposes, keeping their identification anonymous. The institute's review board has approved the study design.

We retrieved and reviewed our data base for heel reconstruction with medial plantar perforator artery flap and assessed it for demographic profile, mode of injury, flap reconstruction, survival, and follow-up. Outcome was assessed in terms of duration to bear weight and return of protective sensations.

## Flap Dissection

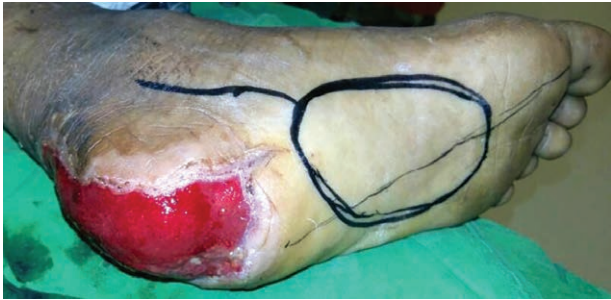After initial judicious debridement, all patients had hand-held Doppler probe (8 Mhz) localization of dorsalis

*From the Department of Plastic and Reconstructive Surgery, Liaquat National Hospital, Karachi, Pakistan.*

*Received for publication January 10, 2018; accepted June 1, 2018.*

*Written work prepared by employees of the Federal Government as part of their official duties is, under the U.S. Copyright Act, a "work of the United States Government" for which copyright protection under Title 17 of the United States Code is not available. As such, copyright does not extend to the contributions of employees of the Federal Government.*

**Disclosure:** *The authors have no financial interest to declare in relation to the content of this article. The Article Processing Charge was paid for by the authors.*



**Fig. 1.** Flap mapping according to heel defect after debridement and vacuum dressing.

pedis and medial plantar arteries. A template of the defect was mapped (Fig. 1). Under general anesthesia and tourniquet control, with patient in lateral decubitus position, an incision on the medial border of instep area was given (parallel to abductor hallucis muscle) and a fasciocutaneous flap was raised, superficial to flexor hallucis muscle and in a retrograde direction. The superficial branch (perforator) of medial plantar artery was visualized, and the lateral plantar neurovascular bundle was carefully identified (Fig. 2). The lateral sensory branch of medial plantar nerve innervating the flap was identified and neurolysis done to gain additional length. The flap was islanded and rotated 180 degree to cover heel defect. Donor site and non-weight-bearing areas were covered with split-thickness skin graft.

## RESULTS

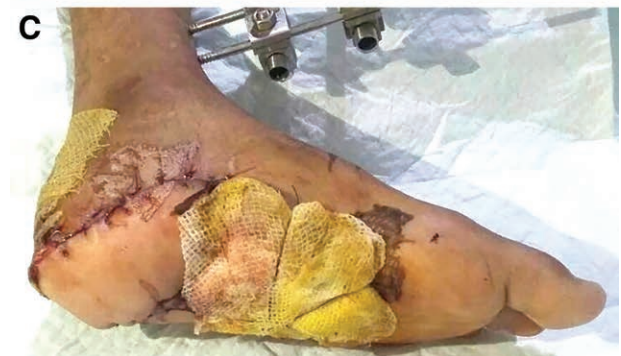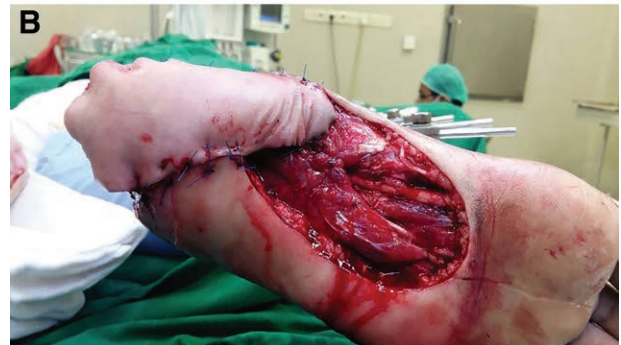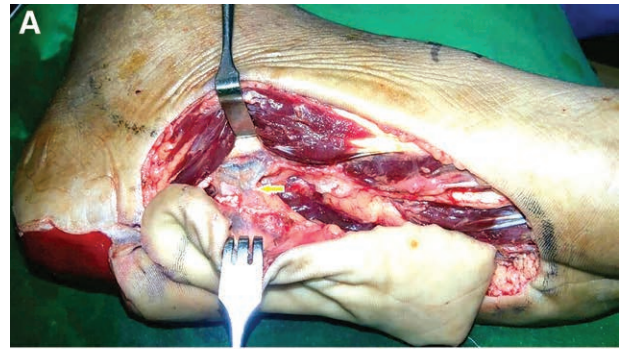
We treated 16 patients with medial plantar perforator artery flap, in which male to female ratio was 7:1. The mode for age group was 23 (range, 6–56 years). Our 15 (93.7%) patients had motor vehicle accident while 1 (6.2%) had chronic nonhealing wound due to contact burn for last 1.5 year. In motor vehicle accident group, 11 (73.3%) patients had isolated heel injury with spoke of wheel.

Eleven (73.3%) patients had soft-tissue defect only on heel (calcaneum), while other 4 (26.6%) had exposed Achilles tendon insertion, with mean surface area of the defect was 10×6 cm. One elderly patient had uncontrolled diabetes for last 8 years for which preoperative optimization was done before proceeding for reconstruction.

### Outcomes

Mean duration from injury to reconstruction was 3±2 days. We islanded 13 (83.3%) flaps for gaining additional arc of rotation. Mean surface area of flap was 4×5 cm. Flaps survived in 15 patients (93.7%), while the only flap which did not survive was of the diabetic elder patient who had poor flap perfusion despite good Doppler signals on dorsalis pedis and posterior tibial arteries. We covered donor site with meshed split-thickness skin graft from thigh on medial plantar arch which had 100% take. All patients had improvised splints for deferring pressure from flap zone (Fig. 3).

Mean follow-up was for 11 months (range, 2–18 months) with all 15 (93.7%) patients with flap survival achieving weight bearing at 6 weeks ± 4 days. The patient with flap

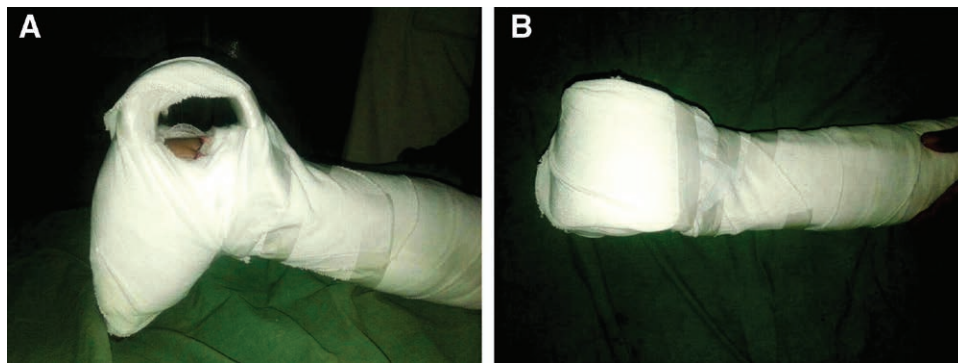


**Fig. 2.** Identification of superficial branch of medial plantar artery (arrow in A), inset of the flap (B) and bolster dressing on graft at the donor site (C).

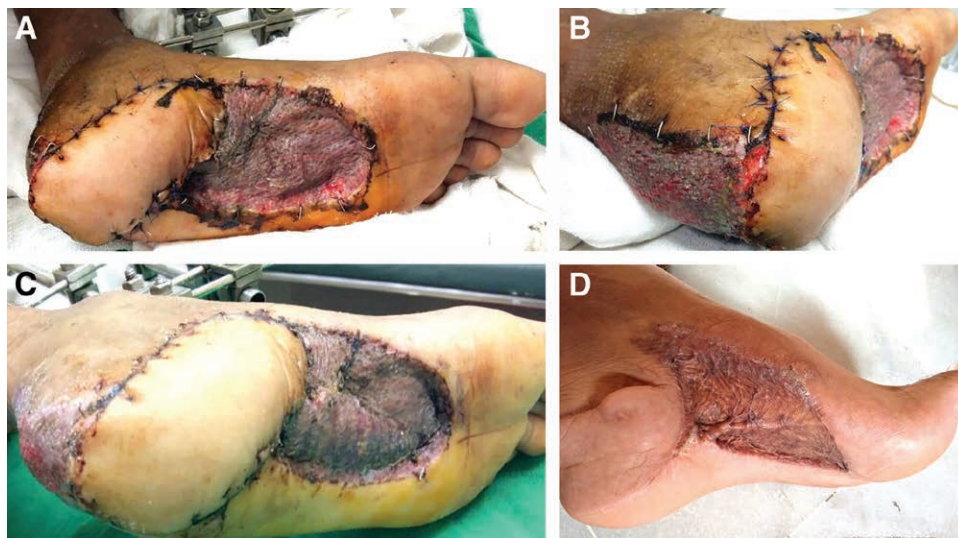
failure had loss of follow-up for 18 days post-procedure and later on he was managed conservatively on dressings. Protective sensation was noticed by 4±2 days. We did not assess lateral plantar sensory innervation routinely; however, none of our patients complained of decreased or loss of sensation in this territory. Mean static 2-point discrimination (2-PD) at 14th postoperative day was 11 mm at flap as compared with 9 mm on the normal heel. On 6 months follow-up, mean static 2-PD was 10.5 mm on flap.

## DISCUSSION

Covering the heel soft-tissue defects has always been a challenge for plastic surgeons. The demand of local tissue for bearing significant body weight makes it a unique tissue, thus local flaps are good and viable options. Reverse sural artery flap,<sup>5</sup> medial plantar artery flap, or peroneal perforator artery flaps<sup>6</sup> are viable local options, each having pros and cons of the procedure.<sup>7</sup>



**Fig. 3.** Two views (A and B) of improvised splint to off load pressure from heel after flap inset.



**Fig. 4.** Completely covered defect (A and B) after 5 days and at 3 weeks of flap inset (C). Follow-up after 18 months of the procedure (D).

Medial plantar perforator artery flap has satisfied most of the requirements, especially its sensory feedback and thick glabrous skin which distinguishes it. This flap does not only provide coverage to hind foot but is a viable option for mid and fore foot defects too.<sup>8-10</sup> As we dissected our flap on a perforator of medial plantar artery, it was not important to confirm the patency of dorsalis pedis artery in every patient as the plantar arterial arch was not disturbed. Due to its difficult dissection, it has a long learning curve to master, but is easier than free micro-vascular tissue transfer, requiring less effort and monitoring. As compared with sensate reverse sural artery flap, which covers heel defects with soft and pliable posterior leg skin, medial plantar artery flap provides glabrous sensate skin fulfilling local area demands. Another problem with reverse sural artery flap is tissue edema in long-term follow-up,<sup>11</sup> probably due to reversed venous flow and fluid stasis; however, we did not observe any significant tissue edema in medial plantar artery flap even at 18 months of follow-up (Fig. 4). Patients regained protective sensation on covered area in  $4 \pm 2$  days, which was always inferior as compared with normal foot, reported by Siddiqi et al.<sup>12</sup> too. Similarly, static 2-point discrimination was near normal at 14th postoperative day, as

compared with 34.4mm, reported by Gu et al.,<sup>13</sup> which may be due to selective neurolysis of sensory branch to flap. On follow-up, we observed that the split skin graft that covered the donor site of the flap was firm and hyperkeratotic, which might be due to continuous force on the area.

In our data, 1 patient had complete loss of the flap. The patient had Charcot foot for which he already had multiple debridements and glabrous skin grafting. After adequate debridement, he had medial plantar artery flap rotation to cover his heel defect with postoperative pressure offloading splint, as published by Sato and Ichioka.<sup>14</sup> He initially had distal flap loss with complete loss at 18th postoperative day and now has improved wound on conservative management.

## CONCLUSIONS

From our experience, medial plantar artery flap is a good local option for soft-tissue coverage, providing glabrous sensate skin for foot wounds.

*Fahad Hanif Khan, MBBS*  
 Department of Plastic and Reconstructive Surgery  
 Liaquat National Hospital  
 National Stadium road, Karachi, Pakistan  
 E-mail: dr.fhkh@hotmail.com

## REFERENCES

1. Yücel A, Senyuva C, Aydin Y, et al. Soft-tissue reconstruction of sole and heel defects with free tissue transfers. *Ann Plast Surg.* 2000;44:259–268; discussion 268.
2. Masquelet AC, Romana MC. The medialis pedis flap: a new fasciocutaneous flap. *Plast Reconstr Surg.* 1990;85:765–772.
3. Mahmoud WH. Foot and ankle reconstruction using the distally based sural artery flap versus the medial plantar flap: a comparative study. *J Foot Ankle Surg.* 2017;56:514–518.
4. Rashid M, Hussain SS, Aslam R, et al. A comparison of two fasciocutaneous flaps in the reconstruction of defects of the weight-bearing heel. *J Coll Physicians Surg Pak.* 2003;13:216–218.
5. Zheng L, Zheng J, Dong ZG. Reverse sural flap with an adipofascial extension for reconstruction of soft tissue defects with dead spaces in the heel and ankle. *Eur J Trauma Emerg Surg.* 2016;42:503–511.
6. Ahn DK, Lew DH, Roh TS, et al. Reconstruction of ankle and heel defects with peroneal artery perforator-based pedicled flaps. *Arch Plast Surg.* 2015;42:619–625.
7. El-Shazly M, Yassin O, Kamal A, et al. Soft tissue defects of the heel: a surgical reconstruction algorithm based on a retrospective cohort study. *J Foot Ankle Surg.* 2008;47:145–152.
8. Javed MU, Josty IC. Salvage of a complex first metatarso-phalangeal joint injury and synchronous reconstruction of medial collateral ligament and soft tissue with a distally based medial plantar artery flap. *J Plast Reconstr Aesthet Surg.* 2016;69:e61–e63.
9. Wu H, Sheng JG, Zhang CQ. Free medial plantar flap connection with a posterior tibial artery flap in reconstruction of fore-mid foot skin defect. *Plast Reconstr Surg Glob Open.* 2016;4:e1091.
10. Scaglioni MF, Rittirsch D, Giovanoli P. Reconstruction of the heel, middle foot sole, and plantar forefoot with the medial plantar artery perforator flap: clinical experience with 28 cases. *Plast Reconstr Surg.* 2018;141:200–208.
11. Tan O, Atik B, Bekerecioglu M. Supercharged reverse-flow sural flap: a new modification increasing the reliability of the flap. *Microsurgery.* 2005;25:36–43.
12. Siddiqi MA, Hafeez K, Cheema TA, et al. The medial plantar artery flap: a series of cases over 14 years. *J Foot Ankle Surg.* 2012;51:790–794.
13. Gu JX, Huan AS, Zhang NC, et al. Reconstruction of heel soft tissue defects using medial plantar artery island pedicle flap: clinical experience and outcomes analysis. *J Foot Ankle Surg.* 2017;56:226–229.
14. Sato T, Ichioka S. Osteotomy and medial plantar artery flap reconstruction for charcot foot ulceration involving the midfoot. *J Foot Ankle Surg.* 2016;55:628–632.