

## The efficacy and safety of using amplatzer for transcatheter closure of atrial septal defect in small children with less than 10 kg

Mehdi Ghaderian<sup>(1)</sup> , Mohammad Reza Sabri<sup>(2)</sup>, Ali Reza Ahmadi<sup>(1)</sup>, Bahar Dehghan<sup>(3)</sup>, Chehre Mahdavi<sup>(3)</sup>, Zakie Zahra Ataei<sup>(4)</sup>

### Original Article

#### Abstract

**BACKGROUND:** Atrial septal defect (ASD) accounts for about 10% of congenital heart diseases (CHDs). Self-closure of these defects in patients with defects less than 8 mm has been reported in several studies. In children, transcatheter closure of the ASD is suggested for asymptomatic patients older than two years and with weight > 15 kg. The purpose of this study was to show that transcatheter closure of ASD in small children with body weight less than 10 kg is an effective and safe method.

**METHODS:** Between July 2016 and September 2018, 35 children with body weight less than 10 kg underwent percutaneous closure of ASD using amplatzer. All patients had minimum defect size of 6 mm, pulmonary blood flow (Qp) to systemic blood flow (Qs) ratio above 1.5, right atrial and ventricular dilation, symptoms of delayed growth, and recurrent respiratory infections in their evaluation and had acceptable rims for intervention. Follow-up evaluations were done 1 day, 1 week, 1 month, 6 months, and yearly after discharge with transthoracic echocardiography (TTE) and electrocardiography (ECG).

**RESULTS:** The mean age of patients at procedure was  $12.06 \pm 4.47$  months (range: 6 to 14 months), mean weight was  $8.32 \pm 0.72$  kg (range: 7.5 to 9.8 kg). The mean defect size was  $10.00 \pm 2.32$  mm (range: 6-13 mm). The mean device size used was  $10.57 \pm 2.57$  mm (range: 7.5 to 15 mm). Mean duration of follow-up was  $16.66 \pm 6.93$  months (range: 1-29 months). Respiratory rate, heart rate, pulmonary stenosis (PS), and Qp to Qs ratio had significant difference before and after procedure during the follow up ( $P < 0.001$ ).

**CONCLUSION:** Transcatheter closure of ASD with amplatzer in symptomatic small children and infants is a safe and effective treatment associated with excellent success, but long-term follow-up in a large number of patients would be warranted.

**Keywords:** Atrial Septal Defect, Devices, Septal Occluder

*Date of submission:* 01 June 2018, *Date of acceptance:* 10 Nov. 2018

#### Introduction

Atrial septal defect (ASD) is one of the most common congenital heart diseases (CHDs) and accounts for about 10% of CHDs, which is regarded as the third common CHD in the world.<sup>1</sup> There are various types of this malformation, which cause blood shunt between the systemic and respiratory blood stream. The majority of these atrial defects can be observed in the central area of atrial septum and fossa ovalis, size of which can

vary from a small hole to extremely large defects which involve almost the entire atrial septum.

**How to cite this article:** Ghaderian M, Sabri MR, Ahmadi AR, Dehghan B, Mahdavi C, Ataei ZZ. **The efficacy and safety of using amplatzer for transcatheter closure of atrial septal defect in small children with less than 10 kg.** ARYA Atheroscler 2019; 15(1): 27-32.

1- Associate Professor, Pediatric Cardiovascular Research Center, Cardiovascular Research Institute, Isfahan University of Medical Sciences, Isfahan, Iran

2- Professor, Pediatric Cardiovascular Research Center, Cardiovascular Research Institute, Isfahan University of Medical Sciences, Isfahan, Iran

3- Assistant Professor, Pediatric Cardiovascular Research Center, Cardiovascular Research Institute, Isfahan University of Medical Sciences, Isfahan, Iran

4- Student of Medicine, Cardiac Rehabilitation Research Center, Cardiovascular Research Institute, Isfahan University of Medical Sciences, Isfahan, Iran

Correspondence to: Mehdi Ghaderian, Email: ghader\_45@yahoo.co.uk

Presentation of the disease is more marked during adulthood and is diagnosed with heart failure (HF) or cardiac dysrhythmia during the third or fourth decade of life. In infants, this disease could be manifested by recurrent respiratory infections, delayed growth, reduced activity tolerance, and HF, even at an early age. Self-closure of these defects in patients with an ASD of less than 8 mm has been reported in several studies.<sup>2,3</sup>

Hemodynamically, it is suggested that these defects must be closed in patients with the ratio of pulmonary blood flow to systemic blood flow ( $Q_p/Q_s$ ) of above 1.5 and/or a dilated right atrium and ventricle. Surgical treatment of these patients has been initiated since the 1960s, which has had positive results and is performed before the age of 25 years. Studies have indicated that surgical closing of ASD can significantly improve the function and morphology of the right ventricle. Interventional closure of this atrial defect was reported and has had significant advances during the past years. Compared to other surgical techniques, this method is associated with shorter hospital stay and fewer complications.<sup>4</sup> In children, closure of the defect is suggested for asymptomatic patients older than 2 years and with weight  $> 15$  kg.<sup>5,6</sup> Symptomatic patients who suffer from recurrent respiratory diseases or lack of sufficient growth and require respiratory support, might benefit from the correction of this defect at an earlier age. Closure of ASD at earlier ages requires more experience in this area, and there is a limited number of reports in this regard.<sup>1,2,7-16</sup>

This research aimed to evaluate the reliability, safety, and effectiveness of percutaneous ASD closure in patients with body weight less than 10 kg.

### Materials and Methods

This observational prospective study was approved by the Ethics Committee of Isfahan University of Medical Sciences, Isfahan, Iran (IR.MUI.MED.REC.1398.067) and written informed consent was obtained from the parents before the procedures. All patients with ASD and body weight less than 10 kg who were hospitalized in Chamran Hospital affiliate to Isfahan University of Medical Sciences during July 2016 to September 2018 and underwent intervention procedures for ASD closure entered the research.

Inclusion criteria were body weight less than 10 kg, minimum ASD size of 6 mm and more, having  $Q_p/Q_s$  above 1.5 in echocardiography evaluations, having right atrial and ventricular

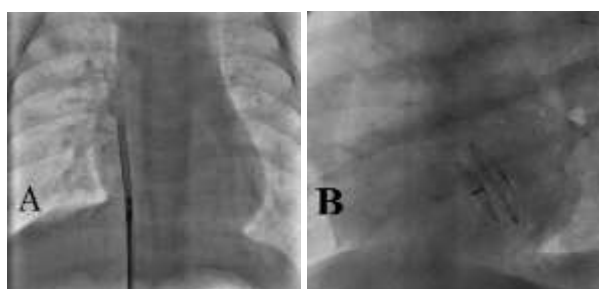
dilatation, having the symptoms of delayed growth, and having recurrent respiratory infections.

Exclusion criteria were: patients with other complex heart diseases who required corrective surgery, patients with body weight more than 10 kg, and patients with no acceptable rims for ASD closure according to echocardiography evaluations.

At first, patients underwent echocardiography which was performed by a pediatric cardiologist in children heart clinic, and were hospitalized in the center for intervention after proving the presence of ASD and the existence of reliable rims and rulling out the existence of partial anomalous pulmonary venous connection (PAPVC). Echocardiography was performed using Samsung MEDISON EKO 7 Ultrasound Machine (Samsung Co., Seoul, South Korea), and all necessary information was recorded in medical files of the patients. Two-dimensional (2D) transthoracic echocardiography (TTE) was performed in standard apical four chamber, subcostal four chamber, and subcostal bicaval views for accurate calculation of ASD size. Signs of increased volume overload in the right side of the heart, along with the increased size of right heart side were observed in all patients. In addition, all of the patients underwent anesthesia with midazolam and ketamine in catheterization room. In the beginning of angiography, patients were injected with 50 units/kg of heparin, followed by the administration of the next doses of heparin for patients with activated clotting time (ACT) values above 200 seconds. During the process, patients received a dose of cefazolin, which continued for 24 hours. Angiography was performed according to standard protocols, and patients were evaluated during the process for pulmonary artery pressure (PAP).

Angiography was performed in the pulmonary artery and right upper pulmonary vein (RUPV) for more accurate assessment of the absence of PV anomalies. Closure of ASD was performed under fluoroscopy and angiography and by controlling the process by TTE. However, no balloon sizing was used, and size of ASD was measured by echocardiography. In ASDs below 10 mm, an amplatzer was designated based on ASD size and in sizes above 10 mm the device was selected 1-2 mm more than echocardiographic size. The selected device was entered into the left atrium by the delivery system that was suitable for selected device and had the smallest size because of low weight of patients. Left disc of device was opened at the beginning of the left upper PV (LUPV), followed by the opening of the right disc in the right atrium and

testing of accurate placement and strength of amplatzer on septum with "Minnesota wiggle" maneuver. If the guiding of the device toward the LUPV was difficult in a patient, the RUPV would be used as opening of amplatzer (Figure 1). At the end of the procedure and before releasing the device, echocardiography, contrast echo, and injection of contrast agent in left atrium were performed to ensure the lack of presence of any residue, followed by the release of the device. At the end, the open disc measurement was performed at the best possible angle which showed the exact size, and the result was compared with the echo size.



**Figure 1.** Implantation of atrial septal defect (ASD) device occluder in right upper pulmonary vein (RUPV) approach during (A) and at the end of procedure (B)

Patients received heparin for 24 hours and 3-5 mg/kg of aspirin for six months on a daily basis. Moreover, echocardiography was performed on patients 1 day and 1, 3, and 6 months after the procedure and then annually. Serial electrocardiography (ECG) analysis was carried out for all patients in the next follow-ups to evaluate delayed arrhythmias. Patients were discharged from the hospital after 24 hours and received outpatient follow-up in the next appointments.

Quantitative and categorical data were expressed as mean  $\pm$  standard deviation (SD) (minimum-

maximum) and frequency and percentage, respectively. Within-group comparisons based on quantitative data were conducted using paired samples t-test. Analyses were performed by SPSS software (version 19, SPSS Inc., Chicago, IL, USA). Statistical significance was defined as a P-value  $<$  0.050.

## Results

In this study, 35 patients were entered, 16 of them were male and 19 were female. Mean age, weight, and height of patients were  $12.06 \pm 4.47$  months (range: 6-14 months),  $8.32 \pm 0.72$  kg (range: 7.5-9.8 kg), and  $64.40 \pm 5.20$  cm (range: 59-71 cm), respectively. In addition, mean sizes of ASD and the selected device were  $10.00 \pm 2.32$  mm (range: 6-13 mm) and  $10.57 \pm 2.57$  mm (range: 7.5-15 mm), respectively. Table 1 shows demographic and characteristic data of the patients.

Furthermore, there was a left to right shunt in all patients. According to the results, closure of ASD was successfully performed for all patients.

Mean weight (kg) to device size (mm) ratio was  $0.85 \pm 0.16$ , which varied from 0.57 to 1.12. In addition, the mean duration of fluoroscopy was  $5.4 \pm 3.7$  minutes (range: 3.7-11.5 minutes) and mean total duration of the procedure was  $33.8 \pm 10.3$  minutes (range: 25-60 minutes). Respiratory rate, heart rate, pulmonary stenosis (PS), and Qp/Qs had significant difference before and after procedure during the follow-up ( $P < 0.001$ ). Blood pressure (systolic and diastolic) and ejection fraction (EF) did not have significant difference before and after procedure (Table 2).

Furthermore, no immediate shunt was observed in 27 patients (77%). In 5 of the patients, no shunt was seen two days after angiography, and no shunt was found in the remaining 3 patients until one month (100%).

**Table 1.** Basic demographic and characteristic data of the patients

Variant	Total (n = 35)	Male (n = 16)	Female (n = 19)
	(mean $\pm$ SD) (minimum-maximum)	(mean $\pm$ SD)	(mean $\pm$ SD)
Age (month)	12.06 $\pm$ 4.47 (6.0-14.0)	11.10 $\pm$ 4.20	13.40 $\pm$ 4.00
Weight (kg)	8.32 $\pm$ 0.72 (7.5-9.8)	8.80 $\pm$ 1.40	8.10 $\pm$ 0.20
Height (cm)	64.40 $\pm$ 5.20 (59.0-71.0)	67.58 $\pm$ 7.20	61.33 $\pm$ 2.70
ASD size (mm)	10.00 $\pm$ 2.32 (6.0-13.0)	10.40 $\pm$ 1.50	10.00 $\pm$ 1.20
PAP (mmHg)			
Systolic	22.90 $\pm$ 7.20 (15.0-30.0)	23.20 $\pm$ 7.10	20.20 $\pm$ 6.10
Diastolic	12.70 $\pm$ 6.10 (8.0-19.0)	14.10 $\pm$ 4.90	12.10 $\pm$ 3.80
Mean PAP (mmHg)	17.70 $\pm$ 4.20 (12.0-23.0)	18.20 $\pm$ 4.80	16.10 $\pm$ 4.50
Fluoroscopy time (minute)	5.40 $\pm$ 3.70 (3.7-11.5)	4.90 $\pm$ 2.10	5.90 $\pm$ 2.70
Total angiography time (minute)	33.80 $\pm$ 10.30 (25.0-60.0)	31.50 $\pm$ 11.60	33.90 $\pm$ 12.90
Size of amplatzer (mm)	10.57 $\pm$ 2.57 (7.5-15.0)	10.60 $\pm$ 3.10	11.40 $\pm$ 2.90

ASD: Atrial septal defect; PAP: Pulmonary artery pressure; SD: Standard deviation

**Table 2.** Mean of study variables before and after procedure

Variable	Before procedure	After procedure	P
	(mean ± SD)	(mean ± SD)	
Blood pressure (mmHg)			
Systolic	92.50 ± 5.40	94.60 ± 6.10	0.350*
Diastolic	72.40 ± 4.90	75.50 ± 5.10	0.360*
Respiratory rate	38.56 ± 1.12	28.90 ± 2.18	< 0.001*
Heart rate	112.90 ± 10.38	92.80 ± 8.30	< 0.001*
PS (mmHg)	25.20 ± 5.26	12.30 ± 2.40	< 0.001*
EF (%)	65.24 ± 8.25	67.36 ± 7.31	0.510*
Qp/Qs	2.52 ± 0.80	1.10 ± 0.10	< 0.001*

\* Based on t-test; PS: Pulmonary stenosis; EF: Ejection fraction; Qp: Pulmonary blood flow; Qs: Systemic blood flow; SD: Standard deviation

Mean duration of follow-up was  $16.66 \pm 6.93$  months (range: 1-29 months) for the patients, during which the growth curve of the patients improved and their weight increased about 10%. None of the patients required hospital readmission, and no delayed bleeding was reported. In 32 patients, delivery system was guided toward LUPV. In 3 patients, the mentioned process was difficult; therefore, delivery system was guided toward RUPV, and the left disc was opened in this PV. During the procedure, 2 patients suffered paroxysmal supraventricular tachycardia (PSVT) attack, which immediately improved without treatment. None of the patients had bleeding and showed signs of hematoma before hospital discharge. Moreover, no acute complications, such as the need for blood transfusion, was observed in the patients, and no femoral vein thrombosis was seen in the patients. One of the patients had seizure about 8 hours after the procedure, which was followed by immediate computed tomography (CT)-scan and magnetic resonance imaging (MRI), showing cerebral thrombosis. Right side hemiparesis was happened in this patient after the seizure and treatment was immediately initiated for the mentioned patient, and the symptoms of the patient were corrected in the next follow-ups. It should be noted that the size of ASD in the patient was large and duration of the procedure was longer, compared to the other patients.

At the beginning of the procedure, one patient had respiratory apnea and bradycardia immediately after receiving anesthesia, which led to postponing of the procedure to the next visit. After two months, the patient underwent angiography one more time and ASD was closed successfully. Device embolism was observed in none of the patients, and there was no sign of delayed arrhythmias or atrioventricular (AV) block in the participants.

## Discussion

Patients with ASD may be asymptomatic in their early years, and the smaller the size of the defect,

the more common it is to experience no symptoms. In patients with larger defects, this disease can be manifested by symptoms, such as HF, recurrent respiratory infections, and/or delayed growth.<sup>17-19</sup> One of the problems of these patients is lack of symptoms of the disease, which leads to the diagnosis of the illness at older ages. Therefore, there would be no long follow-ups before surgical procedures or interventions for these patients. In this regard, the main question is about the speed of increasing of ASD size and the best time to perform therapeutic measures. In a research by McMahan et al., it was reported that the size of ASD increased in 2/3 of patients, which was up to 50% of the primary size in some of the patients.<sup>3</sup> As reported by McMahan et al., the size of the defect increased about 0.8 mm in some patients every year. According to the mentioned researchers, the greater the size of the defect, the higher the increase of its size.<sup>3</sup> Increased age of patients might lead to increased size of the defect, in a way that performing interventional treatments could be difficult. The majority of centers believe that treatment of patients without a sign must be delayed until the age of 4-6 years.<sup>20</sup> However, increased experience of various centers has led to the performing of the relevant procedures at earlier ages. Various reports have been made on ASD closure at ages below 4 years or weights less than 15 kg.<sup>16,21</sup> In a report by Thomas et al., this interventional procedure was performed in children aged below one year. According to the mentioned research, this procedure could be performed in younger patients, in whom increased pulmonary flow would cause pulmonary symptoms and HF.<sup>22</sup> There is a limited number of articles and evaluations on ASD closure at earlier ages and lower weights. In this regard, there is an insufficient experience since arteries and veins are small in these patients and there might be complications during the procedure. In addition, it is still not clear whether this treatment

is necessary and can be beneficial for children or not. While this was our first experience with this type of disease, the present research is of paramount importance due to insufficient experience in this regard. In the current research, we aimed to electively close ASD in patients with body weight less than 10 kg and we had good results in our study and had no major complications.

According to previous studies in which the enlargement of the defect was reported in some of the patients, the mentioned procedure was performed on patients with defects larger than 6 mm and completely sharp defect edges and no flap in the defect, as well as patients with delayed growth and recurrent respiratory infections. Increased age of patients and enlargement of defects in a number of patients could result in the lack of sufficient strength in defect edges to maintain the device, which might be another cause of performing this procedure at earlier ages. We believe that closing of these defects at earlier ages could lead to the use of smaller devices, which can be beneficial for the patient in long term. In addition, the size of the device to septum ratio could be decreased during growth of the patients. Surgical procedures have long-term follow-ups, while non-surgical procedures have no long-term follow-up. In large defects, we have to use a great device, and in the future, these devices may create different problems for our patients; thus we suggest earlier closure of these defects and during the time decreasing of device to septum ratio and complications. Nevertheless, the experience of individuals in performing this procedure is extremely important, and the level of benefits of this process by patients must be taken into consideration.

In our patients, the respiratory rate and heart rate had significant difference before and after the procedure that could decrease patient's energy consumption and help patient's growth increase. It seems that closing of this defect can affect the improved growth of patients and decreased respiratory infections. Due to lack of effect of ASD on the left ventricle, EF had not significant difference during the study.

One important complication was occurrence of cerebral symptoms in a patient, which was improved with treatment. This complication was either due to our procedure or due to the fact that since the patient had a large defect and the right side of the patient was dilated, previous thrombosis on the right side of the heart might have caused embolism and complications.

**Limitations:** In the current research, the duration of follow-up was short, which must be improved in the following studies especially on growth of patients. In addition, the volume of study was low in the present research. Therefore, the future studies must be carried out in multiple centers and on larger patient volumes to more accurately evaluate the related complications and benefits of this technique. Furthermore, there was no time to evaluate the ratio of the size of the device to the septum during the follow-up, which should be taken into consideration in following studies. We had limitation for three-dimensional (3D) echo and in future studies, echo indexes, especially 3D, can be reviewed and reported in the results.

### Conclusion

ASD closure is beneficial for patients with defects larger than 6 mm and with symptoms of delayed growth or recurrent respiratory infections, where there is no hope for self-closure according to clinical evaluations and echocardiography. However, this procedure must be carried out by individuals with sufficient experience in this area.

### Acknowledgments

The authors of this manuscript appreciate all people who helped us in preparation of this study. We have to appreciate officials, head nurse, and nurses of echocardiography room and catheterization laboratory of Chamran and Imam Hossein Hospitals.

This study has been derived from a medical doctorate (MD) dissertation (No. 398067) approved by Isfahan University of Medical Sciences.

### Conflict of Interests

Authors have no conflict of interests.

### References

1. Tanghoj G, Odermarsky M, Naumburg E, Liuba P. Early complications after percutaneous closure of atrial septal defect in infants with procedural weight less than 15 kg. *Pediatr Cardiol* 2017; 38(2): 255-63.
2. Knop M, Szkutnik M, Fiszer R, Bialkowska B, Glowacki J, Bialkowski J. Transcatheter closure of atrial septal defect in children up to 10 kg of body weight with Amplatzer device. *Cardiol J* 2014; 21(3): 279-83.
3. McMahon CJ, Feltes TF, Fraley JK, Bricker JT, Grifka RG, Tortoriello TA, et al. Natural history of growth of secundum atrial septal defects and implications for transcatheter closure. *Heart* 2002; 87(3): 256-9.

4. Cowley CG, Lloyd TR, Bove EL, Gaffney D, Dietrich M, Rocchini AP. Comparison of results of closure of secundum atrial septal defect by surgery versus Amplatzer septal occluder. *Am J Cardiol* 2001; 88(5): 589-91.
5. Feltes TF, Bacha E, Beekman RH 3<sup>rd</sup>, Cheatham JP, Feinstein JA, Gomes AS, et al. Indications for cardiac catheterization and intervention in pediatric cardiac disease: A scientific statement from the American Heart Association. *Circulation* 2011; 123(22): 2607-52.
6. Butera G, De Rosa G, Chessa M, Rosti L, Negura DG, Luciane P, et al. Transcatheter closure of atrial septal defect in young children: Results and follow-up. *J Am Coll Cardiol* 2003; 42(2): 241-5.
7. Chen Q, Cao H, Zhang GC, Chen LW, Xu F, Zhang JX. Short-term and midterm follow-up of transthoracic device closure of atrial septal defect in infants. *Ann Thorac Surg* 2017; 104(4): 1403-9.
8. Wyss Y, Quandt D, Weber R, Stiasny B, Weber B, Knirsch W, et al. Interventional closure of secundum type atrial septal defects in infants less than 10 kilograms: Indications and procedural outcome. *J Interv Cardiol* 2016; 29(6): 646-53.
9. Bishnoi RN, Everett AD, Ringel RE, Owada CY, Holzer RJ, Chisolm JL, et al. Device closure of secundum atrial septal defects in infants weighing less than 8 kg. *Pediatr Cardiol* 2014; 35(7): 1124-31.
10. Petit CJ, Justino H, Pignatelli RH, Crystal MA, Payne WA, Ing FF. Percutaneous atrial septal defect closure in infants and toddlers: Predictors of success. *Pediatr Cardiol* 2013; 34(2): 220-5.
11. Maschietto N, Bonato R, Milanesi O. Is it possible to percutaneously close an atrial septal defect in babies who weigh less than four kilograms? Report of a successful case. *J Cardiovasc Med (Hagerstown)* 2008; 9(9): 929-31.
12. Diab KA, Cao QL, Bacha EA, Hijazi ZM. Device closure of atrial septal defects with the Amplatzer septal occluder: Safety and outcome in infants. *J Thorac Cardiovasc Surg* 2007; 134(4): 960-6.
13. Fraisse A, Losay J, Bourlon F, Agnoletti G, Lusson JR, Godart F, et al. Efficiency of transcatheter closure of atrial septal defects in small and symptomatic children. *Cardiol Young* 2008; 18(3): 343-7.
14. Prada F, Mortera C, Bartrons J, Rissech M, Jimenez L, Carretero J, et al. Percutaneous treatment of atrial septal defects, muscular ventricular septal defects and patent ductus arteriosus in infants under one year of age. *Rev Esp Cardiol* 2009; 62(9): 1050-4.
15. Fischer G, Smevik B, Kramer HH, Bjornstad PG. Catheter-based closure of atrial septal defects in the oval fossa with the Amplatzer device in patients in their first or second year of life. *Catheter Cardiovasc Interv* 2009; 73(7): 949-55.
16. Bartakian S, Fagan TE, Schaffer MS, Darst JR. Device closure of secundum atrial septal defects in children < 15 kg: Complication rates and indications for referral. *JACC Cardiovasc Interv* 2012; 5(11): 1178-84.
17. Geggel RL. Clinical detection of hemodynamically significant isolated secundum atrial septal defect. *J Pediatr* 2017; 190: 261-4.
18. Andrews R, Tulloh R, Magee A, Anderson D. Atrial septal defect with failure to thrive in infancy: Hidden pulmonary vascular disease? *Pediatr Cardiol* 2002; 23(5): 528-30.
19. Lammers A, Hager A, Eicken A, Lange R, Hauser M, Hess J. Need for closure of secundum atrial septal defect in infancy. *J Thorac Cardiovasc Surg* 2005; 129(6): 1353-7.
20. Cardenas L, Panzer J, Boshoff D, Malekzadeh-Milani S, Ovaert C. Transcatheter closure of secundum atrial defect in small children. *Catheter Cardiovasc Interv* 2007; 69(3): 447-52.
21. Chen Q, Chen LW, Cao H, Zhang GC, Chen DZ, Zhang H. Intraoperative device closure of atrial septal defect in infants. *Ann Thorac Surg* 2010; 89(4): 1250-4.
22. Thomas VC, Vincent R, Raviele A, Diehl H, Qian H, Kim D. Transcatheter closure of secundum atrial septal defect in infants less than 12 months of age improves symptoms of chronic lung disease. *Congenit Heart Dis* 2012; 7(3): 204-11.