

## MINI-FOCUS ISSUE: IMAGING

## INTERMEDIATE

## CASE REPORT: CLINICAL CASE

# Resolution of Strain Abnormalities During Extracorporeal Rewarming From Accidental Hypothermic Cardiac Arrest Following Avalanche Burial



Kady Fischer, PhD,<sup>a</sup> Annegret Kauert-Willms, MD,<sup>a</sup> Paul Philipp Heinisch, MD,<sup>b</sup> Alexander Kadner, MD,<sup>b</sup> Hansjörg Jenni, MAS,<sup>b</sup> Balthasar Eberle, MD,<sup>a</sup> Gabor Erdoes, MD, PhD,<sup>a</sup> Dominik P. Guensch, MD<sup>a</sup>

## ABSTRACT

A hypothermic avalanche victim underwent, during extracorporeal warming from asystolic arrest, 3-dimensional transesophageal echocardiography. At 33°C core temperature, left ventricular ejection fraction had recovered, whereas myocardial strain still demonstrated significant dysfunction until 36°C. Deformation analysis seems more sensitive than global assessment during myocardial recovery from hypothermic cardiac arrest. (**Level of Difficulty: Intermediate.**) (J Am Coll Cardiol Case Rep 2021;3:99-103) © 2021 The Authors. Published by Elsevier on behalf of the American College of Cardiology Foundation. This is an open access article under the CC BY-NC-ND license (<http://creativecommons.org/licenses/by-nc-nd/4.0/>).

A 55-year-old male patient suffered an avalanche accident and he was rescued following an estimated 15 min of burial time at a depth of 2 m. After 15 min of lay resuscitation the professional rescue arrived and transferred the

patient under advanced life support measures by helicopter to a level I trauma center. On arrival at the emergency department, the patient was in asystole under ongoing cardiopulmonary resuscitation at 28°C core temperature (hypothermia stage IV). Reperfusion and rewarming were instituted by percutaneously established minimized extracorporeal circulation (ECC), starting 100 min after extraction. Ventricular fibrillation ensued at 32°C and converted to sinus rhythm after 2 defibrillations with 200 J.

## LEARNING OBJECTIVES

- To understand the impact of extracorporeal rewarming on myocardial functional recovery from accidental hypothermic cardiac arrest.
- To recognize the value of analyzing myocardial deformation and its regional heterogeneity in detecting subtle abnormalities beyond global ventricular function.

## PAST MEDICAL HISTORY

This was unknown at admission. The patient was a routine hiker in good physical condition and exercising regularly, with a history of hypertension.

From the <sup>a</sup>Department of Anaesthesiology and Pain Medicine, Inselspital, Bern University Hospital, University of Bern, Bern, Switzerland; and the <sup>b</sup>Department of Cardiovascular Surgery, Inselspital, Bern University Hospital, University of Bern, Bern, Switzerland.

The authors attest they are in compliance with human studies committees and animal welfare regulations of the authors' institutions and Food and Drug Administration guidelines, including patient consent where appropriate. For more information, visit the [Author Center](#).

Manuscript received August 5, 2020; revised manuscript received September 16, 2020, accepted September 23, 2020.

**ABBREVIATIONS  
AND ACRONYMS**

**ECC** = extracorporeal circulation  
**EF** = ejection fraction  
**LV** = left ventricular  
**RV** = right ventricular  
**TEE** = transesophageal echocardiography

**DIFFERENTIAL DIAGNOSIS**

The airway was patent. Differential diagnosis was hypothermia-induced versus hypoxic-asphyctic versus traumatic cardiac arrest.

**INVESTIGATIONS**

During percutaneous cannulation, a transesophageal echocardiography (TEE) probe was inserted for locating guidewire positions (X8-2T probe, EPIC CVx ultrasound system, Philips Medical Systems, Andover, Massachusetts). At a core temperature of 33°C, a full-volume 3-dimensional loop (4 beats) was acquired for each ventricle, and tissue Doppler interrogation was performed for assessment of diastolic function. Images were acquired 141 min after extraction, 41 min after ECC was established. Examinations were repeated at 36°C, 17 min later. A single acquisition was acquired per measurement. Images were analyzed for ventricular function and endocardial strain for all American Heart Association segments using TomTec-Arena version 2.31 (TomTec Imaging Systems, Unterschleissheim, Germany).

At hypothermia at 33°C, left ventricular (LV) ejection fraction (EF; 54%) seemed normal, but global longitudinal strain was impaired (-13.5%) (Table 1). In particular, strain curves exhibited marked regional heterogeneity (Figure 1). Basal myocardial segments showed hypokinesia and dyskinesia, whereas peak strain in more apical segments was hypercontractile (Video 1). Diastolic LV dysfunction was compatible

with a restrictive pattern (grade III). Right ventricular (RV) global longitudinal strain was also impaired (-15.2%) despite an RVEF of 45% (Figure 2).

After normothermia (36°C core temperature) had been reestablished, both LVEF (68%) and strain (longitudinal: -14.5%) had improved, whereas time to peak strain had shortened. Contractile function of LV segments had regained homogeneity among the segments. Diastolic dysfunction had improved to grade II (pseudonormal) (Figure 3). RVEF (74%) and strain (-44.1%) also showed marked increase caused by an enlarged end-diastolic volume.

**MANAGEMENT**

ECC flow was 4.86 l/min at acquisition of images at hypothermia and 4.23 l/min at normothermia. The patient was weaned from mechanical circulatory support after 191 min of extracorporeal perfusion and was transferred to the intensive care unit with normalized cardiac function but on vasopressor agents.

**DISCUSSION**

Accidental hypothermia is frequently caused by environmental exposure, commonly water or alpine incidents, resulting in a core body temperature <35°C (1). Hundreds of people experience avalanche accidents and often more than 100 victims die per season because of avalanches in the European Alps (2), with similar trends observed in other alpine countries. Approximately one-half of fully buried victims survive (3). In case of hemodynamic instability or arrest without lethal injuries, these avalanche victims should be immediately transported to trauma centers for active rewarming, through extracorporeal membrane oxygenation or cardiopulmonary bypass rewarming. Specifically for avalanche victims, pre-hospital factors, such as duration and depth of burial, are key prognosticators for survival (3). Yet, there are reports of severely hypothermic victims who successfully recover from cardiac arrest despite prolonged burial times (4). Thus, focus turns to in-hospital markers.

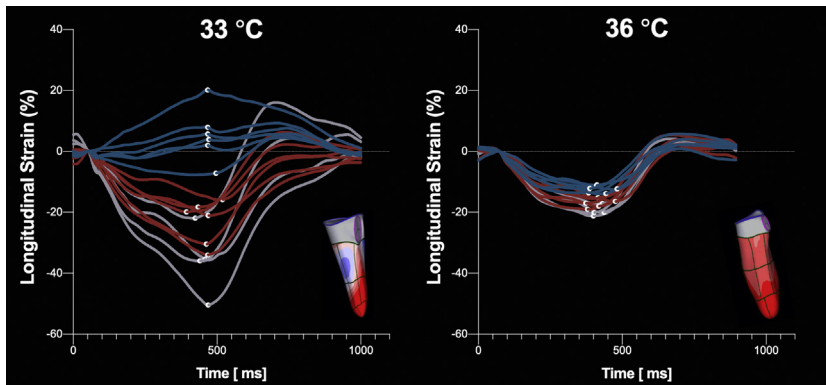
When the patient arrives at the trauma center an interdisciplinary team often uses signs, such as a clinical trauma assessment, core body temperature, serum potassium levels, and imaging of the abdomen, pleural space, and pericardium, to determine the appropriate steps. The Bernese Hypothermia Algorithm details a protocol to facilitate in-hospital decision-making (5). However, there are few reports on the use of advanced cardiac imaging techniques in these patients, which are also not

**TABLE 1 Biventricular Measurements**

	RV		LV	
	33°C	36°C	33°C	36°C
End-diastolic volume (ml)	95	204	44	44
End-systolic volume (ml)	52	54	20	14
Stroke volume (ml)	43	150	24	30
Ejection fraction (%)	45	74	54	68
Fractional area change (%)	32	57		
Heart rate (beats/min)*	52	47	60	53
Septal e' (cm/s)			4	8
Septal E/e'			8.5	7.0
Lateral e' (cm/s)			4	10
Lateral E/e'			8.5	5.6
E/A			2.1	1.8
3D strain				
RV longitudinal (septum, %)	-12.3	-23.9		
RV longitudinal (free wall, %)	-15.2	-44.1		
LV longitudinal (global, %)			-13.5	-14.5
LV time to peak strain (global, ms)			323	286

Transesophageal measurements of the left ventricle (LV) and right ventricle (RV). \*Sequential 3-dimensional (3D) volumetry measurements for the RV and LV, resulting in slightly different heart rates per acquisition.

**FIGURE 1** Left Ventricular 3-Dimensional Longitudinal Strain

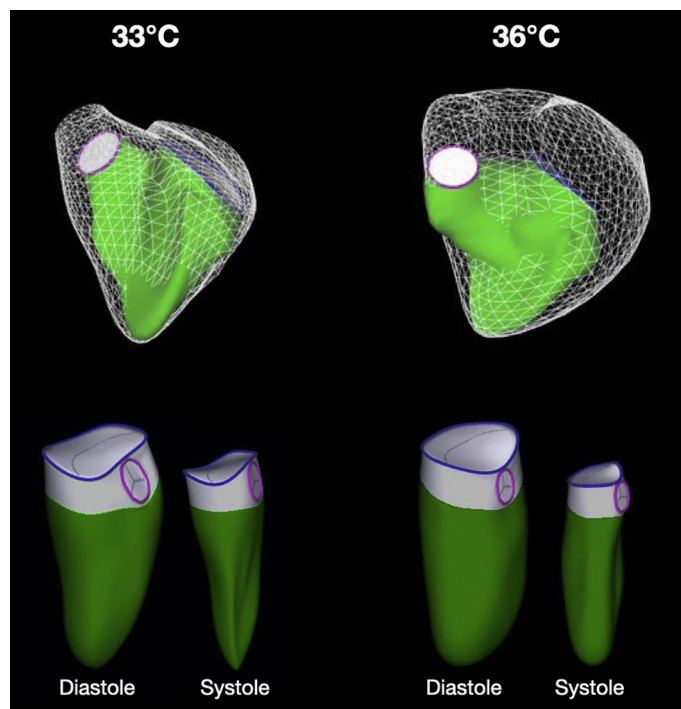


Left ventricular longitudinal strain curves and matching 3-dimensional models demonstrate severely hypokinetic basal segments (**blue curves**) at hypothermia (**left**), whereas mid-ventricular (**red curves**) segments retained contractility and apical (**grey curves**) segments were hypercontractile. Longitudinal strain homogenized with rewarming (**right**).

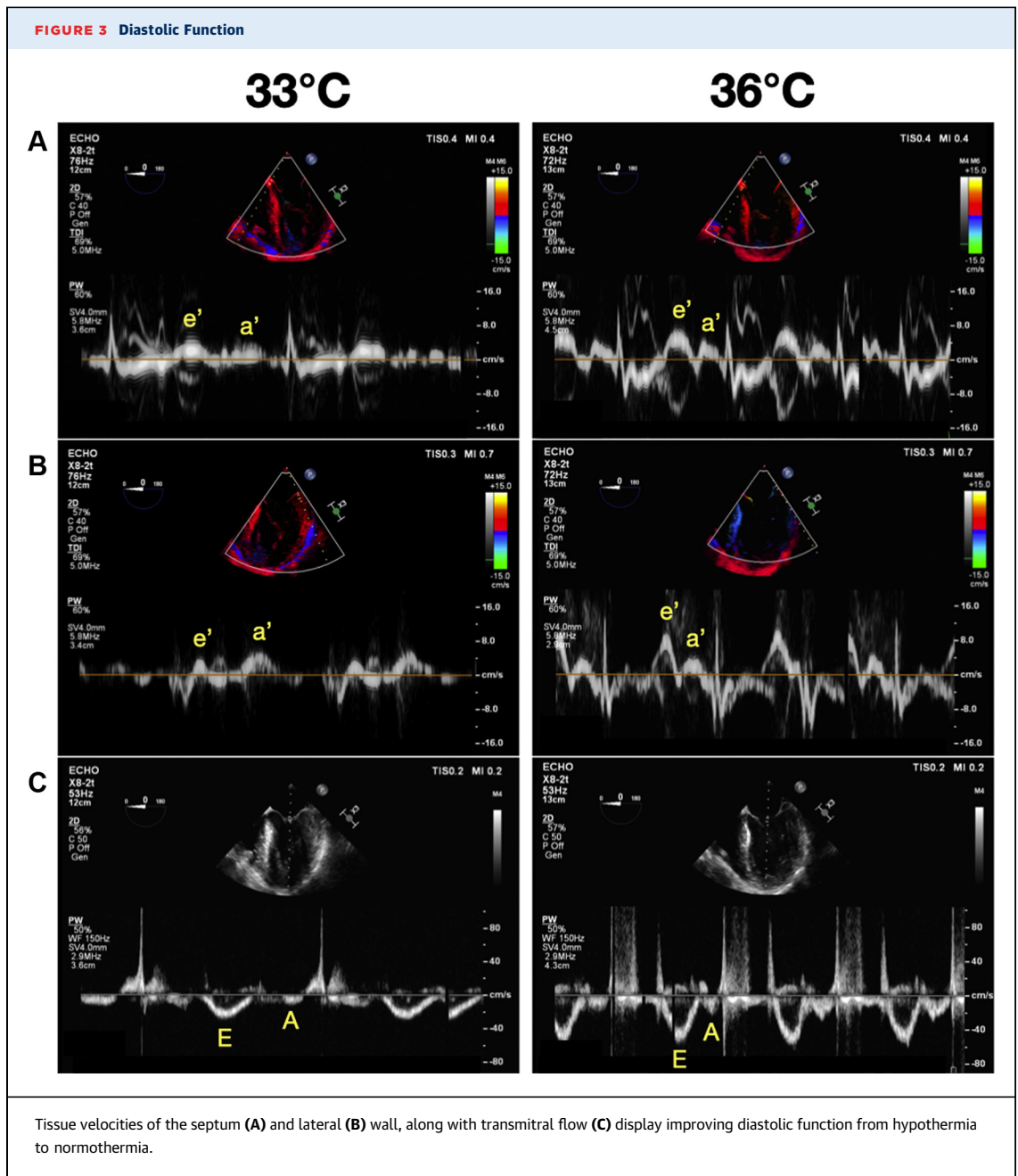
included in current guidelines. TEE is routinely applied in patients on establishment of percutaneous ECC support (e.g., for confirming correct placement of guidewires and cannulae, ruling out cardiac overdistention and aortic valve regurgitation, or assessment of cardiac recovery). Three-dimensional LV and RV assessment overcomes problems of 2-dimensional imaging, such as incomplete coverage and mathematical assumptions of chamber geometry. There have been case reports looking at biventricular function using standard TEE parameters in accidental hypothermia (6). To the best of our knowledge, use of myocardial deformation parameters (e.g. strain) to describe functional recovery of the myocardium from accidental severe hypothermic arrest has not been reported. However, they can be expected to allow earlier detection of subclinical abnormalities and may improve prognostic accuracy compared with standard measurements, such as EF (7).

We demonstrate in this case report that regional variations in myocardial deformation, representing intersegmental heterogeneity, provided valuable detail for assessing recovery from systolic dysfunction. Despite normalized LVEF, global longitudinal peak strain was mildly abnormal at both core temperatures, but slightly improved at normothermia. **Figure 1** demonstrates that strain was severely impaired in basal segments, whereas the apex appeared hypercontractile. This regional dysfunction largely disappeared at normothermia. Similarly, a marked reduction in RV longitudinal strain was observed at hypothermia for both the septum and the

**FIGURE 2** 3-Dimensional Right Ventricular Volumetry



There was a significant increase in end-diastolic volume (**white grid**) of the right ventricle (**top**) with rewarming, resulting in an improvement of ejection. Left ventricular (**bottom**) ejection fraction mildly improved.



free wall, demonstrating that strain analysis was able to detect myocardial dysfunction despite normal RVEF. However, whereas diastolic function improved from grade III to grade II during rewarming, diastolic dysfunction still persisted at 36°C. Accordingly, Darocha et al. (6) reported that in most of their accidentally hypothermic patients, systolic biventricular function normalized following ECC rewarming, whereas diastolic dysfunction persisted in all. In our case the pre-existence of diastolic dysfunction

remains unknown. Myocardial dysfunction is frequently seen in post-cardiac arrest syndrome, which can be related to an inflammatory response. The mild attenuation in shortening of the sub-endocardial fibers remaining at normothermia could indicate such a response in the context of an ischemia-reperfusion injury or persistent myocardial stunning after cardiac arrest. However, ischemia-reperfusion injury is expected to become more pronounced with increasing reperfusion time. Thus, it

does not seem likely that normothermia-related improvement of myocardial function was significantly impacted by ongoing inflammation.

### FOLLOW-UP

---

Several hours after admission to the intensive care unit, multiorgan failure ensued and brain death was diagnosed; however, global systolic ventricular function was preserved. Consent for publication as a case report was obtained from next-of-kin.

### CONCLUSIONS

---

During extracorporeal rewarming at 33°C core temperature, biventricular EF may seem normal, whereas strain analysis reveals severely abnormal myocardial systolic function. Regionally discordant function in a hypothermic post-ischemic heart may

markedly improve when core temperature is normalized. Diastolic function also improved with rewarming. Assessment of diastolic function and 3-dimensional TEE in combination with myocardial strain analysis may be a useful adjunct for evaluating post-arrest recovery of cardiac function in victims of accidental hypothermic cardiac arrest.

### AUTHOR DISCLOSURES

---

All authors have reported that they have no relationships relevant to the contents of this paper to disclose.

---

**ADDRESS FOR CORRESPONDENCE:** Dr. Dominik P. Guensch, Department of Anaesthesiology and Pain Medicine, Bern University Hospital, Inselspital, Freiburgstrasse 10, 3010 Bern, Switzerland. E-mail: [dominik.guensch@gmail.com](mailto:dominik.guensch@gmail.com).

### REFERENCES

1. Mazur P, Kosiński S, Podsiadło P, et al. Extracorporeal membrane oxygenation for accidental deep hypothermia: current challenges and future perspectives. *Ann Cardiothorac Surg* 2019;8:137-42.
2. Techel F, Jarry F, Kronthaler G, et al. Avalanche fatalities in the European Alps: long-term trends and statistics. *Geogr Helv* 2016;71:147-59.
3. Procter E, Strapazzon G, Dal Cappello T, et al. Burial duration, depth and air pocket explain avalanche survival patterns in Austria and Switzerland. *Resuscitation* 2016;105:173-6.
4. Oberhammer R, Beikircher W, Hörmann C, et al. Full recovery of an avalanche victim with profound hypothermia and prolonged cardiac arrest treated by extracorporeal re-warming. *Resuscitation* 2008;76:474-80.
5. Brodmann Maeder M, Martin D, Balthasar E, et al. The Bernese Hypothermia Algorithm: a consensus paper on in-hospital decision-making and treatment of patients in hypothermic cardiac arrest at an alpine level 1 trauma centre. *Injury* 2011;42:539-43.
6. Darocha T, Sobczyk D, Kosiński S, et al. New diastolic cardiomyopathy in patients with severe accidental hypothermia after ECMO rewarming: a case-series observational study. *Cardiovasc Ultrasound* 2015;13:31.
7. Fischer K, Obrist SJ, Erne SA, et al. Feature tracking myocardial strain incrementally improves prognostication in myocarditis beyond traditional CMR imaging features. *J Am Coll Cardiol Img* 2020;13:1891-901.

---

**KEY WORDS** accidental hypothermia, anesthesia, echocardiography, myocardial deformation, speckle tracking, 3-dimensional imaging

---

**APPENDIX** For supplemental videos, please see the online version of this paper.