



Since January 2020 Elsevier has created a COVID-19 resource centre with free information in English and Mandarin on the novel coronavirus COVID-19. The COVID-19 resource centre is hosted on Elsevier Connect, the company's public news and information website.

Elsevier hereby grants permission to make all its COVID-19-related research that is available on the COVID-19 resource centre - including this research content - immediately available in PubMed Central and other publicly funded repositories, such as the WHO COVID database with rights for unrestricted research re-use and analyses in any form or by any means with acknowledgement of the original source. These permissions are granted for free by Elsevier for as long as the COVID-19 resource centre remains active.

## Forum

### SARS-CoV-2-specific neuropathology: fact or fiction?

Anne-Katrin Pröbstel<sup>1,2,\*</sup> and  
Lucas Schirmer<sup>3,4,5,\*</sup>



**Neurological symptoms and varying levels of central nervous system (CNS) immunopathology have been described in COVID-19. Recent reports have suggested an increased level of innate immune activation associated with CNS border areas, as well as with a compartmentalized cytokine response and a dysregulated, autoreactive cerebrospinal fluid (CSF) immune profile. However, it remains contested whether these changes reflect bystander effects of systemic inflammation or relate to CNS-specific viral infection. We summarize some of the key findings pertaining to this ongoing debate and highlight directions for future investigation.**

Over the past year several reports have suggested that a wide range of neurological symptoms are associated with severe acute respiratory syndrome coronavirus 2 (SARS-CoV-2) infection and coronavirus disease 2019 (COVID-19). These potential symptoms include, but are not limited to, loss of smell, fatigue, headaches, anxiety disorders, and cognitive deficits [1]. More recently, persistence of neuropsychiatric symptoms has been associated with a post-COVID-19 syndrome, also known as 'long COVID'. Notably, at least according to some reports, neurological involvement appears to be unrelated to the severity of the respiratory symptoms. Nevertheless, the underlying pathophysiological mechanisms leading to CNS impairment in

COVID-19 remain unclear, posing a therapeutic challenge. It is of crucial importance to disentangle the contributions and routes of CNS infection from cell type-specific immune mechanisms to COVID-19-related neuropathology and neurological sequelae.

We provide an overview and critical evaluation of recent reports related to SARS-CoV-2 neurotropism and potential routes of infection. We discuss recent reports with respect to CNS intrinsic mechanisms of COVID-19-specific pathology and immune activation. The question of how these changes may result in chronic neurological dysfunction as a clinical surrogate of long COVID is currently a matter of intense research and debate.

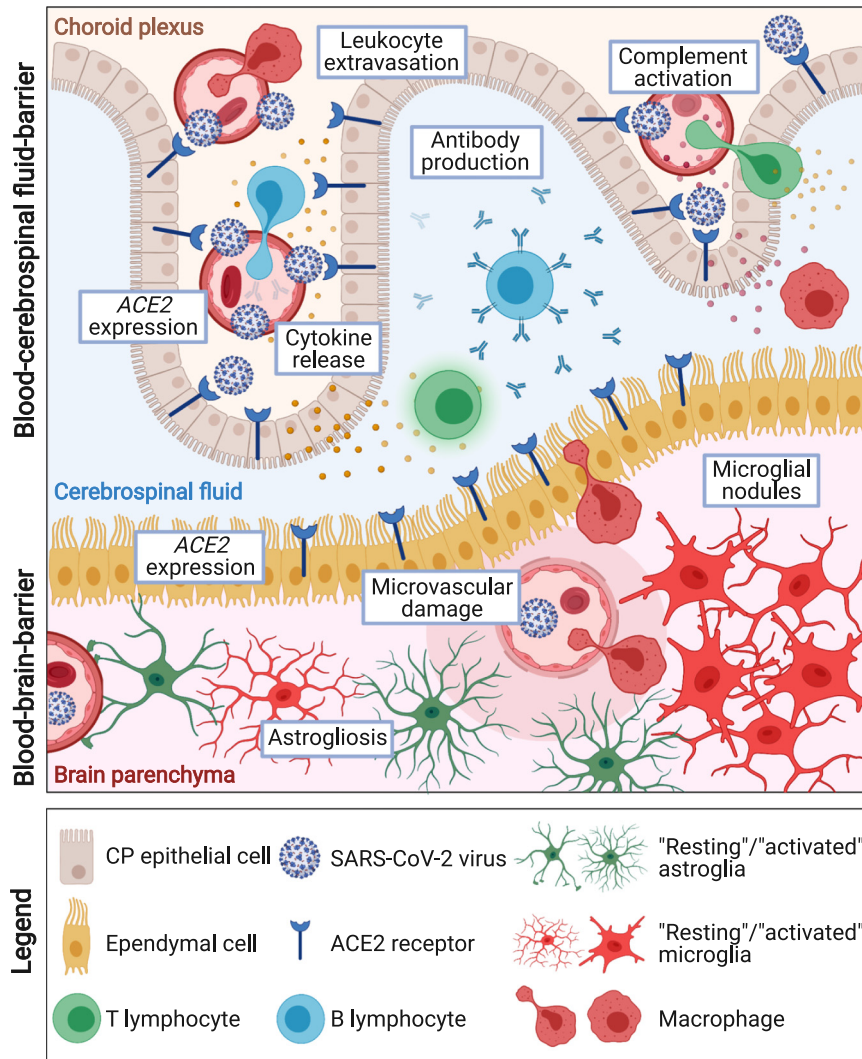
#### **SARS-CoV-2 neurotropism and immune cell activation at the CNS border**

Loss of smell is among the hallmark symptoms of early SARS-CoV-2 infection, and a high viral load has been described in the nasal epithelium. Thus, it is conceivable that the olfactory pathway constitutes an important route of infection. Indeed, several groups have described pathological changes in the olfactory bulb of deceased COVID-19 patients, and were able to amplify virus-specific RNA from along the olfactory tract in postmortem samples [2–4]. Regarding cell type-specificity, several reports found evidence for infection of neuronal and other cell types including sustentacular cells of the olfactory mucosa [3,5,6]. The presence of SARS-CoV-2 in neuroglial cells of the olfactory tract has been demonstrated by qRT-PCR [2–4,6–8] and by cell type-specific assays such as *in situ* hybridization [3,8] and immunohistochemistry [3–5] for virus-specific N (nucleocapsid) [2,4,7,8] and S (spike) [2–5,8] RNA transcripts and proteins. Further, expression of the SARS-CoV-2-specific entry proteins ACE2 [2,3,5] and TMPRSS2 [5] has been described in neuroglial cells along the olfactory pathway.

Other CNS regions and border areas in which SARS-CoV-2-specific virus RNA has been detected are brainstem [2,4,7–10], cranial nerves [4], choroid plexus (CP), and (sub)ependymal regions [2,4,9–11]. Many of these areas are in close vicinity to CSF spaces, suggesting a link between the presence of SARS-CoV-2 in the CSF and brain infection (Figure 1). Notably, studies in brain organoids and postmortem COVID-19 brains have reported the presence of SARS-CoV-2-related transcripts in CP epithelial and ependymal cells of the ventricles [11,12], both of which strongly express *ACE2*, relative to neurons or other glial cell types [10–12]. The CP is a highly vascularized area with an important role in blood–brain barrier (BBB) and blood–CSF barrier function, and is hence a putative entry route and important barrier to SARS-CoV-2 CNS infection. By single-nucleus RNA-sequencing, upregulation of important inflammatory pathway genes such as *IFITM3* (interferon-induced viral defense), *ZFP36* (tumor necrosis factor signaling), and *C7* (membrane attack complex) has been reported in CP cells from COVID-19 patients, consistent with potential SARS-CoV-2 infection of the CP [10]. In summary, CP and ependymal cells are likely to be infected by SARS-CoV-2 in addition to the olfactory mucosa, which demonstrates that different CNS border cell types represent entry points for SARS-CoV-2 virus.

#### **Innate immune activation and COVID-19 brain-specific pathology**

Apart from the question of which CNS cell types are more susceptible to SARS-CoV-2 infection, it is crucial to better understand the extent and chronicity of brain inflammation as a consequence of peripheral infection, and to determine whether concomitant immune activation is key in acute and chronic COVID-19. Over the past year most neuropathological case studies have found evidence for increased innate immune activation related to microglia



**Figure 1.** Current concepts regarding central nervous system (CNS) border pathology underlying neurological symptoms in coronavirus disease 2019 (COVID-19). Both direct infectious pathology and indirect immune-mediated CNS dysfunction are likely to account for the neurological symptoms seen in many COVID-19 patients. Severe acute respiratory syndrome coronavirus 2 (SARS-CoV-2) transcripts and ACE2 expression have been described in border areas of the CNS. In particular, the choroid plexus (CP) and (sub)ependymal regions have been identified as some of the potential CNS entry routes and key viral barriers. Various neuropathological studies have found evidence for microvascular damage and increased innate immune activation related to myeloid cells and astrocytes, accompanied by morphological signs of reactivity and the presence of microglial nodules in brain parenchyma. Cerebrospinal fluid (CSF) findings suggest a specific expansion of dedifferentiated monocytes and exhausted T helper cells, as well as a compartmentalized B and T cell response to CNS antigen, at least in a subset of COVID-19 patients with neurological symptoms. Figure created with [BioRender.com](https://www.biorender.com).

and astrocytes. Specifically, these cell types expanded in numbers and showed morphological signs of reactivity (Figure 1). These signs appeared to be stronger than

in patients who died under similar septic conditions. In particular, COVID-19-related microglia and perivascular macrophages were characterized by activation markers

related to antigen presentation (HLA-DR, CD74) [2,10] and phagocytosis (CD68, CD163) [2,4,8–10], based on conventional immunohistochemistry [2,4,8], cell type-specific *in situ* hybridization [2], and multiplex imaging mass cytometry [9]. Notably, several studies reported the presence of microglial nodules in the inflamed parenchyma of COVID-19 brains, pointing towards a specific compartmentalized feature of innate immune pathology in a subset of cases [8,9]. Further, various studies found little evidence for increased number of T lymphocytes [2,4] in the brain parenchyma of COVID-19 patients, but reported the occasional presence of cytotoxic T cells in the proximity of microglial nodules [8–10]. Although the presence of severe hypoxia and hemorrhagic brain damage due to COVID-19 is contested, there is robust evidence for mild hypoxic/ischemic injury in several grey matter areas across the population of COVID-19 patients [7,8]. In summary, these findings support the hypothesis that, in most if not all cases, COVID-19 neuropathology is not related to massive BBB breakdown, severe vascular pathology, or profound diapedesis of blood-borne immune cells. However, enhanced activation of innate immune cells coupled to the presence of microglial nodules appears to be relatively prevalent, and it seems feasible that these changes could contribute to long-term damage and neuropsychiatric sequelae.

### Compartmentalized immune response and curtailed interferon response in the CSF of COVID-19 patients with neurological symptoms

Mounting evidence further suggests an important role for the adaptive immune response in COVID-19 patients with neurological symptoms. In that regard, a specific expansion of dedifferentiated monocytes and exhausted T helper cells was described in a recent single-cell RNA-sequencing study of COVID-19 CSF [13]. Notably,

comparison of CSF from COVID-19 patients to viral encephalitis patients (from causes other than COVID-19) found lower expression of multiple canonical interferon signaling transcripts across different immune cell types. This was most pronounced in severe COVID-19 cases, suggesting a curtailed interferon response in the CSF [13]. Further, recent data have identified a link between encephalopathy and BBB impairment in COVID-19 patients as a result of peripheral inflammation and/or hypoxia leading to the activation of neurovascular unit cells [14]. Regarding evidence for a compartmentalized CNS immune response, analysis of T cell receptor sequences in the CSF and blood revealed clonal expansion of unique CD4 T cell clones in the CSF that were, however, not shared between COVID-19 patients [13]. Moreover, analysis of CSF B cells and antibody reactivity profiles showed distinct CSF plasma cell clusters in COVID-19 patients compared to controls, as well as a divergent anti-SARS-CoV-2 antibody profile between the CSF and plasma of the same individuals. Lastly, recombinant expression of CSF B cell receptors in COVID-19 individuals yielded reactivity to neural antigens, including crossreactivity between the immunodominant SARS-CoV-2 spike protein and neural tissue, with evidence for intrathecal production of anti-neural autoantibodies [15]. Taken together, these data suggest that there is a compartmentalized B and T cell response to CNS antigen in a subset of patients with neurological symptoms that cannot be solely explained by BBB impairment. However, more work will be necessary to confirm a CSF-specific immune signature in COVID-19 patients.

### Long COVID and chronic neuropathological sequelae in COVID-19

An increasing number of patients with COVID-19 experience prolonged symptoms known as long COVID. Nevertheless,

the mechanisms underlying chronic neurological and psychiatric morbidity in these patients remain largely elusive [1]. It is conceivable that subacute and chronic CNS immune cell activation may contribute to some of the neuropsychiatric symptoms associated with long COVID. In other chronic CNS inflammatory diseases such as multiple sclerosis, it is known that 'smoldering inflammation' is a key driver of disease progression. In particular, sustained activation of microglia and astrocyte subtypes may be crucial for this type of chronic neuroinflammation. An important task for future studies will be to investigate whether similar pathophysiological mechanisms are involved in long COVID.

To conclude, based on current evidence, it seems likely that both direct infectious pathology as well as indirect immune-mediated neural disruption can account for the neurological symptoms seen in COVID-19 patients. Further studies to investigate clinically well-characterized brain tissue and CSF of COVID-19 patients with and without neurological symptoms are warranted. These studies should help to decide whether additional antiviral and/or immunomodulatory therapies may be indicated for select COVID-19 patients with neurological symptoms.

### Acknowledgments

This work was supported by the National Multiple Sclerosis Society (Kathleen C. Moore Fellowship FG-1708-28871 to A.-K.P. and FG-1902-33617 to L.S.), the Swiss National Science Foundation (Eccellenza Professorship PCEFP3\_194609 to A.-K.P.), the Propatient Foundation (pp18-26 to A.-K.P.), the Goldschmidt-Jacobson Foundation (Bench-to-Bed for Top Clinicians to A.-K.P.), intramural funding from the University of Basel (to A.-K.P.) and the Medical Faculty Mannheim of Heidelberg University (to L.S.), research grants from the Hertie Foundation (medMS MyLab P1180016 to L.S.), the European Research Council ("DecOmPress" ERC StG to L.S.), and the German Research Foundation (SCH11330/2-1 to L.S.).

### Declaration of interests

The authors declare no competing interests.

<sup>1</sup>Departments of Neurology and Biomedicine, University Hospital and University of Basel, Basel, Switzerland

<sup>2</sup>Research Center for Clinical Neuroimmunology and Neuroscience Basel (RC2NB), Department of Clinical Research, University Hospital and University of Basel, Basel, Switzerland

<sup>3</sup>Department of Neurology, Medical Faculty Mannheim, Heidelberg University, Mannheim, Germany

<sup>4</sup>Center for Translational Neuroscience and Institute for Innate Immunoscience, Medical Faculty Mannheim, Heidelberg University, Mannheim, Germany

<sup>5</sup>Interdisciplinary Center for Neurosciences, Heidelberg University, Heidelberg, Germany

\*Correspondence:

anne-katrin.proebstel@usb.ch (A.-K. Proebstel) and lucas.schirmer@medma.uni-heidelberg.de (L. Schirmer).

<https://doi.org/10.1016/j.tins.2021.10.006>

© 2021 Elsevier Ltd. All rights reserved.

### References

1. Taquet, M. *et al.* (2021) 6-Month neurological and psychiatric outcomes in 236 379 survivors of COVID-19: a retrospective cohort study using electronic health records. *Lancet Psychiatry* 8, 416–427
2. Deigendesch, N. *et al.* (2020) Correlates of critical illness-related encephalopathy predominate postmortem COVID-19 neuropathology. *Acta Neuropathol.* 140, 583–586
3. Meinhardt, J. *et al.* (2021) Olfactory transmucosal SARS-CoV-2 invasion as a port of central nervous system entry in individuals with COVID-19. *Nat. Neurosci.* 24, 168–175
4. Matschke, J. *et al.* (2020) Neuropathology of patients with COVID-19 in Germany: a post-mortem case series. *Lancet Neurol.* 19, 919–929
5. Cantuti-Castelvetri, L. *et al.* (2020) Neuropilin-1 facilitates SARS-CoV-2 cell entry and infectivity. *Science* 370, 856–860
6. de Melo, G.D. *et al.* (2021) COVID-19-related anosmia is associated with viral persistence and inflammation in human olfactory epithelium and brain infection in hamsters. *Sci. Transl. Med.* 13, eabf8396
7. Solomon, I.H. *et al.* (2020) Neuropathological features of Covid-19. *N. Engl. J. Med.* 383, 989–992
8. Thakur, K.T. *et al.* (2021) COVID-19 neuropathology at Columbia University Irving Medical Center/New York Presbyterian Hospital. *Brain* 144, 2696–2708
9. Schwabenland, M. *et al.* (2021) Deep spatial profiling of human COVID-19 brains reveals neuroinflammation with distinct microanatomical microglia-T cell interactions. *Immunity* 54, 1594–1610
10. Yang, A.C. *et al.* (2021) Dysregulation of brain and choroid plexus cell types in severe COVID-19. *Nature* 595, 565–571
11. Fuchs, V. *et al.* (2021) Presence of SARS-CoV-2 transcripts in the choroid plexus of MS and non-MS patients with COVID-19. *Neurol. Neuroimmunol. Neuroinflamm.* 8, e957
12. Pellegrini, L. *et al.* (2020) SARS-CoV-2 infects the brain choroid plexus and disrupts the blood-CSF barrier in human brain organoids. *Cell Stem Cell* 27, 951–961
13. Heming, M. *et al.* (2020) Neurological manifestations of COVID-19 feature T cell exhaustion and dedifferentiated monocytes in cerebrospinal fluid. *Immunity* 54, 164–175
14. Bernard-Valnet, R. *et al.* (2021) Encephalopathies associated with severe COVID-19 present neurovascular unit alterations without evidence for strong neuroinflammation. *Neurol. Neuroimmunol. Neuroinflamm.* 8, e1029
15. Song, E. *et al.* (2021) Divergent and self-reactive immune responses in the CNS of COVID-19 patients with neurological symptoms. *Cell Rep. Med.* 2, 100288