

Whole-Heart 4D Flow MRI for Evaluation of Normal and Regurgitant Valvular Flow: A Quantitative Comparison Between Pseudo-Spiral Sampling and EPI Readout

Carmen P.S. Blanken, MS,¹  Lukas M. Gottwald, PhD,¹

Jos J.M. Westenberg, PhD,²  Eva S. Peper, PhD,¹ Bram F. Coolen, PhD,³

Gustav J. Strijkers, PhD,³ Aart J. Nederveen, PhD,¹ R. Nils Planken, MD, PhD,¹ and

Pim van Ooij, PhD^{1*}

Background: Pseudo-spiral Cartesian sampling with compressed sensing reconstruction has facilitated highly accelerated 4D flow magnetic resonance imaging (MRI) in various cardiovascular structures. However, unlike echo planar imaging (EPI)-accelerated 4D flow MRI, it has not been validated in whole-heart applications.

Hypothesis: Pseudo-spiral 4D flow MRI (PROUD [PROspective Undersampling in multiple Dimensions]) is comparable to EPI in robustness of valvular flow measurements and remains comparable as the undersampling factor is increased and scan time reduced.

Study Type: Prospective.

Population: Twelve healthy subjects and eight patients with valvular regurgitation.

Field Strength/Sequence: 3.0 T; PROUD and EPI 4D flow sequences, 2D flow and balanced steady-state free precession sequences.

Assessment: Valvular blood flow was quantified using valve tracking. PROUD- and EPI-based measurements of aortic (AV) and pulmonary (PV) flow volumes and left and right ventricular stroke volumes were tested for agreement with 2D MRI-based measurements. PROUD reconstructions with undersampling factors (R) of 9, 14, 28, and 56 were tested for interval consistency (per valve, compared to the other valves) and preservation of peak velocities and E/A ratios.

Statistical Tests: We used repeated measures ANOVA, Bland-Altman, Wilcoxon signed rank, and intraclass correlation coefficients. $P < 0.05$ was considered statistically significant.

Results: PROUD and EPI interval consistencies were not significantly different both in healthy subjects (valve-averaged mean difference [limits of agreement width]: 3.2 ± 0.8 [8.7 ± 1.1] mL/beat for PROUD, 5.5 ± 2.9 [13.7 ± 2.3] mL/beat for EPI, $P = 0.07$) and in patients with valvular regurgitation (2.3 ± 1.2 [15.3 ± 5.9] mL/beat for PROUD, 0.6 ± 0.6 [19.3 ± 2.9] mL/beat for EPI, $P = 0.47$). Agreement between EPI and PROUD was higher than between 4D flow (EPI or PROUD) and 2D MRI for forward flow, stroke volumes, and regurgitant volumes. Up to $R = 28$ in healthy subjects and $R = 14$ in patients with valvular regurgitation, PROUD interval consistency remained comparable to that of EPI. Peak velocities and E/A ratios were preserved up to $R = 9$.

Conclusion: PROUD is comparable to EPI in terms of interval consistency and may be used with higher undersampling factors to shorten scan times further.

Level of Evidence: 1

Technical Efficacy Stage: 2

J. MAGN. RESON. IMAGING 2022;55:1120–1130.

View this article online at [wileyonlinelibrary.com](https://onlinelibrary.wiley.com/doi/10.1002/jmri.27905). DOI: 10.1002/jmri.27905

Received Jun 25, 2021, Accepted for publication Aug 19, 2021.

*P.v.O., Meibergdreef 9, 1105 AZ Amsterdam, The Netherlands. E-mail: p.vanooij@amsterdamumc.nl

From the ¹Department of Radiology and Nuclear Medicine, Amsterdam UMC, Location AMC, Amsterdam, The Netherlands; ²Department of Radiology, Leiden UMC, Leiden, The Netherlands; and ³Department of Biomedical Engineering and Physics, Amsterdam UMC, Location AMC, Amsterdam, The Netherlands

Additional supporting information may be found in the online version of this article

This is an open access article under the terms of the Creative Commons Attribution-NonCommercial License, which permits use, distribution and reproduction in any medium, provided the original work is properly cited and is not used for commercial purposes.

Introduction

4D flow MRI facilitates detailed evaluation of cardiac hemodynamics in various types of heart disease.^{1,2} Whole-heart coverage is desirable for the assessment of diseases that affect the blood flow not just locally but throughout the heart, such as repaired transposition of the great arteries, repaired tetralogy of Fallot, and multiple or complex valvular heart disease. In this context, whole-heart 4D flow MRI has been used for the identification of helical and vortical flow patterns, increased flow velocities, regions of elevated wall shear stress, and valvular regurgitation.^{3–9}

Advanced acquisition strategies have enabled whole-heart coverage at scan times of ~ 10 minutes,^{7,9,10} such that the acquisition can be performed in addition to existing clinical protocols. A recently introduced pseudo-spiral Cartesian sampling strategy with random undersampling in time and compressed sensing (CS) reconstruction has facilitated accurate and repeatable 4D flow MRI in the aorta, carotid arteries, and intracranial arteries.^{11–13} This technique allows for artifact-free image recovery up to high undersampling factors by exploiting image sparsity. Undersampling factors of 8 (aorta) to 30 (intracranial) have been achieved while maintaining good agreement in flow measurements with other accelerated 4D flow MRI techniques and 2D flow MRI measurements. These results encouraged us to investigate the application of pseudo-spiral sampling 4D flow MRI in a whole-heart setting.

To assess the robustness of intracardiac flow measurements, quantification of forward and regurgitant flow volumes across the heart valves can be performed using retrospective valve tracking. Various studies have demonstrated that this analysis technique has good interobserver agreement.^{8,9,14,15} These studies used an echo planar imaging (EPI) readout acquisition technique which has demonstrated good interval consistency of flow measurements and superiority to 4D segmented spoiled gradient echo and 4D k-t BLAST in terms of image quality and accuracy of intracardiac flow and velocity measurements.^{8–10} Hence, we deemed EPI-accelerated whole-heart 4D flow MRI a meaningful reference technique for the interpretation of interval consistency results of pseudo-spiral sampling whole-heart 4D flow MRI.

Thus, the aim of this study was to investigate the performance of pseudo-spiral Cartesian whole-heart 4D flow MRI in healthy subjects and patients with valvular regurgitation and to compare its performance to that of a clinically used EPI readout strategy¹⁴ based on blood flow measurements across the heart valves. Specifically, the aim was to assess interval consistency and agreement with 2D MRI-based measurements. A further aim was to investigate the possibility of shortening the scan time further by increasing the undersampling factor.^{16,17}

Materials and Methods

All healthy subjects gave written informed consent. The requirement for written informed consent from the patients was waived by our

local medical ethical committee, as the study served as protocol validation and the data were fully anonymized.

Study Population and Data Acquisition

Twelve healthy subjects (aged 25 ± 3 years, seven females) and eight patients with valvular regurgitation (aged 39 ± 18 years, three females) underwent cardiac MRI at 3.0 T (Philips Ingenia) including two whole-heart 4D flow MRI acquisitions in the same examination: 1) EPI readout 4D flow MRI and 2) pseudo-spiral Cartesian sampling 4D flow MRI with random undersampling in time and CS reconstruction aided by total variation regularization in time. The pseudo-spiral sampling results in incoherently sampled k-space in time, making it suitable for CS reconstruction. To enable pseudo-spiral ky/kz-plane acquisition, the scanner was equipped with an in-house developed software modification called “PROspective Undersampling in multiple Dimensions (PROUD).”^{11,12} We will therefore refer to the pseudo-spiral acquisitions as PROUD 4D flow scans.

The healthy subjects were prospectively scanned from October to December 2018. Patient scans were collected consecutively from August to October 2020. All patients received PROUD 4D flow MRI as part of their routine clinical MRI examination and had moderate to severe valvular regurgitation as diagnosed by semiquantitative echocardiography, and no intracardiac shunting. EPI 4D flow MRI was prospectively added to the clinical protocol for comparison. Apart from the two 4D flow MRI sequences, cine balanced steady-state free precession (bSSFP) MRI was acquired (two-chamber [2CH] left and right, three-chamber, four-chamber [4CH], coronal aorta view, and sagittal and coronal pulmonary view). In patients with valvular regurgitation, 2D flow MRI was acquired at the aortic (AV) and the pulmonary valve (PV) at a spatial resolution of $1.2 \times 1.2 \times 8.0 \text{ mm}^3$ in 40 cardiac phases.

EPI and PROUD 4D flow data were acquired in 30 cardiac phases during free-breathing with retrospective electrocardiographic (ECG) gating. Acquired and reconstructed spatial resolutions were $3.0 \times 3.0 \times 3.0$ and $2.8 \times 2.8 \times 3.0 \text{ mm}^3$ in healthy subjects, and $2.5 \times 2.5 \times 2.5$ and $2.4 \times 2.4 \times 2.5 \text{ mm}^3$ in patients (higher than in the healthy subjects to better capture complex hemodynamics in pathological areas). Three-directional velocity-encoding sensitivity (VENC) was set to 150 cm/second in healthy subjects and 150–300 cm/second in patients, depending on the presence of velocity aliasing in 2D flow MRI scout images.

EPI 4D flow MRI was acquired with a flip angle of 10° and echo time/repetition time (TE/TR) of 4.8/8.7 msec in the healthy subject scans and 4.3–5.4/8.1–10.0 msec in the patient scans. EPI temporal resolutions were 30.9 (interquartile range [IQR]: 26.6, 35.1) msec in the healthy subjects and 30.8 (IQR: 27.1, 33.4) msec in the patients. The EPI factor was set to 5 and a SENSE factor of 2 was used.

In the PROUD scans, the flip angle was set to 8° and TE/TR were 3.0/5.1 msec in the healthy subject scans and 1.9–2.6/3.8–4.0 msec in the patient scans. PROUD temporal resolutions were 31.6 (IQR: 27.0, 36.6) msec in the healthy subjects and 31.3 (IQR: 27.2, 32.9) msec in the patients. In the healthy subjects, the PROUD undersampling factor ranged from 5.6 to 8.2 to achieve equal scan times for both 4D flow scans ($9:20 \pm 1:04$ minutes). The difference in acceleration factors between EPI and PROUD was

needed because of different phase-encoding directions: right–left for EPI—to minimize respiration-induced intravoxel phase dispersion artifacts—and anterior–posterior for PROUD. Furthermore, the scan time depended on the subject’s heart rate during the EPI scan. The patients were scanned with a fixed PROUD undersampling factor of 7 to adhere to the standard clinical protocol, and the field-of-view (FOV) of the EPI scan was cropped in the craniocaudal dimension to achieve equal scan times ($9:00 \pm 1:10$ minutes).

PROUD-accelerated 4D flow scans were reconstructed offline using ReconFrame (Gyrotools) and the Berkeley Advanced Reconstruction Toolbox (BART).⁵ A sparsifying total variation transform in time was used with a regularization parameter (r) of 0.001 and 20 iteration steps, as previously described.^{11,12}

Reconstructed 4D flow MRI datasets were inspected for velocity aliasing in the phase images, and, if needed, unwrapped by a 4D single-step Laplacian algorithm.¹⁸

In all PROUD scans, additional reconstructions of the first 75%, 50%, 25%, and 12.5% of the acquired data were made. These will be referred by the corresponding undersampling factors (R) of 9, 14, 28, and 56, respectively. The temporal resolutions of these additional reconstructions were similar to those of the original ($R = 7$) reconstructions.

Data Analysis

Data were analyzed by C.P.S.B., who had 3.5 years of experience in cardiac 4D flow MRI analysis.

4D FLOW MRI. Blood flow across the AV, PV, mitral (MV), and tricuspid valve (TV) was quantified using semiautomated retrospective valve tracking including automatic phase offset correction in CAAS MR Solutions 5v1 – 4D Flow (Pie Medical Imaging BV). Valve tracking was performed on 2D cine bSSFP images as previously described.¹⁵ The AV was tracked on a sagittal and coronal cine view of the aortic root, and the PV was tracked on a sagittal and coronal cine view of the pulmonary root. The MV and TV were both tracked on a 2CH (left-sided or right-sided) and 4CH cine view. 4D flow MRI velocity data were superimposed on the moving valve tracking planes, and these color-coded images were used to contour the flow area in every cardiac phase. The EPI and PROUD datasets were analyzed based on the same valve tracking planes, but separately defined contours. The blood flow was quantified in milliliters per heartbeat, corrected for through-plane valve motion. Streamlines, originating from within the measurement contours, provided 3D visualization of measured blood flow patterns over time. Regurgitant volumes were quantified using semiautomated flow tracking, as previously described.¹⁵ PROUD 4D flow reconstructions with different undersampling factors were analyzed by loading these into the existing valve tracking analyses and modifying the measurement contours where needed.

Left ventricular stroke volume (LVSV) was determined by summing AV forward flow volume and MV regurgitant volume. Right ventricular stroke volume (RVSV) was determined by summing PV forward flow volume and TV regurgitant volume. Peak velocities across the AV and PV and early diastole/atrial contraction (E/A) ratios across the MV and TV were determined based on time-resolved peak velocity curves.

Image quality in terms of signal-to-noise ratio (SNR) and lung–liver edge (LLE) width was assessed across an $8 \times 8 \times 30$ (RL \times AP \times FH) voxel region of interest containing the lung–liver interface at the highest point of the liver, as previously described.¹⁹ In short, SNR was determined by measuring the time-averaged mean signal intensity in an 8×8 -voxel slice in the liver and dividing this by the time-averaged standard deviation of the noise in an 8×8 -voxel slice in the lung. LLE width was determined by fitting a sigmoid function to all (64) line profiles between the liver and lung slice.

2D MRI. 2D flow MRI-based blood flow quantification was performed in CAAS MR Solutions 5v1 – 2D Flow with semiautomated contour definition around the flow regions of interest. Contours were manually modified where needed.

LVSV and RVSV were quantified in CAAS MR Solutions 5v1 – MRV from short-axis bSSFP images in a semiautomated manner: upon marking end-systolic and end-diastolic time frames, endocardial contours were automatically generated. These were manually adapted where needed. Apex-to-base volume correction was performed based on manual delineation of the endocardial border on 2CH and 4CH cine views. All LVSV and RVSV measurements were checked by a radiologist (R.N.P.) with 13 years of experience in cardiac MRI.

A combination of 2D short-axis bSSFP MRI and 2D flow MRI was used to quantify MV and TV regurgitant volumes ($Rvol_{MV} = LVSV - AV$ forward flow volume, $Rvol_{TV} = RVSV - PV$ forward flow volume. AV and PV regurgitant volumes were quantified directly from 2D flow MRI.

Statistical Analysis

Statistical testing was performed in SPSS Statistics (version 26; IBM). Valve tracking-based net flows were tested for normality using Shapiro–Wilk tests. Interval differences in net flow were identified using repeated measures ANOVA. A P -value of <0.05 was considered statistically significant. For each valve, net flow measurements were compared with the average measurement over the other three valves, and Bland–Altman analysis was performed. Mean difference, 95% limits of agreement (LOA), and coefficient of variation (CV) were calculated. Bland–Altman analysis was used to evaluate interval and intertechnique (4D flow vs. 2D flow, and PROUD 4D flow vs. EPI 4D flow) means and differences of measured flow volumes. The Wilcoxon signed-rank test was used to compare interval consistencies between PROUD and EPI. Net flow volumes, E/A ratios, and peak velocity measurements were compared between the increasingly undersampled reconstructions and the original reconstruction using Bland–Altman analysis and intraclass correlation coefficients (ICC). ICC was determined based on absolute agreement and a two-way mixed-effects model. ICC was classified as: poor (<0.5), moderate (0.5–0.75), good (0.75–0.9), and excellent (>0.9).²⁰ A Student’s t -test was used to compare SNR and LLE width—averaged over all subjects—between EPI and PROUD, and between the PROUD $R = 7$ reconstruction and $R = 9, 14, 28,$ and 56 reconstructions.

Results

Demographics and clinical information on the patient cohort are listed in Table S1 in the Supplemental Material.

An example of an EPI and PROUD streamline visualization in a healthy subject, obtained by means of semiautomated retrospective valve tracking, is shown in Fig. 1. This example is representative of a trend we observed in the healthy subject cohort. In the example, measured flow volumes are overall lower for PROUD (86.4 \pm 4.2 mL/beat) than for EPI (97.1 \pm 5.7 mL/beat, $P = 0.05$). Furthermore, in the EPI acquisition, the flow volume measured across the TV is somewhat higher than across the other valves, whereas in the PROUD acquisition, the flow volume across the MV is somewhat lower than across the other valves. Figure 2 shows streamline visualizations in four different patients in whom valvular regurgitation was quantified. These examples reflect our overall findings of slightly lower regurgitant volume measurements by EPI (34.0 \pm 17.6 mL/beat) than by PROUD (39.2 \pm 20.1 mL/beat, $P = 0.10$). Valve tracking-based measurements of net flow across the heart valves have been summarized in Fig. 3. Group-averaged flow curves can

be found in Fig. S1 in the Supplemental Material. In the healthy subject group, significant differences were found between EPI-based measurements of AV and TV net flow, and between PROUD-based measurements of PV and MV net flow. In the patient group, no statistically significant measurement differences were found ($P = 1.00$ for all valve combinations). Interval consistency analysis of net flow measurements revealed nonsignificant differences between PROUD and EPI in terms of CVs, both in healthy subjects ($P = 0.07$) and in patients with valvular regurgitation ($P = 0.47$; Table 1). Comparing PV and AV forward flow quantification by 4D flow with 2D flow measurements, PROUD and EPI had similar mean differences and LOA (Fig. 4). In the RVSV measurements, PROUD demonstrated slightly better agreement with 2D MRI than did EPI (Fig. 4). Variability between 4D flow MRI- (EPI or PROUD) and 2D MRI-based LVSV measurements was relatively large, both in terms of mean differences and LOA

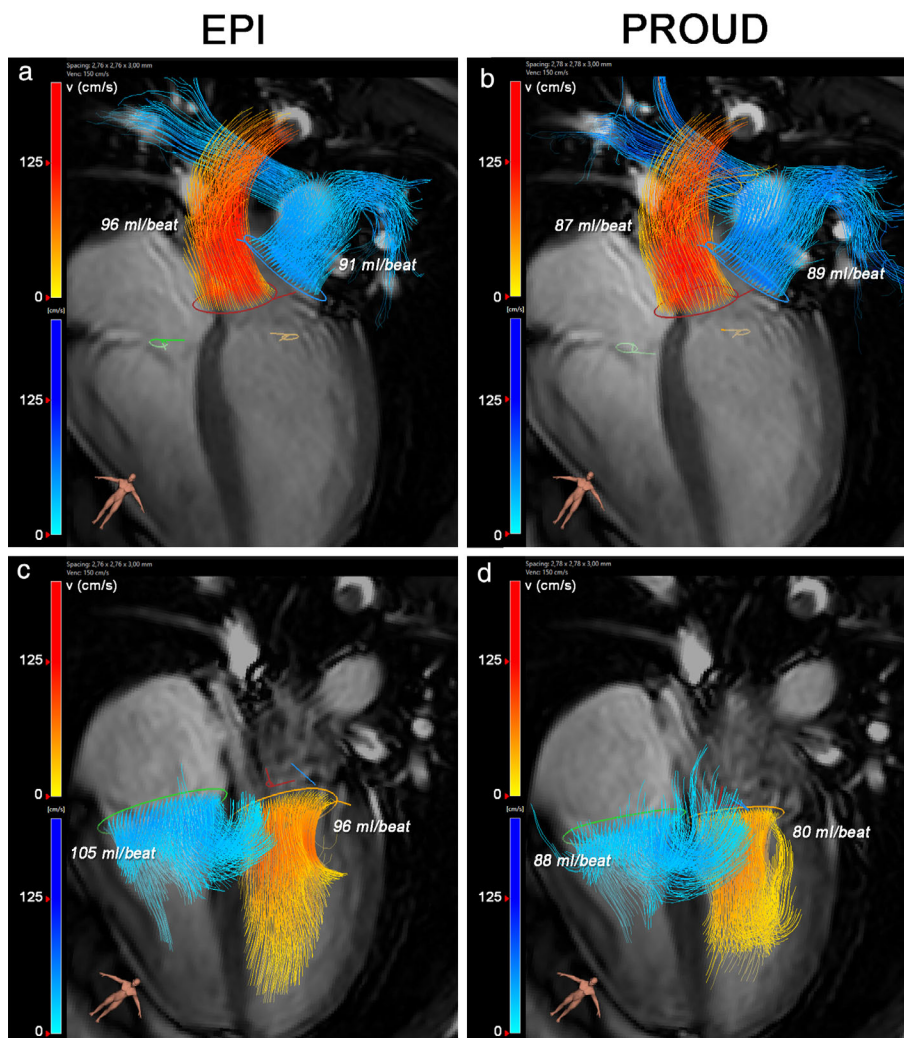


FIGURE 1: EPI and PROUD 4D flow MRI streamline visualizations of blood flow through the aortic valve (a, b, orange), pulmonary valve (a, b, blue), mitral valve (c, d, orange), and tricuspid valve (c, d, blue) in a 31-year-old healthy subject, resulting from semiautomated retrospective valve tracking. Measured flow volumes across the valves are listed in the figure. Valve tracking was performed on bSSFP cine images on two orthogonal views for each heart valve. Four-chamber bSSFP view is visible in the background.

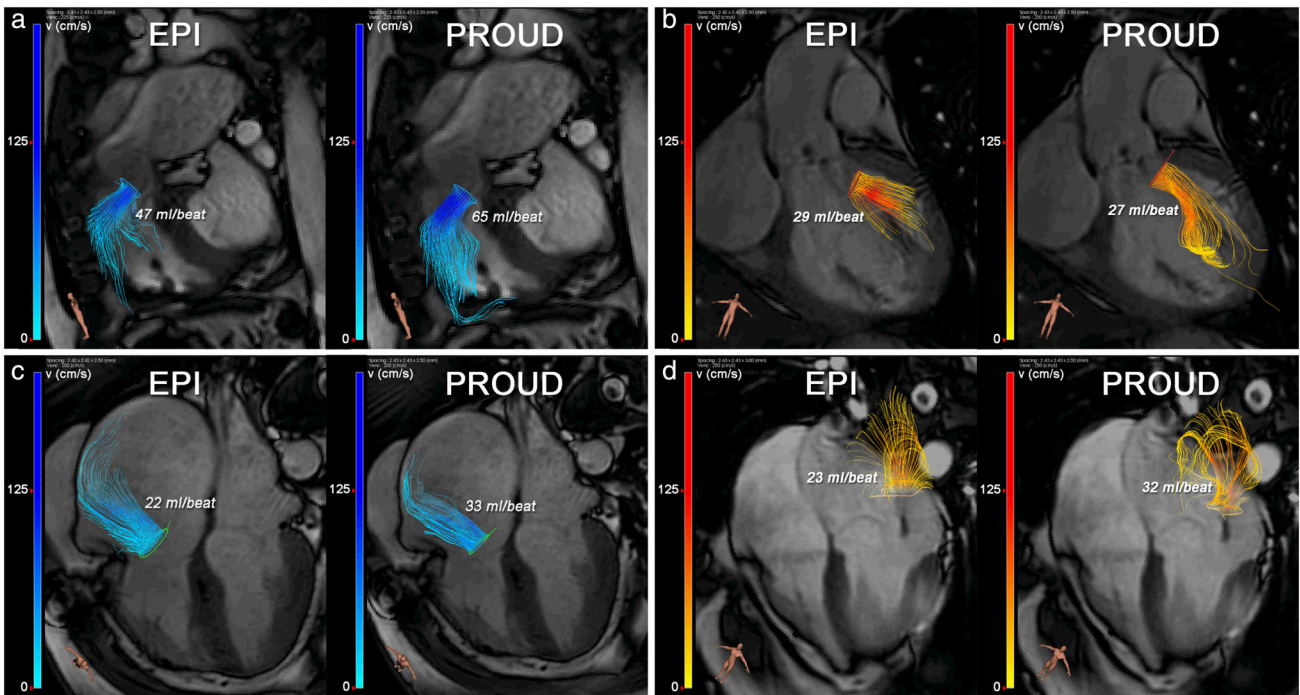


FIGURE 2: EPI and PROUD 4D flow MRI streamline visualizations in four different patients with (a) pulmonary valve regurgitation, (b) aortic valve regurgitation, (c) tricuspid valve regurgitation, and (d) mitral valve regurgitation. Semiautomated retrospective valve tracking was performed on bSSFP cine images on two orthogonal views for each heart valve.

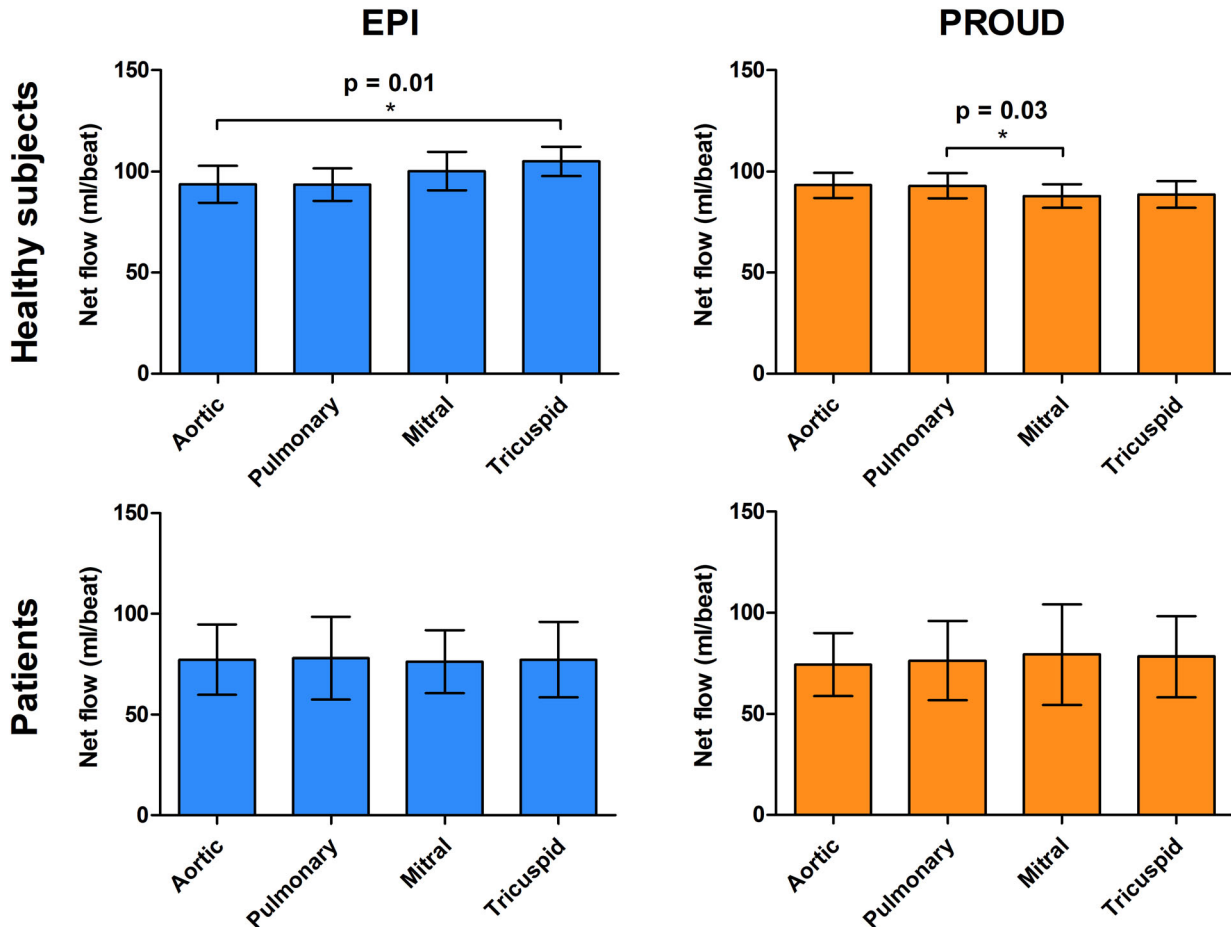


FIGURE 3: Measured net flow per heart valve resulting from valve tracking-based blood flow quantification from EPI (left) and PROUD (right) 4D flow MRI acquisitions in 12 healthy subjects (top) and 8 patients with valvular regurgitation (bottom).

TABLE 1. Bland–Altman Parameters of Interval Consistency in Healthy Subjects (Top) and Patients (Bottom), Resulting from Valve Tracking-Based Blood Flow Quantification from EPI (Left) and PROUD (Right) 4D Flow MRI Acquisitions

	EPI-Based Net Flow Volume			PROUD-Based Net Flow Volume		
	Mean Difference (mL/Beat)	LOA Width (mL/Beat)	CV (%)	Mean Difference (mL/Beat)	LOA Width (mL/Beat)	CV (%)
Healthy subjects						
AV vs. PV/MV/TV	−6.6	11.4	6.1	2.7	7.5	4.2
PV vs. AV/MV/TV	−4.5	14.8	7.9	3.7	8.2	4.6
MV vs. AV/PV/TV	2.2	12.3	6.4	−4.1	8.9	5.1
TV vs. AV/PV/MV	8.9	16.4	8.4	−2.3	10.1	5.7
Mean ± SD of absolute values	5.5 ± 2.9	13.7 ± 2.3	7.2 ± 1.1	3.2 ± 0.8	8.7 ± 1.1	4.9 ± 0.7
			R = 9	1.9 ± 0.8	8.6 ± 1.6	4.8 ± 0.9
			R = 14	1.9 ± 1.8	8.2 ± 1.9	4.6 ± 1.1
			R = 28	5.3 ± 1.1	13.7 ± 4.3	7.5 ± 2.3
			R = 56	6.9 ± 6.3	32.8 ± 10.2	16.6 ± 5.1
Patients						
AV vs. PV/MV/TV	0.0	15.4	10.2	−3.6	18.8	12.6
PV vs. AV/MV/TV	1.1	21.0	13.8	−1.0	13.6	9.0
MV vs. AV/PV/TV	−1.2	19.0	12.6	2.9	21.0	13.8
TV vs. AV/PV/MV	0.1	22.0	14.5	1.7	7.8	5.2
Mean ± SD of absolute values	0.6 ± 0.6	19.3 ± 2.9	12.8 ± 1.9	2.3 ± 1.2	15.3 ± 5.9	10.2 ± 3.9
			R = 9	3.6 ± 2.2	19.7 ± 7.4	13.1 ± 5.1
			R = 14	2.9 ± 2.5	20.7 ± 9.9	13.8 ± 6.7
			R = 28	2.2 ± 1.7	22.2 ± 3.6	14.6 ± 2.5
			R = 56	4.3 ± 1.4	42.9 ± 11.0	30.0 ± 8.1

(Fig. 4). Mean differences and LOA between the two 4D flow techniques (Fig. 5) were smaller than between 4D flow MRI (EPI or PROUD) and 2D MRI for all forward flow and stroke volume measurements (Fig. 4). Likewise, regurgitant volume measurements demonstrated better agreement between the 4D flow techniques than between 4D flow and 2D MRI (Fig. 6).

Net flow measurements obtained from the increasingly undersampled PROUD reconstructions demonstrated good agreement with the original reconstruction up to an undersampling factor of 14; mean differences were small and the CV did not exceed 10% (Fig. 7). The interval consistency remained unaffected in the healthy subject group up to this undersampling factor of 14, and comparable to that of the EPI acquisition up to an undersampling factor of 28 (Table 1). In the patient

group, the interval consistency remained comparable to that of EPI up to $R = 14$. Valve-specific interval consistency parameters can be found in Table S2 in the Supplemental Material. Preservation of peak velocities was excellent in the $R = 9$ reconstructions (ICC PV/ICC AV = 0.94/0.96 [healthy subjects], 0.98/0.90 [patients]), and moderate to excellent in the $R = 14$ reconstructions (ICC PV/ICC AV = 0.87/0.95 [healthy subjects], 0.94/0.71 [patients]) (Fig. 8). Preservation of E/A ratios was good to excellent in the $R = 9$ reconstructions (ICC TV/ICC MV = 0.95/0.81 [healthy subjects], 0.93/0.86 [patients]), and moderate to good in the $R = 14$ reconstructions (ICC TV/ICC MV = 0.82/0.58 [healthy subjects], 0.78/0.68 [patients]) (Fig. 9).

In four patients, image quality analysis was not possible because the FOV did not contain the liver dome. In the remaining

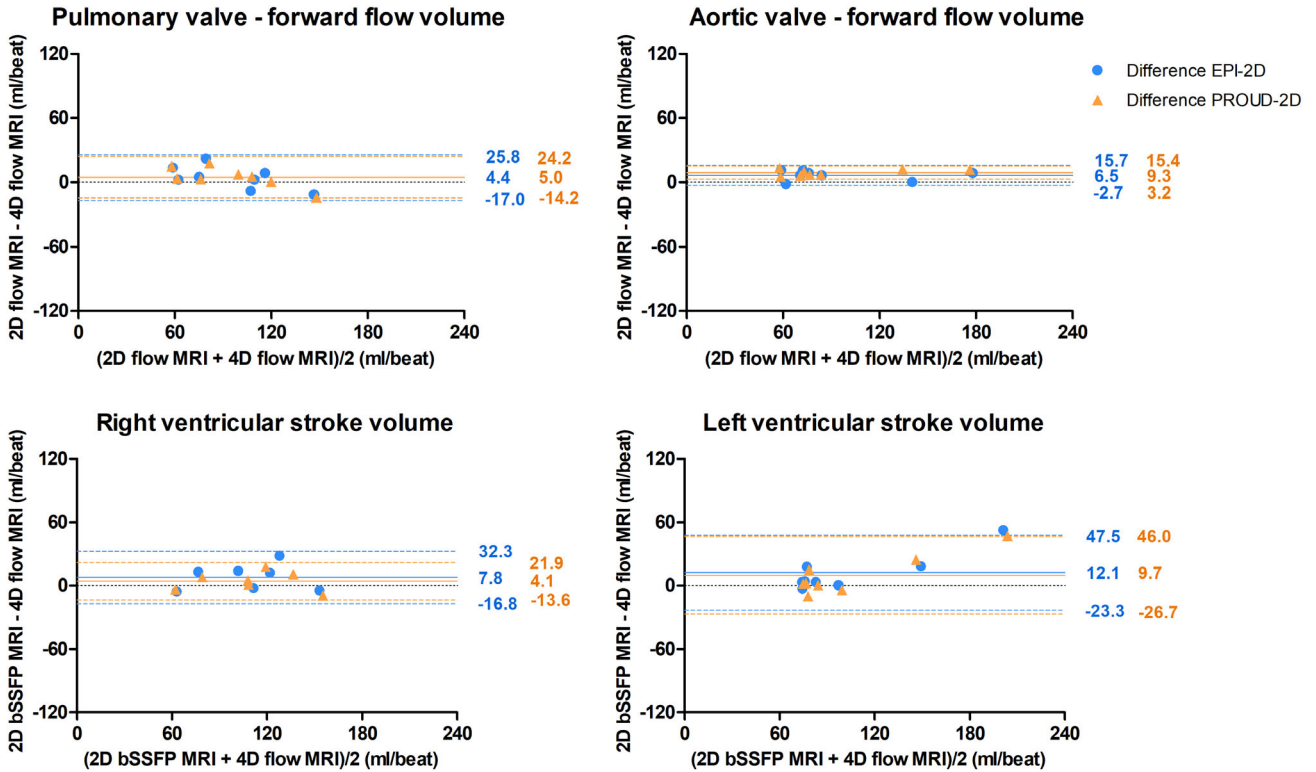


FIGURE 4: Bland–Altman comparison between 4D flow MRI (EPI = blue circles, PROUD = orange triangles) and 2D flow/bSSFP MRI measurements of PV and AV forward flow volumes (top) and RV and LV stroke volumes (bottom) in patients with valvular regurgitation.

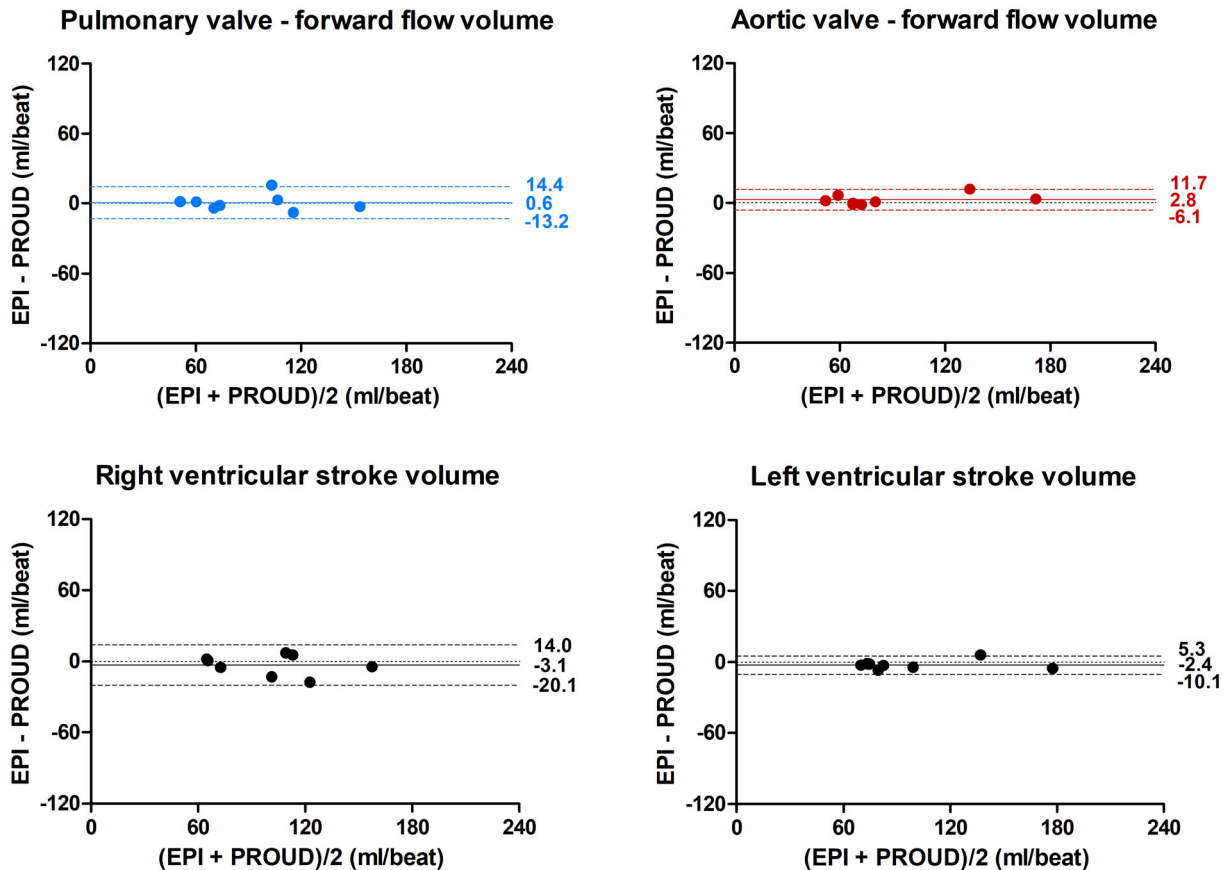


FIGURE 5: Bland–Altman comparison between EPI and PROUD 4D flow MRI measurements of PV and AV forward flow volumes (top) and RV and LV stroke volumes (bottom) in patients with valvular regurgitation.

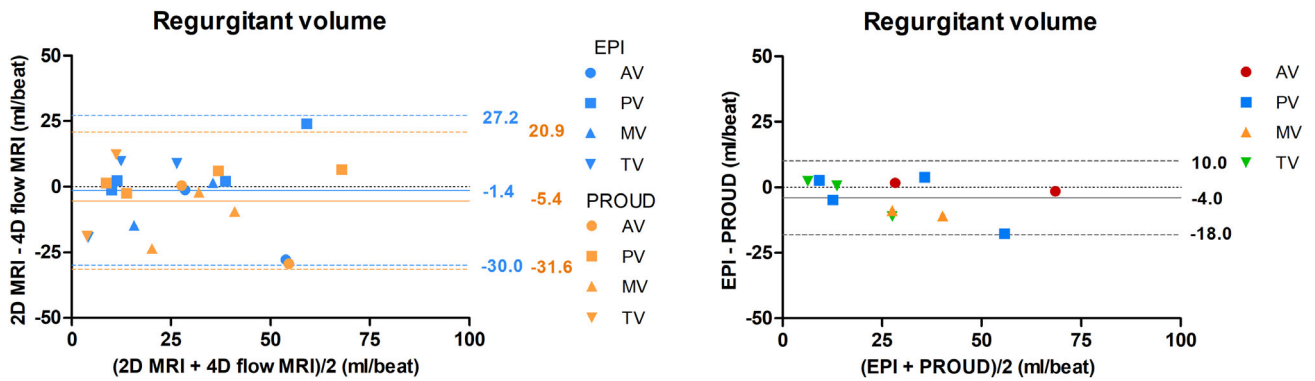


FIGURE 6: Bland–Altman comparison of regurgitant volume measurements: between 4D flow MRI (PROUD or EPI) and 2D MRI (left), and between PROUD and EPI 4D flow MRI (right). 2D MRI entailed a combination of 2D short-axis bSSFP MRI and 2D flow MRI for MV and TV regurgitant volume measurement ($R_{vol_{MV}} = LVS_V - AV$ forward flow volume, $R_{vol_{TV}} = RVS_V - PV$ forward flow volume). AV and PV regurgitant volumes were quantified from 2D flow MRI.

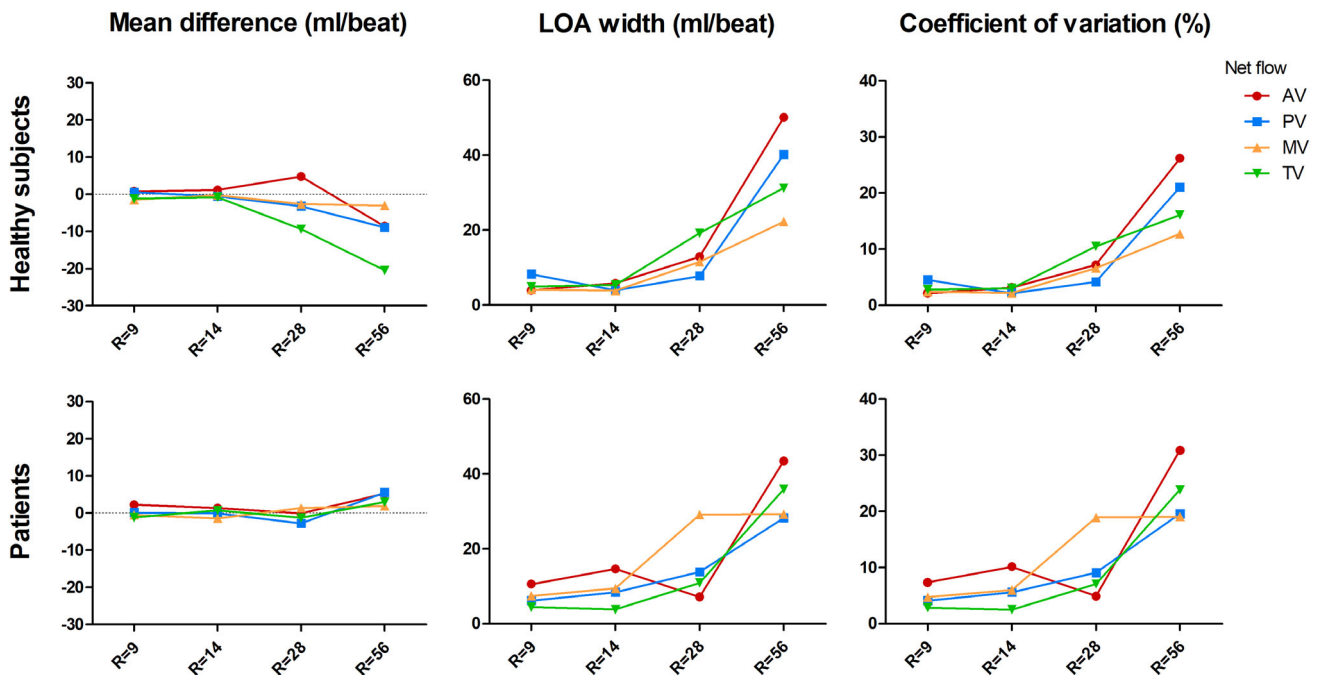


FIGURE 7: Comparison of net flow measurements across the aortic valve (red circles), pulmonary valve (blue squares), mitral valve (orange up-facing triangles), and tricuspid valve (green down-facing triangles) between the increasingly undersampled reconstructions and the original reconstruction based on Bland–Altman analysis.

16 subjects, significantly higher SNRs were found in the PROUD scans (14.9 ± 4.6) than in the EPI scans (11.1 ± 3.4). LLE widths were smaller for EPI (6.7 ± 3.5 voxels) than for PROUD (8.4 ± 2.2 voxels). Bland–Altman parameters of these comparisons and of those between the PROUD $R = 7$ reconstruction and PROUD $R = 9, 14, 28,$ and 56 reconstructions can be found in Table S3 in the Supplemental Material.

Discussion

We compared pseudo-spiral undersampled whole-heart 4D flow MRI with an EPI readout sequence in a cohort of healthy

subjects and patients with valvular regurgitation. Interval consistencies were comparable between PROUD and EPI. Agreement between the two 4D flow techniques was overall higher than between 4D flow MRI (EPI or PROUD) and 2D MRI in measurements of forward flow, stroke volumes, and regurgitant volumes. The observation that increasing the undersampling factor from 7 to 14 (reducing the scan time by 50%) resulted in $<10\%$ measurement deviation from the original acquisition, and only slightly decreased interval consistencies, suggests that PROUD 4D flow scan times may be shortened substantially.

The finding of seemingly—although not significantly—higher interval consistency using PROUD 4D flow

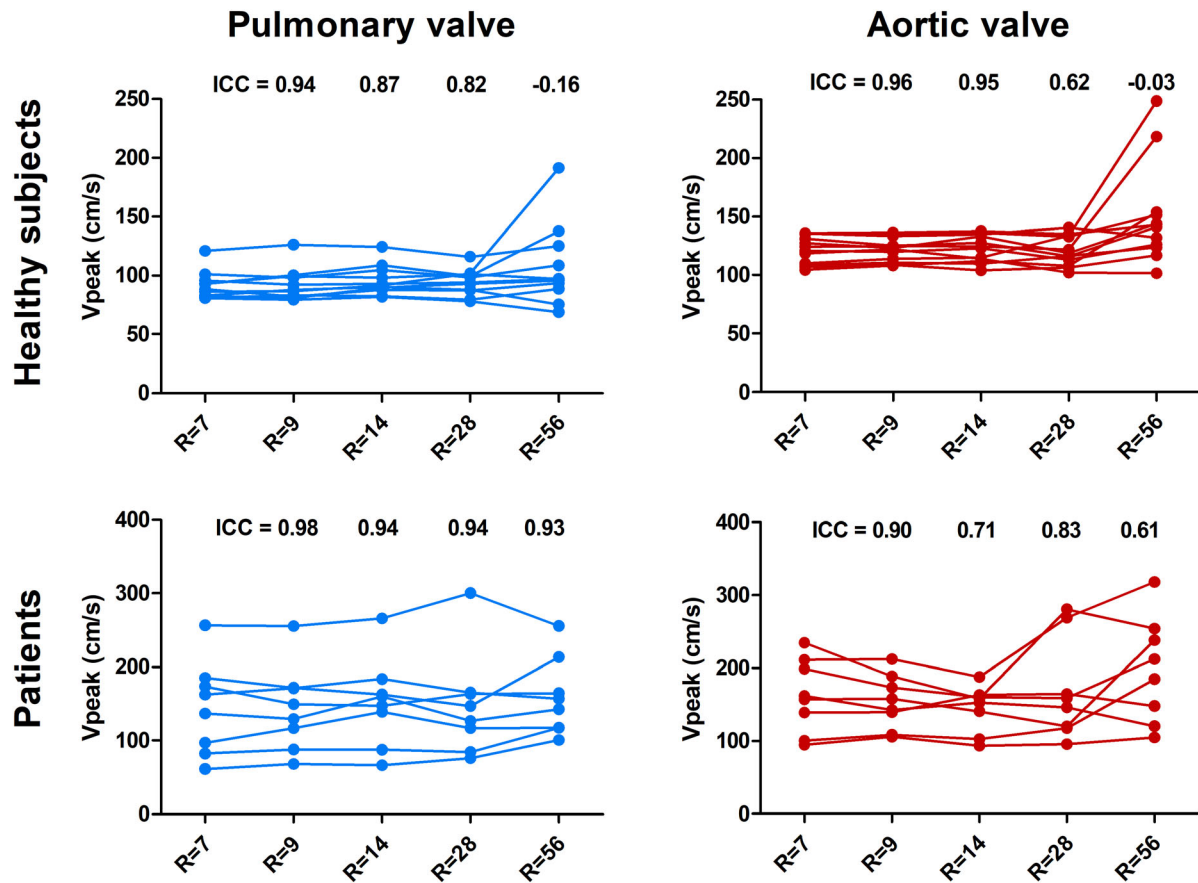


FIGURE 8: Peak velocities measured across the pulmonary (left) and aortic valve (right) in healthy subjects (top) and patients with valvular regurgitation (bottom), plotted for increasing undersampling factors. Measurements in the same subject are connected by lines. Intra-class correlation coefficients between each increasingly undersampled reconstruction and the original reconstruction are shown on the top of each plot.

compared to EPI-based 4D flow is in line with the findings of a recent multicenter study.⁹ The reason for this slight difference in performance can be sought in the limitations that EPI is known to have: flow displacement and phase accumulation resulting in velocity misregistration, and image distortion artifacts due to eddy currents.^{21,22} A detailed study on the former two limitations has shown that phase accumulation results in substantial local reductions of the effective spatial resolutions in frequency- and phase-encoding directions due to modulation of the point spread function.²³ Furthermore, that study found that flow displacement in the order of several millimeters occurs in high-velocity regions. These limitations find their origin in the relatively long echo times, long readout times, and unipolar phase-encoding blips that EPI requires. PROUD 4D flow is less sensitive to flow displacement than EPI because of shorter echo times, and less sensitive to phase accumulation because of a different readout strategy. Another advantage of PROUD compared to EPI is that it exploits the sparsity of the images, and can therefore recover images from highly undersampled k-space data without significant (i.e. only noise-like) artifacts.¹⁶

Noteworthy is that the interval consistencies we found in the EPI and PROUD patient scans were less good

than previously reported in a large-scale study using EPI,⁸ presumably because of a difference in the severity of valvular regurgitation and valvular stenosis. The patients included in the current study had regurgitation fractions of $29.1 \pm 9.6\%$ compared to $<10\%$ in the cited study.

Variability between 4D flow MRI- and 2D MRI-based intracardiac flow measurements has been studied before.^{7,10} Similar to what we have observed, these studies reported that 2D flow MRI measurements of forward flow were higher than those obtained with 4D flow MRI. In our study, but not in the cited studies, this may have been caused by a difference in frame rate: following the normal clinical scan protocol, 2D flow MRI was reconstructed into 40 cardiac frames as opposed to 30 in the 4D flow MRI acquisitions. In addition, the lower spatial resolutions of 4D flow MRI ($2.5 \times 2.5 \times 2.5$ vs. $1.2 \times 1.2 \times 8.0$ mm for 2D flow MRI) may have introduced underestimations in flow and peak velocity in patients with stenotic valves. The wide LOAs seen for the stroke volume and regurgitant volume measurements cannot be attributed to these resolution differences. We have previously shown that 2D MRI-based MV regurgitant volume measurements (which are based on LVSV and AV forward flow volume) are subject to substantial interobserver variability, because of

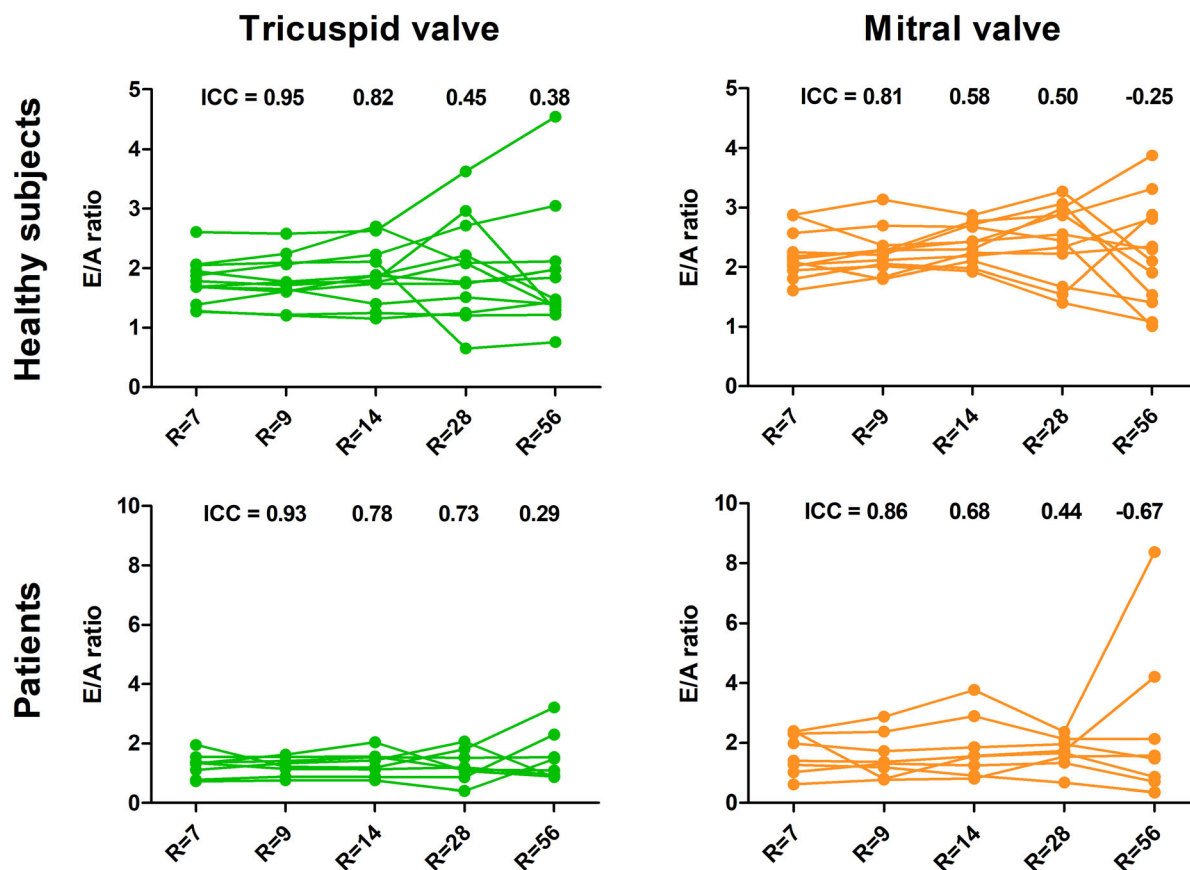


FIGURE 9: E/A ratios measured across the tricuspid (left) and mitral valve (right) in healthy subjects (top) and patients with valvular regurgitation (bottom), plotted for increasing undersampling factors. Measurements in the same subject are connected by lines. Intraclass correlation coefficients between each increasingly undersampled reconstruction and the original reconstruction are shown on the top of each plot.

differences in LVSV quantification,¹⁵ whereas 4D flow MRI-based valve tracking analysis has demonstrated good inter-observer agreement.⁹ Furthermore, stroke volume quantification by a combination of short-axis bSSFP volumetry and 2D flow MRI is sensitive to physiological variability and the patient's ability to hold their breath. Although we had no reference standard available, the availability of four heart valves in a single whole-heart acquisition allowed for cross-comparisons that give a good idea of the overall robustness of the measurements.

In the PROUD reconstructions with different undersampling factors, peak velocities and E/A ratios were well preserved up to an undersampling factor of 9 (using 75% of the initially acquired data). These parameters contain important and clinically used hemodynamic information, and measurement accuracy should not be sacrificed in favor of a higher undersampling factor. Therefore, these parameters should be taken into account when deciding on the maximum undersampling factor in whole-heart 4D flow MRI.

The EPI acquisition had a higher total acceleration factor (10: EPI factor 5, SENSE factor 2) than the PROUD acquisition (factor 7) for approximately the same acquisition time. In some of the test scans we obtained with the EPI

sequence—prior to data acquisition for this study—intravoxel phase dispersion artifacts were present at the borders of the ascending aorta and main pulmonary artery lumen. Changing the phase-encoding direction from anterior–posterior to right–left provided a solution, with the drawback of longer scan times for the same FOV, which is why the EPI acceleration factor had to be set higher. One could argue that the acceleration factors should be equal for a fair comparison. However, since the scan time is ultimately decisive for clinical applicability, we decided to focus on scan times rather than on acceleration factors. Moreover, our results indicated that even for an undersampling factor of 28 in healthy subjects and 14 in patients with valvular regurgitation, PROUD still had comparable interval consistency to EPI.

Limitations

The sample sizes of the healthy subject and patient groups were small and unequal. All results were presented for the two groups separately, but drawing conclusions on how the group-specific results relate to each other is difficult. In the interval consistency tests, smaller mean biases, but larger LOAs, were observed in the patient group which can be partly explained by higher VENCs, and thus lower velocity-to-noise ratios. A difference in

body mass index may also have played a role: more surrounding tissue can lead to a lower SNR. Moreover, irregular breathing such as apneas, hypopneas, and variability in breathing frequency and depth are linked to volume overload heart failure and poor left ventricular function and cannot be ruled out as another reason for larger LOAs in the patient group.^{24,25} No respiratory compensation or correction was performed in the 4D flow MRI acquisitions, as this is standard for the use of EPI 4D flow for intracardiac flow quantification. Moreover, scan times had to be kept predictable at ~9 minutes to be able to perform both 4D flow scans within the allotted time. However, respiratory compensation has been shown to improve image sharpness in PROUD scans, and to have a small effect on flow measurements across the TV and PV compared to no respiratory gating.¹⁹

Another limitation is that no short-axis bSSFP and 2D flow MRI were performed in the healthy subjects. As these scans were not vital for the valve tracking analyses, they were omitted to save enough time for the two 4D flow MRI scans.

Conclusion

Our results indicate that whole-heart 4D flow MRI using pseudo-spiral Cartesian sampling with random undersampling in time (PROUD) and CS reconstruction is a reliable technique for intracardiac flow quantification in <10 minutes. Even for 75% shorter scan times in healthy subjects and 50% shorter scan times in patients with valvular regurgitation, PROUD interval consistencies of flow measurements across the heart valves remain comparable to those of EPI. The current study adds to previous studies that have demonstrated the robustness of PROUD-accelerated 4D flow MRI in other cardiovascular structures.^{11–13} For application in different cardiac pathologies than valvular regurgitation, separate investigation is warranted.

Data Availability Statement

PROUD 4D flow data were acquired using our in-house developed Amsterdam UMC “PROspective Undersampling in multiple Dimensions” patch. A compiled version of this patch is available on reasonable request.

References

1. Markl M, Frydrychowicz A, Kozerke S, Hope M, Wieben O. 4D flow MRI. *J Magn Reson Imaging* 2012;36:1015-1036.
2. Ha H, Kim GB, Kweon J, et al. Hemodynamic measurement using four-dimensional phase-contrast MRI: Quantification of hemodynamic parameters and clinical applications. *Korean J Radiol* 2016;17:445-462.
3. Geiger J, Hirtler D, Bürk J, et al. Postoperative pulmonary and aortic 3D haemodynamics in patients after repair of transposition of the great arteries. *Eur Radiol* 2014;24:200-208.
4. van der Palen RLF, Westenberg JJM, Hazekamp MG, Kuipers IM, Roest AAW. Four-dimensional flow cardiovascular magnetic resonance for the evaluation of the atrial baffle after Mustard repair. *Eur Heart J Cardiovasc Imaging* 2016;17:353-353.
5. Geiger J, Markl M, Jung B, et al. 4D-MR flow analysis in patients after repair for tetralogy of Fallot. *Eur Radiol* 2011;21:1651-1657.
6. Sjöberg P, Bidhult S, Bock J, et al. Disturbed left and right ventricular kinetic energy in patients with repaired tetralogy of Fallot: Pathophysiological insights using 4D-flow MRI. *Eur Radiol* 2018;28:4066-4076.
7. Hsiao A, Tariq U, Alley MT, Lustig M, Vasanawala SS. Inlet and outlet valve flow and regurgitant volume may be directly and reliably quantified with accelerated, volumetric phase-contrast MRI. *J Magn Reson Imaging* 2015;41:376-385.
8. Kamphuis VP, Roest AAW, Ajmone Marsan N, et al. Automated cardiac valve tracking for flow quantification with four-dimensional flow MRI. *Radiology* 2019;290:70-78.
9. Juffermans JF, Minderhoud SCS, Wittgren J, et al. Multicenter consistency assessment of valvular flow quantification with automated valve tracking in 4D flow CMR. *JACC Cardiovasc Imaging* 2021;14:1367-1368.
10. Garg P, Westenberg JJM, van den Boogaard PJ, et al. Comparison of fast acquisition strategies in whole-heart four-dimensional flow cardiac MR: Two-center, 1.5 tesla, phantom and in vivo validation study. *J Magn Reson Imaging* 2018;47:272-281.
11. Gottwald LM, Peper ES, Zhang Q, et al. Pseudo-spiral sampling and compressed sensing reconstruction provides flexibility of temporal resolution in accelerated aortic 4D flow MRI: A comparison with k-t principal component analysis. *NMR Biomed* 2020;33:e4255.
12. Peper ES, Gottwald LM, Zhang Q, et al. Highly accelerated 4D flow cardiovascular magnetic resonance using a pseudo-spiral Cartesian acquisition and compressed sensing reconstruction for carotid flow and wall shear stress. *J Cardiovasc Magn Reson* 2020;22:7.
13. Gottwald LM, Töger J, Bloch KM, et al. High spatiotemporal resolution 4D flow MRI of intracranial aneurysms at 7T in 10 minutes. *AJNR Am J Neuroradiol* 2020;41:1201-1208.
14. Westenberg JJM, Roes SD, Ajmone Marsan N, et al. Mitral valve and tricuspid valve blood flow: Accurate quantification with 3D velocity-encoded MR imaging with retrospective valve tracking. *Radiology* 2008;249:792-800.
15. Blanken CPS, Westenberg JJM, Aben J-P, et al. Quantification of mitral valve regurgitation from 4D flow MRI using semiautomated flow tracking. *Radiol Cardiothorac Imaging* 2020;2:e200004.
16. Lustig M, Donoho D, Pauly JM. Sparse MRI: The application of compressed sensing for rapid MR imaging. *Magn Reson Med* 2007;58:1182-1195.
17. Jaspan ON, Fleisher R, Lipton ML. Compressed sensing MRI: A review of the clinical literature. *Br J Radiol* 2015;88:20150487.
18. Loecher M, Schrauben E, Johnson KM, Wieben O. Phase unwrapping in 4D MR flow with a 4D single-step Laplacian algorithm. *J Magn Reson Imaging* 2016;43:833-842.
19. Gottwald LM, Blanken CPS, Tourais J, et al. Retrospective camera-based respiratory gating in clinical whole-heart 4D flow MRI. *J Magn Reson Imaging* 2021;54:440-451.
20. Koo TK, Li MY. A guideline of selecting and reporting intraclass correlation coefficients for reliability research. *J Chiropr Med* 2016;15:155-163.
21. Butts K, Riederer SJ. Analysis of flow effects in echo-planar imaging. *J Magn Reson Imaging* 1992;2:285-293.
22. Fischer H, Ladebeck R. Echo-planar imaging image artifacts. *Echo-planar imaging*. Berlin, Heidelberg: Springer; 1998. p 179-200.
23. Dillinger H, Walheim J, Kozerke S. On the limitations of echo planar 4D flow MRI. *Magn Reson Med* 2020;84:1806-1816.
24. Feld H, Priest S. A cyclic breathing pattern in patients with poor left ventricular function and compensated heart failure: A mild form of Cheyne-Stokes respiration? *J Am Coll Cardiol* 1993;21:971-974.
25. Toledo C, Andrade DC, Díaz HS, et al. Rostral ventrolateral medullary catecholaminergic neurones mediate irregular breathing pattern in volume overload heart failure rats. *J Physiol* 2019;597:5799-5820.