

Received: 2019.08.07

Accepted: 2019.10.17

Published: 2020.01.23

# Maternal Utero-Placental Perfusion Discordance in Monochorionic-Diamniotic Twin Pregnancies with Selective Growth Restriction Assessed by Three-Dimensional Power Doppler Ultrasound

Authors' Contribution:  
Study Design A  
Data Collection B  
Statistical Analysis C  
Data Interpretation D  
Manuscript Preparation E  
Literature Search F  
Funds Collection G

**BCDEF 1,2,3,4 Lan Zhang**  
**BF 1,3,4 Xiyao Liu**  
**BD 1,2,3,4 Junnan Li**  
**BF 1,2,3,4 Xing Wang**  
**BD 1,2,3,4 Shuai Huang**  
**DF 1,3,4 Xiaofang Luo**  
**DF 1,3,4 Hua Zhang**  
**AEF 1,3,4 Li Wen**  
**AEG 1,3,4 Chao Tong**  
**AE 5,6 Richard Saffery**  
**FG 7 Jianying Yan**  
**AG 1,3,4,7 Hongbo Qi**  
**ADE 8,9 Mark D. Kilby**  
**ADE 10 Philip N. Baker**

1 Department of Obstetrics, The First Affiliated Hospital of Chongqing Medical University, Chongqing, P.R. China  
2 Fetal Medicine Unit, The First Affiliated Hospital of Chongqing Medical University, Chongqing, P.R. China  
3 International Collaborative Joint Laboratory of Reproduction and Development of Ministry of Education P.R.C., Chongqing Medical University, Chongqing, P.R. China  
4 State Key Laboratory of Maternal and Fetal Medicine of Chongqing Municipality, The First Affiliated Hospital of Chongqing Medical University, Chongqing, P.R. China  
5 Cancer, Disease and Developmental Epigenetics, Murdoch Children's Research Institute, Parkville, VIC, Australia  
6 Department of Pediatrics, University of Melbourne, Parkville, VIC, Australia  
7 Fujian Provincial Maternity and Children's Hospital, Affiliated Hospital of Fujian Medical University, Fuzhou, Fujian, P.R. China  
8 Institute of Metabolism and System Research, University of Birmingham, Edgbaston, U.K.  
9 Fetal Medicine Centre, Birmingham Women's and Children's Foundation Trust, Birmingham, U.K.  
10 College of Life Sciences, University of Leicester, Leicester, U.K.

**Corresponding Authors:** Chao Tong, e-mail: [chaotongcqmu@163.com](mailto:chaotongcqmu@163.com), Jianying Yan, e-mail: [yanjy2004@126.com](mailto:yanjy2004@126.com), Hongbo Qi, e-mail: [qihongbo728@163.com](mailto:qihongbo728@163.com)  
**Source of support:** This study was funded by the Ministry of Science and Technology of China (2018YFC1002901 and 2016YFC1000407), the National Natural Science Foundation of China (81520108013, 81771613, 81671488, and 81871189), the Chongqing Municipal Education Commission (CXDX201601014), and the Cultivated Foundation of the First Affiliated Hospital of Chongqing Medical University (PYJ2017-17)

**Background:** The aim of this study was to assess the correlation between selective growth restriction (sGR) and co-twin utero-placental perfusion discordance by using three-dimensional power Doppler (3DPD).

**Material/Methods:** We prospectively recruited 60 sGR and 64 normal monochorionic-diamniotic (MCDA) twin pregnancies. Vascularization index (VI), flow index (FI), and vascularization flow index (VFI) were assessed by 3DPD, while umbilical artery pulsatility index (UA-PI), middle cerebral artery peak systolic velocity (MCA-PSV), pulsatility index (MCA-PI), and cerebroplacental ratio (CPR) were assessed by conventional Doppler imaging.

**Results:** In sGR co-twins, the VI, FI, VFI, MCA-PI, and CPR were significantly lower, while the UA-PI and MCA-PSV were significantly greater, in the smaller fetuses compared with the larger fetuses; significant differences were also observed in the VI, FI, VFI, CPR, and UA-PI in normal co-twins. Compared with the appropriately grown twins, the discordances of the VI, FI, VFI, UA-PI, MCA-PI, and CPR were increased in the sGR cohort. The discordances of the VI, FI, VFI, UA-PI, MCA-PI, and CPR were associated with birthweight discordance, and the FI discordance and CPR discordance were independently associated with sGR. The combination of the FI and CPR discordance showed a higher predictive accuracy for sGR, with an area under the ROC curve of 0.813, and a sensitivity and specificity of 68.33% and 85.94%, respectively.

**Conclusions:** MCDA twin pregnancies with birthweight discordance presented utero-placental perfusion deterioration assessed by 3DPD prior to sGR diagnosis. Co-twin utero-placental perfusion discordance was significantly correlated with growth discordance, and this correlation was more predictive of sGR when 3DPD was combined with conventional Doppler imaging.

**MeSH Keywords:** **Growth Disorders • Placental Circulation • Prenatal Diagnosis • Twins, Monozygotic • Ultrasonography, Doppler, Color**

Full-text PDF: <https://www.medscimonit.com/abstract/index/idArt/919247>



3513 3 3 30

## Background

Selective growth restriction (sGR) complicates approximately 20% of monochorionic-diamniotic (MCDA) twins [1]. sGR, mainly characterized by fetal estimated fetal weight (EFW) discordance being associated with greater risks of intrauterine fetal demise and adverse neonatal outcomes for both offspring [2,3]. The 'threshold' for increased fetal mortality is controversial, with prospective series indicating a threshold increase in risk from an 18% difference in EFW on ultrasound [4], but most series indicating significant increase risk of single or co-twin demise when the % difference in EFW rises to 25% (and abdominal circumference of one twin less than the 10th centile) [1]. As sGR frequently causes poor perinatal outcome, exploring a method to diagnose sGR early is clinically important so that effective interventions can be carried out to improve perinatal outcome.

sGR has been showed to be closely associated with impaired utero-placental perfusion [5,6]. For the non-invasive approach, previous studies evaluating utero-placental perfusion have used conventional Doppler ultrasound [6,7] to assess the umbilical artery and middle cerebral artery velocimetry. Since only severe fetal hypoxemia would result in classical abnormal Doppler velocity waveforms, mildly impaired perfusion prior to the onset of fetal compromise might not be determined in a timely manner [8]. Thus, using the conventional fetal Doppler ultrasound to predict placental perfusion deterioration is limited. A new approach allowing real-time assessment of utero-placental perfusion is required.

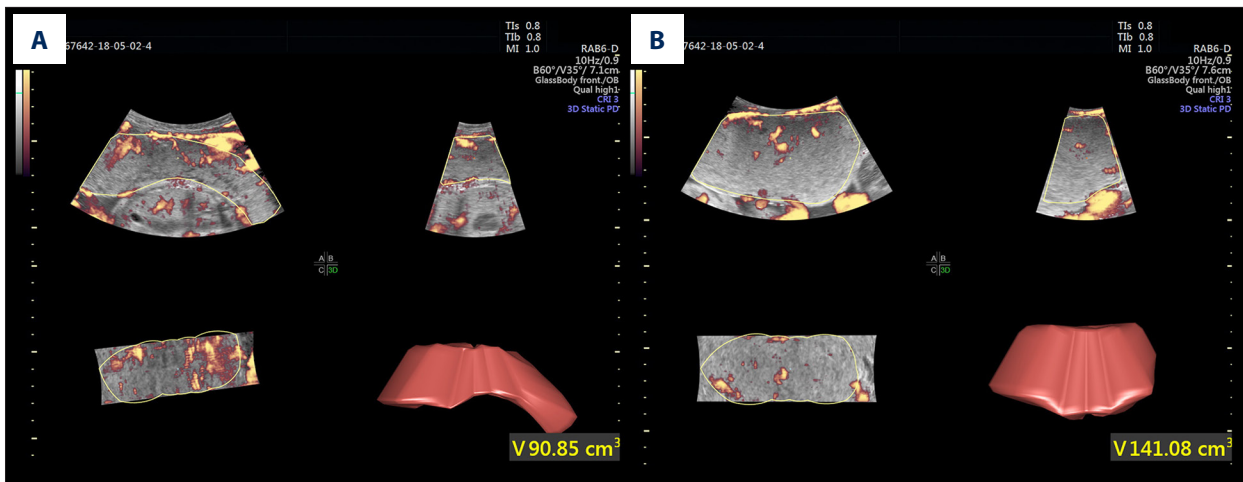
Three-dimensional power Doppler ultrasound (3DPD) is an economical and non-invasive method that has allowed the real-time assessment of utero-placental perfusion by quantitatively depicting the tissue vascularization and flow, especially for small vessels and slow flows [9]. Several studies on singleton pregnancies [10–13] have reported that decreased utero-placental perfusion assessed by 3DPD was related to fetuses with malplacental syndromes (i.e., intrauterine growth restriction, preeclampsia, or gestational diabetes).

Recent studies have demonstrated that sGR might be better evaluated by assessing co-twin discordance rather than individual fetal sizes alone [14,15]. Early detection of flow discordance may indeed improve the detection of sGR, as differences in vascularization of sGR twin placentae have been proved by dye injection [16]. To the best of our knowledge, only one small study [17] observed impaired placental perfusion in sGR using 3DPD. However, whether the unbalanced utero-placental perfusion is associated with birthweight discordance and whether 3DPD is a more effective method than conventional Doppler ultrasound to predict sGR remain unclear.

Therefore, the aim of this study was to investigate the relationship between co-twin utero-placental perfusion discordance assessed by 3DPD and sGR. We hypothesized that this novel technique might provide new insights into the association between utero-placental perfusion discordance and growth disorders, and provide evidence for the early diagnosis, better clinical monitoring, and better evaluation of therapeutic effect and prognosis of this high-risk population.

## Material and Methods

This study was a cross-sectional study of the Chongqing Longitudinal Twin Study (LoTiS) conducted at the Fetal Medicine Center of the First Affiliated Hospital of Chongqing Medical University in Chongqing, China between July 2016 and July 2018. Twins at the time of first diagnosis of sGR (sGR group) at our center at a gestational age (GA) of 18 to 36 weeks were enrolled. The inclusion criteria of sGR group were as follows: 1) MCDA twin pregnancy; and 2) MCDA twin pregnancies with sGR. sGR was diagnosed when the EFW or birthweight of the smaller fetus/neonate was below the 10<sup>th</sup> percentile for the gestational age and the EFW or birthweight discordance was more than 25% between the fetuses/neonates [5]. Data only confirmed sGR after delivery was included. EFW or birthweight discordance was calculated using the following formula: (weight of larger – weight of smaller)/weight of larger × 100%. According to the classification system [18], which was proposed by Gratacos and adopted by the newest International Society of Ultrasound in Obstetrics and Gynecology (ISUOG) practice guideline [5], based on the characteristics of the end-diastolic flow in the umbilical artery of small fetuses, twins with sGR exhibit 3 waveform patterns: Type I (persistently positive), Type II (persistently absent or persistently reversed), and Type III (intermittently absent or intermittently reversed). Participants were excluded for the following reasons: 1) single or co-twin demise; 2) pregnancy with a fetal abnormality, aneuploidy, or a genetic syndrome; 3) pregnancy complicated with twin-to-twin transfusion syndrome or twin-anemia polycythemia sequence; and 4) the inability to detect the placenta by 3DPD. Normal MCDA twins (a birthweight in the normal range), with matched maternal age and GA at ultrasound, were enrolled as a control group. The GA was determined according to the last menstrual period, the first-trimester crown-rump length (CRL), or the head circumference of the larger twin when the first ultrasound examination was performed after 14 weeks of gestation. Chorionicity was determined by an ultrasound evaluation according to the number of placentae and the presence of a T-sign or lambda sign, and was confirmed after delivery. The reasons for termination of pregnancy included premature rupture of membranes, premature labor, fetal distress, pregnancies over 36 weeks, placental abruption, and placenta previa with hemorrhage. The indications for caesarean section included fetal distress, cephalopelvic



**Figure 1.** A representative volumetric image of placentas from selective growth restriction twins. Volumetric images of the utero-placental perfusion of one monozygotic-diamniotic twin pregnancy with selective growth restriction (**A** smaller fetus and **B** larger fetus) at 30<sup>+</sup> weeks of gestation measured by three-dimensional power Doppler ultrasound. The yellow line refers to the whole placental tissue including the chorionic and basal plates.

disproportion, placental abruption, placenta previa, and social factors, or other situations. Complications in pregnancy included gestational diabetes mellitus, intrahepatic cholestasis of pregnancy, and preeclampsia. If the above situations were serious, relevant therapies were provided.

Voluson E8 and E10 ultrasound instruments (GE Healthcare, Austria) were used with C4-8-D (4.0–8.0 MHz), C1-5-D (1.0–5.0 MHz) and RAB6-D (2.0–7.0 MHz) transducers. A complete ultrasound measurement was performed by one experienced observer (L.Z.) according to the International Society of Ultrasound in Obstetrics and Gynecology practice guideline [5].

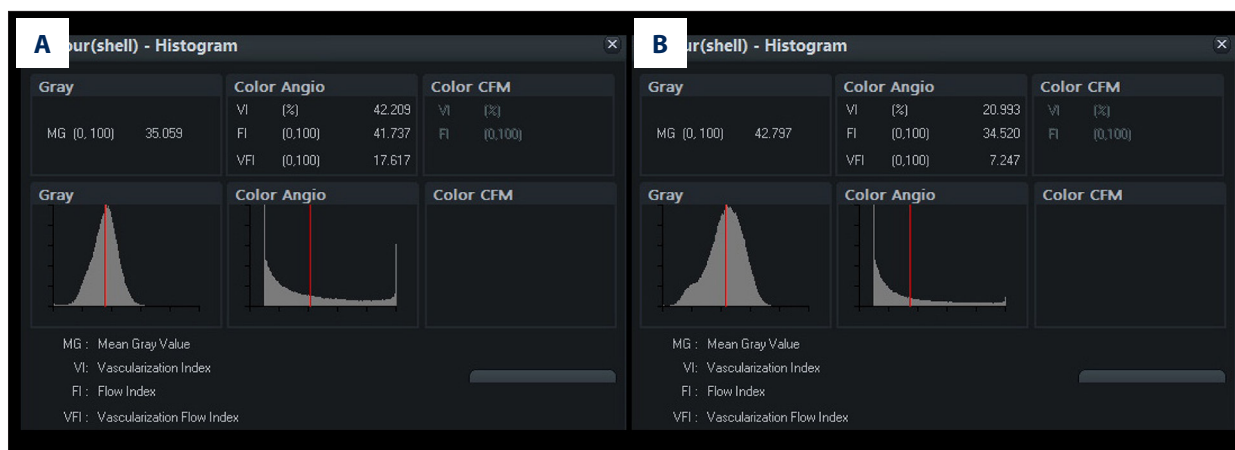
Two-dimensional (2D) and 3DPD scans were performed in each examination. The umbilical artery pulsatility index (UA-PI), middle cerebral artery peak systolic velocity (MCA-PSV), and pulsatility index (MCA-PI) were measured. The cerebroplacental ratio (CPR) was calculated as the ratio of the MCA-PI to the UA-PI. A visual inspection of the ductus venosus Doppler waveform was performed, and the presence of a reversed a-wave was recorded. The EFW was assessed according to the head circumference, the biparietal diameter, the abdominal circumference, and the femur length using the Hadlock formula [19]. The placental cord insertion (PCI) site was categorized as normal, marginal, or velamentous [20]. If the PCI of the larger fetus was normal and the PCI of the smaller fetus was marginal or velamentous, discordant PCI was considered.

After the 2D examination, the placental 3DPD assessment was performed. To acquire maximal sensitivity, the following settings were used: PRF: 0.6 kHz; Quality: norm; WMF: low 1; FRQ: low; Balance: 170; Filter: 2; Smooth: 4/5; and Artifact: on. The point of umbilical cord insertion was used as the center

and the total placental thickness was scanned by 3DPD with a unified acquisition angle of 35°. The acquisition time varied from 5 to 15 s without fetal movements. All 3DPD data were subsequently processed to calculate the volume, vascularization index (VI), flow index (FI), and vascularization flow index (VFI) using the Virtual Organ Computer-aided Analysis (VOCAL) technique. In each case, areas surrounding 3–5 cm of the umbilical cord insertion, including the basal, body, and surface areas of the placenta, were selected as the area of interest in each placental territory (Figure 1). Then, the manual mode was set and the area of interest for each placenta was manually traced by rotating 30 degrees 6 times. Finally, a histogram automatically showed the 3 vascular indices (Figure 2). VI refers to the color voxel/total voxel ratio and represents the presence of blood vessels in the placenta; FI refers to the average amplitude value of all color voxels and represents the blood flow intensity; and VFI refers to the weighted color voxel/total voxel ratio, combining the information on the vessel presence (vascularity) and the amount of blood cells transported (blood flow). Each twin pair was measured 3 times, and the mean values were calculated for the final statistical analysis. Co-twin discordances of UA-PI, MCA-PSV, MCA-PI, CPR, VI, FI, VFI, and CRL were defined as [(larger fetal value–smaller fetal value)/larger fetal value]×100%.

### Statistical analyses

The normality of the data was determined by the Shapiro-Wilk test. Continuous variables are expressed as the mean±standard deviation for normally distributed data or as the median and interquartile range for non-normally distributed data. The data between the control group and sGR group were compared by an independent *t* test or a Mann-Whitney U test. Differences



**Figure 2.** Histograms of the vascular indices. The vascular indices of the same monozygotic twin pregnancy with selective growth restriction (**A** smaller fetus and **B** larger fetus) at 30<sup>+</sup> weeks of gestation, shown as a histogram.

between co-twins were compared by a paired *t* test or a non-parametric paired test. Categorical variables are expressed as absolute values with percentages and were compared by a Pearson's chi-square test. Bivariate correlation analyses were performed to determine the relationship between the co-twin utero-placental perfusion indices (as well as the discordance), GA, and the birthweight discordance. Univariate and multivariate logistic regression analyses were performed to identify the predictive parameters for sGR. Based on the logistics model, we combined the probabilities. Sensitivity and specificity were calculated by a receiver operating characteristic curve (ROC) analysis. Thirty twins were randomly selected to evaluate the intraobserver and interobserver variation in the placental vascularization data post-processing. Intraobserver variation was examined by L.Z., and interobserver variation was examined by L.Z. and X.W. All *p* values were two-sided, and a value of <0.05 was considered statistically significant. Statistical analyses were performed with SPSS version 21.0 (IBM Corporation, Armonk, NY, USA) and MedCalc version 11.4.2 (MedCalc Software, Ostend, Belgium).

### Ethics approval

The study was approved by the Ethics Committee of the First Affiliated Hospital of Chongqing Medical University (record number 201530). All women provided written informed consent.

### Results

During the study period, 168 consecutive MCDA twin pregnancies were enrolled. Eleven twins with suboptimal images and 33 twins with missing outcome data were excluded. A total of 124 subjects were used for the final analysis (64 in the control group and 60 in the sGR group). In the sGR group, 42 were type I, 18 were type II, and none were type III.

The clinical characteristics between the control group and the sGR group are presented in Table 1. Compared with the control group, the sGR group had an earlier delivery GA, a lower birthweight of both offspring, a higher CRL discordance, a higher birthweight discordance, and more Apgar scores <7 at 1, 5, and 10 min (all *p*<0.05). No significant differences were found in maternal age, pre-pregnancy body mass index, parity, GA at ultrasound scan, PCI site, fertilization technique, delivery mode, or neonatal sex between the groups (all *p*>0.05).

The conventional Doppler and 3DPD utero-placental perfusion characteristics are presented in Table 2. In sGR co-twins, the VI, FI, VFI, MCA-PI, and CPR were significantly lower, while the UA-PI and MCA-PSV were significantly higher in the smaller fetuses compared with the larger fetuses (all *p*<0.05). Significant differences were also observed in the VI, FI, VFI, CPR, and UA-PI in normal co-twins (all *p*<0.05). No reversed a-wave was recorded in the ductus venosus Doppler flow profile in any of the subjects.

The conventional Doppler and 3DPD utero-placental perfusion discordances between the control group and sGR group are presented in Table 3. Compared to the controls, the discordances of the UA-PI, MCA-PI, CPR, VI, FI, and VFI were increased in the sGR group (all *p*<0.05). No differences were found in the discordance of the MCA-PSV (*p*>0.05).

The relationship between the GA at ultrasound scan, the conventional Doppler, and 3DPD parameters and their discordances were assessed in controls. There were significant correlations between the GA at ultrasound scan and UA-PI ( $r=-0.594$ ,  $p<0.001$ ), MCA-PSV ( $r=0.782$ ,  $p<0.001$ ), and CPR ( $r=0.583$ ,  $p<0.001$ ). However, no significant correlations were observed between the GA at ultrasound scan and VI ( $r=-0.155$ ,  $p=0.222$ ), FI ( $r=-0.066$ ,  $p=0.606$ ), VFI ( $r=-0.094$ ,  $p=0.460$ ), and MCA-PI ( $r=0.213$ ,  $p=0.092$ ) in the larger fetuses in controls.

**Table 1.** Clinical characteristics of the subjects.

Characteristics	Controls (n=64)	sGR (n=60)	P-value
Maternal age (years)	27 (25.00–30.75)	27 (25.00–31.00)	0.356
Assisted reproduction [n (%)]	3 (4.7%)	5 (8.3%)	0.409
Prepregnancy body mass index (kg/m <sup>2</sup> )	21.09 (19.50–22.64)	20.95 (19.63–22.25)	0.697
Nulliparous [n (%)]	45 (70.3%)	42 (70.0%)	0.970
GA at ultrasound scan (wks)	25.67 (22.64–30.57)	27.86 (24.00–32.11)	0.147
GA at delivery (wks)	36.29 (35.33–37.14)	34.36 (33.04–36.00)	<0.001
Caesarean section [n (%)]	59 (92.2%)	57 (95.0%)	0.524
Male [n (%)]	66 (51.6%)	60 (50.0%)	0.806
CRL discordance (%)	3.08 (1.69–6.80)	8.97 (2.73–13.81)	0.025
Discordant PCI [n (%)]	37 (57.8%)	37 (61.7%)	0.662
Birthweight of the larger fetus (g)	2474.39±331.85	2235.17±351.02	<0.001
Birthweight of the smaller fetus (g)	2140.94±336.09	1469.50±314.55	<0.001
Birthweight discordance (%)	14.19 (9.16–19.20)	32.80 (27.89–39.90)	<0.001
Apgar <7 at 1 min [n (%)]	5 (3.9%)	44 (36.7%)	<0.001
Apgar <7 at 5 min [n (%)]	1 (0.8%)	15 (12.5%)	<0.001
Apgar <7 at 10 min [n (%)]	0 (0.0%)	6 (5.0%)	0.010

GA – gestational age; CRL – crown–rump length; PCI – placental cord insertion. The data are presented as the mean±standard deviation or as median (interquartile range) or number (percentage).

**Table 2.** Conventional Doppler and 3DPD utero-placental perfusion characteristics between the smaller and larger fetuses.

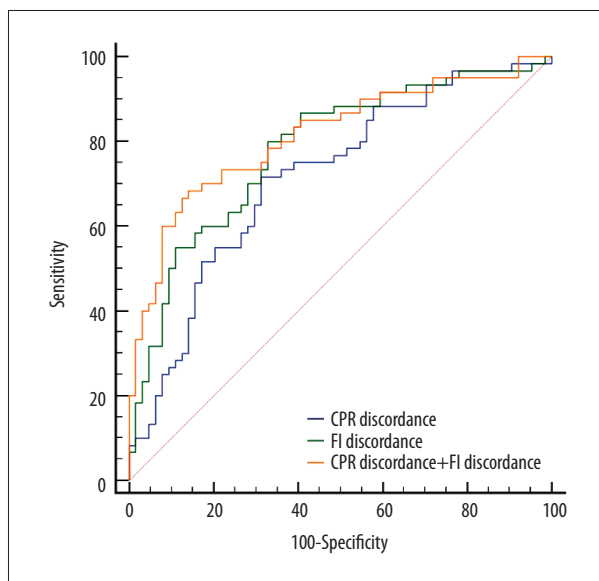
Indices	Controls (n=64)			sGR (n=60)		
	Smaller fetus	Larger fetus	P-value	Smaller fetus	Larger fetus	P-value
UA-PI	1.19 (1.04–1.33)	1.06 (0.92–1.21)	<0.001	1.39 (1.16–1.90)	0.99 (0.85–1.18)	<0.001
MCA-PSV	30.23 (24.65–40.09)	29.31 (24.75–39.36)	0.907	39.22 (29.23–44.39)	34.91 (28.29–43.14)	0.029
MCA-PI	1.49 (1.32–1.68)	1.53 (1.36–1.70)	0.175	1.43 (1.30–1.67)	1.64 (1.49–1.89)	<0.001
CPR	1.24 (1.02–1.61)	1.48 (1.18–1.81)	0.004	1.12 (0.75–1.34)	1.72 (1.33–2.17)	<0.001
VI	49.96±13.31	59.63±14.27	<0.001	41.29±15.64	58.15±15.14	<0.001
FI	37.17±5.00	40.22±4.78	<0.001	32.08 (28.37–37.45)	40.04 (36.72–44.36)	<0.001
VFI	18.93±6.61	24.80±7.42	<0.001	12.80 (8.89–16.93)	22.49 (17.78–28.82)	<0.001

VI – vascularization index; FI – flow index; VFI – vascularization flow index; UA-PI – umbilical artery pulsatility index; MCA-PSV – middle cerebral artery peak systolic velocity; MCA-PI – middle cerebral artery pulsatility index; CPR – cerebroplacental ratio. The data are presented as the mean ± standard deviation or as median (interquartile range).

**Table 3.** Conventional Doppler and 3DPD utero-placental perfusion discordances between the control group and the sGR group.

Characteristics	Controls (n=64)	sGR (n=60)	P-value
UA-PI discordance (%)	10.51 (-5.42–22.38)	24.10 (10.47–41.51)	<0.001
MCA-PSV discordance (%)	–.20 (-18.54–14.15)	11.16 (-9.96–20.15)	0.114
MCA-PI discordance (%)	3.13 (-9.51–13.78)	11.46 (-3.82–23.95)	0.016
CPR discordance (%)	12.89 (-10.64–32.70)	36.16 (15.50–45.96)	<0.001
VI discordance (%)	14.81±18.71	28.26±22.61	<0.001
FI discordance (%)	7.62 (-0.47–16.43)	20.42 (13.83–28.25)	<0.001
VFI discordance (%)	21.30±23.57	41.70±21.15	<0.001

VI – vascularization index; FI – flow index; VFI – vascularization flow index; UA-PI – umbilical artery pulsatility index; MCA-PSV – middle cerebral artery peak systolic velocity; MCA-PI – middle cerebral artery pulsatility index; CPR – cerebroplacental ratio. The data are presented as the mean±standard deviation or as median (interquartile range).



**Figure 3.** Receiver operator characteristic curves. Receiver operator characteristic curves of the cerebroplacental ratio (CPR) discordance, flow index (FI) discordance, and their combination for identifying selective growth restriction.

No significant correlations were observed between the GA at scan and the discordances [VI ( $r=0.186$ ,  $p=0.140$ ), FI ( $r=0.011$ ,  $p=0.932$ ), VFI ( $r=0.232$ ,  $p=0.065$ ), UA-PI ( $r=0.050$ ,  $p=0.695$ ), MCA-PSV ( $r=-0.083$ ,  $p=0.517$ ), or MCA-PI ( $r=0.182$ ,  $p=0.150$ ), CPR ( $r=0.062$ ,  $p=0.625$ )].

By bivariate correlation analyses, the discordances of the VI ( $r=0.358$ ,  $p<0.001$ ), FI ( $r=0.219$ ,  $p=0.005$ ), VFI ( $r=0.394$ ,  $p<0.001$ ), UA-PI ( $r=0.344$ ,  $p<0.001$ ), MCA-PI ( $r=0.510$ ,  $p<0.001$ ), CPR ( $r=0.470$ ,  $p<0.001$ ), and CRL ( $r=0.373$ ,  $p=0.003$ ) were associated with birthweight discordance. The MCA-PSV discordance was not associated with the birthweight discordance ( $r=0.174$ ,  $p=0.053$ ).

To identify the predictive indices for sGR, conventional Doppler and 3DPD utero-placental perfusion discordances, as well as CRL discordance, were included for univariable and multivariable logistic analysis. A backwards stepwise logistic regression analysis identified that only the CPR discordance and FI discordance were independently associated with sGR (all  $p<0.001$ ). The ROC curves showed that the FI discordance and CPR discordance had predictive accuracy for sGR, with an area under the ROC curve of 0.782 [95% confidence interval (CI): 0.699–0.851] and 0.717 (95% CI: 0.629–0.794), respectively, with a sensitivity 80.00% and 71.67%, respectively, and a specificity of 67.19% and 68.75%, respectively. When combining the FI discordance with the CPR discordance, a sensitivity of 68.33% and a specificity of 85.94% with the area under the curve of 0.832 (95% CI: 0.733–0.877) were observed (Figure 3). By pairwise comparison of ROC curves, no superior predictive value was observed in the FI discordance when compared to the CPR discordance ( $p=0.282$ ). However, combining the FI and CPR discordance showed an incremental value compared to either alone (combination vs. FI discordance,  $p=0.040$ ; combination vs. CPR discordance,  $p=0.003$ ).

In this study, analyses of the inter- and intra-observer variability of the VI, FI, and VFI were conducted and demonstrated good reproducibility. The intraclass correlation coefficients for the VI, FI, and VFI were 0.994, 0.989, and 0.967, respectively, and the interclass correlation coefficients were 0.993, 0.923, and 0.967, respectively.

## Discussion

In the present study, real-time utero-placental perfusion and the discordances were detected by both 3DPD and conventional 2D Doppler in normal MCDA twin pregnancies and pregnancies complicated with sGR. Our results showed that the smaller twins presented decreased 3DPD perfusion indices prior to

diagnosis of sGR, and significant decreases in 3DPD and conventional fetal Doppler indices were found in sGR twins. The discordances of the 3DPD and 2D Doppler indices were associated with birthweight discordance, and were higher in the sGR group compared to the controls. The FI discordance and the CPR discordance showed predictive accuracy for sGR. Moreover, their combination showed a better predictive accuracy. It is well known that sGR “predicts” poor perinatal outcome, both short-term and long-term. sGR might be, in a wider sense, an alternative endpoint, and the primary endpoint should be perinatal outcome if one considers the overall welfare of MCDA twins. There were no clear links for the predictive value for perinatal outcomes of the present data, but a theoretical foundation for early diagnosis of sGR was provided, which may improve perinatal outcome indirectly.

MCDA twin pregnancies have unique placental anatomy, with the fetal circulations conjoined in a single placenta. sGR is an adverse outcome of unequal placental “territory sharing” and inter-twin vascular anastomoses [21,22]. Abnormal PCI site is very common (66.4%) in MCDA twin pregnancies and is known to be strongly associated with sGR [20]. However, in this study, no significant difference in PCI site was observed between controls and sGR twins, suggesting that although the discordant PCI is very common in twin pregnancies, it is non-specific to sGR. Since the etiology of sGR lies in understanding the impact and effects of the utero-placental perfusion on fetal well-being, detecting the placental vasculature and interdependent fetal circulation is crucial. Therefore, quantification of the real-time utero-placental perfusion in sGR is worth exploring.

In our study, VI, FI, and VFI derived by 3DPD could sensitively depict the subtle changes of utero-placental perfusion with subtle birthweight discordance prior to a diagnosis of sGR, while MCA and DV were less sensitive in predicting deterioration. This may be explained by the fact that 3DPD is capable of evaluating small vessels with low flow velocity without angle dependence, which is a proven strength of 3DPD over conventional flow assessment [23]. The results of this study are consistent with those of a previous study conducted by Sun et al. [17], which used 3DPD to monitor the placental perfusion of sGR twins and found that the vascular indices of VI, FI, and VFI could sensitively display the varying degrees of change in the placental perfusion.

A recent study investigating the placental vascular indices between normal MCDA and dichorionic-diamniotic twin pregnancies reported a strong linear correlation between the placental vascular indices and birthweight in both twin groups [24]. In our study, a significant relationship was observed between the birthweight discordance and the co-twin utero-placental perfusion discordance as assessed by both 3DPD and conventional Doppler, which was unaffected by GA. This suggests

that sGR might be better evaluated by assessing co-twin discordance rather than by the exact perfusion indices alone, as the conventional Doppler indices may be GA-dependent, although the 3DPD vascular indices did not change with GA in our study. Together, our results suggest that 3DPD vascular indices might be sufficiently predictive for the early detection of co-twin birthweight discordance.

Additionally, the FI discordance and CPR discordance were correlated with the birthweight discordance and showed predictive accuracy for sGR. The FI discordance, representing unbalanced blood transportation, accurately distinguished sGR from twins with normal growth. This may be explained by the smaller twin suffering from unbalanced placental hemodynamics, leading to a significant reduction in the amount of transported blood cells. The CPR has been reported as an excellent marker of fetal compromise, and, in particular, is secondary to the placental insufficiency and hypoxemia [25]. Moreover, our result demonstrated that CPR discordance combined with FI discordance showed a better predictive accuracy for sGR, suggesting that their combination has an incremental value and may be used for early detection in pregnancies with a high risk of sGR.

The results from this study showed no association between the utero-placental perfusion and the GA, suggesting that the number of vessels and the blood flow may increase proportionally to the placental volume, thus maintaining a constant utero-placental perfusion throughout gestation. This result was contradictory to some previous studies [17,26], but consistent with other recent findings [10,27,28]. The contradiction may be explained by the lack of uniform standards used to measure placental perfusion, especially the sample volume and sample numbers. In our study, because completely separating the placental territories was too difficult, the utero-placental perfusion surrounding the 3–5 cm area of the umbilical cord insertion was used to represent the entire placenta, and this method demonstrated valid reproducibility. Overall, the literature [9] supports sampling the entire area of the visualized placenta when possible, which is in agreement with our study.

The strengths of our study include our comparison group and the novel, non-invasive, and economical modality for real-time quantification of the maternal utero-placental perfusion. 3DPD acquisition, which only takes 5 to 15 s, can be promptly and easily performed by a sonographer. The time cost for analysis would be less with increasing proficiency, although the VOCAL technique used for data after analysis required time and expertise. To the best of our knowledge, this is the first study to quantify the maternal utero-placental perfusion and the co-twin utero-placental perfusion discordance assessed by both 3DPD and conventional Doppler. In the future, 3DPD ultrasound with VOCAL technique might be used as a promising screening tool in high-risk populations of sGR.

Certain limitations also exist in the present study. First, there was no assessment of the impact of the placental location on the 3DPD utero-placental perfusion results because a reduction in each index occurs as the distance between the transducer and the vessel increases [29], although other studies [11,27] showed no association between the placental vascular indices and placental position. Second, we did not evaluate the utero-placental perfusion in the first trimester because identifying the main stem of the placental tertiary villi by 3DPD in the first trimester remains challenging. In fact, early budding of the intermediate villi can be seen using 3DPD at 18 weeks of gestation [30]; therefore, we investigated the intermediate villi after 18 weeks of gestation. Finally, we just analyzed the data at the time of first diagnosis of sGR at our center (a tertiary referral center for the care of complicated twin pregnancies). However, most pregnancies with sGR were referred from other hospitals, so we could not collect the actual first-time 2D Doppler and 3DPD utero-placental perfusion data or the serial data. On the other hand, this design leads to the inherent risk of selection bias and the high prevalence of sGR.

## References:

- Valsky DV, Eixarch E, Martinez JM et al: Selective intrauterine growth restriction in monochorionic twins: pathophysiology, diagnostic approach and management dilemmas. *Semin Fetal Neonatal Med*, 2010; 15: 342–48
- Bennasar M, Eixarch E, Martinez JM, Gratacos E: Selective intrauterine growth restriction in monochorionic diamniotic twin pregnancies. *Semin Fetal Neonatal Med*, 2019; 22: 376–82
- Townsend R, D'Antonio F, Sileo FG et al: Perinatal outcome of monochorionic twin pregnancies complicated by selective fetal growth restriction according to management: A systematic review and meta-analysis. *Ultrasound Obstet Gynecol*, 2019; 53: 36–46
- Breathnach FM, McAuliffe FM, Geary M et al: Definition of intertwin birth weight discordance. *Obstet Gynecol*, 2011; 118: 94–103
- Khalil A, Rodgers M, Baschat A et al: ISUOG Practice Guidelines: Role of ultrasound in twin pregnancy. *Ultrasound Obstet Gynecol*, 2016; 47: 247–63
- Rustico MA, Consonni D, Lanna M et al: Selective intrauterine growth restriction in monochorionic twins: changing patterns in umbilical artery Doppler flow and outcomes. *Ultrasound Obstet Gynecol*, 2017; 49: 387–93
- Chang YL, Chang SD, Chao AS et al: Placenta share discordance and umbilical artery Doppler change after antenatal betamethasone administration in monochorionic twins with selective intrauterine growth restriction: Is there a link? *Twin Res Hum Genet*, 2012; 15: 680–84
- Mihu CM, Drugan T, Mihu D: Contribution of 3D power Doppler ultrasound to the evaluation of placental circulation in normal pregnancies and pregnancies complicated by preeclampsia. *J Perinat Med*, 2012; 40: 359–64
- Yamasato K, Zalud I: Three-dimensional power Doppler of the placenta and its clinical applications. *J Perinat Med*, 2017; 45: 693–700
- Moran MC, Mulcahy C, Zombori G et al: Placental volume, vasculature and calcification in pregnancies complicated by pre-eclampsia and intra-uterine growth restriction. *Eur J Obstet Gynecol Reprod Biol*, 2015; 195: 12–17
- Molnar A, Suranyi A, Nyari T et al: Examination of placental three-dimensional power Doppler indices and perinatal outcome in pregnancies complicated by intrauterine growth restriction. *Int J Gynaecol Obstet*, 2015; 129: 5–8
- Suranyi A, Altorjay A, Kaiser L et al: Evaluation of placental vascularization by three-dimensional ultrasound examination in second and third trimester of pregnancies complicated by chronic hypertension, gestational hypertension or pre-eclampsia. *Pregnancy Hypertens*, 2017; 8: 51–59
- Cali G, Foti F, Minneci G: 3D power Doppler in the evaluation of abnormally invasive placenta. *J Perinat Med*, 2017; 45: 701–9
- Khalil AA, Khan N, Bowe S et al: Discordance in fetal biometry and Doppler are independent predictors of the risk of perinatal loss in twin pregnancies. *Am J Obstet Gynecol*, 2015; 213: 222e1–10
- Stagnati V, Pagani G, Fichera A, Prefumo F: Intertwin discrepancy in middle cerebral artery peak systolic velocity and third-trimester fetal growth restriction in monochorionic-diamniotic twin pregnancy. *Ultrasound Obstet Gynecol*, 2016; 48: 66–71
- De Paepe ME, Shapiro S, Young L, Luks FI: Placental characteristics of selective birth weight discordance in diamniotic-monochorionic twin gestations. *Placenta*, 2010; 31: 380–86
- Sun W, Liu J, Zhang Y et al: Quantitative assessment of placental perfusion by three-dimensional power Doppler ultrasound for twins with selective intrauterine growth restriction in one twin. *Eur J Obstet Gynecol Reprod Biol*, 2018; 226: 15–20
- Gratacos E, Lewi L, Munoz B et al: A classification system for selective intrauterine growth restriction in monochorionic pregnancies according to umbilical artery Doppler flow in the smaller twin. *Ultrasound Obstet Gynecol*, 2007; 30: 28–34
- Hadlock FP, Harrist RB, Martinez-Poyer J: In utero analysis of fetal growth: A sonographic weight standard. *Radiology*, 1991; 181: 129–33
- Kalafat E, Thilaganathan B, Papageorghiou A et al: Significance of placental cord insertion site in twin pregnancy. *Ultrasound Obstet Gynecol*, 2018; 52: 378–84
- Lewi L, Cannie M, Blickstein I et al: Placental sharing, birthweight discordance, and vascular anastomoses in monochorionic diamniotic twin placentas. *Am J Obstet Gynecol*, 2007; 197: 587e1–8

## Conclusions

In conclusion, MCDA twin pregnancies with birthweight discordance presented utero-placental perfusion deterioration prior to diagnosis of sGR. Co-twin utero-placental perfusion discordance was related to the growth discordance, and it was more predictive of sGR when 3DPD was combined with conventional Doppler. The measurements run in our study provide a theoretical basis for early diagnosis and better management of sGR, such as determining the timing of termination of pregnancy, and selecting women who need closer monitoring. The value with respect to clinical management and evaluating the prognosis is the subject of an ongoing investigation.

## Acknowledgements

We gratefully acknowledge the technical assistance provided by Dr. Xueting Zhao, and the support from the “111 program” of the Ministry of Education P.R.C., and the State Administration of Foreign Experts Affairs P.R.C.

## Conflict of Interest

None.



22. Chang YL, Chang SD, Chao AS et al: Clinical outcome and placental territory ratio of monochorionic twin pregnancies and selective intrauterine growth restriction with different types of umbilical artery Doppler. *Prenat Diagn*, 2009; 29: 253–56
23. Merce LT, Barco MJ, Bau S et al: Assessment of placental vascularization by three-dimensional power Doppler “vascular biopsy” in normal pregnancies. *Croat Med J*, 2005; 46: 765–71
24. Altorjay AT, Nyari T, Gyurkovits Z et al: Evaluation of placental vascularization indices in monochorionic diamniotic and dichorionic diamniotic twin pregnancies. *Eur J Obstet Gynecol Reprod Biol*, 2018; 228: 225–31
25. Khalil AA, Morales-Rosello J, Morlando M et al: Is fetal cerebroplacental ratio an independent predictor of intrapartum fetal compromise and neonatal unit admission? *Am J Obstet Gynecol*, 2015; 213: 54e1–10
26. Zalud I, Shaha S: Evaluation of the utero-placental circulation by three-dimensional Doppler ultrasound in the second trimester of normal pregnancy. *J Matern Fetal Neonatal Med*, 2007; 20: 299–305
27. de Paula CF, Ruano R, Campos JA, Zugaib M: Quantitative analysis of placental vasculature by three-dimensional power Doppler ultrasonography in normal pregnancies from 12 to 40 weeks of gestation. *Placenta*, 2009; 30: 142–48
28. Pomorski M, Zimmer M, Fuchs T et al: Quantitative assessment of placental vasculature and placental volume in normal pregnancies with the use of 3D Power Doppler. *Adv Med Sci*, 2014; 59: 23–27
29. Raine-Fenning NJ, Nordin NM, Ramnarine KV et al: Determining the relationship between three-dimensional power Doppler data and true blood flow characteristics: An *in-vitro* flow phantom experiment. *Ultrasound Obstet Gynecol*, 2008; 32: 540–50
30. Campbell S: Placental vasculature as visualized by 3D power Doppler angiography and 3D color Doppler imaging. *Ultrasound Obstet Gynecol*, 2007; 30: 917–20