



Contents lists available at ScienceDirect

## International Journal of Surgery Case Reports

journal homepage: [www.casereports.com](http://www.casereports.com)

## Distal pancreatectomy after pancreatic injury, in two pediatric patients

Theodoros Hadjizacharias<sup>b,\*</sup>, Ioannis Kaliviotis<sup>a</sup>, George Kottakis<sup>a</sup>, Orestis Pavlides<sup>a</sup>, Dimitra Papalouka<sup>b</sup>, Andreas Polydorou<sup>b</sup><sup>a</sup> 1st Department of Pediatric Surgery, Panagioti kai Aglaia Kyriakou Pediatric Hospital, Athens, Greece<sup>b</sup> 2nd Department of Surgery, Aretaieion University Hospital, Medical School, National and Kapodistrian University of Athens, Greece

## ARTICLE INFO

## Article history:

Received 2 August 2020

Received in revised form

30 September 2020

Accepted 1 October 2020

Available online 7 October 2020

## Keywords:

Case report

Children

Blunt abdomen trauma

Pancreatic injury

Pancreatic surgery

Main pancreatic duct

## ABSTRACT

**INTRODUCTION:** Although serious trauma is rare in pediatric patients, the management of blunt force trauma to the abdomen remains a challenge for Child Surgery Departments. Pancreatic injury comprises the fourth most common injury among the solid organs and cases accompanied by rupture of the main pancreatic duct (MPD) present a further challenge for physicians (Fayza Haider et al.; Wood et al., 2010; Jobst et al., 1999; Grosfeld et al., 2006).

**CASE PRESENTATION:** Two adolescents, both 13 years old, were referred to our Pediatric Hospital, due to blunt force abdominal trauma. During admission, both patients were hemodynamically stable, in good general condition but suffering from abdominal pain and vomiting. After a full diagnostic check-up, grade IV pancreatic injury was diagnosed in both patients and they were taken to the operation room 3 and 6 days post-injury. Intra-operatively a distal pancreatectomy along with splenectomy was performed in both cases, with catheterization and ligation of the main pancreatic duct. Both patients were admitted to the pediatric ICU for 2 and 4 days. Both made an uneventful recovery and remain well 6 months postoperatively.

**CONCLUSION:** While hemodynamically stable, patients with Grade IV pancreatic injury, benefit from sub-acute management, allowing for planning of the surgical intervention. Distal pancreatectomy with splenectomy, along with catheterization and ligation of the main pancreatic duct, has excellent post-operative results.

The chief of the Pediatric Hospital, said that in 35 years at pediatric surgery, is the first time with the need of operative management, in pancreatic injury. The hepatobiliary surgical expert in adults, who was consulted in both cases, said that without the surgeries, both children were going to die.

© 2020 Published by Elsevier Ltd on behalf of IJS Publishing Group Ltd. This is an open access article under the CC BY-NC-ND license (<http://creativecommons.org/licenses/by-nc-nd/4.0/>).

## 1. Introduction

Pancreatic injuries are very rare, with an incidence of 0.4% in both adult and pediatric populations. In children with severe abdominal blunt trauma, the pancreas is involved in up to 10% of cases and morbidity in these cases, can reach up to 60% [1–4].

The diagnosis of pancreatic trauma, remains challenging. The use of US FAST, reduces the number of computed tomography scans. However, if a CT is needed, intravenous contrast can achieve diagnosis, without the need for oral contrast [5,6].

Pancreatic classification can be done in a number of ways. Computed tomography (CT) and endoscopic retrograde cholangiopan-

creatography (ERCP) grading, is used for precise management. The American Association for the surgery of trauma, classification of pancreatic trauma, classifies such trauma into four grades, according to the laceration and its anatomy, as shown in CT [7,8].

Studies show that in moderate to severe pancreatic injury, specifically over grade 3, and bicycle accidents, were associated with the need for surgical management. The status of the pancreatic duct, is a key decision-making element that determines grade and plays an important role in management. Surgical management is reserved for those with a ductal injury [9,10].

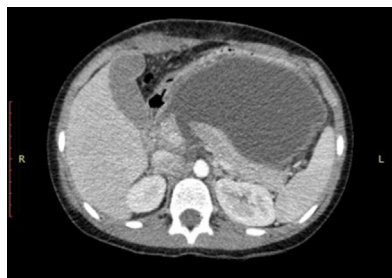This case report, describes the surgical management of two adolescents, with blunt abdominal trauma and complete main pancreatic duct disruption (Fig. 1).

## 2. Case presentation

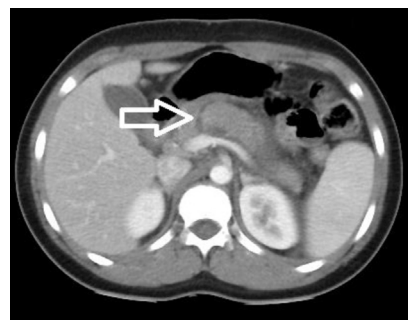The first case is a 13-year-old boy, who was referred to our hospital from a regional hospital. He had a blunt force trauma

\* Corresponding author.

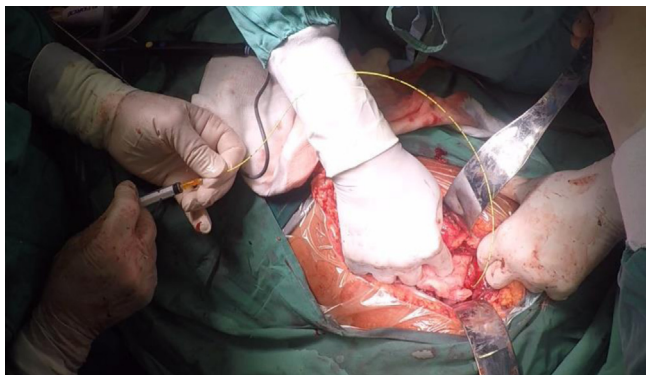
E-mail addresses: [theodoros.hadjizacharias@gmail.com](mailto:theodoros.hadjizacharias@gmail.com) (T. Hadjizacharias), [pedisurg.kaliviotis@gmail.com](mailto:pedisurg.kaliviotis@gmail.com) (I. Kaliviotis), [george.180@hotmail.com](mailto:george.180@hotmail.com) (G. Kottakis), [orepavlides@gmail.com](mailto:orepavlides@gmail.com) (O. Pavlides), [dottdem@windowslive.com](mailto:dottdem@windowslive.com) (D. Papalouka), [apolyd@med.uoa.gr](mailto:apolyd@med.uoa.gr) (A. Polydorou).



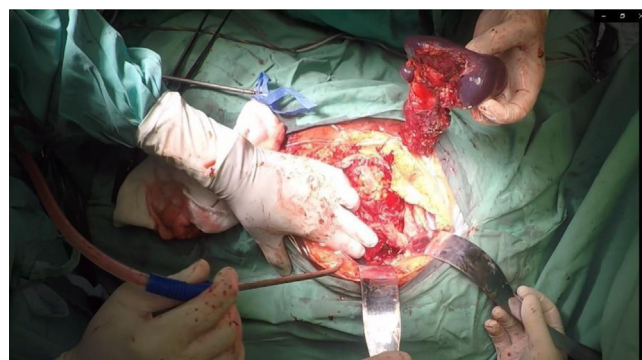
**Fig. 1.** Axial post-intravenous contrast-enhanced computed tomography scan shows grade IV pancreatic trauma in a 13-year-old boy with blunt abdominal trauma.



**Fig. 3.** Axial post-intravenous contrast-enhanced computed tomography scan, shows grade IV pancreatic trauma (white arrow) in a 13-year-old boy with blunt abdominal trauma.



**Fig. 2.** Stent into the main pancreatic duct, in a 13-year-old boy with pancreatic trauma.



**Fig. 4.** Intraoperative image of distal pancreatectomy and splenectomy.

to the abdomen, from a bike's handlebar, after a fall from his bicycle 2 days before referral. He presented with abdominal pain, vomiting and fever. Upon arrival at our Emergency Department (ER), the patient was hemodynamically stable, alert and orientated. During the examination, a coin like bruise, to the right hypochondriac region, was identified. While still in the ER, a US F.A.S.T. was performed, where rupture of the pancreas, with associated fluid collection was diagnosed.

On admission, blood tests were as shown in [Table 1](#). Intra Venus antibiotic therapy was initiated on admission and during the days which followed, further diagnostic checks were performed, including an abdominal U/S which confirmed pancreatic injury and showed further accumulation of fluid collection. An abdominal CT led to the categorization of the injury as Grade IV pancreatic injury, according to the American Association of Surgery for Trauma–Organ Injury Score. The patient was taken to the OR, on the 7<sup>th</sup>-day post-injury, while still stable. Intra-operatively, the pancreatic rupture was confirmed and the fluid collection was drained and sent for laboratory testing and culture. Distal pancreatectomy and splenectomy were performed. The splenectomy was decided, because the splenic vein was injured. The central pancreatic duct was identified, a stent (5 Fr 3 cm Pancreatic stent Cook Medical), was inserted and subsequently the duct was ligated. The coin-like injury in the right hypochondrium region was explored and was found to be a laceration that extended all the way through the peritoneum. The laceration was sutured ([Fig. 2](#)).

Post-operatively, the patient was transferred to the pediatric ICU, where he was monitored for 4 days. The post-operative period, was uneventful and the patient was discharged with normal laboratory tests. He remains well and without the need for insulin therapy, 6 months after the injury ([Fig. 3](#)).

The second case, is also a 13-year-old boy who was referred to our hospital, due to blunt force trauma to the abdomen, following an approximate 2-meter fall. He presented with abdominal

pain and vomiting. Upon arrival at our Emergency Department, the patient was hemodynamically stable, alert and orientated. Before admission, a U/S F.A.S.T. was performed, which showed pancreatic injury. On admission, blood tests were as shown in [Table 2](#). In the first 24 h after admission, serum amylase was raised to 1363 and serum lipase was 7739. After further diagnostic testing, with an MRCP and an abdominal CT, a Grade IV pancreatic injury was diagnosed. Intra Venus antibiotic treatment was prescribed and on the 3<sup>rd</sup>-day post-injury (2<sup>nd</sup> from admission), the patient was led to the OR, while still stable. Intra-operatively, a pancreatic rupture was identified on the right of the superior mesenteric vessels. Peritoneal fluid was drained and sent for laboratory testing and culture. Distal pancreatectomy and splenectomy were performed. The central pancreatic duct was identified. A stent, 5 Fr single pigtail pancreatic stent (Cook Medical LLC Bloomington USA), was inserted into it and the duct was ligated. Post-operatively, the patient was transferred to the Pediatric ICU, where he was monitored for 2 days. He was administered total parenteral nutrition for 11 days. The post-operative period, was uneventful and the patient was discharged with normal laboratory tests. He presented weakness and a drop of the left foot, and an injury of the O5 spinal nerve root was identified, for which the patient was referred to a neurologist and a neurosurgeon. The patient remains well and without the need of insulin therapy, 6 months after the injury ([Fig. 4](#)).

### 3. Discussion

Pancreatic injury represents 0.3% of all pediatric traumas, presenting to national trauma data bank centers and 0.6% of significant abdominal trauma. Pancreatic trauma remains a morbid condition, with a mortality rate of 5% and major complications affecting approximately 1 in 4 children. Nearly 25% of patients undergo a pancreas-specific operation, as part of their management! Pancre-

**Table 1**  
Monitored blood investigations, during the first week, until follow-up after abdominal trauma with pancreatic rupture in the first case.

TEST	D1	D2	D5	D6	D7	D10	D11	W1	M2
Hemoglobin (13.5–17.5 g/dL)	10.8	11.2	10.6	10.4	9.5	10.3	9.4	10.6	11.4
White blood cells count (4.5–13 × 10 <sup>9</sup> /L)	11.42	17.5	15.3	21.2	18.2	31.9	19	13.8	7.4
Platelets (130–400 × 10 <sup>9</sup> /L)	277	228	307	304	295	280	608	918	489
Glucose (70–100 mg/dl)	112	107	115	100	104	117	134	108	93
Alkaline phosphatase (<500 U/L)	258		168	169	167	126	112		264
Alanine amino transferase (<45 U/L)	94	47	22	15	11	46	18	14	28
G-glutamyl transferase (<45U/L)	17	9	13	15	20	19	15		14
Amylase (15–100 U/L)	699	828	259	316	400	283	211	258	54
Amylase of peritoneum						236	83		
HBA1C									55

**Table 2**  
Monitored blood investigations, during the first week until follow-up after abdominal trauma with pancreatic rupture in the second case.

TEST	D1	D2	D2 after OR	D4	D6	W1	W2	W3	M2
Hemoglobin (13.5–17.5 g/dL)	14.3	15.7	13.5	12.6	12.9	13.5	14.2	14.6	14.1
White blood cells count (4.5–13 × 10 <sup>9</sup> /L)	11.4	10.5	9.1	11.6	11.6	15.6	9.9	6.6	7.3
Platelets (130–400 × 10 <sup>9</sup> /L)	249	245	268	314	416	530	820	804	383
Glucose (70–100 mg/dl)	112	88	1406	134	241	109	87	87	
Alkaline phosphatase (<500 U/L)	350		215	187				197	
Alanine aminotransferase (<45 U/L)	84	48	33	35	33	27	41	37	37
G-glutamyl transferase (<45U/L)	9		10	9	15	29		22	14
Amylase (15–100 U/L)	262	1363	721	104	78	97	80	57	
Amylase of peritoneum			236	340	84				
HBA1C									5.7

atic head injuries, were associated with nonoperative management [9].

Although infrequently injured, the pancreas is the fourth most common site of solid organ injury. The mechanism of injury, most often comprises of fracture of the pancreas, over the spinal column.

There is extensive discussion, about the management of pancreatic injuries. The debate is between operative vs nonoperative management. Some authors concluded that outcomes are better for those children suffering a traumatic blunt pancreatic injury, managed nonoperatively, compared with both operative and “delayed operative” management. A key decision-making element in appropriate management of pancreatic injuries, is the status of the main pancreatic duct. Operative management is reserved, for those with main duct injury, such as in our case [9]. Serum amylase levels must be included in laboratory exams at admission, for all children with blunt abdominal trauma. However, the serum amylase may not be diagnostic during the first 4 h after trauma. For this reason, we must repeat amylase values, except if an immediate laparotomy is needed. An indication that it is necessary to repeat serum amylase, is if the abdominal pain worsens.

In both cases, reported in this article, the initial diagnosis was set during admission to the ER, with a U/S F.A.S.T. The stable condition of both patients, allowed time for further imaging studies. An abdomen CT scan with iv contrast, is the preferred method of diagnosis and classification of pancreatic injuries. One of the patients, was also subjected to an MRCP, for further verification of the diagnosis. Endoscopic retrograde cholangiopancreatography, may serve as a useful diagnostic modality, for guiding operative vs nonoperative management decisions [2]. The emergent use of ERCP in children, has not been widely implemented, due to a perceived risk of performing ERCP on young patients [3] and the risk of pancreatitis and infections.

Pancreatic injuries are classified into five grades, in accordance with the Pancreas Injury Scale published in 1990 by the American Association for the Surgery of Trauma. In our cases both injuries, were classified as Grade IV, with rupture of the pancreas and the main pancreatic duct, resulting in intraperitoneal fluid accumulation and a need for surgical management. A hepatobiliary surgical expert in adults, was consulted in both cases, as such injuries are

extremely rare in pediatric patients. The expert (AP) carried out both operations.

Intra-operatively, apart from the removal of the injured distal part of the pancreas, the spleen was removed. The temporary catheterization of the main pancreatic duct, with a stent that is expected to pass with the stool after a few days, was very useful. This helps alleviate the build-up of pressure in the duct, during the first few days and helps avoid leaks.

Post-operatively, while on total parenteral nutrition, one of the patients presented a need for insulin therapy, which subsided when per os nutrition was commenced. Both patients remain well 6 months after the injury. They are regularly tested and do not need insulin therapy.

**Declaration of Competing Interest**

The authors report no declarations of interest.

**Funding**

There are not any sources of funding for our research.

**Ethical approval**

This is a case report, not a research study, so there is no number of ethical approval.

**Consent**

Written informed consent was obtained from the parents of the patients for publication of this case report and accompanying images. A copy of the written consent is available for review by the Editor-in-Chief of this journal on request.

**Author contribution**

The authors Ioannis Kaliviotis, George Kottakis, Orestis Pavlides made the data collection and write some of the paper.

The author Theodoros Hadjizacharias, Andreas Polydorou and Dimitra Papalouka, made the data analysis and wrote the rest of the paper.

### Registration of research studies

N/A.

### Guarantor

The head of hepatobiliary and pancreatic department, Andreas Polydorou, professor of surgery and endoscopic surgery, medical school, national and Kapodistrian university of Athens.

### Scare criteria

This paper has been reported in line with the SCARE 2018 criteria [11].

### Provenance and peer review

Not commissioned, externally peer-reviewed.

### References

- [1] Fayza Haider, Mohammed Amin Al Awadhi, Eizat Abrar, Mooza Al Dossari, Hasan Isa, Husain Nasser, Hakima Al Hashimi, Sharif Al Arayedh, Pancreatic injury in children: a case report and review of the literature, *J. Med. Case Rep.* (2017) 11–217.
- [2] J.H. Wood, D.A. Partrick, J.L. Bruny, A. Saaia, S.L. Moulton, Operative vs nonoperative management of blunt pancreatic trauma in children, *J. Pediatr. Surg.* 45 (2010) 401–406.
- [3] M.A. Jobst, T.G. Canty, F.P. Lynch, Management of pancreatic injury in pediatric blunt abdominal trauma, *J. Pediatr. Surg.* 34 (1999) 818–823.
- [4] JayL. Grosfeld, James A. O'Neill Jr, Arnold G. Coran, Eric W. Fonkalsrud, *Pediatric Surgery*, 6th edition, Mosby, Inc, 2006.
- [5] D.M. Notrica, Pediatric blunt abdominal trauma, *Curr. Opin. Crit. Care* 21 (6) (2015) 531–537, <http://dx.doi.org/10.1097/mcc.0000000000000249>.
- [6] J. Menaker, S. Blumberg, D.H. Wisner, et al., Use of the focused assessment with sonography for trauma (FAST) examination and its impact on abdominal computed tomography use in hemodynamically stable children with blunt torso trauma, *J. Trauma Acute Care Surg.* 77 (2014) 427–432.
- [7] U. Debi, R. Kaur, K.K. Prasad, S.K. Sinha, A. Sinha, K. Singh, Pancreatic trauma: a concise review, *World J. Gastroenterol.* 19 (47) (2013) 9003–9011.
- [8] <http://www.aast.org/library/traumatools/injuryscoringscales.aspx#pancreas>.
- [9] B.R. Englum, B.C. Gulack, H.E. Rice, J.E. Scarborough, O.O. Adibe, Management of blunt pancreatic trauma in children: review of the National Trauma Data Bank, *J. Pediatr. Surg.* 51 (9) (2016) 1526–1531, <http://dx.doi.org/10.1016/j.jpedsurg.2016.05.003>.
- [10] M.E. Linnaus, D.M. Notrica, Evaluating the outcomes of operative vs nonoperative management of pediatric blunt pancreatic trauma, *J. Am. Coll. Surg.* 223 (2) (2016) 421, <http://dx.doi.org/10.1016/j.jamcollsurg.2016.05.005>.
- [11] R.A. Agha, M.R. Borrelli, R. Farwana, K. Koshy, A. Fowler, D.P. Orgill, For the SCARE Group, The SCARE 2018 statement: updating consensus surgical Case Report (SCARE) Guidelines, *Int. J. Surg.* 60 (2018) 132–136.

### Open Access

This article is published Open Access at [sciencedirect.com](https://www.sciencedirect.com). It is distributed under the [IJSCR Supplemental terms and conditions](#), which permits unrestricted non commercial use, distribution, and reproduction in any medium, provided the original authors and source are credited.