

Available online at www.sciencedirect.com

ScienceDirect

journal homepage: www.elsevier.com/locate/radcr

Case Report

Teres minor injury related to vaccine administration☆☆☆

Naveed Natanzi, DO^{a,*}, Frank Hebroni, MD^b, Marko Bodor, MD^c

^aThe Regenerative Sports and Spine Institute, 14332 Ventura Blvd., Sherman Oaks, CA 91423, USA

^bDepartment of Radiology, University of California, Los Angeles, CA 90024, USA

^cBodor Clinic, 3421 Villa Lane Suite 2B, Napa, CA 94558, USA

ARTICLE INFO

Article history:

Received 5 January 2020

Revised 13 February 2020

Accepted 14 February 2020

Keywords:

SIRVA

Vaccine injury

Teres minor injury

Subacromial bursitis

Shoulder injury

Rotator cuff tendinopathy

ABSTRACT

Shoulder injury related to vaccine administration is a relatively rare disorder, which occurs as a result of vaccine being inadvertently injected into the subdeltoid/subacromial bursa, rotator cuff, and or underlying bone. We present 2 cases of shoulder injury related to vaccine administration in 2 women of ages 38 and 42 with injury to the teres minor tendon insertions on magnetic resonance imaging, a location not previously described. When faced with a patient with chronic shoulder pain following a vaccination, the possibility of vaccine deposition or injury to the teres minor tendon insertion should be considered.

Published by Elsevier Inc. on behalf of University of Washington.

This is an open access article under the CC BY-NC-ND license.

(<http://creativecommons.org/licenses/by-nc-nd/4.0/>)

Soreness and pain after vaccination is common and usually resolves within a few days to a couple of weeks. Shoulder injury related to vaccine administration (SIRVA), by comparison, is a musculoskeletal disorder that develops following a vaccination and results in prolonged pain and dysfunction.

SIRVA was first described by Bodor and Montalvo in 2006 in 2 patients who developed subacromial bursitis, bicipital tendinitis, and adhesive capsulitis following influenza and pneumococcal vaccinations. [1]. Since then, over 50 SIRVA cases have been reported in the medical literature [1–14]

SIRVA occurs rarely but is the number one vaccine-related problem for which petitioners seek compensation through the federal no-fault Vaccine Injury Compensation Program. In 2011, there were 7 claims brought before the Vaccine Injury Compensation Program related to SIRVA, whereas in 2016 there were 446. [15].

SIRVA is defined by the Health Resources & Services Administration as shoulder pain with limited range of motion (ROM) occurring within 48 hours following a vaccination in someone with no prior history of pain, inflammation, or dysfunction of the affected shoulder.

* We have obtained written correspondence from our two patients acknowledge use of their clinical history in our case series.

** Funding: None.

* Acknowledgments: Napa Medical Research Foundation.

* Corresponding author.

E-mail addresses: natanzi@trssi.com (N. Natanzi), fhebroni@gmail.com (F. Hebroni), mbodormd@sbcglobal.net (M. Bodor).

<https://doi.org/10.1016/j.radcr.2020.02.009>

1930-0433/Published by Elsevier Inc. on behalf of University of Washington. This is an open access article under the CC BY-NC-ND license. (<http://creativecommons.org/licenses/by-nc-nd/4.0/>)

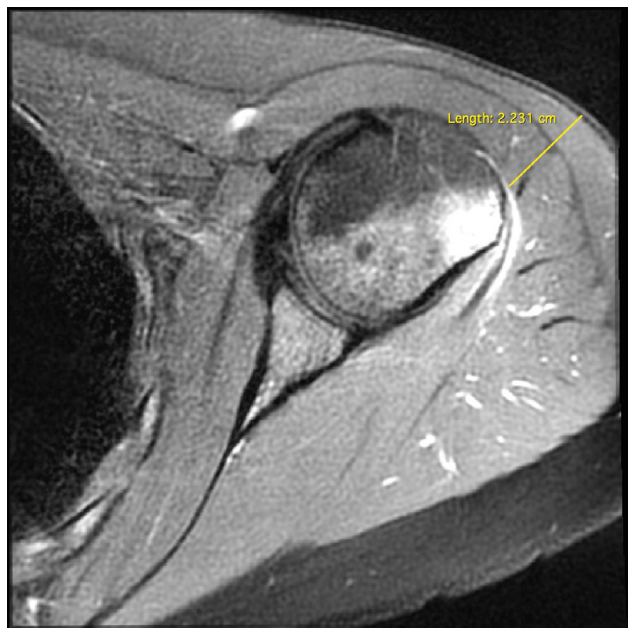


Fig. 1 – Case 1. Axial proton-density T2-weighted fat-saturated MRI demonstrating humeral head edema. Yellow line measures the estimated distance between the humeral head and skin surface.

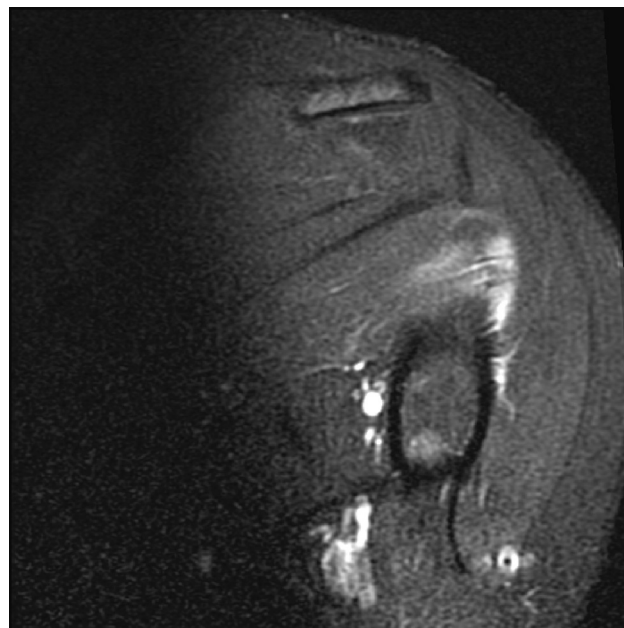


Fig. 2 – Case 1. Coronal T2-weighted fat-saturated MRI demonstrating increased signal in the distal teres minor tendon, which is consistent with tendinopathy.

SIRVA injuries most commonly present with rotator cuff tendinopathy and/or subacromial bursitis. There have been case reports involving the supraspinatus [7,13] subscapularis [3], and infraspinatus tendons [5]. Szari et al described a case of SIRVA with magnetic resonance imaging (MRI) evidence of tendinopathy in all four rotator cuff tendons and possible calcific tendinopathy of the teres minor [8]. We present 2 cases of SIRVA with isolated teres minor pathology accompanied with humeral head edema.

Case 1

A 42-year-old female with no history of musculoskeletal pain described immediate pain in her left shoulder during an influenza vaccination, which persisted and peaked over the next 72 hours. At the time of her vaccination, her left arm was resting by her side. She was seated while the person doing the vaccination was standing. The exact location of injection to the left deltoid muscle was not recorded, although she recalls it was perhaps higher than she was accustomed to in the past. There was no information on the length of the needle used. Physical examination 7 weeks postvaccination revealed weakness and limitation of ROM with signs of impingement and tenderness at the proximal humerus. An MRI of the left shoulder 12 weeks after the vaccination revealed edema (Fig. 1) at the teres minor tendon insertion and underlying humerus (Fig. 2).

Case 2

A 38-year-old female with no history of musculoskeletal pain described pain immediately following an influenza vaccination to her left arm. At the time of her vaccination, her arm was resting by her side. She was seated while the person doing the vaccination was standing. The exact location of injection to the left deltoid muscle was not recorded, nor was there information describing the length of the needle used. Physical examination 2 months after the vaccination revealed shoulder tenderness, swelling, and an inability to raise or extend her arm without pain and signs of impingement. An MRI of the left shoulder a week later demonstrated edema in the humerus (Fig. 3) and at the teres minor tendon insertion and underlying humerus (Fig. 4). MR arthrogram 3 years postvaccination revealed resolution of edema in the teres minor tendon and humerus.

Discussion

SIRVA occurs as a result of a vaccine needle inserted too high and too deep, specifically at the top third of the deltoid muscle, penetrating through the muscle into the subdeltoid/subacromial bursa, the rotator cuff, and/or underlying bone. In the presence of a full-thickness rotator cuff tear, vaccine injected into subdeltoid/subacromial bursa can end up in the glenohumeral joint. Subsequently, the vaccine interacts with antibodies from a prior vaccination resulting in a robust

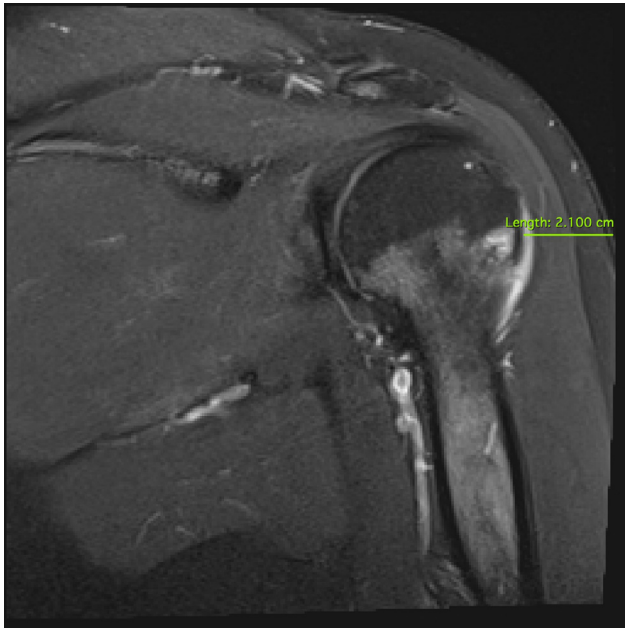


Fig. 3 – Case 2. Short tau inversion recovery (STIR) coronal MRI sequence demonstrating focal humeral head edema. Green line measures the distance between the humeral head and skin surface.

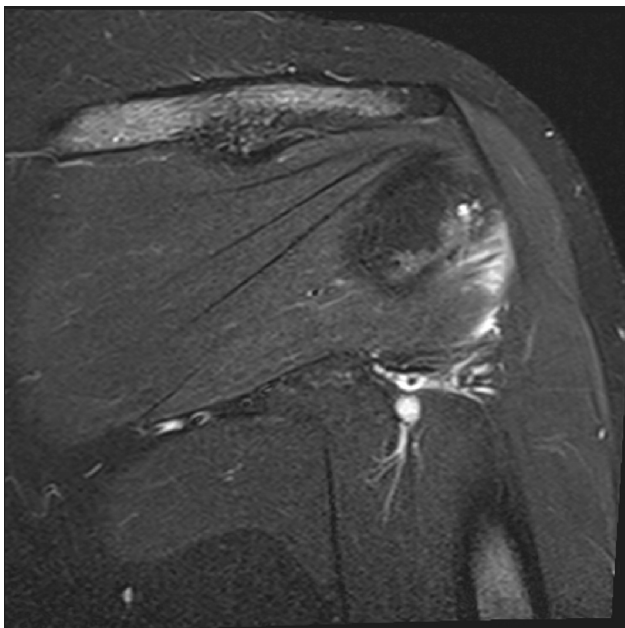


Fig. 4 – Case 2. STIR coronal MRI sequence demonstrating increased signal in the distal teres minor tendon consistent with edema and or tendinopathy.

inflammatory response and a range of findings including pain [1–15], loss of ROM [1–15], subacromial bursitis [1–3, 7,10–13], and rotator cuff tendinopathy [3,5,7,8,13]. SIRVA often leads to adhesive capsulitis [1,14].

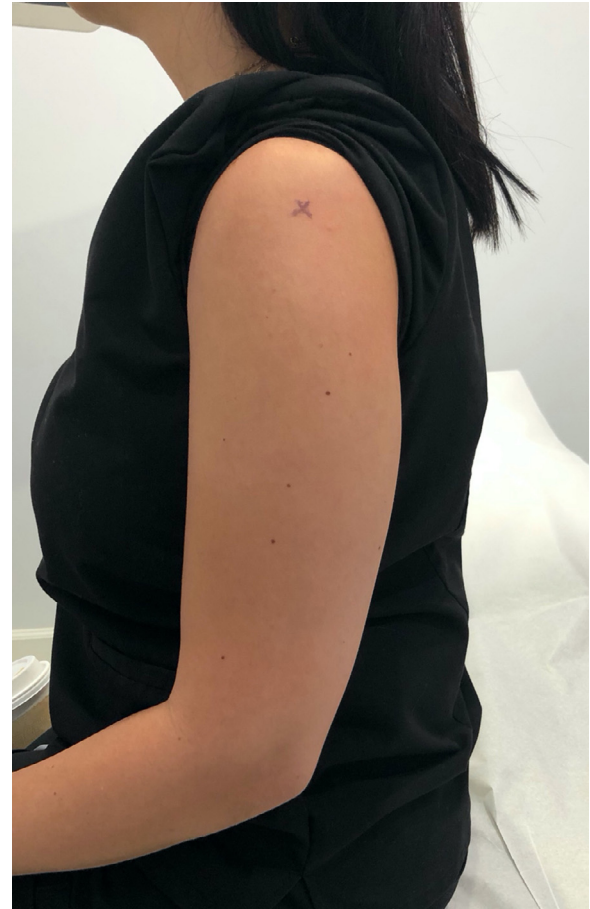

Fig. 5 – The “X” marks the site of the teres minor tendon insertion under the upper third of the deltoid muscle in a healthy individual.

The teres minor is one of the 4 rotator cuff muscles, which has its origin on the lateral border of the scapula and inserts onto the inferior facet of the greater tubercle of the humerus. While seated or standing with the arm at one's side, the teres minor insertion is located precisely laterally on the shoulder, just below the infraspinatus insertion, vulnerable to a vaccination needle placed too high and too deep.

We hypothesize that in our 2 presented cases this was exactly what had occurred, resulting in vaccine injection within the teres minor tendon insertions and periosteum of the humeral head.

Bodor and Montalvo, in their case series, noted that the distance between the skin and subacromial bursa was 0.8 to 1.6 cm [1] in a cohort of healthy volunteers. In our first and second cases, the distances from the skin to the site of humeral head edema were 2.2 and 2.1 cm, respectively (Figs. 1 and 3). As such, given that a typical vaccine needle is 1” (2.54 cm), over-penetration could have easily occurred in our 2 cases and this does not take into account the possibility of compression of the soft tissues, which would allow even greater penetration.

The risk of a SIRVA injury is reduced if both the patient and vaccinator are seated; the patient's clothing is pulled up from

below thus exposing the lower part of the deltoid rather than being pulled down from the neck, which exposes the upper part. Furthermore, the risk can be reduced if the arm being injected is positioned in such a way that the hand is placed on the hip, thus abducting the shoulder approximately 60°, and the target injection site is in the deltoid muscle midway between the acromion and the its insertion at the mid-humerus avoiding top third of the muscle [13]. Fig. 5 marks the location of the teres minor insertion on the skin as mapped out by ultrasound (image not shown) in a healthy unaffected 30-year-old female. This image demonstrated the tendon insertion point, which lies in the upper top third of the deltoid—an area highly susceptible to overpenetration and a SIRVA injury. In both of our cases, suboptimal positioning occurred during vaccination, which likely contributed to overpenetration and SIRVA injury.

In summary, SIRVA is a rare but emerging problem that can cause long-term pain and disability and can occur as a result of incorrect vaccine needle placement and injection in the shoulder. We present 2 cases with teres minor pathology, a location not previously described. In the setting of a patient with chronic shoulder pain following a vaccination, diagnosticians and treating physicians should have a high index of suspicion for vaccine deposition in or injury to the teres minor tendon insertion, which lie precisely lateral and underneath the upper third of the deltoid muscle.

REFERENCES

- [1] Bodor M, Enoch M. Vaccination-related shoulder dysfunction. *Vaccine* 2007;25(4):585–7.
- [2] Arias LHM, Fadrique RS, Gil MS, Salgueiro-Vazquez ME. Risk of bursitis and other injuries and dysfunctions of the shoulder following vaccinations. *Vaccine* 2017;35(37):4870–6.
- [3] Wright A, Patel R, Motamedi D. Influenza vaccine-related subacromial/subdeltoid bursitis: a case report. *J Radiol Case Report* 2019;13(6):24.
- [4] McColgan BP, Borschke FA. Pseudoseptic arthritis after accidental intra-articular deposition of the pneumococcal polyvalent vaccine: a case report. *Am J Emerg Med* 2007;25(7):864–8e1.
- [5] Shahbaz M, Blanc PD, Domeracki SJ, Guntur S. Shoulder injury related to vaccine administration (SIRVA): an occupational case report. *Workplace Health Safety* 2019;67(10):501–5.
- [6] Erickson D, Brause B, Callahan L, Hannafin J. Lytic lesion in the proximal humerus after a flu shot: a case report. *JBJS Case Connector* 2019;9(3):e0248.
- [7] Barnes MG, Ledford C, Hogan K. A “needling” problem: shoulder injury related to vaccine administration. *J Am Board Family Med* 2012;25(6):919–22.
- [8] Szari MS, Belgard A, Adams K, Freiler J. Shoulder injury related to vaccine administration: a rare reaction. *Federal Practitioner* 2019;36(8):380.
- [9] Okur G, Chaney KA, Lomasney LM. Magnetic resonance imaging of abnormal shoulder pain following influenza vaccination. *Skeletal Radiol* 2014;43(9):1325–31.
- [10] Salmon JH, Geoffroy M, Eschard J, Ohl X. Bone erosion and subacromial bursitis caused by diphtheria–tetanus–poliomyelitis vaccine. *Vaccine* 2015;33(46):6152–5.
- [11] Uchida S, Sakai A, Nakamura T. Subacromial bursitis following human papilloma virus vaccine misinjection. *Vaccine* 2012;31(1):27–30.
- [12] Cook IF. Subdeltoid/subacromial bursitis associated with influenza vaccination. *Human Vaccines Immunotherapeutics* 2014;10(3):605–6.
- [13] Cook 2011 paper.
- [14] Degreef I, Debeer PH. Post-vaccination frozen shoulder syndrome. Report of 3 cases. *Acta Chirurgica Belgica* 2012;112(6):447–9.
- [15] Hesse EM, Atanasoff S, Hibbs B, Adegoke O, Ng C, Marquez P, et al. Shoulder injury related to vaccine administration (SIRVA): petitioner claims to the National Vaccine Injury Compensation Program, 2010–2016. *Vaccine* 2019.