



# The patellofemoral joint: from dysplasia to dislocation

Stefano Zaffagnini<sup>1,3</sup>

Alberto Grassi<sup>1,3</sup>

Gianluca Zocco<sup>2</sup>

Michele Attilo Rosa<sup>2</sup>

Cecilia Signorelli<sup>3</sup>

Giulio Maria Marcheggiani Muccioli<sup>1,3</sup>

- Patellofemoral dysplasia is a major predisposing factor for instability of the patellofemoral joint. However, there is no consensus as to whether patellofemoral dysplasia is genetic in origin, caused by imbalanced forces producing maltracking and remodelling of the trochlea during infancy and growth, or due to other unknown and unexplored factors.
- The biomechanical effects of patellofemoral dysplasia on patellar stability and on surgical procedures have not been fully investigated. Also, different anatomical and demographic risk factors have been suggested, in an attempt to identify the recurrent dislocators. Therefore, a comprehensive evaluation of all the radiographic, MRI and CT parameters can help the clinician to assess patients with primary and recurrent patellar dislocation and guide management.
- Patellofemoral dysplasia still represents an extremely challenging condition to manage. Its controversial aetiology and its complex biomechanical behaviour continue to pose more questions than answers to the research community, which reflects the lack of universally accepted guidelines for the correct treatment. However, due to the complexity of this condition, an extremely personalised approach should be reserved for each patient, in considering and addressing the anatomical abnormalities responsible for the symptoms.

**Keywords:** patella; dysplasia; dislocation; luxation; instability; knee

Cite this article: *EFORT Open Rev* 2017;2.

DOI: 10.1302/2058-5241.2.160081. Originally published online at [www.efortopenreviews.org](http://www.efortopenreviews.org)

## Introduction

Trochlear dysplasia is defined as a geometrical abnormality of the shape and depth of the trochlear groove mainly

at its proximal part, where the patella engages into the trochlea. This represents the main feature of the wider and less codified concept of patellofemoral dysplasia, together with patellar height abnormalities, axial and rotational malalignments and soft-tissue imbalances. In this regard, a strict correlation of proximal femoral anatomy and trochlear geometry have been reported, confirming the possible multi-directional factors involved in this dysplastic condition.<sup>1</sup>

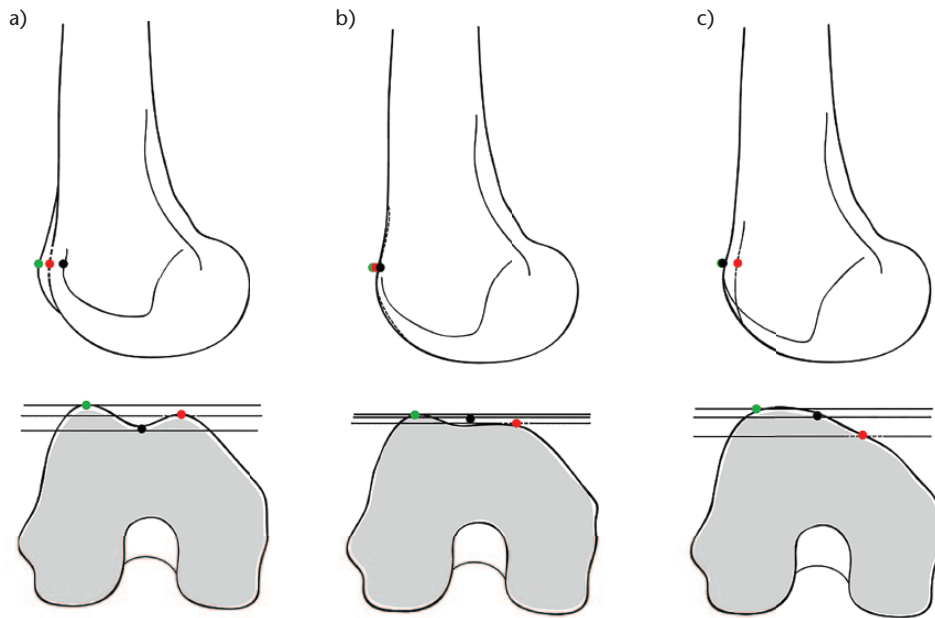
Patellofemoral dysplasia, despite being universally accepted as one of the most important factors in patellar instability, represents a challenging condition from the several points of view of aetiology, evaluation and management.

The aim of this narrative review is therefore to present an up-to-date overview of 'patellofemoral dysplasia', analysing the possible aetiology, the various aspects of evaluation and measurements, its biomechanical effects on knee kinematics and the natural history of dysplasia and dislocation. Finally, after proposing general guidelines for the management of acute and recurrent dislocation, the experience in this field of the Rizzoli Orthopaedic Institute is presented.

## Aetiology of dysplasia

Dysplasia of the femoral trochlea is a major predisposing factor for instability of the patellofemoral joint.<sup>2,3</sup> Considering joint development, it has been demonstrated that the cartilaginous trochlear angle is already shaped at birth, but that the osseous trochlea gains depth during adolescence.<sup>4</sup> However, there is no consensus as to whether patellofemoral dysplasia is genetic in origin,<sup>5</sup> caused by unbalanced forces producing maltracking and remodelling of the trochlea during infancy and growth,<sup>4</sup> or due to other unknown and unexplored factors.

Some authors suggested that breech presentation is a possible predisposing factor for patellofemoral dysplasia.<sup>6</sup> Breech presentation, which is a well-known risk factor for



**Fig. 1** Radiographic features of patellofemoral dysplasia: a) normal deep trochlea; b) 'crossing sign' with a flat trochlea; c) 'double contour sign' with a convex trochlea.

hip dislocation,<sup>7</sup> has been demonstrated to be a recurrent feature in Scandinavian newborns with flat femoral trochlea. The authors, who measured the femoral sulcus angle with ultrasound, separated newborns with values higher or lower than  $159^\circ$  (a cutoff value based on previous ultrasonographic studies) and reported a 15-fold higher incidence of breech presentation in children with values  $> 159^\circ$ . The incidence rose to 45-fold if frank breech presentation with locked knee extension was considered. The authors suggested that the shape of the foetal femoral trochlea could be susceptible to the influence of mechanical forces, highlighting a moving knee with normal patellar tracking in the final stage of pregnancy as a vital condition to ensure normal anatomy. In fact, a foetus with space to kick and flex the lower limbs is believed to have a good prospect of developing an adequately deep femoral trochlea. Conversely, such a situation is not present in breech presentation, especially in those cases with extended knees.

A similar theory was suggested by Salzman et al<sup>8</sup> which imputed the reason for patellar dislocation in a below-knee amputee patient, to be the patellofemoral dysplasia produced by the lack of mechanical stimuli during the developmental years. The patient, who sustained a below-knee amputation at the age of 18 months followed by another 18 months of immobilisation, experienced an atraumatic patellar dislocation at the age of 16 years, due to a grade C trochlear dysplasia according to Dejour and Walch,<sup>2</sup> compared with a perfectly shaped patellofemoral joint in the contralateral knee. This concept finds some confirmation in animal models, in which

an artificially malpositioned patella during growth constrained physiological trochlear sulcus development in terms of depth when compared with controls.<sup>9</sup>

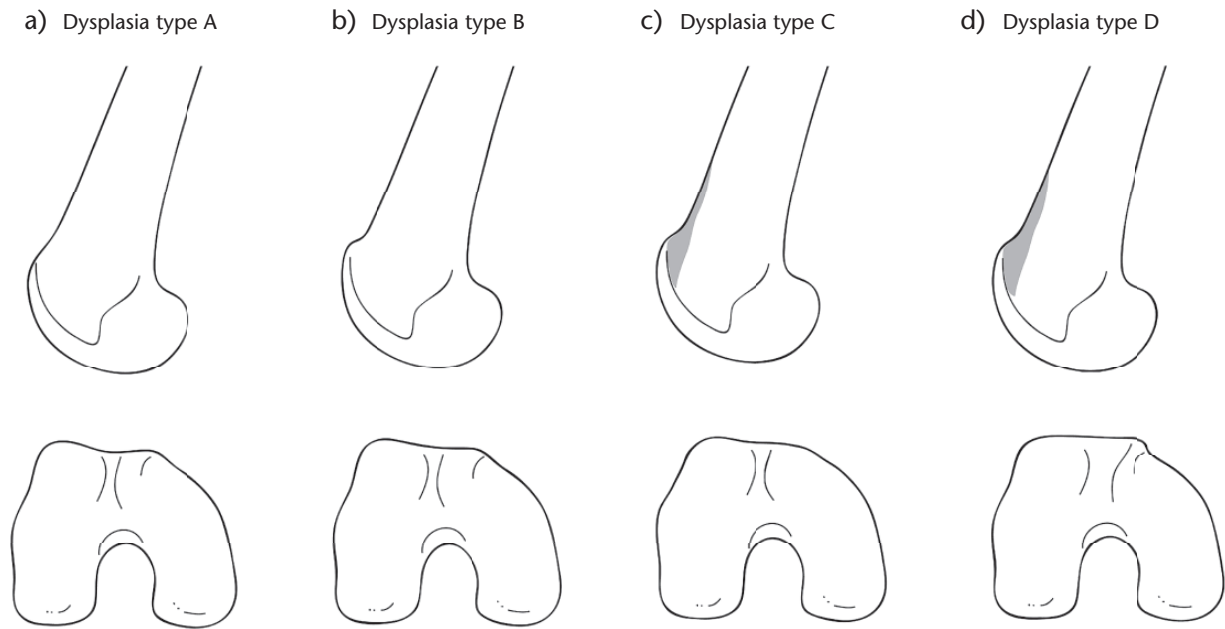
Despite these interesting and fascinating theories, the exact aetiology of patellofemoral dysplasia remains unknown.

### Evaluation of dysplasia

One of the most authoritative methods of evaluating patellofemoral dysplasia, and probably the most used in the International literature, is the four-grade classification of the Lyonese School of Henry and David Dejour.<sup>2</sup>

The three radiographic signs on a true lateral radiograph that characterise dysplastic joints are: (1) the 'crossing sign', which is when the line of the trochlear sulcus crosses the anterior outline of the femoral condyles; (2) the 'supratrochlear spur', which is an osseous prominence of the proximal part of the femoral trochlea measured from a reference line along the anterior cortex; (3) the 'double-contour sign', which is the asymmetry of the height of the medial and lateral trochlear facets, representing an hypoplastic medial trochlear facet (Fig. 1). Based on the presence or absence of these features, four grades can be obtained (Fig. 2):

Type A: the line of the trochlear groove is seen to intersect the anterior border of one of the condyles, therefore only the 'crossing sign' is present. Anatomically, the trochlea appears practically normal.



**Fig. 2** Classification of patellofemoral dysplasia according to Dejour<sup>2</sup>: a) type A with ‘crossing sign’; b) type B with ‘crossing sign’ and ‘supratrochlear spur’; c) type C with ‘crossing sign’ and ‘double contour sign’; d) type D with ‘crossing sign’, ‘double contour sign’ and ‘supratrochlear spur’.

Type B: the ‘supratrochlear spur’ and the ‘crossing sign’ are present. Anatomically, the trochlea is starting to assume a convex shape.

Type C: the ‘double contour’ and the ‘crossing sign’, which represents a convex lateral facet and a hypoplastic medial facet, are present. Anatomically, the trochlea appears flattened.

Type D: all three signs of dysplasia are present (‘crossing sign’, ‘supratrochlear spur’ and ‘double contour sign’). Anatomically the trochlea is convex and shaped like a camel’s hump (Fig. 3).

To better evaluate and quantify the degree of patellofemoral dysplasia, and to guide the surgical treatment, a wide number of measurements and indices are described in the literature.

*Rotational abnormalities*

Tibial tuberosity–trochlear groove (TT-TG) distance (Fig. 4): the TT-TG distance is used to determine the degree of lateralisation of the tibial tubercle in relation to the deepest part of the trochlear groove. A TT-TG distance of more than 20 mm on CT scans is considered pathological and is a significant risk factor for patellar instability. Normal values are considered if the distance is < 15 mm, while values in the range of 15 to 20 mm are considered borderline.<sup>10</sup> Extreme care should be used when evaluating the TT-TG distance, since MRI measures have been found to be on average 2 mm less than CT

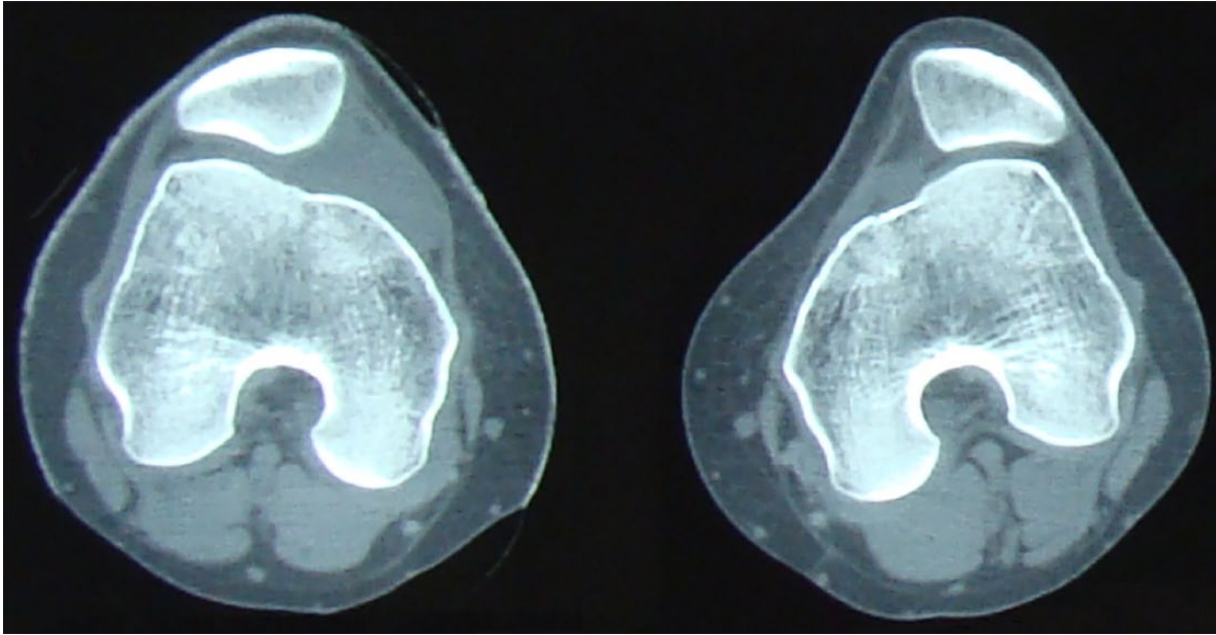
measurements.<sup>11</sup> Moreover, the knee flexion angle at imaging has also been demonstrated to affect this measure, since Tanaka et al<sup>12</sup> reported a decrease of TT-TG distance of almost 1 mm for every 5° of knee flexion. According to a cutoff value of 15 mm, 70% of patients with patellar instability had the indication for tibial tubercle transfer if the measurement was obtained with the knee in full extension, while only 24% would have maintained such indication if TT-TG was measured at 30° of flexion. The authors thus suggested correction of the TT-TG values based on the degrees of knee flexion.

Femoral torsion (Fig. 5a): this is the measure of the angle formed between a line running through the centre of the femoral head and the centre of the femoral neck at its junction with the diaphysis and the posterior bi-condylar line. The mean value of this angle measured using these landmarks is 13° of femoral anteversion.

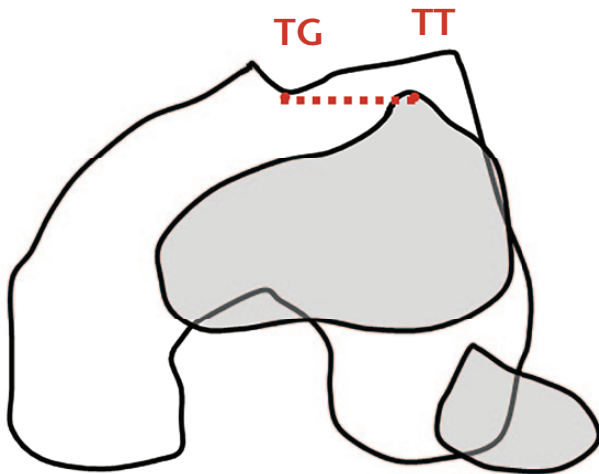
Tibial torsion (Fig. 5b): this is measured between the knee flexion-extension axis and the ankle joint axis. The tangent line to the posterior condyles can be used for an easier measurement of the landmarks. Mean values (30° to 35°) show considerable gender- and race-related variability.

*Patellar height*

Insall-Salvati ratio (Fig. 6): this is the ratio between the patellar tendon length and the length of the patella. The normal range is 0.8 to 1.2, with patella alta being present with a ratio of > 1.2 and patella infera with a ratio of < 0.8.



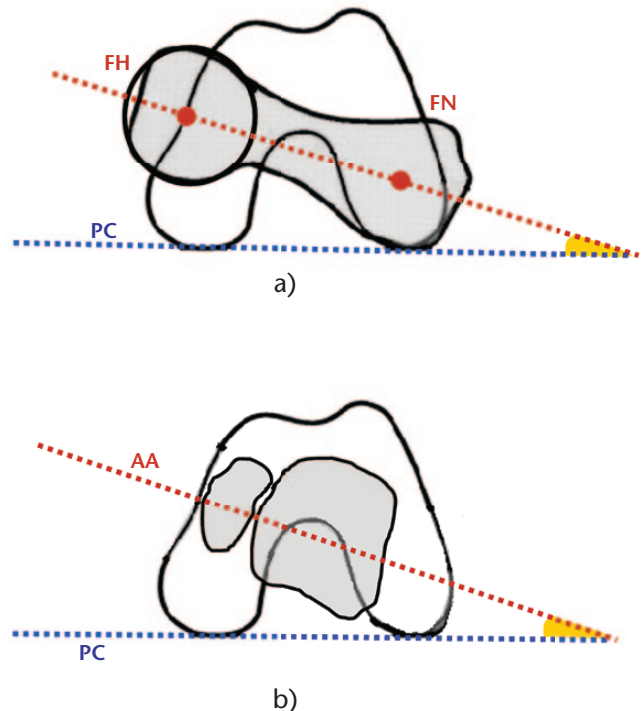
**Fig. 3** CT scan evaluation of patellofemoral dysplasia: a 21-year-old female patient with bilateral patellar instability due to type D dysplasia.



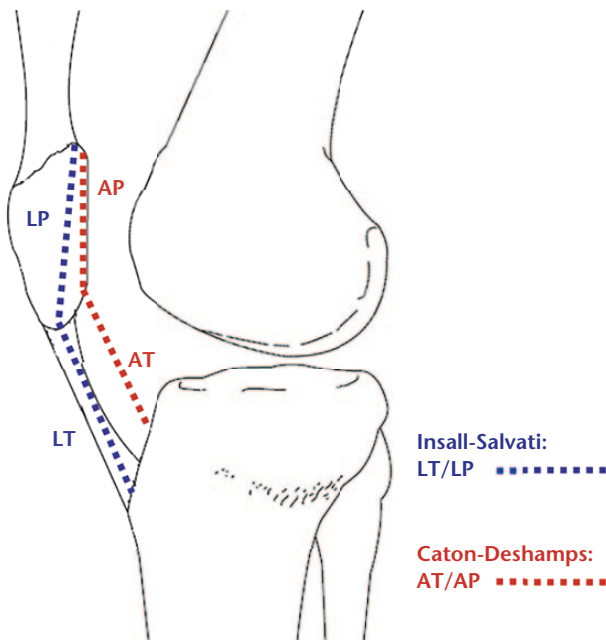
**Fig. 4** Tibial tuberosity – trochlear groove distance measurement: the deepest point of the trochlear groove (TG) is obtained in the axial cut and superimposed in a second axial cut where the anterior tibial tuberosity (TT) is marked. The distance between these two points is measured.

Caton-Deshamps index (Fig. 6): this is the ratio between the distance from the lower pole of the patella and the upper limit of the tibia and the length of the patellar joint surface. The ideal measurement is with the knee at 30° of flexion. The normal range is 0.6 to 1.3, while patella alta has a ratio of > 1.3 and patella infera a ratio of < 0.6.<sup>13</sup>

These measurements, which use the length of the patella *versus* the length of the patellar tendon, do not



**Fig. 5** Measurement of lower limb axial rotational alignment: a) femoral rotational alignment is measured calculating the angle between the line running through the centre of the femoral head (FH) and the centre of the femoral neck (FN) and the posterior bi-condylar line (PC); b) tibial rotational alignment is measured calculating the angle between the tangent line to the posterior condyles (PC) and the axis of the ankle joint (AA).



**Fig. 6** Evaluation of patellar height: a) the Insall-Salvati ratio is measured on a true lateral radiograph with the knee at 30° of flexion, as the ratio between patellar tendon length (LT) and the length of the patella (LP); b) similarly, the Caton-Deshamps ratio is measured as the ratio between the distance from the lower pole of the patella to the upper limit of the tibia (AT) and the length of the patellar joint surface (AP).

account for variations in the proximal extent of the anterior trochlea. Therefore, several authors have suggested parameters that describe the overlap, or lack of it, between the patellar and trochlear articular surfaces, defined as ‘engagement’.

#### Patellar engagement

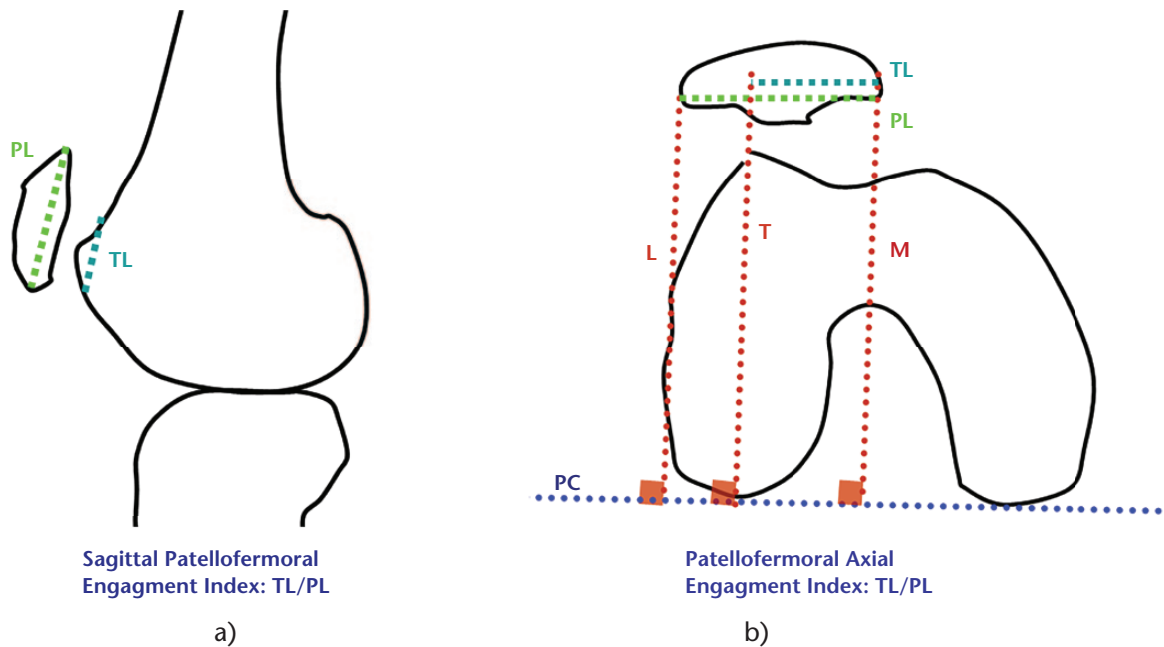
Sagittal patellofemoral engagement index (Fig. 7a):<sup>14</sup> this is an engagement index of the patella that is calculated with MRI sagittal cuts. This index, which aims to evaluate the functional engagement of the patella with the femoral trochlea, is believed to serve as a supplementary tool to existing methods of evaluating patellar height, helping to identify the cases with inadequate engagement despite the absence of patella alta.

Axial engagement index (AEI) (Fig. 7b):<sup>15</sup> this is a new index of measurement for lateral patellar displacement and is a direct reflection of this entity. Measurement of AEI can be obtained with two different axial MRI views, using the cartilaginous and posterior condylar landmarks as references. The normal value is close to one, while lower values indicates more severe forms of objective patellar instability and are correlated with trochlear dysplasia with increased trochlear prominence.

## Biomechanics of dysplasia

In classical mechanics, stability is defined as ‘a property of a body that resists displacement away from the stable position of equilibrium where all forces are in balance’. According to Amis,<sup>16</sup> stability in the patellofemoral joint may be described based on the amount of force required to displace the patella a given linear distance away from its equilibrium position (a translation), or even as the turning moment needed to induce a given rotation, such as a lateral tilt.<sup>17</sup> This stability is influenced by static and dynamic structures, such as geometry of the trochlear groove, limb alignment and rotation, and medial soft tissue and vastus medialis muscles. However, when we refer to ‘patellofemoral dysplasia’, we mainly focus our attention on the osseous patellar, femoral and tibial abnormalities.

The main anatomical feature that influences patellofemoral stability, and which is altered in the dysplastic joint, is the geometry of the trochlear groove; in fact, the depth and steepness of the slopes of the articular facets affects the imbalance forces necessary to induce subluxation or even dislocation. Normally, a well-shaped trochlea has a different cross-section along its length, with a lateral facet height decreasing from proximal to distal, when the patella moves distally with knee flexion. This shape is functional for the forces acting during knee movement, as the quadriceps muscle tension and the patellar tendon tension that combine to produce a resultant force vector directed posteriorly on the patella, increases from extension to flexion, stabilising the patella into the trochlear groove (Fig. 8a). Moreover, knee flexion produces an internal tibial rotation that medialises the tibial tubercle and patellar tendon insertion and decreases the coronal angle between the lines of action of the patellar tendon and of the resultant force of the quadriceps muscle, also known as the ‘Q-angle’ (Fig. 8b). Therefore, full extension represents a biomechanical disadvantageous condition for patellar stability, due to the minimal posteriorly directed stabilising force and an increased ‘Q-angle’ which tend to displace the patella laterally. For these reasons, trochlear geometry and lateral facet shape represent important features for patellar stability in the first degrees of flexion. When the knee is fully extended the patella is not engaged with the trochlea and rather lies proximally to it; therefore, in this position, patellar stability depends only on the soft tissues. When the knee starts to flex, the initial contact is centred at the distal/lateral edge of the patellar articular surface, which bears against the proximal/lateral extremity of the trochlea. Thus, in early flexion there is a mechanism to ‘catch’ the patella, that shifts medially into the centre of the trochlear groove. In the process of flexion the contact area moves proximally across the patella, that remains in congruent contact with



**Fig. 7** Sagittal patellofemoral engagement (SPE) index measurement: a) the SPE index is measured using a sagittal MRI view, with the knee in full extension. The first cut is determined where the patella shows the longest articular cartilage. On this image, a patellar length (PL) line is drawn, that measures the entire length of the patellar articular cartilage. The second cut is selected where the femoral trochlear cartilage extends most proximally. On this slice, the PL line copied from the first cut, is inserted. A second line is then drawn parallel to the PL, which starts from the most proximal articular trochlear cartilage and finishes at the distal end of the PL, providing the trochlear length (TL) line. The SPE is calculated as the ratio between TL and PL. b) Axial engagement index (AEI) measurement: the AEI is measured using an axial MRI view, with the knee in full extension. The first cut is chosen where the lateral border of the trochlea is largest; the posterior bi-condylar line (PC) is drawn. A perpendicular line (T) to the PC line is drawn passing from the most lateral point of lateral trochlear border. A second cut is chosen where the patella is widest; after transferring the BC in this slice, a perpendicular line (M) is drawn passing the most medial part of the patellar cartilage. The distance (TL) between the line T and M is measured. The distance (PL) between most lateral point of the patellar cartilage (L) is measured. The AEI of the patella is equal to LP/LT.

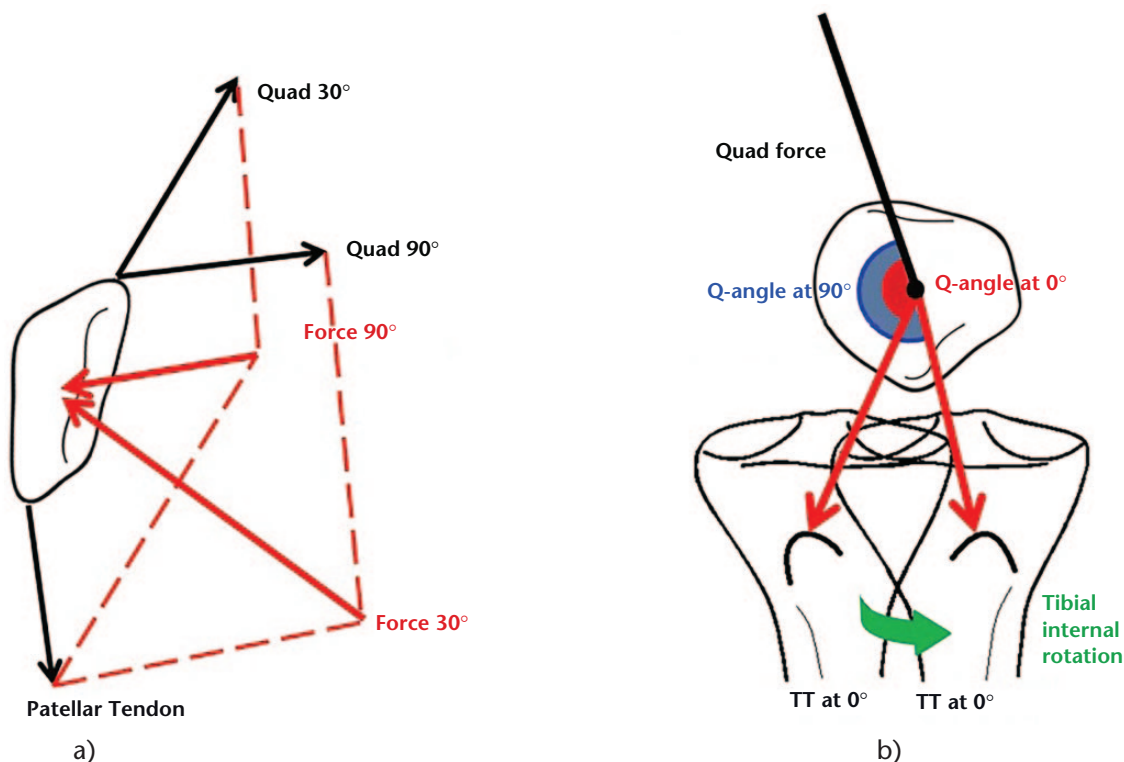
the lateral trochlear facet or the condyle throughout the range of knee flexion. This maintains the stability against lateral displacement.

It is therefore easy to understand that a flat trochlea without a prominent lateral facet lacks an indispensable restraint that can predispose the patella to lateral displacement. This has been confirmed in cadaveric models, where a trochlear dysplasia was simulated by elevating the central groove.<sup>18</sup> Such a condition reduced the force needed to displace the patella laterally up to 50% compared with a normal joint, especially at 30° of flexion. Moreover, flattening the lateral trochlea has been demonstrated to cause a greater loss of patellar stability than dysfunction of vastus medialis obliquus or rupture of the medial retinacula across most of the arc of knee flexion. However, the lateral stability in an extended knee has been reported to be controlled principally by the medial retinacular soft-tissues.<sup>19</sup>

Also the kinematic behaviour of the four different types of patellofemoral dysplasia has been tested in a cadaveric model, simulating the dysplastic trochlea with three-dimensional printed specimens inserted in the human

joint.<sup>20</sup> Increased patellar lateral tilt, lateral tracking and external rotation were found in the dysplastic models compared with the normal joint, especially for type D dysplasia in open-chain activity simulation. Also, an increased patellofemoral pressure and a reduced patellofemoral contact area were reported in trochlear dysplasia, more pronounced in B and D types. Finally, a 100 N lateral force tended to displace the patella 4 mm more in dysplastic models compared with the normal joint, especially at 20° of flexion. Similar findings were reported *in vivo* with a combined MRI and fluoroscopic evaluation of patellar tracking during weight-bearing knee flexion.<sup>21</sup> The authors reported a significant correlation between trochlear geometry and lateral patellar shift and tilt.

Medio-lateral location of the tibial tubercle and patellar tendon insertion have been demonstrated to alter patellofemoral kinematics as well. Cadaveric models that lateralised the tibial tubercle by 15 mm registered an increase of lateral joint contact pressure, lateral patellar tracking and reduced patellar stability after the application of a laterally directed force, especially in early flexion before the patella engaged with the trochlear groove.<sup>22</sup>



**Fig. 8** Patellofemoral biomechanics during knee flexion: a) in the sagittal plane the quadriceps muscle tension and the patellar tendon tension combine to produce a resultant force vector directed posteriorly on the patella; this force vector is minimal in the first degrees of flexion (force 30°), while increasing progressively at higher degrees of flexion (force 90°), stabilising the patella into the trochlear groove. b) In the coronal plane, the angle between the force of the quadriceps muscle and the line of action of the patellar tendon is known as ‘Q-angle’. This tends to increase from knee flexion, where the tibia internally rotates ‘medialising’ the tibial tubercle (Q-angle at 90°), to full extension, where the tibia externally rotates ‘lateralising’ the tibial tubercle (Q-angle at 0°). A higher ‘Q-angle’ represents a disadvantageous condition for patellar tracking. TT, tibial tuberosity.

### Patellar dislocation and risk of recurrence

The average annual incidence of primary patellar dislocation has been reported to be 5.8 cases per 100 000, and the rate is higher for younger and more active populations.<sup>23</sup> Risk factors for primary patellar dislocation, although extensively investigated, remain controversial. A cross-sectional study comparing demographic and anatomical features of 103 skeletally immature patients with lateral patellar dislocation with a matched control group addressed some important points.<sup>24</sup> Overall, 96% of patients with patellar dislocation presented at least one anatomical abnormality among trochlear dysplasia (trochlear depth < 3 mm), abnormal patellar tilt (> 20°), increased TT-TG distance (> 15 mm) or patella alta (Caton-Deshamps Index > 1.2) compared with 42% of the control group. Specifically, 17% of the patellar dislocation group had all four instability factors, 27% had three, 35% had two and only 17% had one abnormality, with trochlear dysplasia the most recurrent one and increased TT-TG never present as an isolated abnormality. Furthermore, based on these findings, a patellar tilt > 15° was suggested

**Table 1.** Anatomical risk factors for lateral patellar dislocation

	Sensitivity	Specificity	Odd Ratio
Patellar tilt > 20°	0.50	1.00	97.79
Patellar tilt > 15°*	0.81	0.93	–
TT-TG > 15 mm	0.38	0.90	5.40
TT-TG > 11 mm*	0.72	0.70	–
Trochlear depth < 3 mm*	0.75	0.96	61.93
Sulcus angle > 145°	0.75	0.88	22.58
Caton-Deshamps > 1.22*	0.72	0.69	5.50

\* suggested threshold.

TT-TG, tibial tuberosity-trochlear groove.

as the parameter with highest sensitivity and specificity (Table 1).

Anatomical abnormalities and especially trochlear dysplasia were reported as risk factors for recurrence of patellar dislocation as well. A cohort study that prospectively followed 312 patients with primary patellar dislocation reported an overall recurrence rate of 29.8%, with the second episode occurring at an average of 16.5 months after

the primary event.<sup>25</sup> The suggested risk factors were young age, sports-related primary injury, patella alta, skeletal immaturity and trochlear dysplasia. The latter, when present, was associated with a five-year risk of recurrence of 23.3%, that rose to 60.2% in patients < 25 years and further rose to 70.4% if patella alta was also present. In other words, isolated patella alta had a hazard ratio (HR) of 1.69, isolated trochlear dysplasia had a HR of 3.73 and the two combined increased the HR to 4.29. Younger age, as previously outlined, represented a negative factor with an additional recurrence risk of 8% every year of age decrease. However, in this series, the gender did not play a significant role.

### Management of lateral patellar dislocation

The correct management of primary and recurrent lateral patellar dislocation, especially in the case of patellofemoral dysplasia, still represents a dilemma.

In the case of a first episode, conservative management has been historically considered to be the treatment of choice due to the reported comparable results with surgical treatment.<sup>26</sup> However, with improvement of biomechanical and anatomical knowledge, coupled with refinement of surgical techniques, a recent meta-analysis reported a lower re-dislocation rate after surgical treatment.<sup>27</sup> Since other authors reported different results based on injury pattern,<sup>28</sup> a tailored and patient-specific treatment should be attempted.

Generally, conservative treatment is reported to guarantee satisfactory results, especially in cases with no evident co-morbidities or concomitant injuries. Some period of immobilisation in extension is advised by placing the patient in an extension brace for a period of three to six weeks. Despite the lack of clear guidelines, immobilisation is followed by physical therapy or patient-directed home therapy focused on range of motion, vastus medialis obliquus re-inforcement and gluteal musculature strengthening. An elastic or hinged brace can be helpful for proprioception and stability. However, conservative treatment has been reported to have a high failure rate in cases of patellofemoral dysplasia, which therefore indicates surgical management after repeated dislocations. Surgical treatment for the primary episode should be reserved mostly to selected cases with large displaced osteochondral fragments, osseous avulsion of the medial patellofemoral ligament (MPFL)<sup>29</sup> and, according to some authors,<sup>30</sup> also those with MPFL injury at its patellar insertion. In this regard, different techniques of MPFL repair or reconstruction have been reported to deal with such situations. Traumatic dislocations with no underlying osseous abnormalities are deemed to perform effectively with MPFL reconstruction/repair.

When the initial conservative treatment fails, the management of recurrent lateral patellar dislocation presents a more precise decisional process, mainly based on anatomicopathological abnormalities. According to a recent algorithm proposed by Weber et al,<sup>31</sup> the main features to take into account are the skeletal maturity and the Dejour criteria of patellofemoral dysplasia (trochlear dysplasia, patella alta, TT-TG and patellar tilt). In the skeletally immature patient, femoral de-rotation osteotomies or hemi-epiphysiodesis are indicated for rotational (> 10° valgus with at least 12 months of remaining growth) or axial (excessive femoral anteversion) malalignment. Anatomical MPFL reconstruction or non-anatomical Roux-Goldthwait procedure in cases with concerns for physeal injury, are indicated in isolated MPFL lesions.

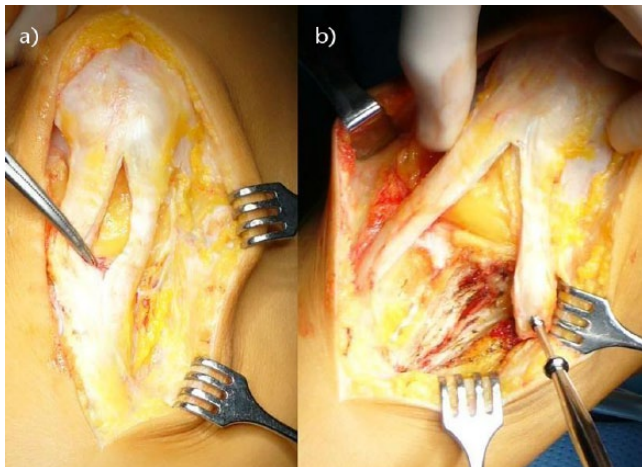
In the skeletally mature patient, tibial tuberosity medialisation is indicated with a TT-TG > 20 mm, a distalisation in the case of patella alta and a deepening trochleoplasty when type B or D trochlear dysplasia is present or a lateral facet elevation in case of type C dysplasia. MPFL reconstruction is advocated in cases with MPFL injury, a lateral release always in combination with other procedures is indicated in cases with patellar tilt > 20°, while de-rotation osteotomies are reserved for the cases of tibial external rotation or femoral anteversion.

### The Rizzoli experience with patellofemoral dysplasia and instability

The treatment of patellofemoral dysplasia and instability have been a historical topic of clinical and basic research of the Sport Traumatology Department of the Rizzoli Orthopaedic Institute, Bologna, Italy.

In 1995, 16 patients with bilateral patellar instability were reviewed after a mean follow-up of 30 years after treatment,<sup>32</sup> which was conservative in one knee and surgical with capsuloplasty according to Roux<sup>33</sup> in the contralateral knee. The authors reported only one recurrence in the operated knee, while in the contralateral non-operated knees dislocation episodes occurred, but decreased in frequency with time. This behaviour was attributed to a remodelling occurring in the patella that acquired a concave shape forming a new joint with the lateral femoral condyle. No significant differences in the clinical or radiographic results between the operated and non-operated joints, and no correlations between the two outcomes were reported. Half of the patients of this series presented major anatomical abnormalities such as a flat trochlea or excessively lateralised patella. In these cases, the outcomes which resulted were inferior compared with patients with less severe dysplasia. It was therefore suggested that conservative treatment should be the first treatment option and that a soft-tissue procedure could not be completely effective in the cases of severe patellofemoral dysplasia.





**Fig. 9** Surgical steps of medial patellotibial ligament (MPTL) reconstruction: a) the patellar tendon is incised to isolate its medial third, which should be detached with a tibial tuberosity bone plug; b) the bone plug is fixed on the medial tibia with a metal screw, anteriorly to the medial collateral ligament (MCL).

In 2003, the clinical and radiographic results of an original procedure were reported.<sup>34</sup> The procedure, which combined the medialisation of the medial third of the patellar tendon to the classical Elmslie-Trillat (medialisation of the whole anterior tibial tuberosity and patellar tendon), was performed in 18 knees and evaluated at five years of follow-up. Satisfactory results were reported in 88% of cases, with radiographic evidence of patellar medialisation/distalisation and no progression of patellofemoral osteoarthritis. However, the cases with severe dysplasia, which required a deepening trochleoplasty, showed the worst radiographic results.

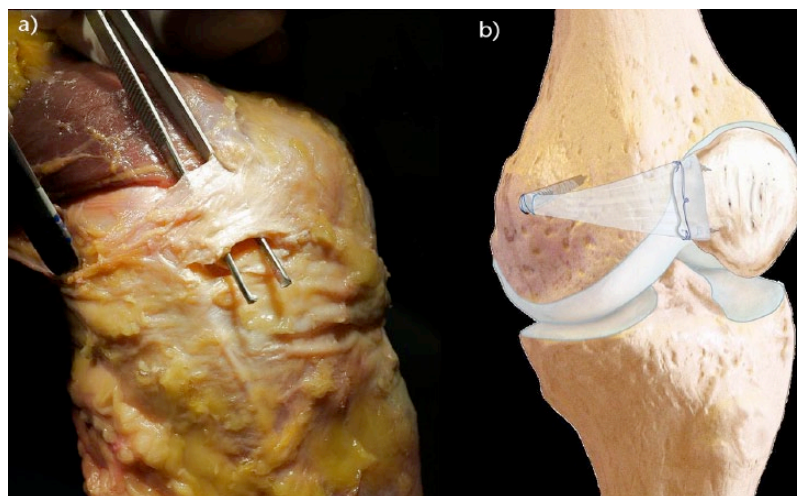
After ten years, the results of the isolated medialisation of the medial third of the patellar tendon, named medial

patellotibial ligament (MPTL) reconstruction (Fig. 9), were reported.<sup>35</sup> The 27 patients evaluated at 6.1-year follow-up had no dislocations in 86% of the cases. Two of the four failures were represented by patients with bilateral type D patellofemoral dysplasia, which had not undergone concurrent trochleoplasty due to their young age (11 years) and skeletal immaturity. The other patients with severe dysplasia who underwent concurrent trochleoplasty showed comparable results with those that underwent the isolated procedure. This confirmed the efficacy of combined distal re-alignment and correction of trochlear depth for the treatment of complex patellofemoral abnormalities.

More recently, the interest of the research community moved to the study of the MPFL, since it is considered the main soft-tissue restraint to lateral patellar displacement in the first degrees of flexion, and its rupture has been described in almost every case of patellar dislocation.<sup>36</sup>

An anatomical and biomechanical study<sup>37</sup> showed how the MPFL has an aponeurotic nature and works as a restraint to lateral dislocation during knee motion (Fig. 10a). However, its role is active predominantly during high stress on the lateral side while its contribution is small during neutral knee flexion. Despite the useful insights on MPFL reconstruction, no information was provided regarding the potential effect of patellofemoral dysplasia since the cadaveric model consisted of cadavers with a normally shaped trochlea.

The biomechanical effect of MPFL reconstruction was investigated in another cadaveric study.<sup>38</sup> The authors reported that patellar stability, in terms of lateral patellar translation and patellar tilt, was comparable to intact MPFL after reconstruction, but the normal kinematics of the original fan-shaped MPFL were not reproduced with the tubular graft and the femoral bone tunnel fixation. It



**Fig. 10** Medial patellofemoral ligament (MPFL) anatomy and reconstruction. Anatomical specimen showing shape and insertions of the MPFL: a) schematic drawing of MPFL reconstruction with fascia lata allograft and b) fixation with anchors and metal screw.

was therefore suggested that it could be difficult to fully reproduce the biomechanics of the natural ligament throughout the whole range of knee motion, even *in vitro* on knees with no additional osseous pathology, because of the different shape and width of the tubular grafts currently used for repairing the MPFL.

For these reasons, the senior author (SZ) developed a personal minimally invasive surgical technique of MPFL reconstruction, using a fan-shaped fascia lata allograft fixed to the femur with an interference screw and to the patella with metal<sup>39</sup> (Fig. 10b). The effect of this technique was evaluated in a cadaveric model, showing no differences of patellar tracking and stability compared with the intact MPFL condition.<sup>40</sup> Altered kinematics and stability, with increased medial tilt, peak pressure and patellar medicalisation, were observed when the graft was over-tensioned or fixed in a non-anatomical femoral position.

However, despite the biomechanical importance of the MPFL, its reconstruction should not be considered as the ‘panacea’ for all the patellofemoral instabilities. In fact, a recent meta-analysis reported a higher rate of recurrence in patients with severe trochlear dysplasia that underwent isolated MPFL reconstruction compared with trochleoplasty and extensor balancing.<sup>41</sup>

In 2016, patellofemoral dysplasia still represents an extremely challenging condition to manage. Its controversial aetiology and its complex biomechanical behaviour continue to pose more questions than answers to the research community, which is reflected in the lack of universally accepted guidelines for the correct treatment. However, due to the complexity of this condition, an extremely personalised approach should be reserved for each patient, aiming to consider and address the anatomical abnormalities responsible for the symptoms.

#### AUTHOR INFORMATION

<sup>1</sup>Istituto Ortopedico Rizzoli, Dipartimento Rizzoli Sicilia, Bagheria (PA), Italy.

<sup>2</sup>Dipartimento di Ortopedia e Traumatologia, Department of Biomedical Sciences and Morphological and Functional Images, Scuola Ortopedia e Traumatologia, Università di Messina, Italy.

<sup>3</sup>Istituto Ortopedico Rizzoli, Laboratorio di Biomeccanica e Innovazione Tecnologica, Bologna (BO), Italy.

Correspondence should be sent to: Cecilia Signorelli, Laboratorio di Biomeccanica ed Innovazione Tecnologica, Istituto Ortopedico Rizzoli, Via di Barbiano 1/10, 40136, Bologna, Italy.  
Email: c.signorelli@biomec.ior.it

#### ICMJE CONFLICT OF INTEREST STATEMENT

None

#### FUNDING

No benefits in any form have been received or will be received from a commercial party related directly or indirectly to the subject of this article.

#### LICENCE

© 2017 The author(s)

This article is distributed under the terms of the Creative Commons Attribution-Non Commercial 4.0 International (CC BY-NC 4.0) licence (<https://creativecommons.org/licenses/by-nc/4.0/>) which permits non-commercial use, reproduction and distribution of the work without further permission provided the original work is attributed.

#### REFERENCES

1. Wright SJ, Boymans TA, Grimm B, Miles AW, Kessler O. Strong correlation between the morphology of the proximal femur and the geometry of the distal femoral trochlea. *Knee Surg Sports Traumatol Arthrosc* 2014;22:2900–2910.
2. Dejour H, Walch G, Nove-Josserand L, Guier C. Factors of patellar instability: an anatomic radiographic study. *Knee Surg Sports Traumatol Arthrosc* 1994;2:19–26.
3. Hawkins RJ, Bell RH, Anisette G. Acute patellar dislocations. The natural history. *Am J Sports Med* 1986;14:117–120.
4. Nietosvaara Y, Aalto K, Kallio PE. Acute patellar dislocation in children: incidence and associated osteochondral fractures. *J Pediatr Orthop* 1994;14:513–515.
5. Glard Y, Jouve JL, Garron E, et al. Anatomic study off femoral patellar groove in fetus. *J Pediatr Orthop* 2005;25:305–308.
6. Øye CR, Foss OA, Hølen KJ. Breech presentation is a risk factor for dysplasia of the femoral trochlea. *Acta Orthop* 2015;87:17–21.
7. Salzmänn GM, Weber TS, Spang JT, Imhoff AB, Schöttle PB. Comparison of native axial radiographs with axial MR imaging for determination of the trochlear morphology in patients with trochlear dysplasia. *Arch Orthop Trauma Surg* 2010;130:335–340.
8. Salzmänn GM, Dovi-Akue D, Wätzig K, Südkamp NP, Niemeyer P. Does form follow function in trochlear dysplasia? Case report of patellar instability in a below-knee amputee. *Int J Surg Case Rep* 2014;5:91–94.
9. Kaymaz B, Atay OA, Ergen FB, et al. Development of the femoral trochlear groove in rabbits with patellar malposition. *Knee Surg Sports Traumatol Arthrosc* 2013;21:1841–1848.
10. Goutallier D, Bernageau J, Lecudonnet B. [The measurement of the tibial tuberosity. Patella groove distanced technique and results (author’s transl)]. *Rev Chir Orthop Reparatrice Appar Mot* 1978;64:423–428. (In French)
11. Camp CL, Stuart MJ, Krych AJ, et al. CT and MRI measurements of tibial tubercle–trochlear groove distances are not equivalent in patients with patellar instability. *Am J Sports Med* 2013;41:1835–1840.
12. Tanaka MJ, Elias JJ, Williams AA, Carrino JA, Cosgarea AJ. Correlation between changes in tibial tuberosity–trochlear groove distance and patellar position during active knee extension on dynamic kinematic computed tomographic imaging. *Arthroscopy* 2015;31:1748–1755.
13. Thévenin-Lemoine C, Ferrand M, Courvoisier A, et al. Is the Caton-Deschamps Index a valuable ratio to investigate patellar height in children? *J Bone Joint Surg [Am]* 2011;93-A:e35.
14. Dejour D, Ferrua P, Ntagiopoulos PG, et al. French Arthroscopy Society (SFA). The introduction of a new MRI index to evaluate sagittal patellofemoral engagement. *Orthop Traumatol Surg Res* 2013;99:S391–S398.
15. Guilbert S, Chassaing V, Radier C, et al. French Arthroscopy Society (SFA). Axial MRI index of patellar engagement: a new method to assess patellar instability. *Orthop Traumatol Surg Res* 2013;99:S399–S405.

16. **Amis AA.** Current concepts on anatomy and biomechanics of patellar stability. *Sports Med Arthrosc* 2007;2:48–56.
17. **Stephen JM., Dodds AL, Lumpaopong P, Kader D, Williams A, Amis AA.** The ability of medial patellofemoral ligament reconstruction to correct patellar kinematics and contact mechanics in the presence of a lateralized tibial tubercle. *Am J Sports Med* 2015;43:2198–2207
18. **Amis AA., Oguz C, Bull AM, Senavongse W, Dejour D.** The effect of trochleoplasty on patellar stability and kinematics: a biomechanical study in vitro. *J Bone Joint Surg [Br]* 2008;90-B:864–869.
19. **Senavongse W, Amis AA.** The effects of articular, retinacular, or muscular deficiencies on patellofemoral joint stability: a biomechanical study in vitro. *J Bone Joint Surg [Br]* 2005;87-B:577–582.
20. **Van Haver A, De Roo K, De Beule M, et al.** The effect of trochlear dysplasia on patellofemoral biomechanics: a cadaveric study with simulated trochlear deformities. *Am J Sports Med* 2015;43:1354–1361.
21. **Varadarajan KM, Freiberg AA, Gill TJ, Rubash HE, Li G.** A relationship between three-dimensional geometry of the trochlear groove and in vivo patellar tracking during weight-bearing knee flexion. *J Biomech Eng* 2010;132:061008.
22. **Stephen JM, Lumpaopong P, Dodds AL, Williams A, Amis AA.** The effect of tibial tuberosity medialization and lateralization on patellofemoral joint kinematics, contact mechanics, and stability. *Am J Sports Med* 2015;43:186–194.
23. **Hsiao M, Owens BD, Burks R, Sturdivant RX, Cameron KL.** Incidence of acute traumatic patellar dislocation among active-duty united states military service members. *Am J Sports Med* 2010;38:1997–2004.
24. **Askenberger M, Ekström W, Finnbogason T, Janarv PM.** Occult intra-articular knee injuries in children with hemarthrosis. *Am J Sports Med* 2014;42:1600–1606.
25. **Lewallen L, McIntosh A, Dahm D.** First-time patellofemoral dislocation: risk factors for recurrent instability. *J Knee Surg* 2015;28:303–309.
26. **Jain NP, Khan N, Fithian DC.** A treatment algorithm for primary patellar dislocations. *Sports Health* 2011;3:170–174.
27. **Saccomanno MF, Sircana G, Fodale M, Donati F, Milano G.** Surgical versus conservative treatment of primary patellar dislocation. A systematic review and meta-analysis. *Int Orthop* 2016;40:2277–2287.
28. **Ji G, Wang S, Wang X, et al.** Surgical versus nonsurgical treatments of acute primary patellar dislocation with special emphasis on the MPFL injury patterns. *J Knee Surg* 2016. [Epub ahead of print]
29. **Sillanpää PJ, Salonen E, Pihlajamäki H, Mäenpää HM.** Medial patellofemoral ligament avulsion in jury at the patella: classification and clinical outcome. *Knee Surg Sports Traumatol Arthrosc* 2014;22:2414–2418.
30. **Mariani PP, Liguori L, Cerullo G, Iannella G, Floris L.** Arthroscopic patellar reinsertion of the MPFL in acute patellar dislocations. *Knee Surg Sports Traumatol Arthrosc* 2011;19:628–633.
31. **Weber AE, Nathani A, Dines JS, et al.** An algorithmic approach to the management of recurrent lateral patellar dislocation. *J Bone Joint Surg [Am]* 2016;98:417–427.
32. **Marcacci M, Zaffagnini S, Iacono F, et al.** Results in the treatment of recurrent dislocation of the patella after 30 years' follow-up. *Knee Surg Sports Traumatol Arthrosc* 1995;3:163–166.
33. **Roux C.** Luxation habituelle de larotule. *Rev Chir* 1888;8:682.
34. **Marcacci M, Zaffagnini S, Lo Presti M, et al.** Treatment of chronic patellar dislocation with a modified Elmslie-Trillat procedure. *Arch Orthop Trauma Surg* 2004; 124:250–257.
35. **Zaffagnini S, Grassi A, Marcheggiani Muccioli GM, et al.** Medial patellofemoral ligament (MPTL) reconstruction for patellar instability. *Knee Surg Sports Traumatol Arthrosc* 2014;22:2491–2498.
36. **Zaffagnini S, Dejour D, Grassi A, et al.** Patellofemoral anatomy and biomechanics: Current concepts. *Joints* 2013;1:15–20.
37. **Zaffagnini S, Colle F, Lopomo N, et al.** The influence of medial patellofemoral ligament on patellofemoral joint kinematics and patellar stability. *Knee Surg Sports Traumatol Arthrosc* 2013;21:2164–2171.
38. **Ntagiopoulos PG, Sharma B, Bignozzi S.** Are the tubular grafts in the femoral tunnel in an anatomical or isometric position in the reconstruction of medial patellofemoral ligament? *Int Orthop* 2013;37:1933–1941.
39. **Zaffagnini S, Marcheggiani Muccioli GM, Grassi A, Bonanzinga T, Marcacci M.** Minimally invasive medial patellofemoral ligament reconstruction with fascia lata allograft: surgical technique. *Knee Surg Sports Traumatol Arthrosc* 2014;22:2426–2430.
40. **Stephen JM, Kittl C, Williams A, et al.** Effect of medial patellofemoral ligament reconstruction method patellofemoral contact pressures and kinematics. *Am J Sports Med* 2016;44:1186–1194.
41. **Balcerek P, Rehn S, Howells NR, et al.** Results of medial patellofemoral ligament reconstruction compared with trochleoplasty plus individual extensor apparatus balancing in patellar instability caused by severe trochlear dysplasia: a systematic review and meta-analysis. *Knee Surg Sports Traumatol Arthrosc* 2016. [Epub ahead of print]