

OPEN

# A Case Report of an Elderly Woman With Thrombocytopenia and Bilateral Lung Infiltrates

## *A Rare Association Between Diffuse Alveolar Hemorrhage and Idiopathic Thrombocytopenic Purpura*

Hafiz Rizwan Talib Hashmi, MD, Sindhaghatta Venkatram, MD, FCCP,  
and Gilda Diaz-Fuentes, MD, FCCP

**Abstract:** Etiologies for diffuse alveolar hemorrhage are wide and range from infectious to vasculitis and malignant processes. Idiopathic thrombocytopenic purpura is an autoimmune disorder characterized by persistent thrombocytopenia, with a relatively indolent course in young patients, but a more complicated progression and high associated mortality in the older patients. Diffuse alveolar hemorrhage, complicating idiopathic thrombocytopenic purpura, is a very uncommon association, with only 2 reported cases in the literature. We present a 69-year-old healthy woman presenting with petechial rash, progressive dyspnea, and bilateral alveolar infiltrates. She was found to have idiopathic thrombocytopenic purpura associated with diffuse alveolar hemorrhage. The patient had an excellent response to high doses of pulse steroids and immunoglobulins.

A high index of suspicion for noninfectious pulmonary diseases should be considered in patients with autoimmune diseases presenting with pulmonary infiltrates and hypoxia. Flexible bronchoscopy with sequential lavage is a relatively safe procedure in patients with coagulopathy and should be attempted to detect and confirm the diagnosis; absence of hemoptysis should not preclude the diagnosis.

(*Medicine* 94(50):e2235)

**Abbreviations:** BALF = bronchoalveolar lavage fluid, CT = computed tomography, DAH = diffuse alveolar hemorrhage, FFB = flexible fiber-optic bronchoscopy, ITP = idiopathic thrombocytopenic purpura, IVIG = intravenous immunoglobulin.

### INTRODUCTION

Diffuse alveolar hemorrhage (DAH) is a clinical diagnosis characterized by diffuse radiographic alveolar infiltrates,

hemoptysis, anemia, and is usually accompanied by respiratory failure.<sup>1</sup> These features—along with increasingly hemorrhagic fluid on sequential bronchoalveolar lavage (BAL) and the presence of hemosiderin-laden macrophages on cytologic analysis—are key components for timely DAH diagnosis.

When a patient presents with DAH, the clinician team needs to perform a comprehensive evaluation to identify the underlying cause with a detailed history, physical examination, and laboratory analyses, to search for the most common causes.<sup>2</sup> The treatments, as well as short and long-term outcomes, vary with the underlying causes of DAH. The association of DAH with idiopathic thrombocytopenic purpura (ITP) is very rare, with only 2 cases reported in the literature.<sup>3,4</sup> We present the case of an elderly woman with acute ITP, complicated with DAH.

### CASE REPORT

A 69-year-old woman with a history of hypertension presented with a generalized petechial rash and shortness of breath of 3 days duration. The rash was nonpruritic, painless, and started at the thighs, but rapidly disseminated to the rest of the body. She had progressive dyspnea on exertion, with a significant decrease in exercise tolerance. She denied fever, headache, dizziness, hemoptysis, or bleeding from anywhere. There was no history of new drug use, unusual food intake, contact with any sick persons, or recent travel. Her only medication was enalapril, which she had been taking for several years. The patient denied any use of recreational drugs, tobacco, or alcohol.

On admission, she was afebrile, normotensive with mild tachypnea (respiratory rate of 22 breaths per minute). Physical examination revealed scattered petechial rash, more prominent in lower extremities, nonpalpable and nonblanching. Chest auscultation revealed coarse crackles bilaterally. Cardiovascular, abdominal, and neurological examinations were normal. There was no palpable lymphadenopathy or visceromegaly.

Laboratory examination revealed thrombocytopenia (platelets 7000/ $\mu$ L), anemia (hemoglobin 10.8 mg/dL and hematocrit 34%), and leukocytosis (white blood cells [WBCs] 11,600/ $\mu$ L). The coagulation profile was normal, which excluded disseminated intravascular coagulation. Arterial blood gas on ambient air revealed a partial pressure of oxygen (PaO<sub>2</sub>) of 64 Torr, a partial pressure of carbon dioxide (PaCO<sub>2</sub>) of 37 Torr (pH 7.45), and an increased alveolar-arterial gradient (44 Torr). Diffuse airspace consolidation was found on chest roentgenogram (Fig. 1A). Computed tomography (CT) of the chest showed diffuse ground glass alveolar opacities and patchy infiltrates (Fig. 1B, C). She was started on broad-spectrum antibiotics and received intravenous steroids. Peripheral smear showed giant platelets and occasional small

Editor: Levent Dalar.

Received: September 22, 2015; revised: November 10, 2015; accepted: November 12, 2015.

From the Division of Pulmonary and Critical Care Medicine, Bronx Lebanon Hospital Center, Bronx, NY.

Correspondence: Hafiz Rizwan Talib Hashmi, Fellow, Division of Pulmonary and Critical Care Medicine, Bronx Lebanon Hospital Center, Affiliated with Albert Einstein College of Medicine, Bronx, NY 10457 (e-mail: rizwan404@hotmail.com).

Conflicts of interest and source of funding: None of the authors has a financial relationship with a commercial entity that has an interest in the subject of the manuscript.

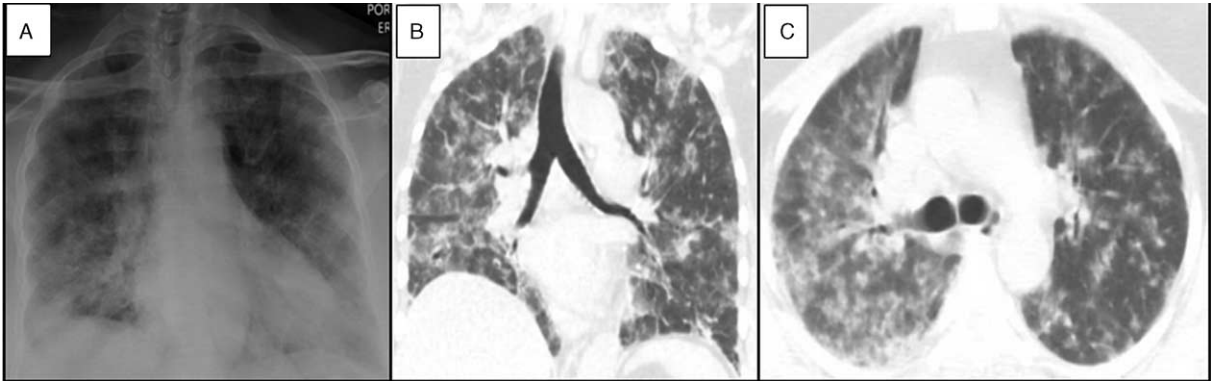
No financial support was used for this case report.

Copyright © 2015 Wolters Kluwer Health, Inc. All rights reserved.

This is an open access article distributed under the Creative Commons Attribution-NoDerivatives License 4.0, which allows for redistribution, commercial and non-commercial, as long as it is passed along unchanged and in whole, with credit to the author.

ISSN: 0025-7974

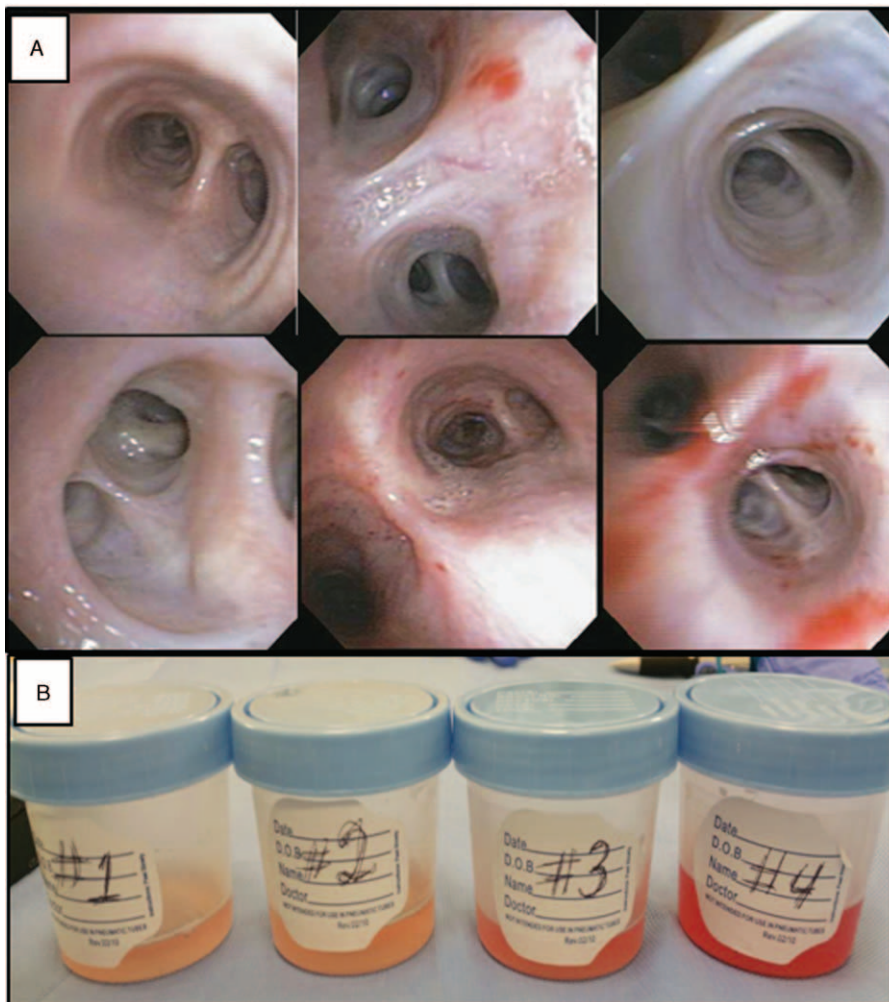
DOI: 10.1097/MD.0000000000002235



**FIGURE 1.** A, Chest radiograph on admission showing bilateral patchy infiltrates. B and C, Chest computed tomography (CT) coronal and axial views showing bilateral patchy ground glass and alveolar infiltrates.

platelet clumps, with no schistocytes. A flexible fiber-optic bronchoscopy (FFB) showed normal mucosa with no endobronchial lesions (Fig. 2A). Serial aliquots of BAL fluid (BALF) turned more hemorrhagic, confirming the

bronchoscopic diagnosis of DAH (Fig. 2B). Cytology of BALF showed a substantial amount of hemosiderin-laden macrophages, further supporting the diagnosis. All BALF cultures and gram stains were negative.



**FIGURE 2.** A, Flexible fiber-optic bronchoscopy (FFB) showing normal mucosa. B, Bronchoalveolar lavage fluid (BALF) showing sequential BAL aliquots with increased hemorrhagic fluid.

The patient remained with severe thrombocytopenia and hypoxia despite steroids and platelets transfusion. High doses of pulse steroids and intravenous immunoglobulins (IVIGs) were added with clinico-radiological improvement. A bone marrow aspirate was morphologically normal. Additional laboratory studies failed to reveal an etiology for secondary thrombocytopenia (Table 1), supporting the diagnosis of ITP. Steroids were gradually tapered. Repeat chest radiograph showed almost complete resolution of bilateral infiltrates (Fig. 3). Platelet count returned to normal by week 10 after admission without any additional therapies (Fig. 4).

**DISCUSSION**

Idiopathic ITP is an autoimmune disorder characterized by a low platelet count due to autoantibody binding to platelet antigen(s), leading to their premature destruction by the mononuclear phagocyte system and, in particular, the spleen.<sup>5</sup> ITP has an insidious onset, with no preceding viral or other illness. Diagnosis of ITP requires exclusion of other etiologies for isolated thrombocytopenia. The estimated incidence of ITP in adults ranges from 1.6 to 3.9 per 105 adults per year.<sup>6</sup>

Symptoms and signs of ITP are highly variable and range from a fairly common asymptomatic patient with mild bruising, mucosal bleeding (eg, oral or gastrointestinal tract bleeding) to frank bleeding from any site. Overall, symptomatic bleeding is uncommon unless the ITP is severe (platelet count <30,000/ $\mu$ L). Investigations in patients presenting with possible ITP focus on excluding conditions that might cause nonimmune thrombocytopenia. Acute thrombocytopenia with neurological signs may indicate a diagnosis of thrombotic ITP; lymphadenopathy and splenomegaly may suggest the presence of a lymphoproliferative disorder. Bone marrow examination in adults is recommended for patients older than 60 years or when splenectomy is considered.

Clinical manifestations of ITP are related to bleeding and thrombocytopenia. Bleeding due to thrombocytopenia is seen in two-thirds of patients with ITP. The most common type of bleeding associated with ITP is referred to as “platelet-type,” with intracranial hemorrhage being the most severe and relatively more common in adults.<sup>7</sup>

There is a poor correlation between the degree of thrombocytopenia and bleeding; however, more severe thrombocytopenia

(platelet count <10,000/ $\mu$ L) is associated with serious bleeding.<sup>8</sup> Previously reported cases<sup>3,4</sup> and our patient with DAH due to ITP had very low platelet counts (<10,000/ $\mu$ L). There are no randomized studies evaluating “no treatment” to therapy with corticosteroids or IVIGs. In addition, there is no indication for therapy in asymptomatic adults or patients with a platelet count >30,000/ $\mu$ L. IVIG infusion is useful in 75% of patients where platelets have to be raised either due to symptoms or signs (as in our patient) or planned surgical procedure.<sup>9</sup>

Diffuse alveolar hemorrhage is recognized by the clinical constellation of hemoptysis, anemia, diffuse radiographic pulmonary infiltrates, and hypoxemic respiratory failure. Hemoptysis is a usual presenting symptom, although it can be absent in one-third of the patients, irrespective of the severity of DAH.<sup>10</sup> Other constitutional, nonspecific symptoms like fever, chest pains, cough, and dyspnea can be seen.

The histopathology of DAH includes the presence of intra-alveolar red blood cells (RBCs) and fibrin, with an accumulation of hemosiderin-laden macrophages, which may take 2 to 3 days to accumulate. One of the 3 histologic patterns—pulmonary capillaritis, bland pulmonary hemorrhage, and diffuse alveolar damage—are associated with DAH. All causes involve injury or inflammation of the arterioles, venules, alveolar wall, or interstitial capillaries. Isolated pulmonary capillaritis is the most common histological finding and portends a better prognosis when compared to DAH associated with systemic vasculitis or collagen vascular disease.<sup>11</sup>

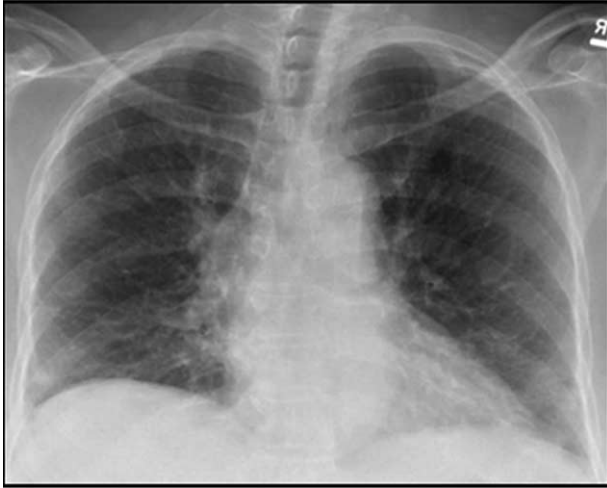
Clinical presentation of the underlying process associated with DAH is variable, and diagnosis relies on the clinician’s recognition along with specific clinical, laboratory, radiologic, and pathologic features. A comprehensive history and examinations help to narrow the differential diagnosis in patients presenting with DAH. It is important to evaluate for multi-systemic disorders versus isolated pulmonary conditions.<sup>12</sup> The most common causes associated with vasculitis or capillaritis include antineutrophilic cytoplasmic antibody-associated vasculitis, antiglomerular basement membrane disease, systemic lupus erythematosus, and other collagen vascular diseases.

The radiologic features of diffuse alveolar opacities are nonspecific. Cavities and nodules on chest imaging are suggestive of vasculitis, and lymphadenopathy is more suggestive of infections or malignancy.<sup>13,14</sup>

**TABLE 1. Laboratory Parameters**

Hematology		Blood Chemistry		Serology/Others	
WBC	11600/ $\mu$ L	Total protein	8.2 mg/dL	ANA	–
Neutro	86.3%	Albumin	4.2 mg/dL	Anti-DNA	–
EOS	0.3%	ALT	24 units/L	Anti-Scl 70	–
Hb	10.9 g/dL	AST	33 units/L	Anti-Sm	–
Hct	34.0%	Total bilirubin	0.5 mg/dL	Anti-RNP	–
Platelet	7000/ $\mu$ L			Anti-GBM	–
Reticulocyte	0.19 MIL/ $\mu$ L	Na	135 mEq/L	RA factor	–
Coagulation profile		K	4.3 mEq/L	Anti-CCP	–
PT	11.6 s	BUN	15 mg/dL	C3	117 (90–150 mg/dL)
INR	1.0	Cr	0.6 mg/dL	C4	16 (16–47 mg/dL)
APTT	26.5 s	Cl	102 mEq/L	Cardiolipin IgG, IgA, IgM	Within normal limit
Fibrinogen assay	384 mg/dL			Urine toxicology	Negative
D-dimers	<150 ng/mL			Hep B,C antibody	Negative

ALT = alanine transaminase, ANA = antinuclear antibody, APTT = activated partial thromboplastin time, AST = aspartate aminotransferase, CCP = cyclic citrullinated protein, EOS = eosinophils, GBM = glomerular basement membrane, Hct = hematocrit, INR = international normalised ratio, PT = prothrombin time, RNP = ribonucleoprotein, WBC = white blood cell.



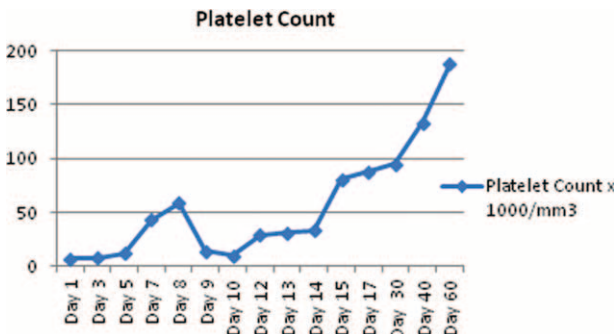
**FIGURE 3.** Follow-up chest radiograph showed significant improvement in diffuse alveolar hemorrhage.

Bronchoscopy with BAL is indicated to document alveolar hemorrhage and exclude infections. A rising red blood cell count in sequential aliquots from the same location is considered diagnostic of DAH. The utility of transbronchial biopsy in patients with suspected DAH is controversial, and this technique is rarely used in identifying the underlying etiology.<sup>15</sup> A confident diagnosis may be made without tissue biopsy; however, more accessible sites such as skin, or upper airway lesions, should be biopsied when clinically indicated.<sup>16</sup>

Therapy for DAH is based on treating both the autoimmune destruction of the alveolar capillary membrane and the underlying condition. Immunosuppressive agents are the mainstay of treatment, especially in vasculitis-related cases.

The incidence of ITP in the older individual is uncommon, and the association with DAH is an extremely rare presentation. We found 2 cases reported in the English literature of DAH due to ITP, one in a young male with Kabuki syndrome and the second one in an older male who responded well to high-dose IVIG therapy combined with corticosteroid pulse therapy.<sup>3,4</sup> The exact mechanism by which ITP may cause DAH remains unknown, but the literature and our present case suggest that the underlying mechanism is an immune process.

We have excluded other etiologies of alveolar hemorrhage to a reasonable degree, and our patient was treated successfully



**FIGURE 4.** Figure showing the patient's platelet counts from admission until complete recovery.

with steroids and IVIGs for underlying ITP. DAH can present as a medical emergency, and early identification is of paramount importance. Patients in whom the diagnosis of DAH is suspected should undergo early FFB with sequential BAL for confirmation.

## CONCLUSIONS

Thrombocytopenia is a common finding in medical practice, occasionally associated with life-threatening bleeding complications. The presence of ITP in an older person associated with bilateral infiltrates and anemia, with or without hemoptysis, should raise suspicions for the presence of DAH. Early diagnosis and aggressive management can lead to better outcomes. The incidence of major hemorrhagic complications and ITP-related mortality is particularly high among older patients. We report this case to raise clinical awareness of a rare but potentially fatal association of ITP with DAH.

## REFERENCES

1. Frankel SK, Cosgrove GP, Fischer A, et al. Update in the diagnosis and management of pulmonary vasculitis. *Chest*. 2006;129:452–465.
2. Franks TJ, Koss MN. Pulmonary capillaritis. *Curr Opin Pulm Med*. 2000;6:430–435.
3. Das S, Cherian S, Hamarneh W, et al. Diffuse alveolar hemorrhage secondary to idiopathic thrombocytopenic purpura; an extremely rare presentation. *Chest*. 2012;142 (4\_MeetingAbstracts):469A.
4. Uchiyama M, Hattori A, Tanaka T, et al. Acute idiopathic thrombocytopenic purpura complicated with diffuse alveolar hemorrhage in an elderly patient. *Intern Med*. 2009;48:1449–1452.
5. Cines DB, Blanchette VS. Immune thrombocytopenic purpura. *N Engl J Med*. 2002;346:995–1008.
6. Terrell DR, Beebe LA, Vesely SK, et al. The incidence of immune thrombocytopenic purpura in children and adults: A critical review of published reports. *Am J Hematol*. 2010;85:174–180.
7. Neunert C, Noroozi N, Norman G, et al. Severe bleeding events in adults and children with primary immune thrombocytopenia: a systematic review. *J Thromb Haemost*. 2015;13:457–464.
8. Lacey JV, Penner JA. Management of idiopathic thrombocytopenic purpura in the adult. *Semin Thromb Hemost*. 1977;3:160–174.
9. British Committee for Standards in Haematology General Haematology Task, F. Guidelines for the investigation and management of idiopathic thrombocytopenic purpura in adults, children and in pregnancy. *Br J Haematol*. 2003;120:574–596.
10. Lara AR, Frankel SK, Schwarz MI. Diffuse alveolar hemorrhage. In: Schwarz MI, King Jr T, Shelton, CT, USA: People's Medical Publishing House; 2011:p. 805.
11. Jennings CA, King TE Jr, Tuder R, et al. Diffuse alveolar hemorrhage with underlying isolated, pauciimmune pulmonary capillaritis. *Am J Respir Crit Care Med*. 1997;155:1101–1109.
12. Park MS. Diffuse alveolar hemorrhage. *Tuberc Respir Dis (Seoul)*. 2013;74:151–162.
13. Specks U. Diffuse alveolar hemorrhage syndromes. *Curr Opin Rheumatol*. 2001;13:12–17.
14. Brown KK. Pulmonary vasculitis. *Proc Am Thorac Soc*. 2006;3:48–57.
15. Colby TV, Fukuoka J, Ewaskow SP, et al. Pathologic approach to pulmonary hemorrhage. *Ann Diagn Pathol*. 2001;5:309–319.
16. Schnabel A, Holl-Ulrich K, Dalhoff K, et al. Efficacy of transbronchial biopsy in pulmonary vasculitides. *Eur Respir J*. 1997;10:2738–2743.