

# Safe Esophageal Bougie Placement for Laparoscopic Hiatal Hernia Repair

David S. Edelman, MD, Moises Jacobs, MD, Christine Lopez-Penalver, MD, Kate Moses, RN

## ABSTRACT

The increased use of laparoscopy for treatment of reflux esophagitis has been associated with a 1-8% complication rate. Perforation of the esophagus from bougie placement, wrap breakdown or too tight a wrap are some of the complications seen from this surgery. An esophageal dilator system was developed to overcome these problems. Thirty patients had an esophageal dilator system used whereby a 48F or 58F dilator was placed over a 18F orogastric tube. Intraoperative gastroscopy documented a properly created wrap. There were no esophageal perforations or morbidity associated with the dilator.

**Key Words:** Laparoscopy, Hiatal hernia, Bougie.

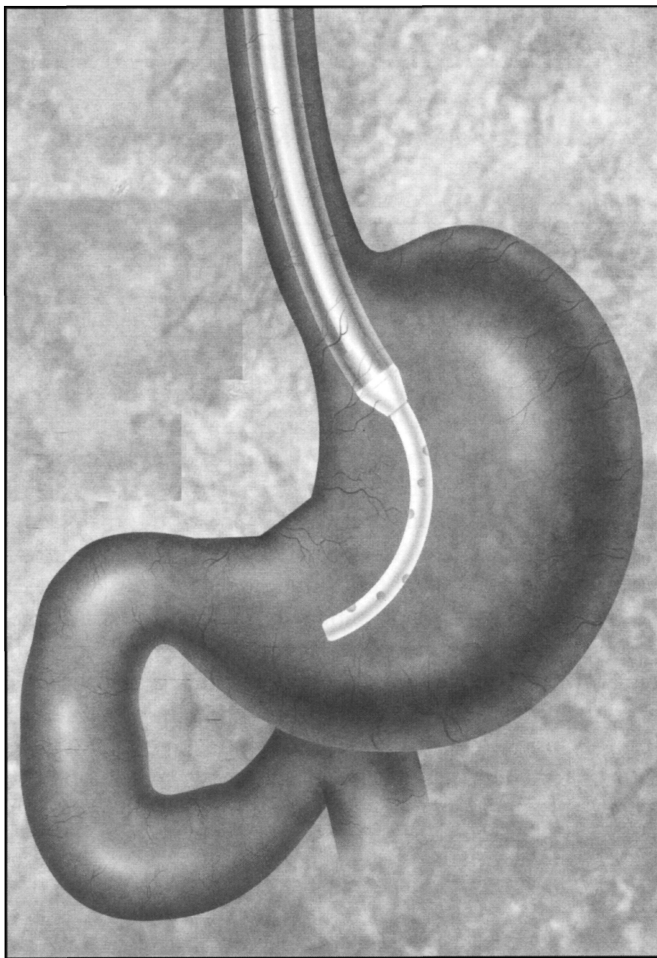
## INTRODUCTION

With the widespread use of laparoscopy in the 1990's, many patients with heartburn and sequelae from gastroesophageal reflux disease (GERD) are undergoing repair of their hiatal hernias. Although there is a greater than 85% success rate, complications and failures occur following surgery (**Table 1**). A bougie is necessary for proper sizing of the esophageal hiatus and wrap. One of the major concerns during the operative procedure is safe placement of a dilator or bougie. Many times the passage of the bougie is not performed by the operating surgeon but by a surrogate, like the anesthesiologist. It is ironic that most surgeons are not concerned by the anesthesiologist placing an orogastric tube for intraoperative gastric decompression and rarely is this 18F tube a cause of a complication, like perforation. With this in mind, a dual tube system was developed to decrease the incidence of esophageal perforation and allow safe dilator placement.

## TECHNIQUE

The first portion of the system is a standard 18F single lumen 'Levine-type' tube. The length is marked to assist placing the tip of the tube through the mouth into the stomach. It is extended with a screw cap to double the length and allow easy threading of the bougie over the 'Levine' tube. The second portion of the system is a clear dilator measuring 48F or 58F where the tip is bored out to allow passage of an 18F tube. It has marks indicating distance from the tip to guide the operator and surgeon while advancing the bougie down the esophagus and into the stomach. Generous lubrication should be utilized. The surgeon using the laparoscope should observe the dilator pass into the stomach as the operator indicates the length of bougie passed. The surgeon may need to grasp the stomach as the bougie reaches the gastroesophageal junction. Usually the gastroesophageal junction is about 45 cm from the teeth. The bougie can be pulled back or readvanced, as needed, during the hiatal hernia repair as sutures are placed or as the wrap is pulled behind the esophagus. The 18F orogastric tube has a dual purpose—to suction out the stomach and to act as a guide for the dilator to be passed directly into the stomach (**Figure 1**). At the completion of the surgery, the 18F orogastric tube may be replaced through the nose for postoperative gastric decompression.

Address reprint request to: David S. Edelman, MD, FACS, The Gallbladder & Laparoscopic Surgery Center, 8720 North Kendall Drive, Suite 204, Miami, FL 33173. Telephone: (305) 271-4080, Fax: (305) 271-7663



**Figure 1. Bougie system in place in the stomach.**

**RESULTS**

Laparoscopic repair of hiatal hernias was introduced at the Baptist Hospital Laparoscopic Surgery Center in 1994. Since that time, 145 patients have had the procedure performed. During the first 3 years of performing these procedures (102 patients), there were 5 perforations of the esophagus and 3 wraps that were redone for being too tight. A dilator system was developed and used on the next 43 patients. The initial system had a tapered tip. There was difficulty with this system in getting the stiff tapered tip past the oropharynx. This system was abandoned for a softer, blunt-tipped system much like a “Maloney” dilator. This was used on the next 30 patients with excellent success. There was one stomach perforation from an orogastric tube, but it was not related to the Dilator System. This perforation was recognized and repaired at the time of the hiatal hernia repair and caused no postoperative sequelae. All patients using the Dilator System had intraoperative esophagogastroscopy.

**Table 1.**  
Laparoscopic Fundoplication Statistics.

	1994	1995	1996	1997
Cases	14	43	45	43
Complications	3	5	7	5
pulmonary	0	0	5	3
abcess	2	0	1	0
perforation	0	3	2	1
bleeding	0	1	1	0
re-do, tight	1	1	1	0
Age	48.5	54.1	52.5	47.4
OR time	210	176.1	141.6	133.2
Hosp stay	2.07	2.8	2.3	1.66

**Table 2.**  
Rates of Perforations.

	% perforation
Weerts <sup>3</sup>	2.3
Schauer <sup>4</sup>	4.7
Hinder <sup>5</sup>	1.5
Swanstron <sup>6</sup>	1.3
Hunter <sup>7</sup>	1.3

The average age of all patients was 51 years, which did not change over the 4-year period. Operative time has declined to 132 minutes, after initial times began at 210 minutes. Length of hospital stay was 2.3 days for the first 3 years and, during 1997, had decreased to 1.66 days. Since the introduction of the new Dilator System, there have been 5 postoperative complications of which 3 were atelectasis, the one recognized gastric perforation noted above, and one patient returned to the OR on the same admission to have a Heller Myotomy following a Toupet fundoplication.

Intraoperative esophagogastroscopy was performed by one of the operating surgeons or the gastroenterologist who had referred the patient for surgery. It confirmed proper wrap size and placement, as well as testing the security of the sutures holding the wrap in place. The stomach was distended with air and submerged in saline during the gas-

troscopy to look for air bubbling indicating a perforation. There were no esophageal perforations found intraoperatively or postoperatively.

## DISCUSSION

The standard of any surgical procedure is the success rate associated with it. Reports in the literature have quoted excellent control of reflux symptoms after laparoscopic Nissen fundoplication from 85 to 91%.<sup>1,2</sup> However, with any surgical operation there are well recognized complications. Improvement and prevention of surgical complications is a major goal of any surgeon.

There are numerous reports in the literature discussing the benefits justifying laparoscopic fundoplication for the treatment of GERD. A few of the reports have been examined and the perforation rates and dysphagia rates identified (**Table 2**). Weerts and Dallemagne reported 1 perforation, 2 lacerations of the gastroesophageal junction and 1 wrap disruption in 132 patients.<sup>3</sup> Schauer et al.<sup>4</sup> reported on 17 perforations in 364 patients of which 5 were due to the passage of the bougie. One of the first reports in the literature in 1994 was by Hinder who noted 3 perforations in the first 198 patients.<sup>5</sup> Swanstrom and Pennings discussed safe dissection and had 2 complications from the bougie in 152 procedures.<sup>6</sup> Reporting on 300 patients over a 4 year period, Hunter et al. had 3 gastric perforations and 1 esophageal perforation.<sup>7,8</sup> These perforation rates are very low. The rate of esophageal perforation is probably higher in those institutions that are not performing this surgery at the same number of cases, much like our data.

It is imperative to take every precaution to perform safe laparoscopic dissection of the gastroesophageal junction. The GE junction in these patients is at high risk of perforation because of the chronic irritation from reflux juices and the angle of the junction below the crura. Passage of the bougie is for all intents and purposes a blind procedure.

There are very few reported or noted perforations from standard orogastric or nasogastric decompression tubes. The Seldinger technique for placement of catheters is well known to surgeons. With this in mind, the COOK Esophageal dilator set has been shown in this limited study to be safe and effective for placing a bougie during laparoscopic repair of hiatal hernias.

## References:

1. Peter JH, Heimbucher J, Kauer WK, Incarbone R, Bremner CG, DeMeester TR. Clinical and physical comparison of laparoscopic and open Nissen fundoplication. *JACS*. 1995;180(4):385-393.
2. Dallemagne B, Weerts JM, Markiewicz S, Jehais C, Lombard R. Laparoscopic Nissen fundoplication: preliminary report. *Surg Laparosc Endosc*. 1991;1:138-143.
3. Weerts JM, Dallemagne B, Hamoir E, Demarche M, et al. Laparoscopic Nissen fundoplication: detailed analysis of 132 patients. *Surg Laparosc Endosc*. 1993;3:359-364.
4. Schauer PR, Meyers WC, Eubanks S, Norem FR, Franklin M, Pappas TN. Mechanisms of gastric and esophageal perforations during laparoscopic Nissen fundoplication. *Ann Surg*. 1996;223(1):43-52.
5. Hinder RA, Filipi CJ, Wetscher G, Neary P, DeMeester TR, Perdakis G. Laparoscopic Nissen fundoplication is an effective treatment for gastroesophageal reflux disease. *Ann Surg*. 1994;220(4):472-483.
6. Swanstrom LL, Pennings JL. Safe laparoscopic dissection of the gastroesophageal junction. *Am J Surg*. 1995;169:507-511.
7. Hunter JG, Swanstrom L, Waring JP. Dysphagia after laparoscopic antireflux surgery. *Ann Surg*. 1996;224(1):51-57.
8. Hunter JG, Trus TL, Branum GD, Waring JP, Wood WC. A physiologic approach to laparoscopic fundoplication for gastroesophageal reflux disease. *Ann Surg*. 1996;223(6):673-687.