

Anterior Cable Tears in Arthroscopic Rotator Cuff Repairs



Paul B. Roache, M.D.

Purpose: To determine whether anterior cable tears could be identified at the time of arthroscopic rotator cuff repair and determine the characteristics of the anterior cable tears identified. **Methods:** From 2016 to 2017 all shoulder arthroscopies had data collected prospectively at the time of surgery, specifically including injury to the capsular and tendon zones of insertion on the greater tuberosity. Anterior cable position and degree of injury and medialization were recorded, as well as complete findings of the diagnostic arthroscopy. The inclusion criterion was primary shoulder arthroscopy. The exclusion criterion was any revision shoulder arthroscopy. All arthroscopic rotator cuff repairs (ARCR) were grouped together and all other nonarthroscopic rotator cuff repair surgeries (non-ARCR) were grouped together. **Results:** In total, 118 shoulder arthroscopies had data collected prospectively at the time of surgery: 90 primary shoulder arthroscopies met the inclusion criteria; 28 were excluded because they were revision surgeries. There were 42 patients in the ARCR group (Group 1). Six of these were partial tears, and 36 were full-thickness tears. There were 48 patients in the non-ARCR group (Group 2). The non-ARCR Group 2 served as an anatomic baseline for ARCR Group 1. In all 90 shoulders, the rotator cable and anterior cable were identified. Group 1 (ARCR) incidence of anterior cable tears with abnormal position was 71.4% compared to 2.1% in group 2 (non-ARCR) ($P < .001$) Group 1 (ARCR) incidence of anterior cable tears with normal anterior cable position ($n = 12$) was compared to abnormal anterior cable position ($n = 30$). Injury to the anterior footprint capsular and tendon zones were compared. Normal anterior cable position correlated with no or low-grade injury to anterior footprint capsular zone. (Nimura zone C1). Abnormal anterior cable displacement graded as moderate ($n = 20$) and severe ($n = 10$) were compared for injury to the anterior footprint. Moderate displacement correlated with complete or high grade injury to C1 in 85% and complete injury to R1 in 45% ($P < .001$ and $.049$). In severe displacement complete C1 injury was 100%, and complete R1 injury was 100% ($P < .001$ and $.001$). **Conclusions:** Anterior cable tears are universally identified in ARCR. Three patterns of medial displacement severity correlated with injury to a crucial insertion zone (C1) at the anterior footprint. The degree of anterior cable disruption at the anterior footprint and displacement was commonly disproportionately greater than the injury to the supraspinatus. **Level of Evidence:** Level III, diagnostic study.

The anterior attachment of the rotator cuff cable is essential for preserving superior capsule function, rotator cuff function, and shoulder kinematics.¹ Clinical and biomechanical studies have demonstrated the importance of repairing the superior capsule's anterior cable attachment in rotator cuff tears.²⁻⁵

From the Department of Orthopedic Surgery, California Pacific Medical Center, San Francisco, California, U.S.A.

The author reports no conflicts of interest in the authorship and publication of this article. Full ICMJE author disclosure forms are available for this article online, as [supplementary material](#).

Received September 3, 2020; accepted January 12, 2021.

Address correspondence to Paul B. Roache, M.D., California Pacific Medical Center, 2269 Chestnut Street, No. 975, San Francisco, CA 94123, U.S.A. E-mail: PBR@RoacheMD.com

© 2021 THE AUTHORS. Published by Elsevier Inc. on behalf of the Arthroscopy Association of North America. This is an open access article under the CC BY-NC-ND license (<http://creativecommons.org/licenses/by-nc-nd/4.0/>). 2666-061X/201498

<https://doi.org/10.1016/j.asmr.2021.01.007>

The rotator cable is the lateral thickening of the superior capsule with ligamentous fibers running in a semicircular direction from anterior to posterior.⁶⁻¹⁰ The superior capsule and the supraspinatus layers are fused and together comprise the superior rotator cuff complex.^{1,11} The importance of the superior capsule alone in rotator cuff function has been demonstrated with the success of superior capsule reconstruction for irreparable rotator cuff tears.¹²⁻¹⁴

The superior capsule's rotator cable layer and the supraspinatus tendon layer both insert on the greater tuberosity. The rotator cable capsular layer insertion covers a substantial amount of the greater tuberosity.^{1,8,15} The rotator cable layer has additional insertions anteriorly with fibers inserting onto the biceps pulley and upper border of the subscapularis.^{9,10,16}

The anterior cable insertion of the rotator cable is predominantly at the anterior footprint of the supraspinatus directly behind the bicep tendon. It has been

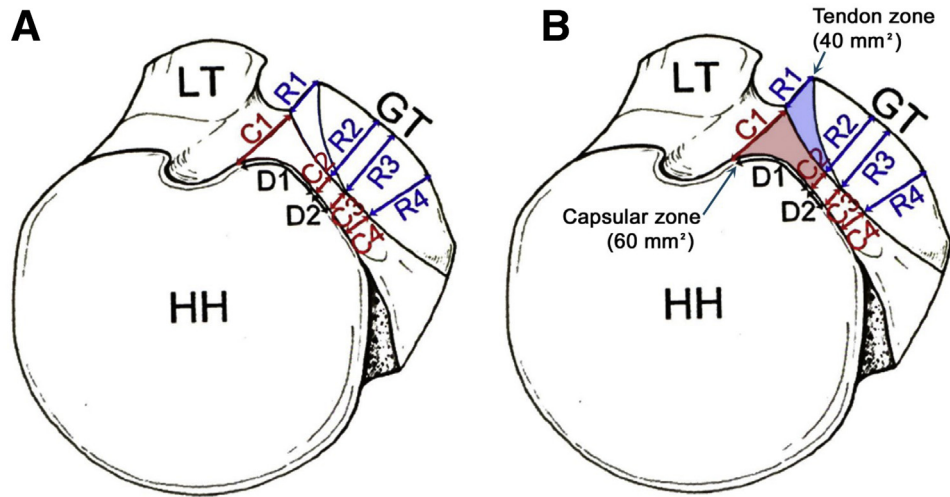


Fig 1. (A) Superior aspect of the humerus. (B) Anterior footprint 2 anatomical zones : C1 measures $5.6 \text{ mm} \pm 1.6 \text{ mm}$ (red capsular zone); R1 measures $3.5 \text{ mm} \pm 2.3 \text{ mm}$ (blue tendon zone); D1 measures $10.9 \text{ mm} \pm 3.1 \text{ mm}$. Area of capsular zone 60 mm^2 , Area of tendon zone 40 mm^2 (approximately). (C1, width of the attachment of the articular capsule at the anterior margin of the greater tuberosity; C2, minimum width of the attachment of the articular capsule; C3, width of the attachment of the articular capsule at the posterior margin of the supraspinatus; C4, width of the attachment of the articular capsule at the point of maximum width of the infraspinatus; D1, distance from anterior margin of the greater tuberosity to the point of minimum width of the articular capsule. D2, distance from point of minimum width of the articular capsule to the posterior margin of the supraspinatus; GT, greater tuberosity; HH, humeral head; LT, lesser tuberosity; R1, width of the footprint of the supraspinatus at the anterior margin of the greater tuberosity; R2, width of the footprint of the supraspinatus and infraspinatus at the point of the minimum width of the articular capsule; R3, width of the footprint of the infraspinatus at the posterior margin of the supraspinatus; R4, maximum width of the footprint of the infraspinatus. Reproduced with permission from K. Nimura et al. The superior capsule of the shoulder joint complements the insertion of the rotator cuff. *Journal of Shoulder and Elbow Surgery* 2012;21:867-872.

described as the 8 to 12 mm of the supraspinatus insertion immediately posterior to the bicipital pulley and bicipital groove.⁴

Although it is anatomically ligament and distinctly different from the supraspinatus tendon, the cable and tendon insertion have generally been considered as a single anatomic structure, with no distinction made of the anterior cable from the supraspinatus tendon at the anterior footprint.

Nimura et al.¹ in a 2012 anatomic study mapped and measured the 2 layers of insertion of the superior capsule and the rotator cuff tendons on the greater tuberosity. Their study defined 2 distinct zones of insertion at the anterior footprint. The capsular insertion zone of the anterior cable and the tendon insertion zone of the supraspinatus. This defined the anterior footprint as 2 distinct anatomic structures. The size of the capsular and tendon zones was measured, and by area the capsular insertion zone of the anterior cable was larger than the tendon insertion zone of the supraspinatus. The capsular zone was approximately 60 mm^2 for the anterior cable insertion and the tendon zone was 40 mm^2 for the supraspinatus tendon insertion (Fig 1).

This demonstrated that the anterior footprint was not only comprised of 2 distinct zones, but that by area, the anterior footprint was mostly capsular insertion of the anterior cable. The supraspinatus tendon insertion was by area the minority of the anterior footprint. This definitively demonstrates that rotator cuff tears of the anterior footprint are predominantly superior capsule injuries resulting from anterior cable tears at the footprint and not simply supraspinatus tendon tears. Currently, the focus of arthroscopic rotator cuff repair (ARCR) could be described as a tendon-first repair approach. Yet, by footprint anatomy, a cable-first repair approach to compliment tendon repair in ARCR is warranted. The cable-first approach would restore superior capsule function and more fully restore both the capsular and tendon components of the anterior footprint.¹⁷

Clinically, at time of ARCR, anterior cable tears (ACT) at their insertion in the anterior footprint have not been specifically distinguished from the tendon tear of the supraspinatus from its insertion. Although there are several studies that address repairing the "deep lamina" in ARCR, and 1 study that addresses repairing the superior capsule in ARCR.^{16,18-20} Knowledge is limited on

<p>[SECTION #4B]</p> <p>1-GH Insufflation: 32-Bursal insufflation</p> <p>2-Biceps insertion: 33-SAS:</p> <p>3-SLAP: 34-CAL/Acromion:</p> <p>4-Superior Labrum: 35-GT:</p> <p>5-CGL: 36-AC/CC L:</p> <p>6-SGHL: 37-Coracoid:</p> <p>7-MGHL: 38-CHL:</p> <p>8-Superior AB-IGHL: 39-SSC:</p> <p>9-AB-IGHL: 40-RI</p> <p>10-Inferior Labrum/cap:</p> <p>11-PB-IGHL:</p> <p>12-Posterior Labrum:</p> <p>13-Glenoid:</p> <p>14-RI:</p> <p>15-SSC:</p> <p>16-SGHL:</p> <p>17-Anterior Pulley</p> <p>18-Pulley Roof:</p> <p>19-Biceps:</p> <p>20-Posterior Pulley</p> <p>21-Cable-Anterior:</p> <p>22-C1/Crucial zone:</p> <p>23-Mid Cable:</p> <p>24-Crescent:</p> <p>25-C2-C3</p> <p>26-C4 of PCF</p> <p>27-Barespot-hum:</p> <p>28-T min :</p> <p>29-Humeral Head:</p> <p>30-Post Capsule:</p> <p>31-Sup Capsule:</p>	<p>Name: _____ Date sheet for shoulder arthroscopy patients:</p> <p>DOB: _____ Age: _____ Sex: F M</p> <p>Sx side: L R</p> <p>DOx: _____</p> <p>previous sx no yes type: ARCR, ASAD, Bankart</p> <p>ARCR (not SSC): no yes</p> <p>anchors: 0, 1, 2, 3, 4, 5, 6, 7, 8,</p> <p>-Acute tear no yes</p> <p>-Tear pattern crescent U L ant L post</p> <p>-Tear Size small(1) med(1-2) Large(2) Massive(2+) irreparable(2+)</p> <p>-CAFR no yes cable position: ni, lat, med, indeterminate</p> <p>-TMS/MTB no yes</p> <p>-IS repair no yes</p> <p>-Type side to side anchor tms/mtb</p> <p>-crimson duvet w msc vents, w msc vents #</p> <p>-Cable Recon no yes Biceps, graft</p> <p>-Margin conv no yes</p> <p>Biceps tenod no yes, soft tissue, Anchor at BG, subpec to cable to CAF</p> <p>Biceps aug no yes</p> <p>Biceps tenot no yes</p> <p>xenograft (rotation) no yes size: _____ location: _____</p> <p>SCR no yes graft?</p> <p>ASAD no yes</p> <p>ACA no yes</p> <p>ASCD no yes</p> <p>Labrum repair no yes, type: SLAP, AS, Bankart, Posterior anchors 0,1,2,3,4,5,6</p> <p>Capsular release no yes, Ri, Sup, Post, Ant,</p> <p>ASMC release no yes,</p> <p>C1L release no yes, type: partial, complete</p> <p>Additional sx no yes describe: _____</p> <p>SSC tear no yes size: low grade high grade complete</p> <p>-Footprint tear no yes type: partial complete loc: F1, F2, F3, F4</p> <p>-SSC repair no yes, type: soft tissue, anchored</p> <p>C1 injury (crucial) no yes, type: low gr <5mm, High grade 5mm&gt;, complete</p> <p>R1 SSCT tear (latS) no yes, type: partial, complete</p> <p>SSC/Antpul (antS) no yes, type: partial, complete</p> <p>Cable position ni abn, abn: mod, severe(at glenoid)</p> <p>Cable Shape ni abn, abn: arch, U, broken</p> <p>Crescent C2-3 tear no yes, type: partial, complete</p> <p>C4-5 tear no yes type: partial, complete</p> <p>IS R2,3-4 tear no yes type: partial, complete loc: 2, 3, 4</p> <p>Tm RS tear no yes type: partial, complete</p> <p>Cable dysfunction no yes, type: CAF 1, 2, 3, 4, Cable 1, 2, 3 Combined</p> <p>Biceps tear no yes type: partial, complete</p> <p>Slap tear no yes type: 1 2 3 4</p> <p>Labrum tear no yes type: ant sup, ant inf, post sup, post inf</p> <p>CM no yes loc: glenoid, HH, both grade: 1 2 3 4</p> <p>CAL tear no yes</p> <p>Acrom spur no yes</p> <p>ACOA no yes</p> <p>Special Video/imaging: _____ Notes: _____</p>
--	---

Fig 2. Surgical checklist and data sheet.

the details of specifically identifying ACTs as distinct injuries at the time of ARCR. Consequently, there is little known on the effect of specifically repairing the anterior cable tear as part of ARCR.

Our limited understanding may relate to variance in ability to identify the superior capsule and rotator cable at the time of ARCR. One recent study called into question the ability to identify the rotator cable during ARCR. Identification of the anterior cable tear is a prerequisite for specifically repairing it during ARCR, no matter how essential it may be.

The purpose of this clinical anatomic study was to determine whether anterior cable tears could be identified at the time of ARCR and to determine the characteristics of the ACTs identified. The hypothesis was that the identification of the ACT from its insertion on the anterior footprint was a consistent finding in ARCR.

Methods

From January 2016 to June of 2017, all shoulder arthroscopies had data collected prospectively at the time of surgery. A standardized diagnostic arthroscopy checklist was completed, and the findings were prospectively documented by video and use of an extensive operative data sheet that was completed at surgery (Fig 2). The inclusion criterion was primary shoulder arthroscopy. The exclusion criterion was any revision

shoulder arthroscopy. All ARCRs CPT 29827 were grouped together, and all other nonarthroscopic rotator cuff repair surgeries (non-ARCR) were grouped together.

The non-ARCR group served as an anatomical baseline for reference in evaluating the anterior cable position and its attachment in shoulders that did not require ARCR. A single fellowship-trained senior orthopedic surgeon (P.B.R.) specialized in shoulder surgery performed all surgeries. All surgeries were performed with patients in the lateral decubitus position.

During surgery glenohumeral structures were observed and documented while viewing from a posterior medial portal using a 30° arthroscope. Further assessment was completed of bursal structures from a lateral subacromial portal. The Nimura zones of capsular insertion and tendon insertion were specifically applied to the evaluation of the greater tuberosity. The zones and injury to the zones were estimated by visual observation using a 5 mm shaver as a reference for estimating size and depth of injury. Injuries to the zones were estimated as partial or complete. In the C1 zone partial injuries were further estimated to be low grade if <5 mm and high grade if >5 mm. The rotator cable was identified by identifying its posterior attachment and following the semicircular transverse-

Table 1. Injury Patterns in ARCR Group Versus Non-ARCR Group

	ARCR group (n = 42)		Non-ARCR (n = 48)		P Value
	N	%	N	%	
Anterior cable in normal position	12	28.6	47	97.9	<.001*
Anterior cable in abnormal position	30	71.4	1	2.1	<.001*
Cable with moderate displacement (midway to glenoid)	20	47.6	1	2.1	<.001*
Cable with severe displacement (at glenoid)	10	23.8	0	0.0	<.001*
C1—No injury	3	7.1	36	75.0	<.001*
C1—Injury	39	92.9	12	25.0	<.001*
C1—Low-grade injury	11	26.2	11	22.9	.808
C1—High-grade injury	6	14.3	1	2.1	.047*
C1—Complete injury	22	52.4	0	0.0	<.001*
R1—Partial injury	12	28.6	0	0.0	<.001*
R1—Complete injury	20	47.6	0	0.0	<.001*
LRI—Partial injury	10	23.8	1	2.1	.002*
LRI—Complete injury	3	7.1	0	0.0	.098
R2—R4 IS insertion injury	36	85.7	0	0.0	<.001*
C2—C3 crescent injury	33	78.6	6	12.5	<.001*

ARCR, arthroscopic rotator cuff repairs; C1, width of the attachment of the articular capsule at the anterior margin of the greater tuberosity; C2, minimum width of the attachment of the articular capsule; C3, width of the attachment of the articular capsule at the posterior margin of the supraspinatus; IS, infraspinatus; LRI, lateral rotator interval; non-ARCR, nonarthroscopic rotator cuff repair surgeries; R1, width of the footprint of the supraspinatus at the anterior margin of the greater tuberosity; R2, width of the footprint of the supraspinatus and infraspinatus at the point of the minimum width of the articular capsule; R3, width of the footprint of the infraspinatus at the posterior margin of the supraspinatus; R4, maximum width of the footprint of the infraspinatus.

*Significant difference.

oriented fibers forward to their end point. An empiric definition of anterior cable displacement was made as follows: The anterior cable position was evaluated as normal or minimally displaced if the lateral edge of the anterior cable was within 1 cm of the articular edge of the lateral biceps pulley. When the lateral edge of the anterior cable was retracted medially greater than 1 cm from the articular edge of the lateral biceps pulley but greater than 1 cm from the superior labrum, a location approximately halfway between the articular edge and the superior labrum was evaluated as a moderate displacement. The anterior cable was evaluated as a severe medial displacement if it was within 1 cm of the superior labrum. Anterior cable position was evaluated for normal position versus abnormal position as it correlated with injury to the Nimura C1 zone.

This retrospective review of existing surgical data met the conditions for Institutional Review Board exemption criteria under 45 CFR 46.101(b)(4), and appropriate Institutional Review Board exemption documentation was obtained. No external source of funding was provided for this study.

Statistics

Statistical analysis was performed using SPSS Version 22 (IBM Corp, Armonk, NY). Categorical variables for the 2 study groups were compared using χ^2 analysis, and Cramer's V was performed to assess nominal-by-nominal measures of association. Fisher's exact test (F-statistic) is reported where appropriate. All data analyses were 2-sided, and results were considered statistically significant at the $P < .05$ level.

Results

A total of 118 patients underwent shoulder arthroscopy during the study period. Ninety primary shoulder arthroscopies met the inclusion criteria; 28 were excluded because they were revision surgeries. There were 42 patients in the arthroscopic rotator cuff repair group (ARCR Group 1). Six of these were partial tears, and 36 were full-thickness tears. There were 48 patients in the nonarthroscopic repair group (Non-ARCR Group 2). Group 2 served as an anatomic baseline for reference in evaluating the anterior cable position and its attachment in shoulders that did not require ARCR.

In all 90 shoulders, the rotator cable and anterior cable were able to be identified. The characteristics of ACT from the anterior cable insertion was first compared between the ARCR Group 1 and the non-ARCR Group 2 and are listed in Table 1.

In Table 1 the anterior cable position was observed as abnormal in 71.4% of the ARCR Group 1 compared to 2.1% of the Non-ARCR Group 2. There was a significant difference in injury to C1 zone for the 2 groups. C1 injury occurred in 92.9% of the ARCR Group 1 compared to 25% of the Non-ARCR Group 2. The 1 patient in the Non-ARCR group with an abnormal cable position had a unique configuration of the anterior cable in a medialized position with a direct biceps insertion into the anterior cable. There was no injury observed to the C1 location or rotator cuff. Eleven of 12 patients in the Non-ARCR group had low grade injuries to C1. One of 12 had a high-grade injury to C1 but did not require ARCR because of other pathology. Further analysis of the characteristics of the anterior cable tear

Table 2. Difference in Amount of Cable Displacement by Zone of Injury Compared to Normal Cable Position in ARCR Group (n = 42)

	Normal Cable Position in ARCR Group (n = 12)		Abnormal Cable Position: Moderate Displacement (n = 20)		P Value	Abnormal Cable Position: Severe Displacement (n = 10)		P Value
	N	%	N	%		N	%	
C1—No injury	3	25.0	0	0.0	.044*	0	0.0	.221
C1—Low-grade injury	8	66.7	3	15.0	.006*	0	0.0	.002*
C1—High-grade injury	1	8.3	5	25.0	.370	0	0.0	1.00
C1—Complete injury	0	0.0	12	60.0	.000*	10	100	.000*
R1—No injury	9	75.0	1	5.0	.000*	0	0.0	.000*
R1—Partial injury	2	16.7	10	50.0	.075	0	0.0	.481
R1 - Complete injury	1	8.3	9	45.0	.049*	10	100	.000*
LRI—No injury	12	100	17	85.0	.274	0	0.0	.000*
LRI—Partial injury	0	0.0	3	15.0	.274	7	70.0	.001*
LRI—Complete injury	0	0.0	0	0.0	1.00	3	30.0	.078
R2— R3 IS insertion injury	7	58.3	19	95.0	.019*	10	100	.039*
C2— C3 crescent injury	7	58.3	16	80.0	.240	10	100	.039*

ARCR, arthroscopic rotator cuff repairs; C1, width of the attachment of the articular capsule at the anterior margin of the greater tuberosity; C2, minimum width of the attachment of the articular capsule; C3, width of the attachment of the articular capsule at the posterior margin of the supraspinatus; IS, infraspinatus; LRI, lateral rotator interval; non-ARCR, nonarthroscopic rotator cuff repair surgeries; R1, width of the footprint of the supraspinatus at the anterior margin of the greater tuberosity; R2, width of the footprint of the supraspinatus and infraspinatus at the point of the minimum width of the articular capsule; R3, width of the footprint of the infraspinatus at the posterior margin of the supraspinatus; R4, maximum width of the footprint of the infraspinatus.

*Significant difference from normal cable position.

medial displacement was completed in the ARCR Group 1 (n = 42) as it related to the extent of injury in the two specific footprint zones.

Anterior Cable Position and Specific Footprint Zone injury in ARCR Group 1 (Table 2)

Normal Anterior Cable Position

In patients having normal anterior cable position in the ARCR group (n = 12), C1 zone injuries occurred in 9 shoulders (75%), with the majority of injuries graded as low grade (66.7%). R1 zone injuries occurred in 25% of shoulders (n = 3) in this subgroup. Three of the 12 shoulders (25%) were partial bursal-sided rotator cuff tears.

Moderate Abnormal Anterior Cable Position

In the ARCR group having moderate abnormal anterior cable position (n = 20), C1 zone injury was present in 100% of shoulders. This C1 injury occurrence was significantly greater than that of the ARCR group having normal anterior cable position (P = .044). The majority (85%) of these injuries were graded as high grade or complete. The occurrence of low-grade C1 injuries (15%) and complete C1 injuries (60%) differed significantly from those injury levels in cases with normal anterior cable position (P = .006, P < .001). The R1 zone had injury in 95% of shoulders in this subgroup, with complete R1 injuries being significantly higher than those of the normal anterior cable position group (P = .049). Additional injury was noted anterior to the anterior footprint zones in the

biceps pulley of the lateral rotator interval. This injury was graded as a partial injury and was present in only 15% of the shoulders. Three of 20 shoulders (15%) has partial articular-sided rotator cuff tears.

Severe Abnormal Anterior Cable Position

In the ARCR group with severe anterior cable abnormal position, there was complete injury in the C1 zone in 100% of shoulders, a statistically more significant difference than the occurrence of complete C1 injury in ARCR cases with normal anterior cable position (P < .001). The R1 zone had a complete lesion in 100% of shoulders, again a significantly higher occurrence than in normal anterior cable position cases in this group (P < .001). Additional injury was noted anterior to the anterior footprint zones in the medial biceps pulley of the lateral rotator interval. This injury was present in 100% of the shoulders, with 70% being partial injury (P = .001) and 30% being complete.

Overall, 91.7% of patients with little or no anterior cable displacement have no significant injury to C1, and 85% of patients with moderate displacement have a significant disruption of the C1 zone. Only 45% of patients with moderate displacement have a significant disruption of R1 zone. The C1 zone injury high correlation with ACT displacement identifies the C1 zone as a "crucial zone" of injury in ACT medial displacement (Fig 3).

Three characteristic patterns of anterior cable tears were identified by the amount of medial displacement of the anterior cable from this crucial zone(C1). The

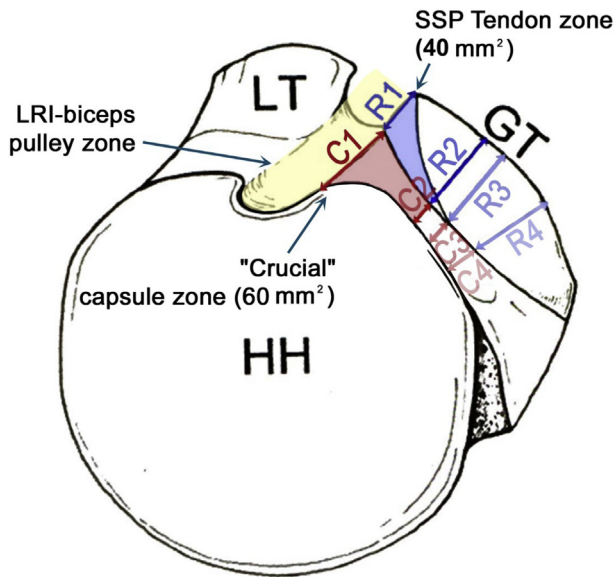


Fig 3. The anterior footprint on the greater tuberosity 2 zones are the C1 capsular zone (red) and the R1 supraspinatus tendon zone (blue). The results of the data demonstrate the following: (1) The anterior cable position is dependent first on the capsular zone at C1. When the anterior cable tears away from the crucial zone, it begins to medialize. Injury to the C1 zone correlated with the anterior cable position. The results indicate that the C1 zone is “crucial” for maintaining the anterior cable position and preventing medialization of the anterior cable. (2) The R1 tendon zone of the anterior footprint supports the C1 “crucial zone” and helps maintain the anterior cable position. As injury extends into the R1 zone from the crucial zone (C1), the anterior cable tear moderately medializes away from the footprint toward the glenoid. The LRI-biceps pulley supports the crucial zone (C1) and the tendon zone (R1). Injury that extends into the biceps pulley and includes the roof or medial biceps sling allows the anterior cable to severely retract medially to the glenoid. The results indicate that the C1 zone is a “crucial” zone for maintaining anterior cable position and preventing medialization of the anterior cable. The crucial zone (C1) is further stabilized by the R1 zone (supraspinatus tendon) and the biceps pulley of the lateral rotator interval. (C1, capsular zone [red]; GT, greater tuberosity; HH, humeral head; LRI, lateral rotator interval [yellow]; LT, lesser tuberosity; R1, tendon zone [blue]; SSP, supraspinatus).

severity of the medial displacement correlated directly with the increasing disruption of the insertion of the crucial zone (C1) and indirectly with disruption of the supraspinatus tendon zone (R1). This was found in both full-thickness and partial tears. The degree of anterior cable displacement was not directly related to supraspinatus displacement. This created a gap from the torn edge of the anterior cable and the torn edge of the supraspinatus. In full thickness tears at C1 and R1 the intimate connection of the anterior cable and cuff separated into distinct layers (Fig 4).

Discussion

The results of this study supported the hypothesis. The identification of the rotator cable was universal in both groups of patients. Specifically, the identification of the ACT in patients undergoing ARCR for a full-thickness tear was universal. Identification of ACTs with displacement was very common in the ARCR group and rare in the non-ARCR group. Injury to the anterior cable insertion at C1 was nearly universal in the ARCR group and infrequent in the non-ARCR group. The degree of anterior cable disruption at the anterior footprint and displacement was commonly disproportionately greater than the injury to the supraspinatus. These results indicate that the C1 zone is a “crucial” zone for maintaining anterior cable position and preventing medialization of the anterior cable. The crucial zone (C1) is further stabilized by the R1 zone (supraspinatus tendon) and the biceps pulley of the lateral rotator interval (Fig 3).

This is an essential first step to include repair of the ACT at the time of ARCR. The identification of the ACT and the footprint injury allow the surgeon to specifically and purposely repair the ACT with the tendon. The ACT repair with the tendon repair at ARCR anatomically restores the two zones of the anterior footprint.

Separate identification of the ACT and the supraspinatus tear is necessary because each injury retracts medially to different degrees, which creates a separation of the torn edges and a gap between edges. This is likely related to the tensile differences of each component. The degree of anterior cable disruption at the anterior footprint and displacement was commonly disproportionately greater than the injury to the supraspinatus.

The increasing severity of medial displacement of the ACT observed in this study implies increasing loss of function of the rotator cable and superior capsule, resulting in a decoupling of forces to the proximal humerus, as well as the anterior and posterior rotator cuff. The increasing medial displacement of the ACT occurred as injury progressed through its primary insertion at the crucial zone (C1) and expanded into the secondary stabilizers at the anterior footprint. As the ACT medializes, the superior capsule loses its native tension. The horizontal force couple becomes uncoupled, superior instability develops, and supraspinatus force transmission to the proximal humerus diminishes.^{2,20,21}

Kim et al.²² demonstrated supraspinatus fatty degeneration in 88% of full-thickness tears that included the region directly posterior to the biceps. This is the same location as the crucial zone (C1) in the results of this study and corresponds directly to the creation of the anterior cable tear. This may provide an

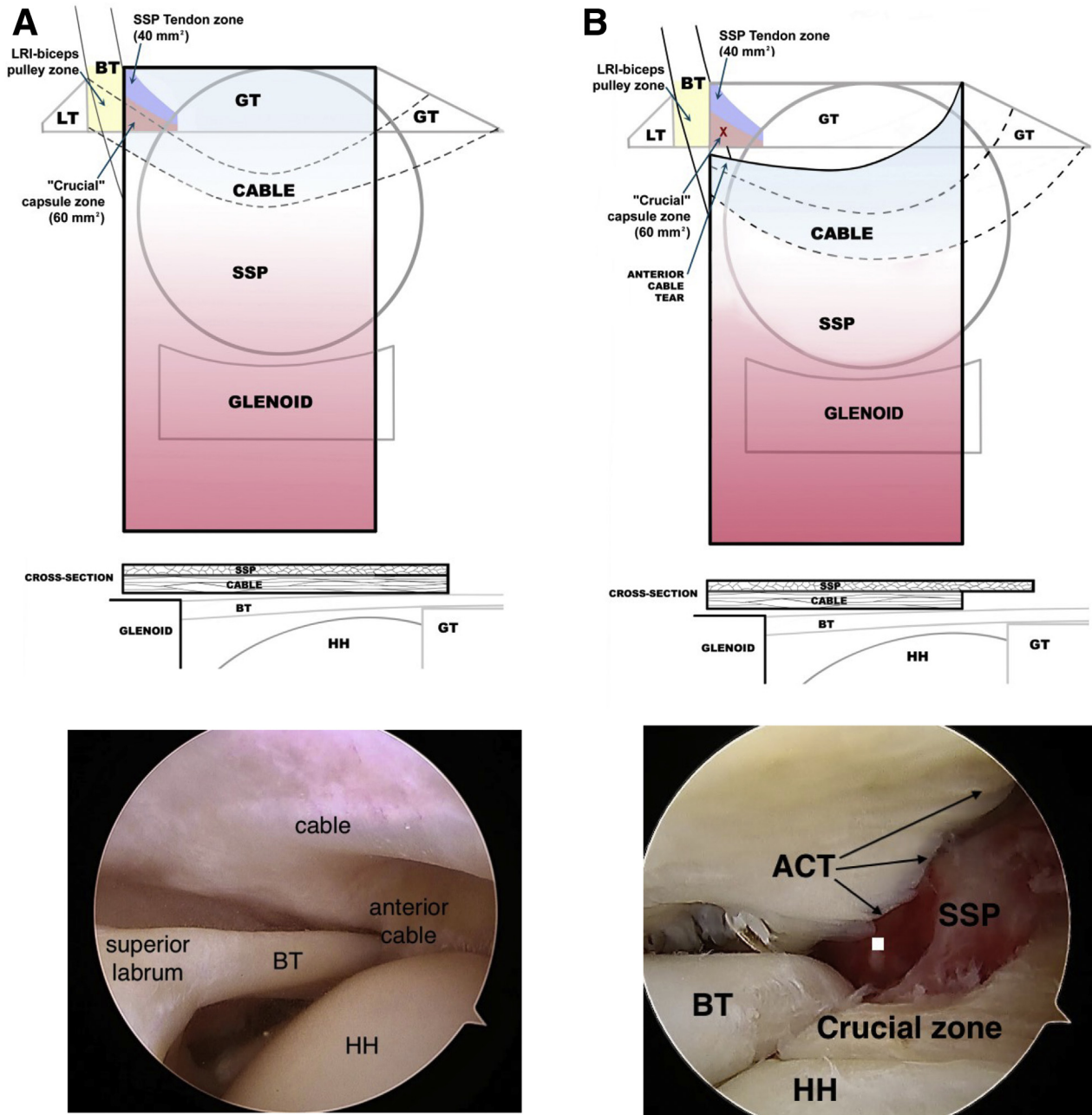


Fig 4. Anterior cable tear characteristics: Superior view and lateral cross-section of supraspinatus and cable with clinical picture demonstrating cable and anterior cable position. Clinical pictures: Arthroscopic views from posterior medial portal. (Lateral position with arm in 40° abduction and 20 FF and scope rotated 90° to bring the shoulder upright). (A) Normal cable and anterior cable position with no injury. (B) ACT 1, anterior cable tear with no or minimal medial displacement (<1 cm). Minimal change in shape of the cable; typically found in pasta tears and bursal tears. Partial to complete disruption of crucial zone (C1) or complete disruption of supraspinatus tendon zone (R1). (C) ACT 2, Anterior cable tear with moderate medial displacement (>1 cm from crucial zone laterally and superior labrum medially) Distinct change in shape of cable can be noted; Usually to a “U” or arch; Typically found in full-thickness tears that expose the biceps partially with disruption of the lateral biceps sling. Complete disruption of crucial zone (C1), plus partial to complete disruption of supraspinatus tendon zone (R1). (D) ACT 3, Anterior cable tear with severe medial displacement (<1 cm from superior labrum). Usually a complete loss of shape from a broken cable, like the handle of a bucket breaking free from its attachment. The biceps is completely exposed with complete disruption of the lateral biceps sling and a partial to complete disruption of the medial biceps sling. Complete disruption of crucial zone (C1), plus complete disruption of supraspinatus tendon zone (R1), plus at least partial injury to biceps pulley (lateral and medial pulley). (ACT, anterior cable tear; BT, biceps tendon; GT, greater tuberosity; HH, humeral head; LRI; lateral rotator interval; LT, lesser tuberosity; SSP, supraspinatus; X(red), injury to zone).

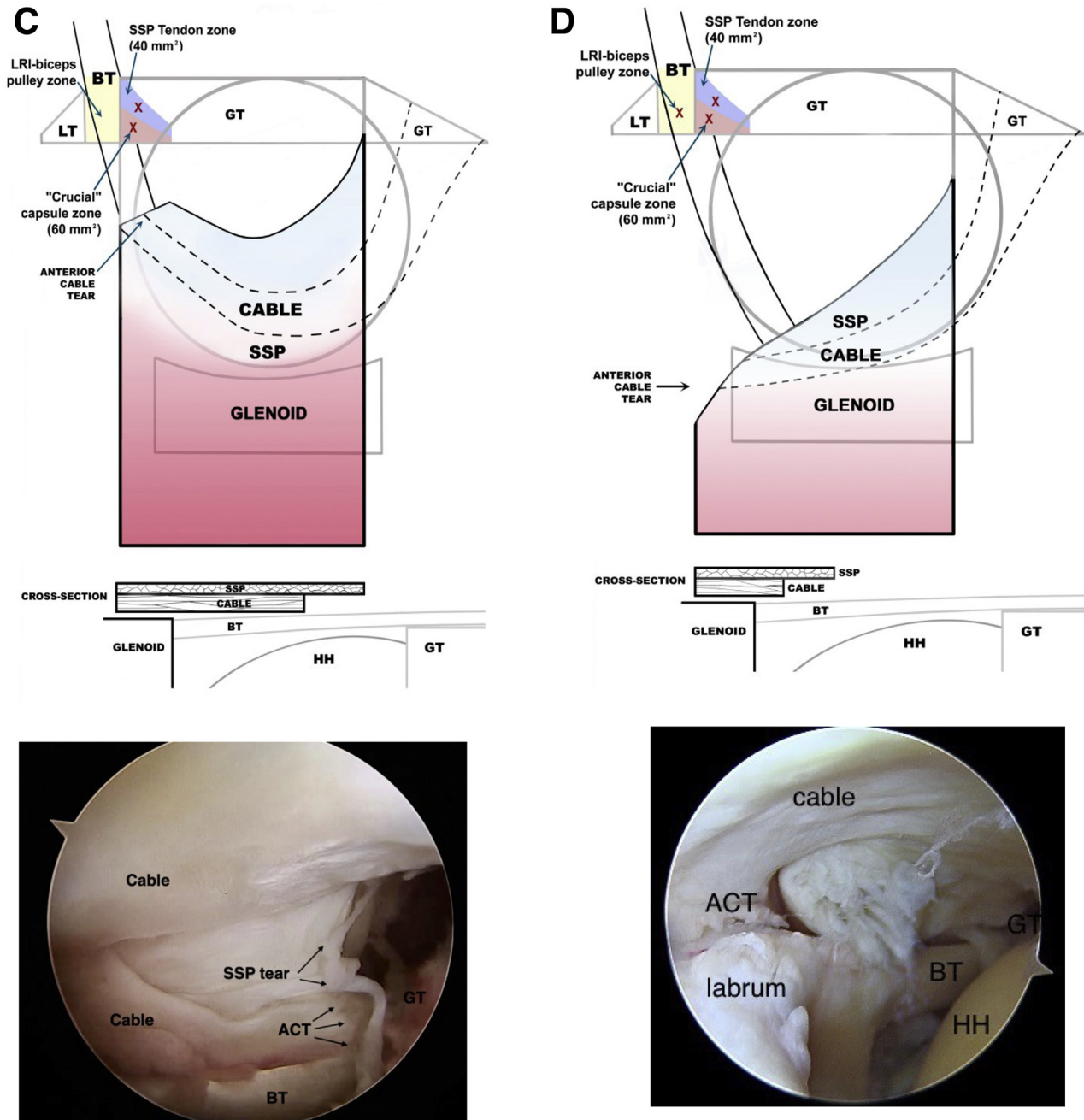


Fig 4. Continued.

anatomic and biomechanical rationale for the increased fatty degeneration of the supraspinatus of tears outlined in their study.

Despite the increasing evidence of the importance of restoring the function of the rotator cable and the superior capsule as part of ARCR, the identification of the rotator cable has been reported to vary at time of surgery. This represents a significant potential obstacle to include ACT repair at ARCR. Davis et al.²³ reported that the rotator cable was verified in only 10% of patients under age 40 and was not able to be verified in 20% of

patients over age 40. Habermeyer et al.²⁴ reported a positive “cable sign” in only 62.5 % in their study. Wieser et al.²⁵ reported that, although the rotator cable was well identified in the lab setting, it was not always possible to identify the cable at ARCR.

In contrast to those studies, the results of this clinical anatomic study observed a universal identification of the rotator cable at ARCR, confirming what numerous lab studies have reported.^{4,5,7-9} This variance in ability to reliably identify the cable in this study from those previous studies is likely the result of several factors:

Table 3. Biomechanical and Biological Advantages of ACT Repair

Biomechanical	Biological
<ul style="list-style-type: none"> • Restoration of shoulder kinematics by reestablishing the pre-injury physiological tension of the cable and superior capsule. Avoiding the negative impact of overtensioning the repair³² • Improved rotator cuff force transmission and distribution to the proximal humerus by an anatomic anterior footprint repair of both footprint components • Reestablishing or restoring the horizontal force couple of the front and back rotator cuff³⁰ • Decreased strain on the tendon bone interface of the repair • Improved suture hold for cable/tendon en-masse repair²⁵ • Restoration of concavity compression stability with closed capsule 	<ul style="list-style-type: none"> • Reduced strain at repair site positive healing effect³³ • Limits joint fluid into tendon repair site, restores tendon enthesis as “extra-articular”, resulting in more organized tendon bone interface³⁴

First, superior capsule anatomy can vary, and although the lateral capsule is very consistent, the rotator cable configurations can vary substantially. The rotator cable has a range of normal configurations from “cable dominant” to “crescent-dominant.”⁶ This range of configurations can greatly affect how the rotator cable is being defined and be identified in the altered anatomy encountered in ARCR. Often, in rotator cuff tears, it no longer appears “cable” or “cord” like, and in younger patients often has no crescent zone. It is commonly covered by a thick synovium that may obscure from view the semicircular transverse sweep of its fibers.^{8-10,26} Synovitis is common in rotator cuff tears and may obscure direct visualization of the cable, if not fully debrided. In addition, the deep layer of the cable has often retracted more medially than the torn tendon edge. The tendon edge will be thinner laterally to the retracted cable layer in tears that have not delaminated.

Second, portal placement, patient position, arm position and pump pressure can also greatly affect how readily the superior capsule and rotator cable are viewed and identified. Reliable identification of the cable and ACT during ARCR requires both a broader understanding of the altered cable anatomy and a good portal vantage point for viewing the cable.

Anterior cable tears have been reliably identified and described in previous studies. The injury to the anterior cable insertion at the crucial zone (C1) described in this study has been described previously but with terminology of the supraspinatus to represent the entire anterior footprint.

Habermeyer et al.²⁴ in 2008 observed that 73% of articular-sided supraspinatus tears involved the coracoacromial ligament (CHL; lateral biceps pulley), a type “2C” in their classification. The lateral biceps pulley is anterior edge of the anterior cable insertion of the crucial zone (C1).

Martetschlager et al.²⁷ in 2020 revised the classification of biceps pulley lesions by Habermeyer et al.²⁸ in 2004. They also reported a high frequency of anterior superior supraspinatus tears associated with the lateral biceps pulley lesions (Habermeyer type 2) and that the

anterior superior rotator cuff was an indirect stabilizer of the biceps pulley.^{16,27,28} The CHL has been documented as a key anatomic component of the biceps pulley at the lateral rotator interval.^{10,16,29} The lateral biceps pulley (CHL) is confluent anatomically with the crucial zone (C1).

In the earlier observations of Habermeyer and Martetschlager the anterior footprint stabilized the biceps pulley. The results of this article on identification of the ACT indicate that the supraspinatus tendon and the biceps pulley appear to stabilize the anterior cable insertion at the crucial zone (C1). Essentially, this confirms the earlier observations by Habermeyer and Martetschlager but from a different perspective, the anterior cable perspective. Together, these 2 perspectives are complimentary and describe the full array of injuries encountered in the anterior superior corner complex.

The importance of repairing the ACT at ARCR has not been specifically addressed in clinical studies. However, there is significant evidence that it is important to improving ARCR outcomes. Several studies address repairing the “deep lamina” either in layers or en masse at ARCR.¹⁷⁻²⁰ One study noted “delamination” after ARCR as a negative prognostic factor but also noted that delamination was frequently missed.¹⁸ Only one study addresses repairing the “superior capsule” specifically as part of ARCR.²

The delamination layer described in these articles is the superior capsule layer, because the deep layer delamination is distinguished from the tendon layer. Delamination is a complete separation of the layers, whereas the ACT is typically a partial separation of the intimate connection of the footprint with a gap created between the edge of the tendon and the anterior cable but with the cable cuff connection preserved medial to the cable.

The ACT has been shown to diminish rotator cable function and superior capsule function. The importance of the superior capsule in rotator cuff function has been become clear both clinically and biomechanically. Mihata et al.¹³ and others have demonstrated the

clinical importance of the superior capsule with the success of superior capsule reconstruction in irreparable rotator cuff tears.^{12,13} Biomechanically the important role of the superior capsule in shoulder kinematics has been confirmed in multiple studies.^{14,21} In normal shoulders and repairable rotator cuff tears, the superior capsule is now understood to compliment the function of the rotator cuff.^{1,2}

The rotator cable has been well described by multiple authors.⁶⁻¹⁰ Burkhart et al.⁶ originally described it as the “suspension bridge” of the shoulder for its resemblance to the main cable of a suspension bridge and coined the terminology “rotator cable.” It is also known as the “transverse band” and the “ligamentum semi-circulare humeri.”^{7-10,26} The cable acts as a sling, reinforcing the insertion of the rotator cuff tendons. Functionally, the cuff transfers force and stress to the cable.⁸ It creates a horizontal force couple between the anterior and posterior cuff.⁶ The cable also maintains tension in the superior capsule, which provides anterior superior stability to the shoulder.²

An intact rotator cable was noted to be critical in preserving kinematic function in massive rotator cuff tears. The maintenance of the anterior and posterior cable attachments was the determining factor for preserving the force couple of the Cable and cuff function.³⁰

The anterior cable attachment has been clinically documented to preserve rotator cuff function and shoulder kinematics.⁵ An intact anterior cable appears to prevent tear enlargement in anterior superior rotator cuff tears.³

Mesiha et al.⁴ described the anterior cable attachment as the 8 to 12 mm of the supraspinatus tendon insertion immediately posterior to the bicipital pulley and bicipital groove. They confirmed in their biomechanical study that it was the primary load-bearing structure for supraspinatus force transmission and provided stress-shielding to the cuff posterior to the anterior cable. Abnormal glenohumeral kinematics have been documented after partial articular-sided tears involving the anterior cable attachment.⁵ The clinical relevance of repairing tears of the anterior cable attachment has been reported in another recent cadaver study.³¹

So, although the clinical benefits of specifically repairing the ACT at ARCR have not been studied, there is significant evidence that there are clinical and biomechanical advantages for shoulder function with an intact anterior cable and a functioning superior capsule.^{5,12-14,21,30,31}

One immediate practical application of identifying the ACT is in expanding the recognition of the injury pattern to include both the tendon and capsular layers. Rahu et al.¹¹ demonstrated that the rotator cable is universally present and tightly connected to the supraspinatus tendon deep surface, indicating that it

can be used as a “landmark” for anatomic restoration of both the cable and the supraspinatus tendon.¹¹ The crucial zone (C1) of this study gives the specific location for the repair of the ACT and anatomic restoration of the anterior footprint. There are potential biomechanical and clinical advantages of specifically repairing the superior capsule at the ACT and fully restoring the anterior footprint (Table 3).²⁶

This simple clinical anatomic study demonstrates that the ACT can be readily identified at time of surgery. This is an important first step and a prerequisite for expanding rotator cuff repair to include repair of the anterior cable tear and achieving a more anatomic footprint restoration.

This study has numerous strengths. First, the data were collected prospectively at the time of surgery by a single senior surgeon. Second, it demonstrates that the rotator cable is a structure that is universally present at ARCR and can be consistently identified. Third, it demonstrates that the ACT can be identified and occurs in recognizable patterns.

Limitations

This study has several weaknesses. First, the data were collected and reviewed by a single surgeon and by default are subject to confirmation bias. Second, it uses small sample sizes. Third, medial displacement of the anterior cable, injury to the capsular and tendon zones on the greater tuberosity, were approximations and were not made with a calibrated probe. Finally, it is an observational study without interobserver or intraobserver confirmation of findings.

Conclusions

ACTs are universally identified in ARCR. Three patterns of medial displacement severity were correlated with injury to a crucial insertion zone (C1) at the anterior footprint. The degree of anterior cable disruption at the anterior footprint and displacement was commonly disproportionately greater than the injury to the supraspinatus.

Acknowledgments

Statistics by Jeanie McGee, D.H.Ed., M.S.H.S., C.H.E.S., C.C.R.C., and illustrations by Denise Thompson.

References

1. Nimura K, Kato A, Yamaguchi K, et al. The superior capsule of the shoulder joint complements the insertion of the rotator cuff. *J Shoulder Elbow Surg* 2012;21:867-872.
2. Adams CR, DeMartino AM, Rego G, Denard PJ, Burkart SS. The rotator cuff and the superior capsule: Why we need both. *Arthroscopy* 2016;32:2628-2637.

3. Keener JD, Patterson BM, Orvets N, Chamberlain AM. Degenerative rotator cuff tears: Refining surgical indications based on natural history data. *J Am Acad Orthop Surg* 2019;27:156-165.
4. Mesiha MM, Derwin KA, Sibole SC, Erdemir A, McCarron JA. The biomechanical relevance of anterior rotator cuff cable tears in a cadaveric shoulder model. *J Bone Joint Surg Am* 2013;95:1817-1824.
5. Pinkowsky G, El Attrache N, Peterson A, Akeda M, McGarry M, Lee T. Partial-thickness tears involving the rotator cable lead to abnormal glenohumeral kinematics. *J Shoulder Elbow Surg* 2017;26:1152-1158.
6. Burkhart SS, Esch JC, Jolson SR. The rotator crescent and rotator cable: An anatomic description of the shoulder's "suspension bridge. *Arthroscopy* 1993;9:611-616.
7. Clark JM, Harryman DT. Tendons, ligaments, and capsule of the rotator cuff: Gross and microscopic anatomy. *J Bone Joint Surg Am* 1992;74:713-725.
8. DiGiacomo G, Pouliart N, Costantini A, DeVita A. Glenohumeral capsule, *Di Giacomo G. Atlas of functional shoulder anatomy*. Milan: Springer, 2008;110-194.
9. Gohlke F, Bernhard E, Schmitz. The pattern of collagen fiber bundles of the capsules of the glenohumeral joint. *J Shoulder Elbow Surg* 1994;3:111-128.
10. Kolts I, Busch LC, Tomusk H, et al. Macroscopical anatomy of the so-called "rotator interval": A cadaver study on 19 shoulder joints. *Ann Anat* 2001;184:9-14.
11. Rahu M, Kolts I, Poldoja E, Kask K. Rotator cuff tendon connections with the rotator cable. *Knee Surg Sports Traumatol Arthrosc* 2017;25:2047-2050.
12. Mihara S, Fujita T, Ono T, Inoue H, Kisimoto T. Rotator cuff repair using an original iliotibial ligament with a bone block patch: Preliminary results with a 24-month follow-up period. *J Shoulder Elbow Surg* 2016;25:1155-1162.
13. Mihata T, Lee TQ, Watanabe C, et al. Clinical results of arthroscopic superior capsule reconstruction for irreparable rotator cuff tear. *Arthroscopy* 2013;29:459-470.
14. Mihata T, McGarry MH, Pirolo JM, Kinoshita M, Lee LQ. Superior capsule reconstruction to restore superior stability in irreparable rotator cuff tears: A biomechanical cadaveric study. *Am J Sports Med* 2012;2240-2248.
15. Mochizuki T, Sugaya H, Mari Uomizu M, et al. Humeral insertion of the supraspinatus and infraspinatus: New anatomical findings regarding the footprint of the rotator cuff. *J Bone Joint Surg Am* 2008;90:962-969.
16. Jost B, Koch PP, Gerber C. Anatomy and functional aspects of the rotator interval. *J Shoulder Elbow Surg* 2000;9:336-341.
17. Moezzi D. Editorial Commentary: Restoration of rotator cuff footprint anatomy is all that matters, no matter how we get there. *Arthroscopy* 2018;34:3157-3158.
18. Kim YK, Jung KH, Kwon HM. Comparison of structural integrity and functional outcome between delaminated and nondelaminated rotator cuff tears after arthroscopic repair. *Arthroscopy* 2019;35(12):e36.
19. Kim YK, Jung KH, Park CK, Yun SB. Morphologic factors related to repair outcomes for delaminated rotator cuff tears: A minimum 2 year retrospective comparison study. *Arthroscopy* 2019;35:332-340.
20. Nakamizo H, Horie R. Comparison of en masse versus dual-layer suture bridge procedures for delaminated rotator cuff tears. *Arthroscopy* 2018;34:3150-3156.
21. Ishihara Y, Mihata T, Tambolia M, et al. Role of the superior shoulder capsule in passive stability of glenohumeral joint. *J Shoulder Elbow Surg* 2014;23:642-648.
22. Kim HM, Dahiya N, Teehey SA, Keener JD, Galatz LM, Yamaguchi K. Relationship of tear size and location to fatty degeneration of the rotator cuff. *J Bone Joint Surg Am* 2010;92:829-839.
23. Davis DE, Lee B, Leem A, Abboud J, Ramsey M. Interobserver reliability of the rotator cable and its relationship to rotator cuff congruity. *J Shoulder Elbow Surg* 2020;29:1811-1814.
24. Habermeyer P, Krieter C, Tang KL, Lichtenberg S, Magosch P. A new arthroscopic classification of articular-sided supraspinatus footprint lesions: A prospective comparison with Snyder's and Ellman's Classification. *J Shoulder Elbow Surg* 2008;17:909-913.
25. Wieser K, Rahm S, Farshad M, Ek ET, Gerber C, Meyer D. Stitch positioning influences the suture hold in supraspinatus tendon repair. *Knee Surg Sports Traumatol Arthrosc* 2013;21:1587-1592.
26. Pouliart N, Somers K, Eid S, Gagey O. Variations in the superior capsuloligamentous complex and description of a new ligament. *J Shoulder Elbow Surg* 2007;16:821-836.
27. Martetschlager F, Zampeli F, Tauber, Habermeyer P. Lesions of the biceps pulley: A prospective study and classification update. *JSES Int* 2020;4:318-323.
28. Habermeyer P, Magosch P, Pritsch M, Scheibel M, Lichtenberg S. Anterosuperior impingement of the shoulder as a result of medial sheath lesions: A prospective arthroscopic study. *J Shoulder Elbow Surg* 2004;13:5e12.
29. Arai R, Nimura A, Yamaguchi K, et al. The anatomy of the coracohumeral ligament and its relation to the subscapularis muscle. *J Shoulder Elbow Surg* 2014;23:1575-1581.
30. Nguyen ML, Quigley RJ, Galle SE, et al. Margin convergence anchorage to bone for reconstruction of the anterior attachment of the rotator cable. *Arthroscopy* 2012;28:1237-124.
31. Burkhart SS. Fluoroscopic comparison of kinematic patterns in massive rotator cuff tears. A suspension bridge model. *Clin Orthop Relat Res* 1992;284:144-152.
32. Park SG, Shim BJ, Seok HG. How much will high tension adversely affect rotator cuff repair integrity? *Arthroscopy* 2019;35:2992-3000.
33. Schlegel TF, Abrams JS, Bushnell BD, Brock JL, Ho CP. Radiologic and clinical evaluation of a bioabsorbable collagen implant to treat partial-thickness tears: A prospective multicenter study. *J Shoulder Elbow Surg* 2018;27:242-251.
34. Derwin KA, Galatz LM, Ratcliffe A, Thomopoulos S. Enthesis repair: Challenges and opportunities for effective tendon-to-bone healing. *J Bone Joint Surg Am* 2018;100:e109:1-7.