

A rare case of plasmacytoid urothelial carcinoma of bladder: Diagnostic dilemmas and clinical implications

Khaliqur Rahman, Santosh Menon, Asawari Patil, Ganesh Bakshi¹, Sangeeta Desai

Departments of Pathology and ¹Urologic Surgery, Tata Memorial Centre, Mumbai, India

ABSTRACT

Plasmacytoid urothelial carcinoma is an uncommon and aggressive variant of urothelial carcinoma associated with late presentation and poor prognosis. We discuss here the first reported case from India of a 54-year-old male who presented with hematuria. Cystoscopy showed edematous and ulcerated mucosa throughout the bladder. A transurethral biopsy revealed urothelial carcinoma with plasmacytoid appearance. He underwent a radial cystectomy which on histopathology showed plasmacytoid urothelial carcinoma of the bladder of high stage with involvement up to bladder serosa and adventitial walls of the ureter. The diagnostic dilemmas of this unusual variant of urothelial malignancy and its clinical impact are discussed.

Key words: Pathology, plasmacytoid, urothelial carcinoma

INTRODUCTION

Plasmacytoid urothelial carcinoma is a rare malignant neoplasm in the urinary bladder recognized by recent WHO classification of urothelial carcinoma.^[1] It is an aggressive variant associated with poor prognosis that presents at an advanced clinical stage. Limited data is available about the pathological, immunohistochemical characteristic as well as clinical behavior of this rare variant. Morphological distinction from other malignant neoplasms with plasmacytoid phenotype is critical for its clinical management. Treatment remains a challenge because of late presentation of the disease and presence of metastasis at the time of initial work up.^[2-7] We present here a case of 54-year-old male patient who was referred to our hospital for diagnostic work-up of bladder cancer.

For correspondence: Dr Santosh Menon, Department of Pathology, 8th Floor, Annexe Building, Tata Memorial Hospital, Dr Ernest Borges Marg, Parel, Mumbai – 400 012, India.
E-mail: santosh.menon@rediffmail.com

Access this article online

Quick Response Code:



Website:

www.indianjurol.com

DOI:

10.4103/0970-1591.78409

CASE REPORT

A 54-year-old male presented with hematuria and lower abdominal pain. He had a history of smoking 10 cigarettes per day for last 22 years. Cystoscopy revealed edema and ulceration of the entire bladder mucosa. CT scan of abdomen and pelvis showed thickened urinary bladder wall with irregularity of the mucosa involving entire bladder. Other pelvic and abdominal organs were unremarkable. Transurethral bladder biopsy revealed a malignant urothelial tumor with plasmacytoid appearance. Radical cystectomy was done which on gross examination showed a grey white firm to hard, ill-circumscribed ulcerative tumor involving almost the entire bladder measuring 2 cms in thickness. The tumor was seen infiltrating the perivesicular fat up to the circumferential margin. Microscopic examination showed a high-grade tumor composed of discohesive plasmacytoid cells replacing the lamina propria [Figures 1 and 2]. The tumor cells were seen extending from the mucosal aspect and invaded through the detrusor muscle to invade the perivesical fat and the serosa [Figure 3]. Perineural invasion was noted. The tumor cells were seen extending along the adventitia of both the ureters even up to the surgical cut margins. Tumor cells were seen undermining the prostatic urothelial lining. Distal urethral cut margin was also involved by the tumor. Bilateral iliac lymph nodes were free of tumor. On immunohistochemistry the tumor cells were positive for CK, CK 7 [Figure 4] and CD 138; while they were negative for LCA, CD20, κ and λ light chains.

The patient is on regular follow-up and is doing fine for last

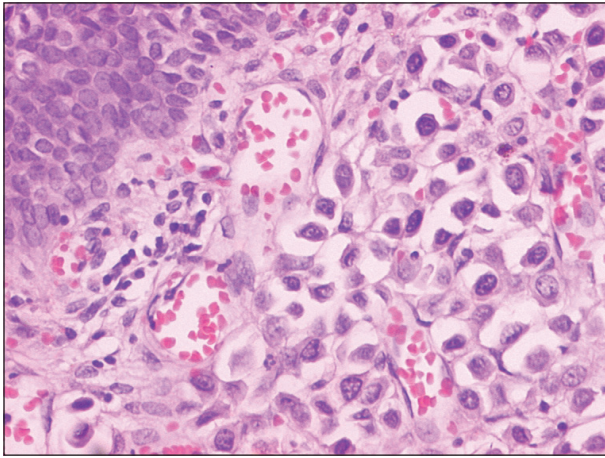


Figure 1: Plasmacytoid urothelial carcinoma: The tumor cells are seen undermining the normal urothelium with retraction spaces around them. (H and E, Original Magnification ×100).

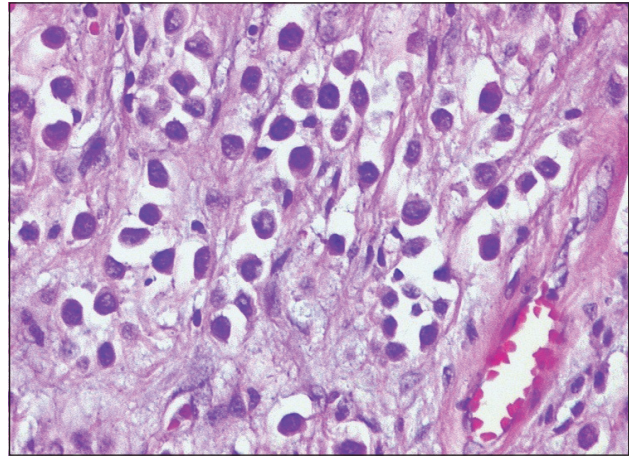


Figure 2: The malignant cells have eccentric nuclei with eosinophilic cytoplasm giving them a plasmacytoid appearance. The stroma shows a myxoid character. (H and E, Original magnification ×200).

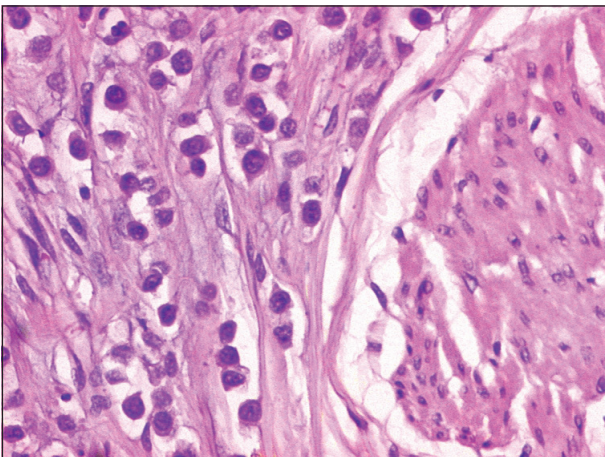


Figure 3: Plasmacytoid urothelial carcinoma cells invading the detrusor muscle bundles. (H and E, Original magnification ×200).

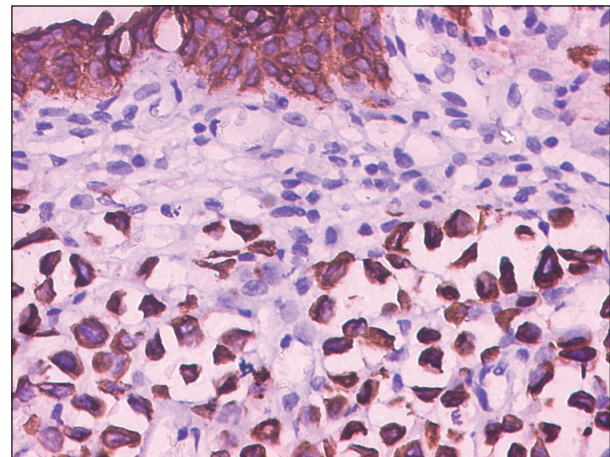


Figure 4: Immunohistochemical staining with antibody to CK7 marks the tumor cells as well the overlying urothelium thereby confirming their epithelial origin. (Immunoperoxidase method, Original magnification ×200).

6 months without any evidence of recurrence or metastasis elsewhere in the body.

DISCUSSION

Recent years have witnessed the illustrations and documentation of several morphological variants of urothelial carcinomas, which have significance from therapeutic and prognostic perspective. The plasmacytoid variant is an unusual variant that has been recognized in the latest WHO classification of urothelial carcinomas.^[1] Earliest description of this variant came from the case reported by Sahin *et al.*^[2] in 1991 and since then, not more than 40 cases have been reported.^[2-6] There is very limited data available about the pathological, immunohistochemical characteristic as well as clinical behavior of this rare variant. Patients usually present late and in advanced stage of cancer with very poor outcome. Most common presenting symptom is hematuria.^[4-8]

Histopathologically, plasmacytoid urothelial carcinoma is

characterized by plasmacytoid tumor cells arranged in cords and single-file pattern, small nests, solid sheet like growth or diffuse discohesive pattern-less architecture.^[4] Cytoplasm is moderate to abundant and amphophilic to eosinophilic, with eccentrically placed nuclei. The nuclei vary from hyperchromatic to vesicular with evenly distributed chromatin and variability in the prominence of nucleoli. There is overall monotony of the nuclear feature.^[4,6] Stromal reaction in the form of prominent myxoid stroma is noted. Prominent retraction artifact around each tumor cell may also be seen. In the present case almost all these findings were prominent.

The plasmacytoid urothelial carcinoma can coexist with non-invasive papillary urothelial carcinoma, urothelial carcinoma in situ or invasive high-grade urothelial carcinoma.^[7,8] However, in our case there were no areas of either papillary or in situ urothelial malignancy.

Plasmacytoid appearance of this tumor can lead to diagnostic

dilemma, especially in smaller biopsies. Differential diagnosis ranges from benign conditions like chronic cystitis with prominent plasma cell infiltrate to malignant tumors like plasmacytoma and signet ring carcinoma. In our case a plasma cell tumor/myeloma was a major differential diagnosis. However, unlike in a plasmacytoma, these urothelial carcinoma cells lacked prominent perinuclear “hoff” or clearing and there was absence of binucleation/multinucleation.^[4] Some cells also had focal signet ring-like appearance which led to confusion with signet ring cell carcinoma. However, the nuclei were eccentric rather than being peripherally compressed as in true signet ring cell carcinoma. Metastatic carcinoma from breast or stomach, malignant melanoma and rhabdomyosarcoma can have striking plasmacytoid morphology and can cause considerable diagnostic difficulties. In such situations, it is imperative to employ a panel of antibodies for confirmation of diagnosis. Immunohistochemical studies have shown that plasmacytoid urothelial carcinoma cells to be positive for CK-7, CK-20, CK, AE1/AE3, EMA and CD-138, but negative for LCA, S 100, HMB 45, κ, λ and CD 79-α,^[4,6,8,9] as was seen in our case also.

Because of late presentation, biopsy usually reveals a high-grade tumor infiltrating the lamina propria and muscularis, with high potential of metastasis.^[5]

Treatment is a challenge owing to late presentations with metastasis. Some reports have shown good response to neoadjuvant chemotherapy,^[10] but this aspect needs further evaluation. Our patient also had high-stage disease (pT3) and underwent radical cystectomy with ileal conduit. On final histopathology, the tumor cells were seen extending along the ureteric adventitia till the surgical resection margins. Hence, he was given adjuvant chemotherapy plus radiation.

Prognosis is extremely poor with an aggressive behavior of this variant. In the case series by Nigwekar *et al*,^[4] no patient with greater than 1-year follow-up survived the disease. Another report by Lopez-Beltran *et al*,^[6] showed that within 2 years of follow-up, all patients either died of cancer or had metastasis. In our case the patient is free of disease since last 6 months after surgery.

In conclusion, plasmacytoid variant of urothelial carcinoma is a rare and important variant form diagnostic, therapeutic and prognostic point of view. It has an aggressive behavior with poor prognosis. It can be mistaken for other pathologies of bladder having plasmacytoid features and should be differentiated from them because of the difference in the therapeutic approach. The role of neoadjuvant chemotherapy is to be further evaluated.

REFERENCES

1. Lopez-Beltran A, Suater G, Gasser T, Hartmann A, Schmitz-Drager BJ, Helpap B, *et al.* Infiltrating urothelial carcinoma. In: Eble JN, Sauter G, Epstein JI, Sesterhenn IA, editors. Pathology and Genetics of tumors of urinary system and male genital organs. Lyon: IARC press; 2004. p.93-109.
2. Sahin AA, Myhre M, Ro JY, Sneige N, Dekmezian RH, Ayala AG. Plasmacytoid transitional cell carcinoma: Report of a case with initial presentation mimicking multiple myeloma. *Acta Cytol* 1991;35:277-80.
3. Zuckerberg LR, Harris NL, Young RH. Carcinomas of urinary bladder simulating malignant lymphoma: A report of five cases. *Am J Surg Pathol* 1991;15:569-76.
4. Nigwekar P, Tamboli P, Amin MB, Osumkoya AO, Ben-Dor D, Amin MB. Plasmacytoid urothelial carcinoma: Detailed analysis of morphology with clinicopathologic correlation in 17 cases. *Am J Surg Pathol* 2009;33:417-24.
5. Aldousari S, Sircar K, Kassouf W. Plasmacytoid urothelial carcinoma of the bladder: A case report. *Cases J* 2009;28:6647.
6. Beltran AL, Requena MJ, Montironi R, Blanca A, Cheng L. Plasmacytoid urothelial carcinoma of the bladder. *Hum Pathol* 2009;40:1023-8.
7. Coyne JD, Sim E. Urothelial neoplasia with plasmacytoid morphology. *Histopathology* 2006;48:200-1.
8. Ro JY, Shen SS, Lee HI, Hong EK, Lee YH, Cho NH, *et al.* Plasmacytoid transitional cell carcinoma of urinary bladder: A clinicopathological study of 9 cases. *Am J Surg Pathol* 2008;32:752-7.
9. Mai KT, Park PC, Yazdi HM, Saltel E, Erdogan S, Stinson WA, *et al.* Plasmacytoid urothelial carcinoma of the urinary bladder report of seven new cases. *Eur Urol* 2006;50:1111-4.
10. Kohno T, Kitamura M, Akai H, Takaha M, Kawahara K, Oka T. Plasmacytoid urothelial carcinoma of the bladder. *Int J Urol* 2006;13:485-6.

How to cite this article: Rahman K, Menon S, Patil A, Bakshi G, Desai S. A rare case of plasmacytoid urothelial carcinoma of bladder: Diagnostic dilemmas and clinical implications. *Indian J Urol* 2011;27:144-6.

Source of Support: Nil, **Conflict of Interest:** None declared.