

## Original Article

### Risk factors for anterior open bite: A case-control study

Suellen de Lima Mendes<sup>1</sup>, Isabella Lima Arrais Ribeiro<sup>2</sup>, Ricardo Dias de Castro<sup>2</sup>, Vitor Marques Filgueiras<sup>2</sup>, Tânia Braga Ramos<sup>1</sup>, Rosa Helena Wanderley Lacerda<sup>1,2</sup>

<sup>1</sup>Brazilian Dental Association, <sup>2</sup>Graduate Program in Dentistry, University Hospital Lauro Wanderley, Universidade Federal da Paraíba, João Pessoa, PB, Brazil

#### ABSTRACT

**Background:** Anterior open bite (AOB) is noteworthy because it is a complex dysplasia, and clinical studies on this malocclusion are usually epidemiological studies or experimental models with small samples and no control group, which renders the data on AOB incomplete and therefore inconclusive. The objective of this study was to assess the risk factors involved in developing AOB.

**Materials and Methods:** A case-control study was provided with a total of 96 lateral cephalometric radiographs of male and female patients aged between 8 and 14 years were used, regardless of facial type. The dependent variable was the presence or absence of AOB, which divided the participants into case and control groups, respectively; these groups were matched for gender and age. The case and control groups data were analyzed by descriptive and inferential analysis by binary logistic regression using at the 5% significance level

**Results:** The occurrence of AOB was associated with the presence of deleterious oral habits ( $P = 0.014$ ; Chi-square test) and was approximately three times (odds ratio = 3.04) more likely to occur in participants with AOB. No significant association between the presence of mouth breathing and the occurrence of AOB was found ( $P = 0.151$ ; Chi-square test). The odds associated with tongue interposition were 10.51 times higher than those of participants with no such deglutition. The odds associated with the dolichofacial pattern were 5.74 times those of participants with a nondolichofacial pattern.

**Conclusion:** Tongue interposition and dolichocephalic facial pattern were risk factors for developing AOB.

**Key Words:** Facial, habits, head, nasopharynx, oropharynx

Received: December, 2018  
Accepted: October, 2019

Address for correspondence:  
Dr. Isabella Lima Arrais  
Ribeiro,  
University of Paraíba, João  
Pessoa, Paraíba, Brazil.  
E-mail: isabella\_arrais@  
yahoo.com

## INTRODUCTION

Anterior open bite (AOB) is characterized by a deficit in the normal vertical contact between the antagonist teeth in the anterior dental arches.<sup>[1]</sup> Furthermore, AOB causes various esthetic and functional changes that impair food gripping and cutting as well as generates problems in articulating specific phonemes. These changes can lead to unfavorable psychosocial conditions.<sup>[2]</sup>

The etiology of AOB is related to heredity and the environment. Environmental etiologic factors are most commonly observed during child development and are usually associated with tonsillar hypertrophy, mouth breathing, and deleterious oral habits including thumb and pacifier sucking. Tongue interposition, considered a secondary oral habit, worsens AOB, even after the removal of the primary etiologic

This is an open access journal, and articles are distributed under the terms of the Creative Commons Attribution-NonCommercial-ShareAlike 4.0 License, which allows others to remix, tweak, and build upon the work non-commercially, as long as appropriate credit is given and the new creations are licensed under the identical terms.

For reprints contact: reprints@medknow.com

**How to cite this article:** Mendes Sd, Ribeiro IL, de Castro RD, Filgueiras VM, Ramos TB, Lacerda RH. Risk factors for anterior open bite: A case-control study. Dent Res J 2020;17:388-94.

#### Access this article online



Website: [www.drj.ir](http://www.drj.ir)  
[www.drjjournal.net](http://www.drjjournal.net)  
[www.ncbi.nlm.nih.gov/pmc/journals/1480](http://www.ncbi.nlm.nih.gov/pmc/journals/1480)

factor.<sup>[3,4]</sup> Vertical growth pattern with or without anterior maxillary inclination is also related to the development of AOB.<sup>[5]</sup>

Correcting AOB at an early age favors growth reestablishment and normal dentofacial development, preventing dentoalveolar changes from resulting in the significant skeletal deformities that compromise functional balance and facial harmony. This malocclusion can have skeletal implications at the end of the craniofacial development period if not treated early, especially in patients with a vertical growth pattern.<sup>[6]</sup>

In this context, AOB is noteworthy because it is a complex dysplasia, and clinical studies on this malocclusion are usually epidemiological studies or experimental models with small samples and no control group, which renders the data on AOB incomplete and therefore inconclusive.<sup>[7-10]</sup> Thus, the present study is relevant because it assessed risk factors associated with developing the malocclusion in question.

## MATERIALS AND METHODS

### Ethical considerations

The present study was approved by the ethics committee under protocol number: 43133415.8.0000.5178, in accordance with resolution 196/96 of the Brazilian Ministry of Health/National Health Committee/National Research Ethics Committee.

### Study design

This is an original research, by a case-control study provided with a total of 96 lateral cephalometric radiographs of male and female patients aged between 8 and 14 years, regardless of facial type.

### Sample

The sample size was calculated for a case-control study using the parameters of one control per case considering 64% exposed participants among the cases and 37.21% exposed participants among controls, a 5% significance level, and 85% test power; totaling a need of evaluation of a minimum of 96 patients, equally divided into two groups, with 48 patients each, according to the occurrence of AOB: the case group (presence of AOB) and the control group (absence of AOB). The cases and controls were paired by sex and age.

### Data collect

The case group consisted of 48 cast models and 48 lateral cephalometric radiographs obtained on the

same day from the same male and female patients of any facial type, aged between 8 and 14 years with fully erupted upper and lower incisors, without associated deformities.

All the 48 case group participants had AOB. A digital calibrator (Digimes) was used to assess the severity of the malocclusion in the individually articulated study models. The distance was measured between the midpoint (mesial-distal direction) of the incisal edge of the most anterior maxillary central incisor and the midpoint of the incisal edge of the lower central incisor on the same side. The measurements were recorded on a Microsoft Excel spreadsheet, and the severity of AOB was subsequently rated according to the following classification:<sup>[7]</sup> 0–2 mm (moderate open bite); –4–3 mm (severe open bite); and >4 mm (extreme open bite).

Dental casts without AOB and the correspondents cephalometric radiographs were selected for the control group, being the controls selected from the gender and age paired with the case group, regardless of facial type.

All the documents used for the case and control groups were obtained by the archives of the Specialization Course in Orthodontics held at the Brazilian Association of Dentistry, Paraíba Section. The participants had never received orthodontic treatment and were assisted between the years of 2004 and 2014.

A single examiner evaluated the radiographic images, and an orthodontist experienced in cephalometry compared these images with anatomical drawings of all selected images created on Canson paper in a dark environment using a 0.3-mm graphite pencil. Tracings were made, and the landmarks were measured with a ruler and protractor.

The following points were marked on the anatomical drawings: sella (S), nasion (N), basion (Ba), pterygoid (Pt), gnathion (Gn), porion (Po), orbitale (Or), gonion (Go), menton (Me), mandibular centroid (Xi), anterior nasal spine (ANS), pogonion (Pg), suprapogonion (PM), and condyle (DC). After marking the points, the following Ricketts' landmarks needed to determine the VERT index were measured: facial axis (Ba-N. Pt-Gn); facial depth (Po-Or. N-Pg); mandibular plane angle (Go-Me. Po-Or); lower facial height (LFH; Xi-ANS. Xi-PM); and mandibular arch (DC-Xi. Xi-PM).

According to the guidelines for VERT index determination,<sup>[11]</sup> after calculating the angle values of each participant, the individualized norm for each angle was calculated after considering the age. After establishing the difference from the value found according to the clinical deviation (which varies with the angle), a positive value was assigned to indicate a brachyfacial growth trend, and a negative value was assigned to indicate a dolichofacial trend [Table 1]. The facial pattern was determined according to the value found, of the same way: values between  $-2$  and  $-0.5$  mm characterized the facial pattern dolichofacial; values between  $-0.49$  and  $+0.49$  characterized the facial pattern mesofacial; and values higher than  $+0.5$  characterized the facial pattern brachyfacial.

The sizes of the nasopharyngeal and oropharyngeal spaces, which were manually traced, were measured using the distance between the nasal and oropharyngeal posterior edges and the soft palate, respectively. Those measurements were performed according to McNamara.<sup>[12]</sup>

The other data used for analysis (the presence of deleterious oral habits such as finger sucking, pacifier sucking, nail biting, lip sucking, and bottle feeding as well as the presence or absence of mouth breathing) were collected from the medical records of the patients who completed an initial evaluation before the orthodontic treatment. The data concerning tongue interposition were collected from speech therapy records, which were also included in the patient records.

### Data analysis

The dependent variable for data analysis was the presence or absence of AOB, which divided

the participants into case and control groups, respectively.

To tests, the dolichocephalic facial growth pattern was grouped into two categories in both cases: dolichocephalic and nondolichocephalic (i.e., mesofacial and brachyfacial).

The dependent variable was the presence of AOB, and the outcome was defined as 1 (with AOB) and 0 (without AOB). This classification was required to logistic binary regression analysis.

The data independent variables (finger or pacifier sucking, tongue interposition, mouth breathing, oropharynx size, nasopharynx size, and the facial growth trend of the case and control groups) were entered into a Microsoft Excel spreadsheet and subjected to a descriptive analysis (absolute and percentage frequency) and an inferential statistical analysis using binary logistic regression.

First, a univariate analysis was performed adopting a 0.20 significance level for input variable selection for the multiple regression model of binary logistic regression. Next, variables with significance values lower than 0.20 were entered into the multivariate model, and variable inclusion was performed using the backward-selection method, adopting a significance level of 0.05. After fitting the multiple regression model, diagnostic tests were performed, and the receiver operating characteristic (ROC) curve was plotted. Analyses were performed using the Statistical Package for the Social Sciences (IBM SPSS; version 21.0; IBM Corporation, Armonk, New York, United States) and R (version 3.1.3; The R Foundation, St. Louis, Missouri, United States).

## RESULTS

Were evaluated in each group, 27 (56.3) girl's cases and 21 (43.7%) boy's cases. The mean ages of both groups were identical and equal to  $10.98 \pm 2.33$  years. More than half (52.1%) of case group participants had moderate AOB, followed by extreme (29.2%) and severe (18.7%) AOB.

The presence of deleterious oral habits occurred in 31 (64.6%) case group patients but only 18 (37.5%) control group participants. Table 2 details the major deleterious oral habits found in both groups.

AOB was associated with the presence of deleterious oral habits ( $P = 0.014$ ; Chi-square test), with

**Table 1: The values to determine the landmarks needed to calculate the VERT index with variations according to age**

Landmarks	FA	FD	MPA	LFH	MA
Variation/age	No	+1°/3 years	-1°/3 years	No	+0.5°/year
9 years	90°	87°	26°	47°	26°
10 years	90°	87.33°	25.67°	47°	26.5°
11 years	90°	87.66°	25.34°	47°	27°
12 years	90°	88°	25°	47°	27.5°
13 years	90°	88.33°	24.67°	47°	28°
14 years	90°	88.66°	24.34°	47°	28.5°
14 years	90°	89°	24°	47°	29°
16 years (male)	90°	89.33°	23.67°	47°	29.5°
17 years (male)	90°	89.66°	23.34°	47°	30°

FA: Facial axis; FD: Facial depth; MPA: Mandibular plane angle; LFH: Lower facial height; MA: Mandibular arch

an approximately three times higher chance of occurring (odds ratio [OR] = 3.04) in participants with AOB.

Thirty (62.5%) case group patients breathed through their mouths, whereas only 45.8% of the control group did so. However, no significant association was found between the presence of mouth breathing and the occurrence of AOB ( $P = 0.151$ ; Chi-square test).

A risk factor assessment using a univariate analysis [Table 3] of the variables of interest input into the multiple regression model revealed that both tongue interposition and vertical growth pattern (dolichofacial) were risk factors for the occurrence of AOB. The chance of AOB associated with tongue interposition was 10.51 times greater than that of participants without such deglutition. Moreover, the chance of AOB associated with the dolichofacial facial pattern

was 5.749 times greater than that of participants with a nondolichofacial pattern.

The multiple regression model outlined in Table 4 was fit to the data according to the analysis of deviance (deviance = 90.492) compared with the Chi-square test ( $\chi^2 = 116.511$ ). Thus, the proposed model was well fit to the study data. Furthermore, the ROC curve was plotted with the sensitivity and specificity values as well as the associated predictive values and area under the curve [Figure 1].

Figure 1 shows that the model proposed in the present study identified 68.8% of AOB cases when they occurred (sensitivity) and discarded 89.6% of AOB cases when they did not occur (specificity). The area under the curve was 0.847, which is considered as acceptable. Based on the prevalence of AOB in the study sample, the model was able to predict 25.9% of the occurrence and 13.2% of the nonoccurrence of AOB.

**Table 2: The frequencies of the major deleterious oral habits found in both study groups**

Oral habits	Case group, n (%)	Control group, n (%)
Finger sucking	13 (41.9)	1 (5.6)
Pacifier sucking	10 (32.3)	8 (44.4)
Nail biting	6 (19.4)	7 (38.9)
Lip sucking	1 (3.2)	2 (11.1)
Bottle feeding	1 (3.2)	0 (0.0)
Total	31 (100.0)	18 (100.0)

João Pessoa, 2017

**Table 3: Univariate analysis to selecting the variables to the multiple regression model**

Variable	Score	Df	Significance
Age	0.000	1	1.000
Gender	0.042	1	0.837
Other habits	7.045	1	0.008*
Mouth breathing	2.685	1	0.101*
Tongue interposition	28.971	1	0.000*
Nasopharynx size	0.040	1	0.842
Oropharynx size	0.155	1	0.694
Growth pattern: Dolichocephalic	20.308	1	0.000*
Finger sucking	0.000	1	1.000
Pacifier sucking	0.334	1	0.563

João Pessoa, 2017. \*Variables input into the multiple regression model for the adjusting of final model. Df: Degrees of freedom

## DISCUSSION

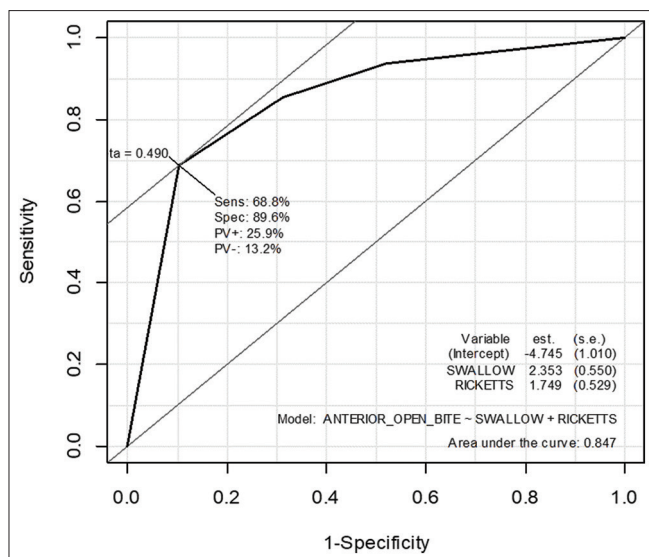
Although AOB is not the most prevalent malocclusion in the Brazilian population, its prevalence among the children studied was only 12.1% according to the Oral Health Brazil 2010 project (SB Brazil 2010); the study of AOB is highly relevant because many cases of orthodontic treatment relapse are associated with the presence of open bite. This finding emphasizes the importance of studying the associations among the presence of AOB, the influence of development, and the severity associated with environmental factors and growth trends.<sup>[13,14]</sup>

Cozza *et al.*<sup>[15]</sup> observed a prevalence of AOB in mixed dentition ranging from 17% to 36.3%, corroborating data indicating that the prevalence of AOB in mixed dentition is 18% and decreases with age.<sup>[16]</sup> The prevalence in the black population is five times higher than that in the white or Hispanic populations.<sup>[17]</sup> Ize-Iyamu and Isiekwe<sup>[17]</sup> found similar data to SB Brasil in a study conducted in Nigeria

**Table 4: Adjusted multiple regression model for the occurrence of anterior open bite**

Variable	B	SE	Significance	OR	95% CI for OR	
					Lower	Upper
Constant	4.745	1.010	0.000	0.009		
Tongue interposition	2.353	0.550	0.000	10.517	3.580	30.894
Vertical growth pattern	1.749	0.529	0.001	5.749	2.039	16.208

João Pessoa, 2017. B: Estimator; CI: 95% Confidence interval; SE: Standard error; OR: Odds ratio



**Figure 1:** Receive operating characteristic curve for the adjusted final model to the occurrence of anterior open bite. João Pessoa, 2017. Sens: Sensitivity; Spec: Specificity; PV+: Predictive positive power of model; PV-: Predictive negative power of model; RICKETTS: Ricketts scale.

because the prevalence of open bite was only 2.8%, which corroborates previously reported data.<sup>[17]</sup>

The presence of nonnutritive sucking habits leads to the development of malocclusion, and the most prevalent malocclusion was AOB.<sup>[14,17,18-28]</sup> However, these habits (finger and pacifier sucking) were not risk factors for developing AOB in the present study after binary regression. This result is most likely related to the age group studied because these habits have usually already been stopped, and spontaneous correction might have occurred in most cases.

When examining the involvement of deleterious oral habits in the development of AOB, tongue interposition (characterized by the adapted deglutition that is common in cases of AOB) was the strongest risk factor for developing this malocclusion because AOB was 10.5 times more likely to occur when tongue interposition was present. Previous studies<sup>[7,28,29]</sup> have suggested that correcting tongue positioning enables the autocorrection of AOB to ensure satisfactory posttreatment stability.

The second risk factor for developing AOB found in the present study was the vertical growth pattern; however, this finding was weaker than tongue interposition (OR = -5.74), corroborating previous findings.<sup>[30,31]</sup> However, some studies failed to find this association,<sup>[23,24]</sup> including Justos<sup>[31]</sup> and Dung and Smith<sup>[32]</sup> who observed that most of the hyperdivergent

participants in their sample had normal or exaggerated overbite, whereas patients with normal facial patterns showed persistent AOB. This finding might strengthen the hypothesis that the vertical growth patterns are not the most important risk factor for developing AOB.

The literature clearly shows that patients with a vertical growth pattern have the following cephalometric changes typical of this facial type: increased gonial (mandibular) angles, increased lower anterior facial height, and a change in the ratio of posterior facial height. In addition to the aforementioned characteristics, patients with AOB show other cephalometric indicators of a predisposing condition for this malocclusion, including excessive vertical maxillary growth, short mandibular rami, and obtuse gonial angles. Such changes tend to cause downward and backward (clockwise) mandibular rotation, thereby increasing the anterior LFH, thereby leading to AOB.<sup>[33,34]</sup>

Thus, examining the association between facial growth pattern and AOB becomes important because the present study showed that morphogenetic factors are directly related to the type of malocclusion under discussion.

No significant association was found when analyzing the relationships between the nasopharynx and oropharynx sizes with regard to the dolichocephalic pattern. This finding goes against previous studies<sup>[35-39]</sup> stating that the dolichofacial pattern is characterized by narrower nasopharyngeal structures than the other facial types as reported by Laranjo and Pinho<sup>[39]</sup> whose study patients with AOB had smaller nasopharynx and oropharynx as well as an increased alveolar and facial height.<sup>[40]</sup> These characteristics typify vertical posterior and rotational mandibular growth.

The lack of a correlation between the nasal and oropharyngeal dimensions and dolichocephalic growth patterns were also observed in other studies,<sup>[41-42]</sup> thereby corroborating the present findings.

Because this study used a case-control design with a well-defined and adequate sample size, the results provide information that furthers the knowledge of AOB. Although some authors affirm that case-control studies do not allow a specific guarantee of cause and effect, this information will be highly relevant in diagnosis so that orthodontic planning and treatment are more accurately performed, and satisfactory posttreatment stability is ensured. We recommend for future studies that the habits and the facial patterns

were always considered in evaluations about risk factors for AOB.

## CONCLUSION

Tongue interposition and a dolichocephalic facial pattern were risk factors for the development of AOB.

### Financial support and sponsorship

This study was funded by the author himself.

### Conflicts of interest

The authors of this manuscript declare that they have no conflicts of interest, real or perceived, financial or nonfinancial in this article.

## REFERENCES

- Ramos-Jorge J, Motta T, Marques LS, Paiva SM, Ramos-Jorge ML. Association between anterior open bite and impact on quality of life of preschool children. *Braz Oral Res* 2015;29:46.
- Machado DB, Brizon VS, Ambrosano GM, Madureira DF, Gomes VE, de Oliveira AC. Factors associated with the prevalence of anterior open bite among preschool children: A population-based study in Brazil. *Dental Press J Orthod* 2014;19:103-9.
- Garrett J, Araujo E, Baker C. Open-bite treatment with vertical control and tongue reeducation. *Am J Orthod Dentofacial Orthop* 2016;149:269-76.
- Meyer-Marcotty P, Kochel J, Stellzig-Eisenhauer A. The impact of spur therapy in dentoalveolar open bite. *Aust Orthod J* 2013;29:145-52.
- Celli C, Santos-Pinto PR, Capelozza Filho L, Souza YS, Santos-Pinto G. Correction of the anterior open bite with the use of the removable suspended shell expander. *Clín Ortod Dent Press* 2013;12:38-50.
- Artese A, Drummond S, Nascimento JM, Artese F. Diagnostic Criterion and stable treatment of anterior open bite. *Dent Press J Orthod* 2011;16:136-61.
- Pisani L, Bonaccorso L, Fastuca R, Spina R, Lombardo L, Caprioglio A. Systematic review for orthodontic and orthopedic treatments for anterior open bite in the mixed dentition. *Prog Orthod* 2016;17:28.
- Van Dyck C, Dekeyser A, Vantricht E, Manders E, Goeleven A, Fieuws S, *et al.* The effect of orofacial myofunctional treatment in children with anterior open bite and tongue dysfunction: A pilot study. *Eur J Orthod* 2016;38:227-34.
- Rijpstra C, Lisson JA. Etiology of anterior open bite: A review. *J Orofac Orthop* 2016;77:281-6.
- Ricketts RM. Cephalometrics analysis and synthesis. *Angle Orthod* 1961;31:141-56.
- McNamara JA Jr. A method of cephalometric evaluation. *Am J Orthod* 1984;86:449-69.
- Almeida MR, Pereira AL, Almeida RR, Almeida-Pedrin RR, Silva-Filho OG. Prevalence of malocclusion in children from 7 to 12 years old. *Dental Press J Orthod* 2011;16:123-311.
- Drummond AL, Nery CG, Oliveira JÁ, Flach LD, Ferrante AS, Lenza M. Occurrence of anterior open bite and deleterious oral habits in children from 4 to 12 years old. *Dent Press J Orthod* 2011;10:58-62.
- Cozza P, Baccetti T, Franchi L, Mucedero M, Polimeni A. Sucking habits and facial hyperdivergency as risk factors for anterior open bite in the mixed dentition. *Am J Orthod Dentofacial Orthop* 2005;128:517-9.
- Ng CS, Wong WK, Hagg U. Orthodontic treatment of anterior open bite. *Int J Paediatr Dent* 2008;18:78-83.
- Ismail IN, Leung YY. Anterior open bite correction by le fort I osteotomy with or without anterior segmentation: Which is more stable? *Int J Oral Maxillofac Surg* 2017;46:766-73.
- Ize-Iyamu IN, Isiekwe MC. Prevalence and factors associated with anterior open bite in 2 to 5 year old children in Benin city, Nigeria. *Afr Health Sci* 2012;12:446-51.
- Tibolla C, Rigo L, Nojima LI, Estacia A, Frizzo EG, Lodi L. Association between anterior open bite and pacifier sucking habit in schoolchildren from a southern Brazilian municipality. *Dent Press J Orthod* 2012;17:89-96.
- Magalhaes L, Mn C, Rodrigues MJ, Heimer MV, Alencar AS. Prevalence of nonnutritive sucking habits and their relationship with anterior open bite in children attended at the Pediatric Dentistry Clinic of the University of Pernambuco. *Dent Press J Orthod* 2012;17:119-23.
- Vasconcelos FM, Massoni AC, Heimer MV, Ferreira AM, Katz CR, Rosenblatt A, *et al.* Non-nutritive sucking habits, anterior open bite and associated factors in Brazilian children aged 30-59 months. *Braz Dent J* 2011;22:140-5.
- Romero CC, Scavone-Junior H, Garib DG, Cotrim-Ferreira FA, Ferreira RI. Breastfeeding and non-nutritive sucking patterns related to the prevalence of anterior open bite in primary dentition. *J Appl Oral Sci* 2011;19:161-8.
- Moimaz SA, Rocha NB, Garbin AJ, Saliba O. The influence of breastfeeding practice on the acquisition of non-nutritive sucking habits and prevention of occlusions. *Odontol UNESP J* 2013;42:31-6.
- Heimer MV, Katz CR, Rosenblatt A. Anterior open bite: A case-control study. *Int J Paediatr Dent* 2010;20:59-64.
- Nogueira Fialho MP, Pinzan-Vercelino CR, Nogueira RP, Gurgel JA. Relationship between facial morphology, anterior open bite and non-nutritive sucking habits during the primary dentition stage. *Dental Press J Orthod* 2014;19:108-13.
- Cardoso AC, Bello MG, Vellini-Ferreira F, Ferreira-Santos RI. Sucking habits and anterior open bite among Venezuelan and Brazilian children. *Braz J Oral Sci* 2014;13:219-24.
- Urzal V, Braga AC, Ferreira AP. Diagnostic model of anterior open bite – A new way to predict skeletal type: A cross-sectional study. *Int Orthod* 2014;12:358-70.
- Germa A, Clément C, Weissenbach M, Heude B, Forhan A, Martin-Marchand L, *et al.* Early risk factors for posterior crossbite and anterior open bite in the primary dentition. *Angle Orthod* 2016;86:832-8.
- Botero-Mariaca P, Sierra-Alzate V, Rueda ZV, Gonzalez D. Lingual function in children with anterior open bite: A case-control study. *Int Orthod* 2018;16:733-43.
- Souza E Jr., Freitas KM, Valarelli FP, Cançado RH, Oliveira RC. Prevalence and correlation between facial pattern,

- anterior open bite and posterior crossbite. *Dental Press J Orthod* 2013;12:88-4.
30. Shenoy U, Hazarey P, Akhare PJ, Mute BK. Cephalometric appraisal of tongue and related soft tissues in normal and open bite subjects at rest. *J Clin Diagn Res* 2015;9:ZC16-20.
  31. Justos R. Correction of open bite with spurs: Long-term stability. *World J Orthod* 2001;2:219-31.
  32. Dung DJ, Smith RJ. Cephalometric and clinical diagnoses of open bite tendency. *Am J Orthod Dentofacial Orthop* 1988;94:484-90.
  33. Khan N, Shafi M. Open bite – A review. *Int J Health Sci Res* 2014;4:288-95.
  34. Celikoglu M, Bayram M, Sekerci AE, Buyuk SK, Toy E. Comparison of pharyngeal airway volume among different vertical skeletal patterns: A cone-beam computed tomography study. *Angle Orthod* 2014;84:782-7.
  35. Gungor AY, Turkkahraman H, Yilmaz HH, Yariktas M. Cephalometric comparison of obstructive sleep apnea patients and healthy controls. *Eur J Dent* 2013;7:48-54.
  36. Zhong Z, Tang Z, Gao X, Zeng XL. A comparison study of upper airway among different skeletal craniofacial patterns in nonsnoring Chinese children. *Angle Orthod* 2010;80:267-74.
  37. Ucar FI, Uysal T. Orofacial airway dimensions in subjects with class I malocclusion and different growth patterns. *Angle Orthod* 2011;81:460-8.
  38. Feres MF, Enoki C, Anselmo-Lima WT, Matsumoto MA. Nasopharyngeal and facial dimensions in different morphological patterns. *Dent Press J Orthod* 2010;15:52-61.
  39. Laranjo F, Pinho T. Cephalometric study of the upper airways and dentoalveolar height in open bite patients. *Int Orthod* 2014;12:467-82.
  40. Mani P, Muthukumar K, Krishnan P, Senthil Kumar KP. Upper and lower pharyngeal airway space in West-Tamil Nadu population. *J Pharm Bioallied Sci* 2015;7:S539-42.
  41. Silva NN, Lacerda RH, Silva AW, Ramos TB. Assessment of upper airways measurements in patients with mandibular skeletal class II malocclusion. *Dent Press J Orthod* 2015;20:86-93.
  42. Memon S, Fida M, Shaikh A. Comparison of different craniofacial patterns with pharyngeal widths. *J Coll Physicians Surg Pak* 2012;22:302-6.