



## Case report

## Open removal of pediatric airway foreign body: A case report and literature review

Majid Reza Akbarizadeh<sup>a</sup>, Alireza Malekzadegan<sup>b,\*</sup>, Sima Chupani<sup>c</sup><sup>a</sup> Department of Pediatrics, School of Medicine, Amir al Momenin Hospital, Zabol University of Medical Sciences, Zabol, Iran<sup>b</sup> Department of Surgery, School of Medicine, Amir al Momenin Hospital, Zabol University of Medical Sciences, Zabol, Iran.<sup>c</sup> Department of Pediatrics, Zabol University of Medical Sciences, Zabol, Iran

## ARTICLE INFO

## Keywords:

Children  
Foreign body aspiration  
Bronchoscopy  
Open surgery

## ABSTRACT

**Background:** Foreign Body Aspiration is a common finding in children diagnosed based on clinical signs and radiological studies so that timely diagnosis and successful removal of the foreign body is essential to reduce complications and mortality.

**Case presentation:** In this study, we described a case of a 7-year old boy with a foreign airway body whose bronchoscopy was not successful in removing the foreign body, and the removal required open surgery. We also review the literature on Pediatric airway foreign bodies.

**Discussion:** The patient was discharged in good condition after being monitored and receiving antibiotics in the pediatric ward for seven days.

**Conclusion:** Rigid bronchoscopy involves fewer complications and is more successful in removing the foreign body in children. However, a small percentage of children require open surgery for removal, which can be attributed to the size of the FB, its shape, how long the FB stays in the airways, and the changes that follow are involved and sufficient expertise in rigid bronchoscopy.

## 1. Introduction

Foreign Body Aspiration (FBA) is a common finding in children that should be diagnosed based on clinical signs and radiological studies so that timely diagnosis and successful removal of the Foreign Body (FB) is essential to reduce complications and mortality [1].

Most cases of FBA occur in preschool age, especially in children under three years of age [2]. Factors such as inadequate observation by adults, children, and infants' tendency to explore the environment through the mouth, the inability to chew food, and the immaturity of the protective neuromuscular mechanisms in the airways are vital, influential factors in aspiration in children [2–4].

## 2. Case presentation

The patient is a 7-year-old boy brought to the emergency department following the Palm kernel's aspiration with a 2-day history of shortness of breath, cough, fever, and cyanosis. The patient had no history of any specific disease. The patient was visited by a pediatric specialist with 10 years of experience. At the time of presentation, the patient had unstable

conditions, So he underwent O<sub>2</sub> therapy and was transferred to the Pediatric intensive care unit (PICU) ward. His vital signs include: PR: 130, RR: 50, T:38.5 °C, SpO<sub>2</sub>: 80%.

On physical examination, the patient was in moderate respiratory distress, shortness of breath, and had subcostal retraction. On auscultation, a marked decrease in pulmonary sounds was observed on the right side. The remainder of the examination was generally not significant. Chest radiography revealed severe turbidity of the right lung and the left lung's overinflation (Fig. 1).

According to the above and radiological findings, the patient underwent bronchoscopy. However, due to purulent secretions in the airways, it was not possible to see the FB and remove it.

The next day, the patient's CT scan showed extensive hemothorax on the right side, and he underwent bronchoscopy again. The FB was seen that was located in the right bronchial opening on the Carina, but its removal was not successful. Therefore, the patient underwent open surgery, and the FB was removed. The patient underwent intubation and was transferred to the PICU ward. He was hospitalized there for four days.

Finally, the patient was discharged in good condition after being

\* Correspondence author.

E-mail address: [malekzadegan@gmail.com](mailto:malekzadegan@gmail.com) (A. Malekzadegan).<https://doi.org/10.1016/j.ijscr.2021.106034>

Received 16 April 2021; Received in revised form 16 May 2021; Accepted 21 May 2021

Available online 26 May 2021

2210-2612/© 2021 Published by Elsevier Ltd on behalf of IJS Publishing Group Ltd. This is an open access article under the CC BY-NC-ND license

<http://creativecommons.org/licenses/by-nc-nd/4.0/>.

monitored and receiving antibiotics in the pediatric ward for seven days. We report this case in line with the updated consensus-based surgical case report (SCARE) guidelines [3]. (See Fig. 2.)

### 3. Discussion

In general, infants and children tend to put most objects in their mouths, which poses a risk of FBA due to their protective mechanisms' immaturity [4]. Foreign bodies are often aspirated into the bronchial tubes, lungs, and trachea, and most include peanuts, grains, beans, chicken and fish bones, and plastic objects are available [5]. In general, intrinsic and external factors are involved in the occurrence and development of Tracheobronchial foreign body aspiration (TFBA). For example, age, sex, and Tracheobronchial anatomy are intrinsic factors influencing this field. External factors such as residence, FB species, and prehospital time can be mentioned [6]. Cultural contexts and eating habits in specific geographic areas play a significant role [5].

FBA is one of the most important causes of preventable mortality in children and mimics other common respiratory diseases' signs and symptoms in children [2]. Patients with foreign bodies have a variety of presentations in the airways. The common signs and symptoms of foreign body aspiration include coughing, wheezing, and unilateral reduction in pulmonary sounds and choking [7,8]. However, most of the above symptoms are nonspecific, Yang et al. In their study identified each history of choking as one of the most specific symptoms [9]. In the present study, foreign body aspiration was observed by the patient's family and was easy to diagnose. However, FBA is difficult to diagnose in children because it can present as a complication of asthma or other respiratory infections. The sensitivity and specificity of thorax radiology vary from 68.73% and 45–67%, respectively [10,11]. Therefore, normal radiography does not mean the absence of FB, which leads to delayed diagnosis and treatment. Thus, in cases where the possibility of FBA cannot be ruled out through history, physical examination, and radiology, the need for bronchoscopy is raised because the earlier rigid bronchoscopy is performed, the fewer complications occur [12].

The evidence shows that the range of finding FB in children with FBA is wide (25–25%) [8,7,13]. Rigid bronchoscopy under general anesthesia is a highly accurate surgical technique for identifying, localizing, and removing a foreign body in the airways.

In general, rigid bronchoscopy is the standard gold method for assessing and managing FBA [14,15]. Recent studies, however, have reported the usefulness of using flexible bronchoscopy to remove FB

[16]. Many studies have considered flexible bronchoscopy under intravenous sedation and topical anesthesia to be useful and effective in patients with suspected FBA in the upper tracheobronchial tree [17].

In the present study, the patient underwent emergency rigid bronchoscopy twice, which was unsuccessful in removing FB, so the patient underwent open surgery, and FB was removed. As some studies have reported that endoscopic removal by rigid bronchoscopy is successful in 97% of patients with FBA, and only 3% of pediatric patients undergo thoracic surgery to remove FB [18]. Cataneo et al. In their study of FB in children showed that bronchoscopy was successful in removing FB in 89% of cases, 6% of patients required surgical extraction or resection of the destroyed part of the lung, and In 5% of patients with severe small of FB, it was a spontaneous elimination [19]. However, in failed rigid bronchoscopy cases, available surgical options such as bronchotomy, tracheostomy, and thoracotomy are considered to remove the foreign body [20]. In this context, it seems that the size of FB, its shape, how long FB stays in the airways, and the changes that follow are involved and sufficient expertise in rigid bronchoscopy.

### 4. Conclusion

Removal of the foreign body should be done urgently and as soon as possible. Rigid bronchoscopy involves fewer complications and is more successful in removing the foreign body in children. However, a small percentage of children require open surgery for removal, which can be attributed to the size of the FB, its shape, how long the FB stays in the airways, and the changes that follow are involved and sufficient expertise in rigid bronchoscopy.

### Abbreviations

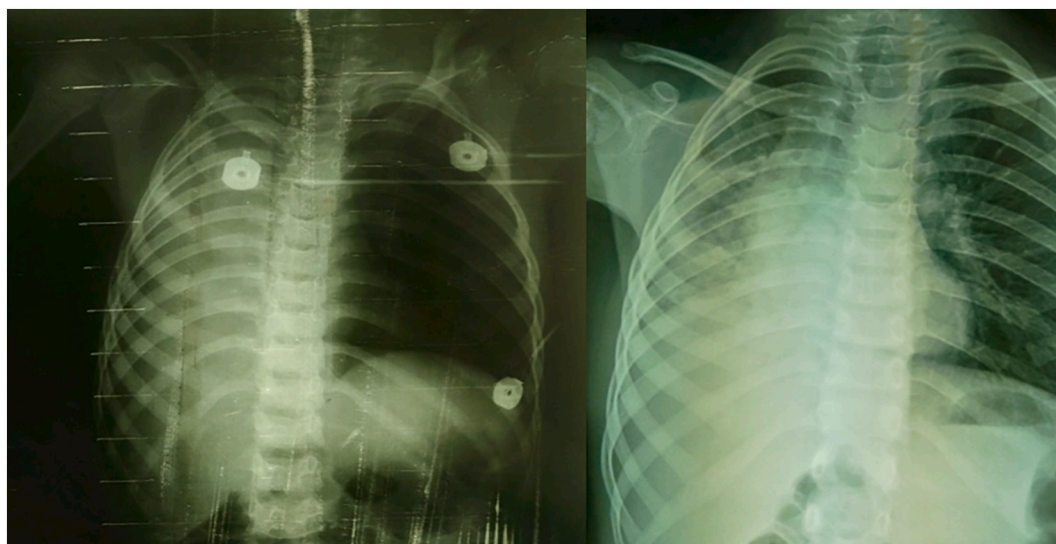
FB	foreign body
FBA	foreign body aspiration
TFBA	tracheobronchial foreign body aspiration

### Sources of funding

None.

### Ethical approval

This case report was exempted from ethical approval from the



**Fig. 1.** Chest X-Ray of the patient. (a) CXR at the time of the patient's arrival at the hospital and (b) after successful bronchoscopy (2 days after the onset of symptoms) showed right lung opacity and left lung overinflation.

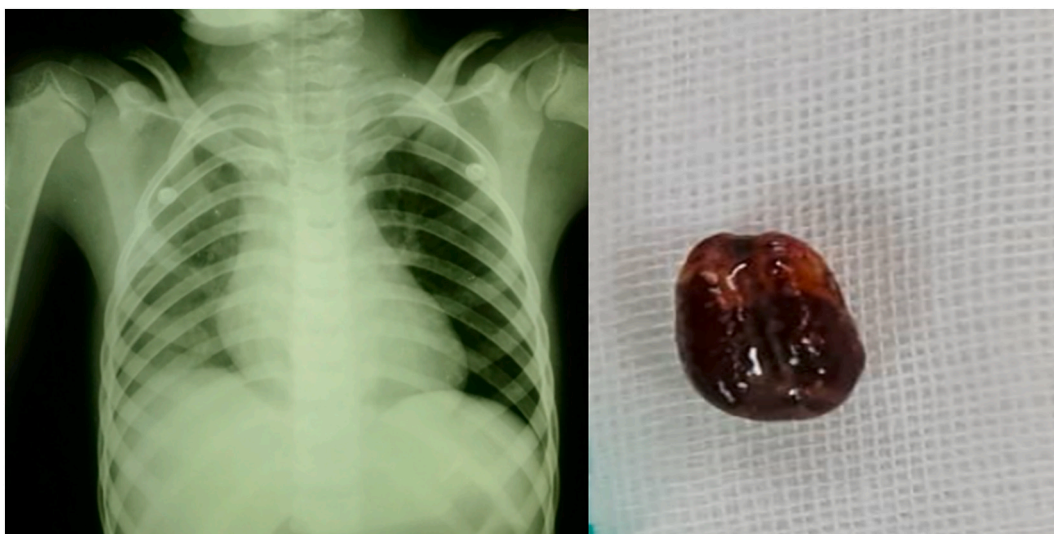

Fig. 2. Chest X-Ray of the patient after removal of the foreign body.

institution.

#### Consent

Written informed consent was obtained from the patient for publication of this case report and accompanying images. A copy of the written consent is available for review by the Editor-in-Chief of this journal on request.

#### Author contribution

Dr. Majid Reza Akbarizadeh and Alireza Malekzadegan have designed the concept of the study, literature review, Data Collection, and analysis. Dr. Sima Chupani has contributed to study concept design, treatment of the patient, and manuscript writing.

#### Research registration

Not applicable.

#### Guarantor

Alireza Malekzadegan.

#### Provenance and peer review

Not commissioned, externally peer-reviewed.

#### Declaration of competing interest

None.

#### References

- [1] W. Qiu, L. Wu, Z. Chen, Foreign body aspiration in children with negative multi-detector computed tomography results: own experience during 2011–2018, *Int. J. Pediatr. Otorhinolaryngol.* 124 (2019) 90–93.
- [2] S. Na'ara, I. Vainer, M. Amit, A. Gordin, Foreign body aspiration in infants and older children: a comparative study, *Ear Nose Throat J.* 99 (1) (2020) 47–51.
- [3] R.A. Agha, T. Franchi, C. Sohrabi, G. Mathew, A. Kerwan, A. Thoma, A.J. Beamish, A. Noureldin, A. Rao, B. Vasudevan, The SCARE 2020 guideline: updating consensus Surgical CAse REport (SCARE) guidelines, *Int. J. Surg.* 84 (2020) 226–230.
- [4] F. Orji, J. Akpeh, Tracheobronchial foreign body aspiration in children: how reliable are clinical and radiological signs in the diagnosis? *Clin. Otolaryngol.* 35 (6) (2010) 479–485.
- [5] Ö. Göktas, S. Snidero, V. Jahnke, D. Passali, D. Gregori, Foreign body aspiration in children: field report of a German hospital, *Pediatr. Int.* 52 (1) (2010) 100–103.
- [6] W. Gan, N. Xiao, Y. Feng, D. Zhou, J. Hu, S. Liu, J. Zou, Clinical analysis of tracheobronchial foreign body aspiration in children: a focus on external and intrinsic factors, *BMC Surg.* 21 (1) (2021) 1–6.
- [7] F. Pinzoni, C. Boniotti, S.M. Molinaro, A. Baraldi, M. Berlucchi, Inhaled foreign bodies in pediatric patients: review of personal experience, *Int. J. Pediatr. Otorhinolaryngol.* 71 (12) (2007) 1897–1903.
- [8] C.M. Heyer, M.E. Bollmeier, L. Rossler, T.G. Nuesslein, V. Stephan, T.T. Bauer, C. H. Rieger, Evaluation of clinical, radiologic, and laboratory prebronchoscopy findings in children with suspected foreign body aspiration, *J. Pediatr. Surg.* 41 (11) (2006) 1882–1888.
- [9] S.Y. Jung, S.Y. Pae, S.M. Chung, H.S. Kim, Three-dimensional CT with virtual bronchoscopy: a useful modality for bronchial foreign bodies in pediatric patients, *Eur. Arch. Otorhinolaryngol.* 269 (1) (2012) 223–228.
- [10] A.B. Silva, H.R. Muntz, R. Clary, Utility of conventional radiography in the diagnosis and management of pediatric airway foreign bodies, *Ann. Otol. Rhinol. Laryngol.* 107 (10) (1998) 834–838.
- [11] E. Svedström, H. Puhakka, P. Kero, How accurate is chest radiography in the diagnosis of tracheobronchial foreign bodies in children? *Pediatr. Radiol.* 19 (8) (1989) 520–522.
- [12] N. Saki, S. Nikakhlagh, F. Rahim, H. Abshirini, Foreign body aspirations in infancy: a 20-year experience, *Int. J. Med. Sci.* 6 (6) (2009) 322.
- [13] S. Ibrahim Sersar, W. Hassan Rizk, M. Bilal, M.M. El Diasty, T. Abudlla Eltantawy, B. Badry Abdelhakam, A.M.F. Elgamil, A.A. Abou Bieh, Inhaled foreign bodies: presentation, management and value of history and plain chest radiography in delayed presentation, *Otolaryngol. Head Neck Surg.* 134 (1) (2006) 92–99.
- [14] J. Liang, J. Hu, H. Chang, Y. Gao, H. Luo, Z. Wang, G. Zheng, F. Chen, T. Wang, Y. Yang, Tracheobronchial foreign bodies in children—a retrospective study of 2,000 cases in Northwestern China, *Ther. Clin. Risk Manag.* 11 (2015) 1291.
- [15] M. Mohammad, M. Saleem, M. Mahseeri, I. Alabdallat, A. Alomari, I. Qudaisat, A. Shudifat, M.N. Alzoubi, Foreign body aspiration in children: a study of children who lived or died following aspiration, *Int. J. Pediatr. Otorhinolaryngol.* 98 (2017) 29–31.
- [16] A.M. Salih, M. Alfaki, D.M. Alam-Elhuda, Airway foreign bodies: a critical review for a common pediatric emergency, *World J Emerg Med* 7 (1) (2016) 5.
- [17] C. Cutrone, B. Pedruzzi, G. Tava, E. Emanuelli, U. Barion, D. Fischetto, M. Sari, S. Narne, N. Zadra, A. Martini, The complimentary role of diagnostic and therapeutic endoscopy in foreign body aspiration in children, *Int. J. Pediatr. Otorhinolaryngol.* 75 (12) (2011) 1481–1485.
- [18] A. Boufersaoui, L. Smati, K. Benhalla, R. Boukari, S. Smail, K. Anik, R. Aouameur, H. Chaouche, M. Baghriche, Foreign body aspiration in children: experience from 2624 patients, *Int. J. Pediatr. Otorhinolaryngol.* 77 (10) (2013) 1683–1688.
- [19] A.J.M. Cataneo, D.C. Cataneo, R.L. Ruiz, Management of tracheobronchial foreign body in children, *Pediatr. Surg. Int.* 24 (2) (2008) 151–156.
- [20] O. Soysal, A. Kuzucu, H. Ulutas, Tracheobronchial foreign body aspiration: a continuing challenge, *Otolaryngol. Head Neck Surg.* 135 (2) (2006) 223–226.