



Since January 2020 Elsevier has created a COVID-19 resource centre with free information in English and Mandarin on the novel coronavirus COVID-19. The COVID-19 resource centre is hosted on Elsevier Connect, the company's public news and information website.

Elsevier hereby grants permission to make all its COVID-19-related research that is available on the COVID-19 resource centre - including this research content - immediately available in PubMed Central and other publicly funded repositories, such as the WHO COVID database with rights for unrestricted research re-use and analyses in any form or by any means with acknowledgement of the original source. These permissions are granted for free by Elsevier for as long as the COVID-19 resource centre remains active.



# Pathology and Tissue Distribution of Turkey Coronavirus in Experimentally Infected Chicks and Turkey Poults

**D. E. Gomes<sup>\*</sup>, K. Y. Hirata<sup>\*</sup>, K. Saheki<sup>\*</sup>, A. C. G. Rosa<sup>\*</sup>,  
M. C. R. Luvizotto<sup>†</sup> and T. C. Cardoso<sup>\*</sup>**

*<sup>\*</sup>Laboratory of Animal Virology, DAPSA and <sup>†</sup>Laboratory of Veterinary Pathology, DCCRA, Veterinary School, UNESP, University of São Paulo State, Clóvis Pestana Street 793, 16.050-680, Araçatuba, São Paulo, Brazil*

## Summary

Twenty 1-day-old specific pathogen free chicks and 20 1-day-old commercially derived turkey poults were inoculated with a Brazilian strain of turkey coronavirus (TCoV) to study the pathogenicity and virus distribution up to 14 days post-inoculation by histopathology, immunohistochemistry, reverse transcriptase polymerase chain reaction and sequencing. At 2–14 dpi, TCoV antigens were detected in the paranasal sinus and lachrymal accessory gland (Harderian gland) of infected chicks and in the ileum, ileocaecal junction and caecum of infected poults. Lymphocytic inflammation was present in these tissues. TCoV was re-isolated from pooled tissue suspensions of nasal concha, Harderian gland and paranasal sinus from chicks, as well as from the ileum, ileocaecal junction and caecum of poults, after three consecutive passages in 28-day-old embryonated turkey eggs. Viral RNA corresponding to the spike gene region (1178–2073 genome position) was amplified from the upper respiratory tract of chickens and from the intestinal tract of poults and phylogenetic analysis confirmed the identity as TCoV. This is the first description of TCoV antigens and mRNA in upper respiratory tissues in experimentally infected chickens.

© 2010 Elsevier Ltd. All rights reserved.

*Keywords:* apoptosis; immunohistochemistry; pathology; turkey coronavirus; viral infection

## Introduction

The Brazilian turkey industry is the second highest producer in the world and in 2008 more than 187 million carcasses were produced. In 2006, an outbreak of poult enteritis mortality syndrome (PEMS) caused by a group III coronavirus was detected for the first time (Teixeira *et al.*, 2007). Since then, the respective virus has been isolated (BR/TCoV/2006) and a partial sequence of the spike gene has been published (Cardoso *et al.*, 2008).

The primary presentation of the poult enteritis complex (PEC) is diarrhoea, restlessness and poor body condition (Guy, 1998; Cavanagh *et al.*, 2001) and where mortality and morbidity is high, the disease is classified as PEMS. PEMS has also been

described in the UK and in the USA (Culver *et al.*, 2006). PEMS associated with turkey coronavirus (TCoV) infection has been characterized as an excess or ‘spiking’ mortality of turkey poults (Brown *et al.*, 1997; Guy *et al.*, 1997), but it has been suggested that other undetected viruses or secondary infections may be associated with such high flock mortality under field conditions (Jindal *et al.*, 2009).

TCoV is closely related to infectious bronchitis virus (IBV) of chickens and TCoV has been propagated in both turkey and chicken embryos by inoculation via the amniotic route. Despite this, natural infection of chickens by TCoV has not been widely investigated. The aim of the present study was to describe the pathological changes and virus distribution in 1-day-old specific pathogen free (SPF) chicks and commercially derived turkey poults infected experimentally with a Brazilian isolate of TCoV.

Correspondence to: T.C. Cardoso (e-mail: [tcardoso@fmva.unesp.br](mailto:tcardoso@fmva.unesp.br)).

## Materials and Methods

### *Virus*

The TCoV strain (TCoV/Brazil/2006 accession number FJ188401), isolated from field cases of PEMS in 2007 (Teixeira *et al.*, 2007) and purified and characterized in 2008 (Cardoso *et al.*, 2008), was used for experimental inoculation of SPF chicks and commercially derived turkey poults. The virus was propagated in 24-day-old embryonated commercial turkey poults inoculated via the amniotic sac (Gough *et al.*, 1988). The intestines of the inoculated embryos were collected 48 h after inoculation, homogenized and clarified by centrifugation at 3,000 g for 30 min. The supernatants were filtered through 0.45 µm and then 0.22 µm syringe filters (Corning, Lowell, Massachusetts). Aliquots (1 ml) were frozen at -86°C and then thawed and used for titration before experimental inoculation. The SPF chicks were obtained from a flock that had been raised for vaccine production in Brazil (Biovet, Sao Paulo, Brazil). The birds were kept in wire cages inside high-security isolation rooms and provided with feed and water *ad libitum*.

### *Experimental Infection and Sampling*

Twenty 1-day-old SPF chicks and 20 turkey poults were inoculated with 10<sup>2.3</sup> embryo infective doses (EID<sub>50</sub>) of TCoV per bird by the oral route. The same number of birds was kept in a separate room and served as unexposed controls. The birds were observed twice daily for clinical signs of illness and five birds were killed at 2, 5, 7 and 14 days post-inoculation (dpi). After death, the bursa of Fabricius (BF), thymus, Harderian gland, nasal concha, paranasal sinus, larynx, cranial portion of the trachea, ileum, ileocaecal junction and caecum were collected and fixed in 4% paraformaldehyde, embedded in paraffin wax and sectioned (4 µm). Samples were also collected from the liver, kidney, spleen, pancreas, myocardium, lung, cerebrum and cerebellum.

### *Virus Re-isolation*

Tissue suspensions were prepared from all organs from infected and uninfected chicks and poults at each dpi. All samples were homogenized with a two-fold volume of minimal essential medium (MEM), clarified by centrifugation at 2,500 g for 20 min, and filtered twice through 0.45 µm and 0.22 µm syringe filters. Next, 28-day-old embryonated turkey eggs were inoculated with 300 µl of each tissue suspension via the amniotic sac and tissue from these embryos was harvested after 48 h. Harvested tissues were processed and propagated serially as described above for

three consecutive passages. Tissue suspensions from the third passage were processed, homogenized, clarified and filtered, and a suspension of 200 µl was kept at -86°C for detection of viral RNA by reverse transcriptase polymerase chain reaction (RT-PCR), as described previously (Teixeira *et al.*, 2007; Culver *et al.*, 2008; Guy, 2008).

### *Histopathology and Immunohistochemistry*

Paraffin wax-embedded tissues were sectioned and stained with haematoxylin and eosin (HE). The examiner was unaware of the species of bird and scored the severity of inflammation of the lesions as: -, no lesion; +/-, minimal; +, mild; ++, moderate; +++, severe. The distribution of lesions was recorded as focal, multifocal or diffuse.

Immunohistochemistry (IHC) was performed with unstained sections following dewaxing, rehydration and repeated washes in buffered saline containing 0.1% Tween 80. Immediately before the procedure the slides were treated with 4% paraformaldehyde. The slides were washed five times for 10 min on each occasion in buffered saline between each stage of the process. The immunohistochemical procedure has been previously described (Cardoso *et al.*, 2008). Positive controls consisted of tissue sections from TCoV-infected poults in which the infection had been confirmed by RT-PCR amplification. Negative controls consisted of tissues collected from uninoculated poults, for which infection status had been confirmed to be negative. The intensity of labelling in each section was scored as follows: -, no detectable antigen; +/-, weak, antigen faintly detected; +, moderate, antigen readily detected; ++, strong, intense antigen labelled; +++, widespread labelling. Photomicrographs of positively infected cells were taken with an ultraviolet Axio Imager A.1 microscope connected to an AxioCam MRc3 (Carl Zeiss Oberkochen, Germany). The micrographs were processed with Axiovision 4.7 software (Carl Zeiss).

### *Extraction of RNA and Reverse Transcriptase Polymerase Chain Reaction*

RNA was extracted from each tissue using the Pure Link<sup>®</sup> viral RNA/DNA extraction kit (Invitrogen, Carlsbad, California) following the manufacturer's instructions. The RT-PCR was performed as described previously (Teixeira *et al.*, 2007). A portion of the S2 gene was amplified using 10 pmol of primers: S2 + (1178 position in the genome) forward and S2 - (2,073 position in the genome) designed specifically for this study. The expected products were analyzed by 1.5% agarose gel electrophoresis and

visualized by staining with ethidium bromide and UV illumination.

#### *Nucleotide Sequencing and Phylogenetic Analysis*

The amplified products were purified by use of a commercial kit (Concert, Gibco-BRL, Grand Island, New York) and sequenced with both forward and reverse primers using the BigDye™ Terminator Kit (Applied Biosystems, Foster City, California) with an automated sequencer (ABI, model 377, Applied Biosystems), according to the manufacturer's instructions. Sequences were aligned using Lasergene DNASTAR (Version 7, Lasergene Corp., Madison, Wisconsin). The degree of identity among sequences at the nucleotide and amino acid levels was determined using BIOEDIT v.7.0.5. The trees were constructed using the neighbour-joining program and viewed using DNASTAR. Accession numbers for the sequences can be acquired from the GenBank public database.

## Results

#### *Experimental Inoculation of Chicks*

No clinical signs or gross lesions were seen in the chicks infected with TCoV; however, virus antigen was detected by IHC in epithelial and glandular tissue closely related to the paranasal sinus (Harderian gland) at each dpi (Fig. 1). No virus antigen was detected in the tissue of control birds. There was inflammation of moderate severity in these upper respiratory tract tissues (Fig. 1A), but no microscopical changes were found in any other tissue (Table 1). No viral RNA was detected in any tissue other than those from the respiratory tract.

#### *Experimental Inoculation of Poults*

Inoculated turkey poults developed depression and diarrhoea. The birds were stunted in growth and had 'frothy' droppings from 2–14 dpi. On post-mortem

examination, the intestines were markedly enlarged and filled with loose yellow content. The intestinal walls were flaccid and pale. The microscopical lesions were mild multifocal enteritis, predominantly at the ileocaecal junction (Fig. 2). There were differences in villus height and crypt depth between infected and uninfected poults at 2, 5, 7 and 14 dpi. IHC identified TCoV antigen at the tip and middle sections of affected villi (Table 1). Viral RNA was detected in the pooled intestinal contents and tissue suspensions of these poults at 2, 5, 7 and 14 dpi. The control poults remained negative for these parameters throughout the experiment. No microscopical alterations or viral RNA was found in any other tissue from the infected birds.

#### *Virus Recovery and Sequencing*

Viral RNA was recovered from positive tissue suspensions after the third consecutive passage in embryonated turkey embryos (Table 1). Confirmation of this was performed by amplification of 3' untranslated region of the TCoV region by RT-PCR (results not shown). After sequencing each individual positive amplified segment of S2 obtained from the upper respiratory tracts of infected chicks, no genetic difference was found between the re-isolated TCoV and 18 coronavirus sequences obtained from GenBank (Fig. 3). The resultant phylogenetic tree showed that the sequence from the present analysis aligned with a clade where it had 100% identity with the original virus strain and to two isolates from the USA (AY342356; AY342357). The accession number assigned to the present isolate is FJ957898.

## Discussion

The present study has characterized the distribution of TCoV in the tissues of experimentally infected SPF chicks and commercial turkey poults and the microscopical lesions associated with virus infection.

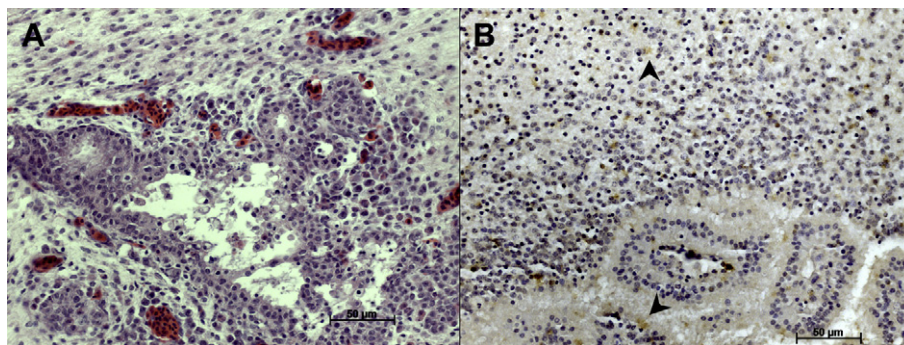


Fig. 1. (A) Inflammation within the Harderian gland of an infected chick. HE. (B) TCoV antigens in the cytoplasm of epithelial cells and in the glandular portion of chick Harderian gland at 7 dpi (arrowheads). IHC.



**Table 1**  
**Immunohistochemical and molecular detection of TCoV in infected birds**

Tissue	Chicks								Turkey poults							
	IHC (dpi)				RT-PCR (dpi)				IHC (dpi)				RT-PCR (dpi)			
	2	5	7	14	2	5	7	14	2	5	7	14	2	5	7	14
BF	-	-	-	-	-	-	-	-	-	-	-	-	-	-	-	-
Thymus	-	-	-	-	-	-	-	-	-	-	-	-	-	-	-	-
Spleen	-	-	-	-	-	-	-	-	-	-	-	-	-	-	-	-
Ileum	-	-	-	-	-	-	-	-	+++	+++	+++	+++	+	+	+	+
Ileocaecal junction	-	-	-	-	-	-	-	-	+++	+++	+++	+++	+	+	+	+
Caecum	-	-	-	-	-	-	-	-	+++	+++	+++	+++	+	+	+	+
Liver	-	-	-	-	-	-	-	-	-	-	-	-	+	+	+	+
Pancreas	-	-	-	-	-	-	-	-	-	-	-	-	+	+	+	+
Nasal concha	-	-	-	-	+	+	+	+	-	-	-	-	-	-	-	-
Paranasal sinus	-	-	++	++	+	+	+	+	-	-	-	-	-	-	-	-
Larynx	-	-	-	-	+	+	+	+	-	-	-	-	-	-	-	-
Trachea	-	-	-	-	+	+	+	+	-	-	-	-	-	-	-	-
Harderian gland	+	++	+++	+++	+	+	+	+	-	-	-	-	-	-	-	-

The amount of immunohistochemical labelling is scored as: -, no detectable antigen; +, weak labelling with antigen faintly detected; ++, moderate labelling with antigen readily detected; +++, strong labelling with intense antigen detection. RT-PCR is recorded as positive or negative.

IHC and RT-PCR were used for detection of viral antigens and genomes, respectively. Of the tissues examined, only the upper respiratory tract of chicks and the alimentary tract of poults were consistently positive for the presence of TCoV.

The pattern of virus spread and replication observed among the TCoV isolates in turkeys is different from that reported previously (Dea *et al.*, 1991; Heggens *et al.*, 1998; Ismail *et al.*, 2001, 2003). It has been reported that PEMS causes alterations in the cells of the immune system, including down-regulation of macrophage function and a reduction in expression of lymphocyte subpopulations in the thymus and spleen (Heggens *et al.*, 1998). However, in the present study there were no remarkable histological changes in the BF, thymus or spleen after infection, which is

in accordance with a previous report (Teixeira *et al.*, 2007). Moreover, in a retrospective review of previous work, the propagation of TCoV in turkey and chicken embryos via the amniotic route was documented and it was suggested that TCoV is not pathogenic to chickens; however, replication of the virus in the gut of chickens raises a question about the potential role of chickens as carriers of the virus (Adams and Hofstad, 1971; Ismail *et al.*, 2003). The possibility of TCoV replication in cells other than those of the intestinal epithelium was not addressed by these previous studies.

The Harderian gland is an abundant source of immunocompetent cells in some vertebrates, especially birds, where the Harderian glands form part of the so-called head associated lymphoid tissue (Payne, 1994). In spite of its localization (upper

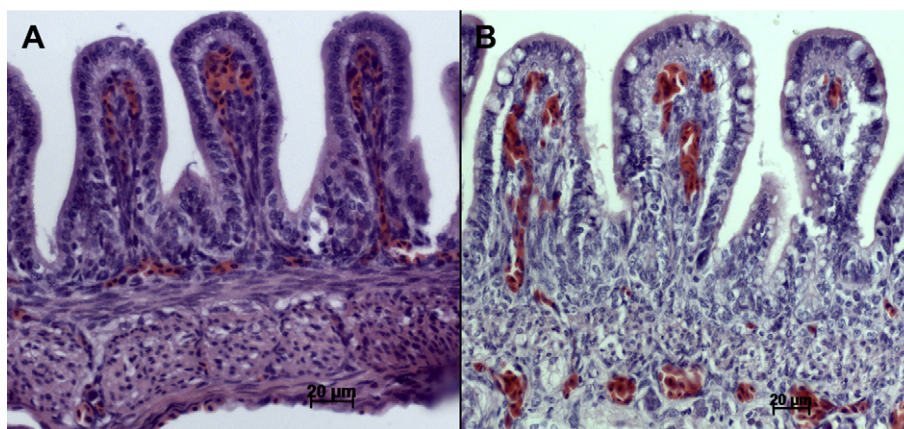


Fig. 2. Mucosa of the ileocaecal junction from (A) an uninfected turkey poult and (B) an infected poult at 7 dpi. There is evidence of inflammatory infiltration of the lamina propria in (B).

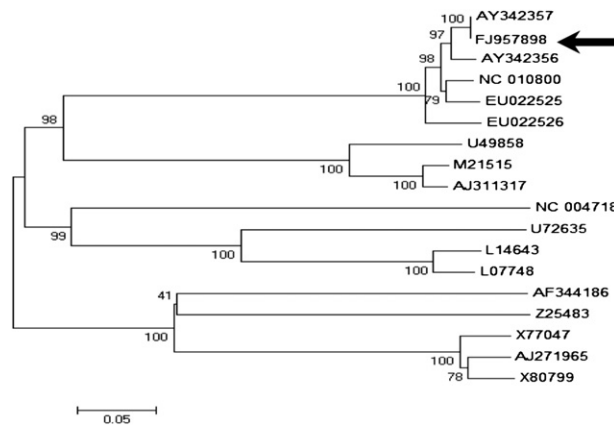


Fig. 3. Phylogenetic analysis based on the amino acid sequence of the 809 bp fragment of the spike gene of TCoV used to orally infect chicks and poults in the present study. The tree was constructed by a neighbour-joining method using Kimura's two-parameter correction and bootstrap values calculated from 1,000 trees. The TCoV recovered from respiratory and intestinal tissue suspensions identified in the present study is shown (arrow).

respiratory tract), there are large interstitial aggregates of B cells (Montgomery and Maslin, 1992). The concentration of plasma cells in the Harderian gland has been considered higher than in other avian organs (Payne, 1994). In the present study, the combination of IHC and RT-PCR demonstrated TCoV antigens and viral RNA in the Harderian gland of infected chicks. This observation supports the idea that TCoV has the ability to replicate at a low level, confirmed by virus re-isolation and subsequent sequencing of the partial spike gene; however, no clinical signs of a respiratory disorder were documented. Furthermore, no phylogenetic differences were observed between TCoV isolated in Brazil and the closely related American isolates (Breslin *et al.*, 1999a,b; Pantin-Jackwood *et al.*, 2008).

Although the avian intestinal tract is anatomically complete early in embryonic development and at hatch, the poult digestive system is still immature, which renders it vulnerable to various infectious and non-infectious agents that commonly bombard the digestive tract during brooding (Brown *et al.*, 1997). As reported previously, TCoV alone does not damage the integrity of the intestines (Guy, 2003). Other organisms may contribute to the appearance and severity of clinical signs initiated, at least in experimental trials, by TCoV infections (Ismail *et al.*, 2003). This was observed in the present study by infecting poults with TCoV isolated in Brazil, with mild microscopical lesions being documented in the ileum, ileocaecal junction and caecum. Finally, this study contains the first description of TCoV detected in the upper respiratory tract of experimentally infected chicks.

## Acknowledgments

This research was carried out with co-operation of Biovet Laboratories (São Paulo, Brazil), supported by FAPESP (grants 05/52994-3; 07/56041-6; 08/50380-6) and CNPq (grant 472226/2007-0).

## References

- Adams NR, Hofstad HS (1971) Isolation of transmissible enteritis agent of turkeys in avian embryos. *Avian Diseases*, **15**, 426–433.
- Breslin JJ, Smith LG, Fuller FJ, Guy JS (1999a) Sequence analysis of the matrix/nucleocapsid gene region of turkey coronavirus. *Intervirology*, **42**, 22–29.
- Breslin JJ, Smith LG, Fuller FJ, Guy JS (1999b) Sequences analysis of the turkey coronavirus nucleocapsid protein and 3' untranslated region identifies the virus as a close relative of infection bronchitis virus. *Virus Research*, **65**, 187–193.
- Brown TP, Garcia AP, Kelly L (1997) Spiking mortality of turkey poults: I. Experimental reproduction in isolation facilities. *Avian Diseases*, **41**, 604–609.
- Cardoso TC, Castanheira TL, Teixeira MC, Rosa AC, Hirata KY *et al.* (2008) Validation of an immunohistochemistry assay to detect turkey coronavirus: a rapid and simple screening tool for limited resource settings. *Poultry Science*, **87**, 1347–1352.
- Cavanagh D, Mawditt K, Sharma M, Drury SE, Ainsworth HL *et al.* (2001) Detection of a coronavirus from turkey poults in Europe genetically related to infectious bronchitis virus of chickens. *Avian Pathology*, **30**, 365–378.
- Culver F, Britton P, Cavanagh D (2008) RT-PCR detection of avian coronaviruses of galliforms birds (chicken, turkey, pheasants) and in parrots. *Methods in Molecular Biology*, **454**, 35–42.
- Culver F, Dziva F, Cavanagh D, Stevens MP (2006) Poult enteritis and mortality syndrome in turkeys in Great Britain. *Veterinary Record*, **159**, 209–210.
- Dea S, Verbeek A, Tijssen P (1991) Transmissible enteritis of Turkeys: experimental inoculation studies with tissue-cultured-adapted turkey and bovine coronaviruses. *Avian Diseases*, **35**, 767–777.
- Gough RE, Alexander DJ, Lister MS, Cox WJ (1988) Routine virus isolation or detection in the diagnosis of diseases of birds. *Avian Pathology*, **17**, 893–907.
- Guy JS (2003) Turkey coronavirus enteritis. In: *Disease of Poultry*, 11th Edit., YM Saif, HJ Barnes, JR Glisson, AM Fadryl, LR McDougald *et al.*, Eds., Iowa State University Press, Ames, pp. 300–307.
- Guy JS (1998) Virus infections of the gastrointestinal tract of poultry. *Poultry Science*, **77**, 1166–1175.
- Guy JS (2008) Isolation and propagation of coronavirus in embryonated eggs. *Methods in Molecular Biology*, **454**, 109–117.
- Guy JS, Barnes HJ, Smith LG, Breslin J (1997) Antigenic characterization of a turkey coronavirus identified in poult enteritis- and mortality syndrome-affected turkeys. *Avian Diseases*, **41**, 583–590.

- Heggens CL, Qureshi MA, Edens FW, Barnes HJ, Havenstein GB (1998) Alterations in lymphocytic and mononuclear phagocytic systems of turkey poults associated with exposure to pout enteritis and mortality syndrome. *Avian Diseases*, **42**, 711–720.
- Ismail MM, Cho KO, Ward LA, Saif YM (2001) Experimental bovine coronavirus in turkey poults and young chickens. *Avian Diseases*, **45**, 157–163.
- Ismail MM, Tang Y, Saif YM (2003) Pathogenicity of turkey coronavirus in turkeys and chickens. *Avian Diseases*, **47**, 515–522.
- Jindal N, Patnayak DP, Ziegler AF, Lago A, Goyal SM (2009) A retrospective study on poult enteritis syndrome in Minnesota. *Avian Diseases*, **53**, 268–275.
- Montgomery RD, Maslin WR (1992) A comparison of the gland of harder response and head-associated lymphoid tissue (HALT) morphology in chicken and turkeys. *Avian Diseases*, **36**, 755–759.
- Pantin-Jackwood MJ, Day JM, Jackwood MW, Spackman E (2008) Enteric viruses detected by molecular methods in commercial chicken and turkey flocks in the United States between 2005 and 2006. *Avian Diseases*, **52**, 235–244.
- Payne AP (1994) The harderian gland: a tercentennial review. *Journal Anatomy*, **185**, 1–49.
- Teixeira MC, Luvizotto MC, Ferrari HF, Mendes AR, da Silva SE *et al.* (2007) Detection of turkey coronavirus in commercial turkey poults in Brazil. *Avian Pathology*, **36**, 29–33.

[ Received, February 7th, 2009 ]  
[ Accepted, December 23rd, 2009 ]