

Role of Combined Vertebroplasty and Spinal Decompression in the Management of Aggressive Vertebral Hemangiomas

Abstract

Background: There are different surgical modalities designed to manage aggressive vertebral hemangioma (VH) that causes neurological symptoms. The selection of the best approach is still controversial. It is crucial to safely achieve neurological recovery with the elimination of the risk of recurrence. The combined use of surgical decompression and vertebroplasty is one of the surgical modalities that are used to manage these cases. **Patients and Methods:** From January 2012 to January 2019, nine patients with aggressive VH were retrospectively included in the study. All of them were operated upon using combined surgical decompression and vertebroplasty. We evaluated all the patients preoperatively, immediate postoperative, 1 month, and 12 months later. Clinical and radiological outcomes were assessed. **Results:** Affected spinal levels were dorsal in six cases and lumbar in three cases. There was no postoperative worsening of the preoperative neurological status. For the cases presented with sciatica, the mean VAS score has dropped from 8.33 preoperatively to 2.67 postoperatively. One month later, all of them are free from the radicular pain. For the cases presented with myelopathy, they regain their motor power in both lower limbs over a period of 4 weeks with a mean Nurick grade of 1.17. The postoperative radiological studies revealed near total occlusion of the VH with the maintenance of the vertebral body height. No clinical or radiological signs of spinal instability or recurrence are observed over the period of follow-up. **Conclusions:** The combined use of surgical decompression and vertebroplasty is considered a safe and effective modality in the management of aggressive VHs.

Keywords: Bone cement, laminectomy, vertebral hemangioma, vertebroplasty

Introduction

Vertebral hemangiomas (VH) are considered the most common benign spinal tumor that occurs in about 10%–12% of the population.^[1,2] They are described as benign vascular tumors formed from the vascular spaces that are lined with endothelium and arise within the marrow spaces.^[3] Some authors, due to the absence of aggressive histopathological criteria, have considered them as vascular malformations or hamartomas.^[4–6] They are mostly silent and discovered accidentally except for about 1% that are considered symptomatic, and when they extend beyond the vertebral body, they are called aggressive or extensive VH.^[7,8] Early presentation is usually localized pain while further symptoms develop due to neural compression secondary to vertebral body expansion, cortical erosion, fracture, epidural hematoma, or rarely

due to cord ischemia.^[9–12] The presenting symptoms depend on the tumor location and the extent of spinal cord or nerve root compression.^[13] Even in aggressive hemangiomas, the lesion keeps its benign nature with no malignant transformation.^[1]

Intervention is considered only in symptomatic lesions. Different lines are described in the literature, and the selection is still controversial.^[3,14,15] These treatment modalities include radiotherapy, endovascular embolization, alcohol injection, vertebroplasty, decompression, fixation, or even *en bloc* verteberectomy. Either single or multiple lines may be combined to achieve best therapeutic outcome.^[7,16,17]

Vertebroplasty using methyl methacrylate (MMA) has been first described in the management of VHs in the late 1980s. It was proved to produce hemostatic embolization in addition to maintain

Ebrahim Ahmed Shamhoot, Ahmed Mohammed Balaha, Ahmed Atef Ganna

Department of Neurosurgery,
Faculty of Medicine, Tanta
University, Tanta, Egypt

Address for correspondence:

Dr. Ahmed Mohammed Balaha,
Department of Neurosurgery,
Tanta University Hospitals,
El-Geesh Street, Tanta 31527,
Egypt.
E-mail: drahmedbalaha@gmail.com

Access this article online

Website: www.asianjns.org

DOI: 10.4103/ajns.AJNS_291_20

Quick Response Code:



This is an open access journal, and articles are distributed under the terms of the Creative Commons Attribution-NonCommercial-ShareAlike 4.0 License, which allows others to remix, tweak, and build upon the work non-commercially, as long as appropriate credit is given and the new creations are licensed under the identical terms.

For reprints contact: WKHLRPMedknow_reprints@wolterskluwer.com

How to cite this article: Shamhoot EA, Balaha AM, Ganna AA. Role of combined vertebroplasty and spinal decompression in the management of aggressive vertebral hemangiomas. *Asian J Neurosurg* 2020;15:919-25.

Submitted: 12-Jun-2020

Revised: 04-Aug-2020

Accepted: 01-Sep-2020

Published: 18-Oct-2020

and improve the load-bearing capacity of the vertebral body.^[16,18] In cases with neurological symptoms secondary to the extension of the lesion in the spinal canal, surgical decompression is indicated.^[7]

The aim of the present study is to evaluate the combined use of spinal decompression and vertebroplasty in the management of aggressive VH. All clinical, radiographic, and operative aspects are described.

Patients and Methods

In this study, the researchers include all patients who have been presented with neurological symptoms secondary to an aggressive solitary VH. All have been operated upon using the spinal decompression in addition to transpedicular vertebroplasty. The researchers have excluded patients with significant vertebral body destruction that require additional hardware stabilization.

This study includes nine consecutive patients; 6 females and 3 males. Age of the patients ranges between 22 and 62 years, with a mean age of 45 years. All patients have been admitted and operated at the Department of Neurosurgery, Tanta University Hospitals from January 2012 to January 2019. Patients' data have been retrospectively collected from the hospital records and operative room reports. The researchers have excluded patients with missed data from the study. Patients' data, diagnosis, and treatment outcomes are confidentially kept private and patients are presented by specific codes. Written consent has been obtained from all patients before the surgery.

The researchers collect and review the following data: Patients' age, sex, clinical presentation, affected spinal level, radiological features, operative details, and clinical outcomes.

All patients are evaluated and subjected to clinical history, general and neurological examination, and routine laboratory investigations. Preoperative clinical examination is carefully done and muscle strength of the lower limbs for each patient is carefully graded according to the motor power grading system from 0 to 5. Furthermore, each patient is assigned to a clinical grade according to the Nurick functional grading system [Table 1].^[19]

Table 1: Nurick grades

0: Signs or symptoms of root involvement but without evidence of spinal cord disease
1: Signs of spinal cord disease but no difficulty in walking
2: Slight difficulty in walking which does not prevent full-time employment
3: Difficulty in walking which prevent full-time employment or the ability to do all housework, but which is not so severe as to require someone else's help to walk
4: Able to walk only with someone else's help or with the aid of a frame
5: Chair bound or bed ridden

Radiological investigation

All patients are preoperatively radiologically evaluated using the X-ray films in both anteroposterior and lateral views, computed tomography scans (CT), and magnetic resonance imaging (MRI).

Surgical technique

All cases are operated in the prone position under general anesthesia. After confirming the affected level using the C-Arm, a midline skin incision is performed. This is followed by fascial and muscle dissection from the spinous process. A conventional laminectomy opposite to the site of spinal compression is performed. In a single case with a lesion limited to one side of the vertebral body, the researchers perform only a unilateral foraminal decompression. After ensuring adequate decompression of the neural structures, the researchers introduce the transpedicular vertebroplasty trocar needle under fluoroscopic guidance. A biopsy is obtained for all cases to exclude other possible pathologies.

Under continuous fluoroscopic guidance, the researchers inject the semi-liquid MMA bone cement through the needle into the vertebral body with direct visualization of the thecal sac to avoid intraoperative leakage and subsequent neurological damage. The aim is to fill the space of the lesion as much as possible to obliterate and shrink it [Figure 1]. Then, the researchers use the bipolar coagulation to perform further shrinkage of the epidural component followed by careful excision of coagulated parts. In two cases in which the VH invade the posterior arch of the affected vertebra, the researchers start with decompression cranial and caudal to the affected level, followed by vertebroplasty, and lastly by laminectomy of the affected level. This order is done to minimize the blood loss.

After ensuring adequate decompression of the neural structures, the wound is then closed in layers. After recovery from the anesthesia, all patients are re-evaluated

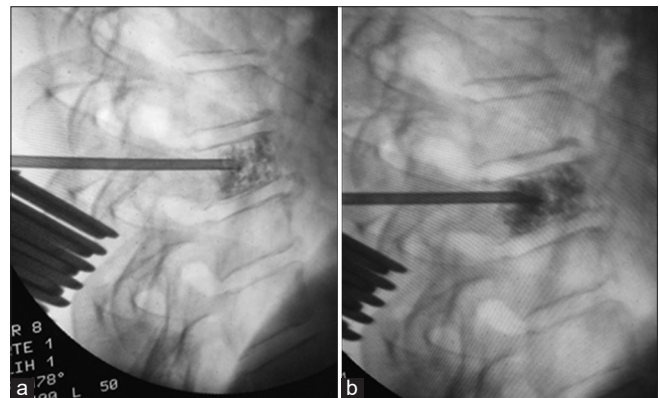


Figure 1: (a and b) Two subsequent intraoperative lateral C-Arm images showing the transpedicular needle reaching the middle of D8 vertebral body with gradual filling of vertebral hemangioma with the radiopaque methyl methacrylate to avoid leakage

clinically. The researchers start early mobilization of the patients when possible, otherwise physiotherapy program for paraparetic patients has been started immediately. Postoperative radiological evaluation using either X-ray or CT films is done to evaluate the extent of VH filling with the MMA bone cement. The patients are discharged to home after 24–48 h and followed in the outpatient clinic.

Follow-up of the patients clinically and with radiographs are done at 1 month and 12 months intervals.

Results

The present study includes 3 males and 6 females with a male:female ratio of 1:2. The age at the time of presentation ranged from 22 to 62 years with a mean of 45 years. All of them are presented with a history of progressive back pain associated lastly with neurological complaint. The mean duration of neurological complaint is 2.78 months (range 1–6 months). The neurological complaints are as follows: Unilateral sciatica in 1 patient, bilateral sciatica in 2 patients, and myelopathy in 6 patients (5 of them have subjective lower limb weakness). Three patients presented with sciatica are intact regarding the motor power in both lower limbs. Six myelopathic patients have a mean motor power grade of 3.67 (range 2–5) in both lower limbs and a mean Nurick grade of 4.33 (range 3–5).

Imaging

On examination of the radiological finding, the researchers have found that the affected spinal regions are lumbar in 3 patients and dorsal in 6 patients. Three patients have other hemangiomas, but the presenting lesion is only one in each case. The affected vertebrae are as follow: 2 cases in D6, 1 case in D7, 2 cases in D8, 1 case in D10, 1 case in L3, and 2 cases in L4. All lesions occupy significant part of the vertebral body and extend to somewhat in the spinal canal [Figures 2 and 3]. One case with L4 affection has an extension limited to the medial border of the left pedicle resulting in unilateral sciatica [Figure 5]. Of the six cases with dorsal spine affection, paraspinal extension is found in 4 of them [Figures 3 and 4].

The vertebral body height is maintained in all cases. In MRI studies, all lesions appear hypointense in T1WI and hyperintense in T2WI with the salt and pepper characteristic appearance [Figure 3]. In CT studies, most of the lesions show the typical vertical trabeculation of the VH [Figure 3].

Operative

All cases are treated using combined spinal decompression and vertebroplasty of the affected level. No significant intra or postoperative events are observed in this study. The mean intraoperative blood loss is 511.11 ml (range 300–750 ml). No mortalities are documented. The biopsies that have been obtained from all lesions reveal benign nature of the hemangiomas.

Outcome and follow-up

On recovery from the anesthesia, no worsening of the preoperative neurological status is observed. For the three cases presented with sciatica, the mean VAS score has dropped from 8.33 (range 7–10) preoperatively to 2.67 (range 1–4) postoperatively. 1 month later, all of them are free from the radicular pain.

For the six cases of myelopathy, they regain their motor power in both lower limbs over a period of 4 weeks with a mean motor power grade of 5 and a mean Nurick grade of 1.17 (range 0–2) [Figure 4]. The radiological studies that have been done postoperatively reveal near total occlusion of the VH with the maintenance of the vertebral body height [Figures 2–6]. No clinical or radiological signs of spinal instability or recurrence are observed over the period of follow-up.

Discussion

Virchow is the first one who describes the VH in 1867. Although they are considered benign vascular lesions, they may have an aggressive behavior like malignant tumors. They are found incidentally in about 10%–12% of the population. This percentage may reach 30% in female. VH may be solitary or multiple. Dorsal spine is commonly affected followed by lumbar and lastly by cervical and sacral areas. In about 1% of cases with VH, they develop symptoms as they continue growing within the bony structures of the vertebra then they have extraosseous extension either within the spinal canal or in the paraspinal region.^[20–24]

VH develops neurologic symptoms either by bony compression resulting from hypertrophy or expansion of the affected bony parts of the vertebra, soft-tissue compression secondary to VH extension into the epidural and foraminal space, pathological fracture of the affected vertebral body; and/or epidural hematoma.^[2,11,25]

There are different classification systems for VH. They commonly focus on the extension of the lesion and on the patient clinical presentations. They could be simply classified into four types or stages: Type I: Asymptomatic lesion with mild bony destruction; Type II: Localized pain with bony destruction; Type III: Asymptomatic lesion with epidural and/or soft-tissue extension; and Type IV: Neurological symptoms with epidural and/or soft-tissue extension. Both types III and IV are considered aggressive types.^[6,26]

In the present study, the researchers have selected patients that have been presented with neurological symptoms secondary to aggressive VH. In all of the cases, the normal vertebral body height is maintained. According to the previously mentioned classification, all are considered Type IV. Sixty-seven percent of cases were females. The affected spinal regions are dorsal spine in 67% of cases and lumbar

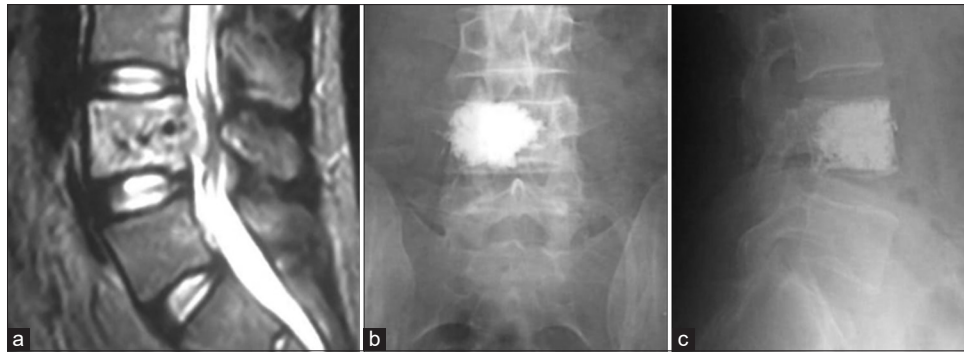


Figure 2: Case 2: Male, 55 years, bilateral sciatica, (a) Sagittal magnetic resonance imaging T2WI showed hyperintense vertebral hemangioma with salt and pepper appearance affecting L4 body with epidural extension ventral to the thecal sac, postoperative (b) anteroposterior and (c) lateral radiographs showing adequate filling with methyl methacrylate and maintained vertebral body height

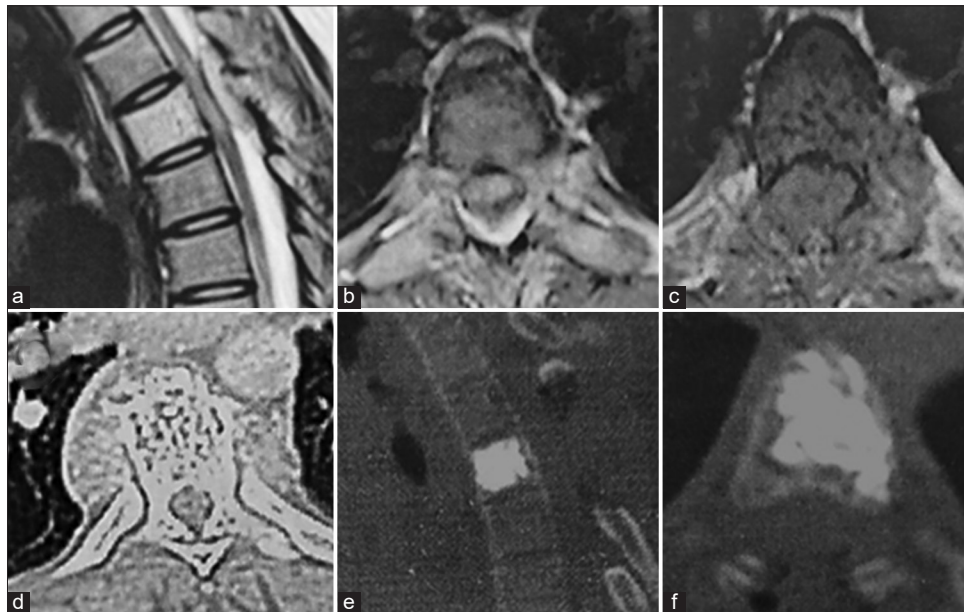

Figure 3: Case 3: Female, 22 years, myelopathic. magnetic resonance imaging (a) Sagittal T2WI, (b) Axial T1WI, (c) Axial T2WI showing vertebral hemangioma in the body of D6 eroding through both pedicles with dorsal compression of the spinal cord and with mild paraspinal extension, (d) Axial computed tomography showing vertical trabeculation of the vertebral body, postoperative (e) sagittal and (f) Axial computed tomography showing site of laminectomy and filling of the body with radiopaque methyl methacrylate

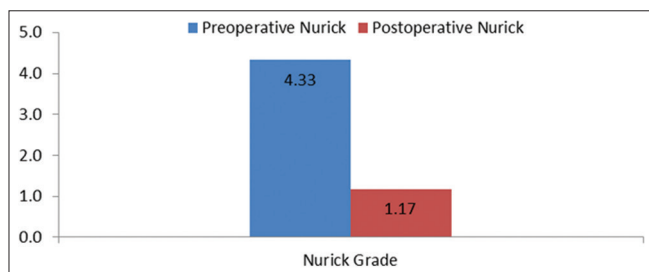


Figure 4: Graph shows the change in nurick grade for cases with myelopathy before and after surgery

spine in 33% of cases. The dorsal cases are presented with myelopathy, and the lumbar cases with sciatica. The mean duration of neurological complaint is 2.78 months (range 1–6 months) which means a slowly progressive course.

All of the cases are treated with the same technique which is combined surgical decompression combined with

vertebroplasty in the same session. Surgical decompression is admitted as all of the cases have neurological symptoms secondary to extraosseous extension of the VH. The add value of vertebroplasty is to occlude the vascular spaces of the VH, maintain the height of the vertebral body to prevent further collapse and possible pathological fracture, and to minimize the risk of recurrence. This combination is associated with mean blood loss of 511.11 ml which is considered appropriate in such procedures. No deterioration of the preoperative neurological condition or surgery-related mortality is reported.

The combination of both modalities has achieved the desired outcome in the form of decompression of the neural elements with relatively mild blood loss. Both resulted in clinical cure of the patients' symptoms, preservation and stabilization of the affected vertebral body. In addition to that, no cases of recurrence are recorded during the follow-up period.

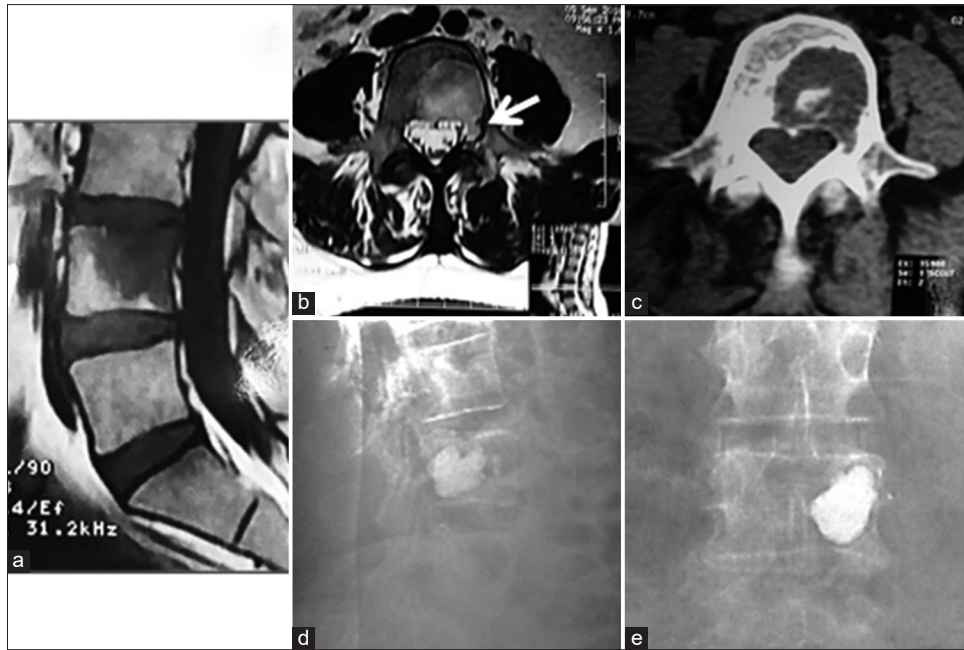


Figure 5: Case 1, female, 39 years, left sciatica, (a) sagittal magnetic resonance imaging T1WI showed hypointense vertebral hemangioma in L4, (b) axial magnetic resonance imaging T2WI show hyperintense vertebral hemangioma in the body and eroding the medial border of the left pedicle (arrow), (c) axial ct show destructive nature of the vertebral hemangioma, postoperative (d) lateral and (e) anteroposterior radiographs showing adequate filling of the vertebral hemangioma with radiopaque methyl methacrylate

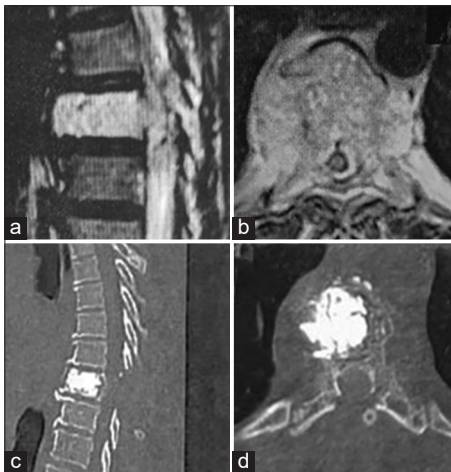


Figure 6: Case 4: Female, 38 years, Myelopathic. magnetic resonance imaging (a) sagittal and (b) Axial T2WI hyperintense vertebral hemangioma in the body of D8 with extension ventral to the cord and paraspinal extension, postoperative (c) Sagittal and (d) Axial computed tomography showing site of laminectomy and filling of the vertebral hemangioma with radiopaque methyl methacrylate

Several options are described in the literature for the management of aggressive VH. These treatment modalities include radiotherapy, endovascular embolization, vertebroplasty, transpedicular injection of absolute alcohol, surgical decompression, or any combination of those modalities. Due to the rarity of cases, the selection between these treatment lines is still controversial. The selection depends on many factors such as clinical presentation, radiological features, expected outcome, possible complication, learning curve, technical requirements, and treatment costs.^[27-29]

Surgical decompression can be done either through posterior laminectomy or through a more extensive approach in the form of corpectomy and/or spondylectomy. They are indicated in the presence of rapidly progressive or severe neurological symptoms. In spite of the beneficial effect of surgical intervention in decompressing the neural structures and alleviating the risk of recurrence, they are associated with the significant amount of blood loss and higher risk of mortality.^[3,14,16,30] They should be combined with other modalities that reduce the risk of excessive intraoperative bleeding such as endovascular embolization of the feeding arteries, or transpedicular injection of bone cement, alcohol, or glue to occlude the vascular spaces within the VH.^[27,28,31] Jiang *et al.* report intraoperative lower amount of blood loss by about 50% when combined both vertebroplasty and laminectomy.^[6]

Vertebroplasty is first invented by Deramond and coworkers in 1984. They use it in a case with C1 body aggressive VH.^[32] Vertebroplasty using MAA bone cement has proven to provide hemostasis and stabilization when done either preoperatively or intraoperatively. In patients with aggressive VH, vertebroplasty carries a risk of cement leakage through the eroded posterior vertebral wall and potential neurological complications. However, it can be safely done under direct visualization after laminectomy and with the aid of intraoperative fluoroscopy.^[7,33,34]

Radiotherapy can also be used either alone or in combination with other modalities. It can be used either before or after surgical decompression. It is used alone in mild cases without evident neurological symptoms. It

can minimize the risk of recurrence. It carries the risk of radiation-induced myelitis, radionecrosis, and secondary malignant transformation. It also does not provide structural support to the affected vertebral body which may result in pathological fracture. It can be reserved for postoperative use to minimize the risk of recurrence.^[2,35]

Ethanol injection in the VH is first used by Heiss *et al.* in 1994 to achieve the destruction of the endothelium of the hemangioma and intralesional thrombosis.^[20,36] It carries the risk of transient neurological deterioration, spinal cord injury, osteonecrosis, pathological fracture, hemodynamic instability, and asystole.^[4,36,37]

Conclusions

The researchers conclude that the combined use of both surgical decompression and intraoperative transpedicular vertebroplasty in cases with aggressive VH is considered safe and effective modality. Both result in symptom relief, improving quality of life, with no risk of recurrence or mortality. Preoperative selection of the ideal patient for this modality is crucial to achieve the desired outcome.

Financial support and sponsorship

Nil.

Conflicts of interest

There are no conflicts of interest.

References

- Dobran M, Mancini F, Nasi D, Gladi M, Sisti S, Scerrati M. Surgical treatment of aggressive vertebral hemangioma causing progressive paraparesis. *Ann Med Surg (Lond)* 2018;25:17-20.
- Fox MW, Onofrio BM. The natural history and management of symptomatic and asymptomatic vertebral hemangiomas. *J Neurosurg* 1993;78:36-45.
- Acosta FL Jr., Sanai N, Cloyd J, Deviren V, Chou D, Ames CP. Treatment of Enneking stage 3 aggressive vertebral hemangiomas with intralesional spondylectomy: Report of 10 cases and review of the literature. *J Spinal Disord Tech* 2011;24:268-75.
- Goyal M, Mishra NK, Sharma A, Gaikwad SB, Mohanty BK, Sharma S. Alcohol ablation of symptomatic vertebral hemangiomas. *AJNR Am J Neuroradiol* 1999;20:1091-6.
- Harrison MJ, Eisenberg MB, Ullman JS, Oppenheim JS, Camins MB, Post KD, *et al.* Symptomatic cavernous malformations affecting the spine and spinal cord. *Neurosurgery* 1995;37:195-205.
- Jiang L, Liu XG, Yuan HS, Yang SM, Li J, Wei F, *et al.* Diagnosis and treatment of vertebral hemangiomas with neurologic deficit: A report of 29 cases and literature review. *Spine J* 2014;14:944-54.
- Chen YL, Hu XD, Xu NJ, Jiang WY, Ma WH. Surgical treatment of compressive spinal hemangioma : A case series of three patients and literature review. *Orthopade.* 2018;47:221-22.
- Nguyen JP, Djindjian M, Gaston A, Gherardi R, Benhaiem N, Caron JP, *et al.* Vertebral hemangiomas presenting with neurologic symptoms. *Surg Neurol* 1987;27:391-7.
- Baker ND, Greenspan A, Neuwirth M. Symptomatic vertebral hemangiomas: A report of four cases. *Skeletal Radiol* 1986;15:458-63.
- Eisenstein S, Spiro F, Browde S, Allen CM, Grobler L. The treatment of a symptomatic vertebral hemangioma by radiotherapy. A case report. *Spine (Phila Pa 1976)* 1986;11:640-2.
- MANNING HJ. Symptomatic hemangioma of the spine. *Radiology* 1951;56:58-65.
- Mohan V, Gupta SK, Tuli SM, Sanyal B. Symptomatic vertebral haemangiomas. *Clin Radiol* 1980;31:575-9.
- Chen HI, Heuer GG, Zaghoul K, Simon SL, Weigele JB, Grady MS. Lumbar vertebral hemangioma presenting with the acute onset of neurological symptoms. Case report. *J Neurosurg Spine* 2007;7:80-5.
- Acosta FL Jr, Dowd CF, Chin C, Tihan T, Ames CP, Weinstein PR. Current treatment strategies and outcomes in the management of symptomatic vertebral hemangiomas. *Neurosurgery* 2006;58:287-95.
- Aich RK, Deb AR, Banerjee A, Karim R, Gupta P. Symptomatic vertebral hemangioma: Treatment with radiotherapy. *J Cancer Res Ther* 2010;6:199-203.
- Vasudeva VS, Chi JH, Groff MW. Surgical treatment of aggressive vertebral hemangiomas. *Neurosurg Focus* 2016;41:E7.
- Nigro L. Algorithm of treatment for extensive vertebral hemangiomas according to Tomita classification of vertebral tumors. *J Neurol Neurosci* 2017;8:2.
- Zapalowicz K, Skora P, Myslinski R, Karnicki F, Radek A. Balloon kyphoplasty for painful C-7 vertebral hemangioma. *J Neurosurg Spine* 2008;8:458-61.
- Nurick S. The pathogenesis of the spinal cord disorder associated with cervical spondylosis. *Brain* 1972;95:87-100.
- Doppman JL, Oldfield EH, Heiss JD. Symptomatic vertebral hemangiomas: Treatment by means of direct intralesional injection of ethanol. *Radiology* 2000;214:341-8.
- Alibai E, Taghipour M, Yadollahi G. Management of aggressive vertebral hemangioma with cord compression. *Neurology Asia* 2013;18:203-8.
- McAllister V, Kendall B, Bull J. Symptomatic vertebral haemangiomas. *Brain: A J Neurol* 1975;98:71-80.
- Hillman J, Bynke O. Solitary extradural cavernous hemangiomas in the spinal canal. Report of five cases. *Surg Neurol* 1991;36:19-24.
- Barzin M, Maleki I. Incidence of vertebral hemangioma on spinal magnetic resonance imaging in Northern Iran. *Pak J Biol Sci* 2009;12:542-4.
- Cross JJ, Antoun NM, Laing RJ, Xuereb J. Imaging of compressive vertebral haemangiomas. *Eur Radiol* 2000;10:997-1002.
- Boriani S, Weinstein JN, Biagini R. Primary bone tumors of the spine: Terminology and surgical staging. *Spine* 1997;22:1036-44.
- Prabhuraj AR, Mishra A, Mishra RK, Pruthi N, Saini J, Arvinda HR. Per-operative glue embolization with surgical decompression: A multimodality treatment for aggressive vertebral haemangioma. *Interv Neuroradiol* 2019;25:570-8.
- Templin CR, Stambough JB, Stambough JL. Acute spinal cord compression caused by vertebral hemangioma. *Spine J* 2004;4:595-600.
- Krueger EG, Sobel GL, Weinstein C. Vertebral hemangioma with compression of spinal cord. *J Neurosurg* 1961;18:331-8.
- Inoue T, Miyamoto K, Kodama H, Hosoe H, Shimizu K. Total spondylectomy of a symptomatic hemangioma of the lumbar spine. *J Clin Neurosci* 2007;14:806-9.
- Shah KC, Chacko AG. Extensive vertebral haemangioma with cord compression in two patients: Review of the literature. *Br J*

- Neurosurg 2004;18:250-2.
32. Deramond H, Depriester C, Galibert P, Le Gars D. Percutaneous vertebroplasty with polymethylmethacrylate. Technique, indications, and results. *Radiol Clin North Am* 1998;36:533-46.
 33. Atalay B, Caner H, Yilmaz C, Altinors N. Sacral kyphoplasty for relieving pain caused by sacral hemangioma. *Spinal Cord* 2006;44:196-9.
 34. Evangelopoulos DS, Kontovazenitis P, Kokkinis K, Glynos M, Korres DS, Sapkas G. Cement leakage in a symptomatic vertebral hemangioma: A case report and review of the literature. *Cases J* 2009;2:7148.
 35. Heyd R, Seegenschmiedt MH, Rades D, Winkler C, Eich HT, Bruns F, *et al.* Radiotherapy for symptomatic vertebral hemangiomas: Results of a multicenter study and literature review. *Int J Radiat Oncol Biol Phys* 2010;77:217-25.
 36. Heiss JD, Doppman JL, Oldfield EH. Relief of spinal cord compression from vertebral hemangioma by intralesional injection of absolute ethanol. *N Engl J Med* 1994;331:508-11.
 37. Yadav N, Prabhakar H, Singh GP, Bindra A, Ali Z, Bithal PK. Acute hemodynamic instability during alcohol ablation of symptomatic vertebral hemangioma: A prospective study. *J Clin Neurosci* 2010;17:810-1.