

# Retrieval of a chronically implanted leadless pacemaker within an isolated heart using direct visualization



Pierce J. Vatterott, MD,<sup>\*</sup> Michael D. Eggen, PhD,<sup>†§</sup> Alexander R. Mattson, BS,<sup>‡§</sup> Pamela K. Omdahl, MBA,<sup>§</sup> Kathryn E. Hilpisch, BS,<sup>§</sup> Paul A. Iaizzo, PhD, FHRS<sup>†‡</sup>

From the <sup>\*</sup>United Heart and Vascular Clinic, St. Paul, Minnesota, <sup>†</sup>Department of Surgery, University of Minnesota, Minneapolis, Minnesota, <sup>‡</sup>Department of Biomedical Engineering, University of Minnesota, Minneapolis, Minnesota, and <sup>§</sup>Medtronic, Mounds View, Minnesota.

## Introduction

Recent outcomes associated with the use of leadless pacemakers have shown reduced or minimal chronic complications (eg, lead infections, pocket infections, and/or lead fractures) compared with traditional leaded systems. Yet, even with fewer system complications, there have been described some circumstances in which leadless pacemaker retrievals have been performed, including elevated pacing thresholds, need for alternate therapy, pacemaker syndrome, or prosthetic valve endocarditis.<sup>1</sup> Detailed here is the retrieval of a chronically implanted leadless pacemaker in a reanimated swine heart. A superior retrieval approach was utilized and observed using direct visualization. Analysis of this multimodal imaging allows for a better understanding of the retrieval procedure and device–tissue interactions.

## Case report

This research followed the guidelines established in the Guide for the Care and Use of Laboratory Animals. A Micra single-chamber transcatheter pacing system (TPS, Medtronic, Minneapolis, MN) was implanted within the right ventricular apex of a Yorkshire-cross swine (75.2 kg). The Micra device was enveloped in a resorbable meshed coating (Vicryl, Ethicon, Somerville, NJ) prior to implant, to promote rapid encapsulation. Eight weeks post-implant, the animal's heart was recovered and reanimated with a clear Krebs-Henseleit buffer, using previously described Visible Heart

methodologies.<sup>2</sup> Endoscopic cameras (IplexFX, Olympus Corporation, Tokyo, Japan) were placed within the right atrium and right ventricle while continuous fluoroscopy was recorded (Ziehm Vision R, Ziehm Imaging, Nuremberg, Germany).

A foreign body single-loop retrieval snare (7-mm Amplatz GooseNeck Snare, Covidien Medtronic, Plymouth, MN) was advanced through the tether lumen of the Micra TPS delivery system using a superior approach via the superior vena cava. The delivery system was then placed through the right atrium, across the tricuspid valve, and into the right ventricular apex of the heart. The snare was advanced to the proximal retrieval feature of the Micra. After the snare was secured to the proximal retrieval feature, the recapture cone of the delivery system was advanced and the snare tensioned to ensure proper alignment with the retrieval tool. The Micra was subsequently pulled within the delivery system using the device cup as counter-traction. The captured device and delivery system were then removed from the heart (Figure 1 and Video in Supplemental Material).

## Discussion

Using the delivery catheter and a snare, the surgeon successfully retrieved a chronically implanted Micra leadless pacemaker from an isolated swine heart using a superior approach, which offered ease in snaring the device and, once snared, allowed the surgeon to directly and effectively apply traction and counter-traction. In this example, the pacemaker was not fully encapsulated even at 8 weeks post-implant, and thus the snare could be placed tightly around the proximal retrieval feature. During retrieval, the distal encapsulated tissue separated from the device body as it was pulled into the device cup, and this tissue remained attached to the endocardium, forming a small “sock” (Figure 1C). It is important to note that it is unknown whether these methodologies and tools are applicable for extraction of a fully encapsulated device that could potentially be composed of calcified tissue.

**KEYWORDS** Extraction; Leadless pacemaker; Micra; Retrieval; Visualization (Heart Rhythm Case Reports 2018;4:167–169)

This research was funded by a research contract with Medtronic. The sponsor had no involvement in study design, data collection/analysis/interpretation, report writing, or decision to submit for publication. Dr Iaizzo has a research contract with Medtronic; Dr Eggen, Ms Omdahl, and Ms Hilpisch are Medtronic employees; Mr Mattson has an internship with Medtronic; Dr Vatterott is a consultant with Medtronic and receives consulting and teaching fees from Spectranetics. **Address reprint requests and correspondence:** Dr Paul A. Iaizzo, 420 Delaware St SE, B172 Mayo, MMC 195, Minneapolis, MN 55455. E-mail address: [iaizz001@umn.edu](mailto:iaizz001@umn.edu).

### KEY TEACHING POINTS

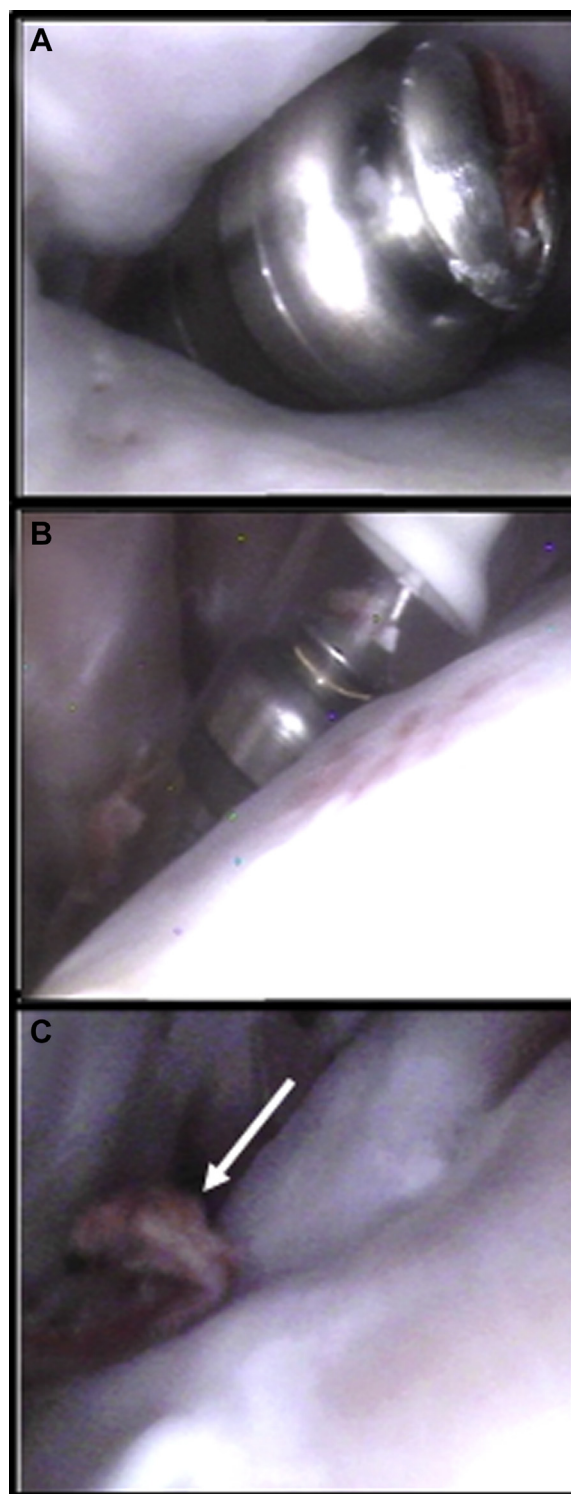
- On occasion leadless pacemakers need to be retrieved despite outcomes showing reduced or minimal chronic complications. Complications might include elevated pacing thresholds, need for alternate therapy, pacemaker syndrome, or prosthetic valve endocarditis.
- This case report shows the successful retrieval of a chronically implanted leadless pacemaker in a reanimated swine using direct visualization.
- Images presented in this case report have notable educational value for clinicians and design engineers.

As such, any required retrieval of Micra devices will not be limited to the techniques presented in this report. Indeed, snaring the proximal retrieval feature of the Micra device with the compatible 7-mm snare may not be practical in all clinical scenarios (for example, where tissue covering the retrieval feature exceeds 7 mm in diameter). In these cases, larger snares may be used in conjunction with a steerable sheath. To date, there are limited data reported for Micra retrievals. There have been 5 percutaneous retrieval attempts reported (implant time range, 5–406 days), with successful removal of 3 out of 5 devices. Of the 3 successful removals, 2 used a deflectable sheath and a larger loop snare without counter-traction (5 and 16 days), and 1 (406 days) used the techniques demonstrated in this study.<sup>3</sup> Although the techniques reported here were used to remove a Micra device at 406 days, it is unknown what the level of encapsulation was on the device and what the overall success rate will be with this technique in fully encapsulated devices. As such, the technique shown in this study is primarily intended for early retrieval cases where the proximal retrieval feature is still accessible. The flexibility of the nitinol tines has facilitated the ability to retrieve the device without counter-traction.<sup>4</sup>

Of note, there are relatively robust extraction data on the Nanostim leadless pacemaker. Nanostim retrieval success was reported as 90.4% (66 of 73 attempts; implant duration range, 1 day to 4.0 years).<sup>5</sup> Also, the reported rates of retrieval success were 86%, 93%, and 90% at <1 year, 1–2 years, and >2 years from implant, respectively. As such, the Nanostim data cannot be extrapolated to the Micra leadless pacemaker, as the fixation mechanisms and device length are not similar.

### Conclusion

In our case study, direct visualization aided in the snaring and retrieval of the device in a healthy swine heart, where there was no interaction with trabeculation or any valve structures. Snaring and retrieval may be more difficult when only utilizing fluoroscopy, as in a clinical setting, and also when



**Figure 1** A: Encapsulation is visualized at the distal end of the Micra. B: The Micra is retrieved. C: Post-extraction, the fibrous capsule remains.

considering the high levels of trabeculation occurring within the human heart. Although retrieval of a leadless pacemaker using direct visualization is not representative of the visualization techniques available in a clinical setting, the images presented here have notable educational value for both clinicians and design engineers.

## Appendix Supplementary data

Supplementary data associated with this article can be found in the online version at <https://doi.org/10.1016/j.hrcre.2017.11.014>.

## References

1. Karim S, Abdelmessih M, Marieb M, Reiner E, Grubman E. Extraction of a Micra transcatheter pacing system: first-in-human experience. *HeartRhythm Case Rep* 2016;2:60–62.
2. Chinchoy E, Soule CL, Houlton AJ, Gallagher WJ, Hjelle MA, Laske TG, Morissette J, Iaizzo PA. Isolated four-chamber working swine heart model. *Ann Thorac Surg* 2000;70:1607–1614.
3. Grubman E, Ritter P, Ellis CR, et al. Micra Transcatheter Pacing Study Group. To retrieve, or not to retrieve: System revisions with the Micra transcatheter pacemaker. *Heart Rhythm* 2017;14:1801–1806.
4. Eggen MD, Grubac V, Bonner M. Design and evaluation of a novel fixation mechanism for a transcatheter pacemaker. *IEEE Trans Biomed Eng* 2015;62:2316–2323.
5. Lakkireddy D, Knops R, Atwater B, et al. A worldwide experience of the management of battery failures and chronic device retrieval of the Nanostim leadless pacemaker. *Heart Rhythm* 2017;14:1756–1763.