

Portobiliary Fistula in a Liver Transplant Recipient Treated With an Endoscopically Deployed Fully Covered Self-Expandable Biliary Metal Stent

Fritz Murray, MD¹, Simon Buetikofer, MD¹, Philipp Dutkowski, MD², and Christoph Gubler, MD¹

¹Division of Gastroenterology, and Hepatology, University Hospital Zurich, Zurich, Switzerland

²Department of Surgery, Swiss Hepatopancreatobiliary and Transplantation Center, University Hospital Zurich, Zurich, Switzerland

ABSTRACT

Biliary complications following liver transplantations, with leaks and bile duct strictures being the most common ones, are greatly feared. Portobiliary fistulas are rare, but may cause potentially life-threatening complications. The presented case shows the first successful treatment of a portobiliary fistula by an endoscopically deployed fully covered self-expandable metal stent after liver transplantation. In accordance to the already established use in refractory bile leaks, we believe that fully covered self-expandable metal stent is a safe and efficient treatment option for portobiliary fistula.

INTRODUCTION

To date, only 2 cases of portobiliary fistulas after liver transplantation (LT) and only 6 cases related to endoscopic retrograde cholangiopancreatography (ERCP) have been reported in the literature.¹ The etiologies range from iatrogenic injuries to hepatobiliary pathologies (eg, cholangitis and stone erosion) but may also be caused by recurrent or chronic inflammatory processes and vascular pathologies.² To our knowledge, this is the first reported case of a portobiliary fistula in a liver transplant recipient treated with endoscopically deployed biliary fully covered self-expandable metal stent (FCSEMS).

CASE REPORT

A 60-year-old woman with hepatitis C-related cirrhosis complicated by recurrent hepatic encephalopathies and chronic portal vein thrombosis underwent LT with construction of an end-to-side anastomosis of the donor portal vein to the superior mesenteric vein and an end-to-end bile duct anastomosis in common technique. Because of massive venous bleeding from local varices during preparation of the recipient's hepatic artery, an iliac conduit was constructed instead. The patient recovered well after surgery with normal liver graft function.

Five months after LT, stenosis of the bile duct anastomosis with biliary leakage causing elevated liver enzymes in a cholestatic pattern was treated with a pigtail. Six weeks later, a FCSEMS was inserted because of persisting leakage with no further signs of leakage after stent extraction 3 months later. The further clinical course was complicated by hepatitis C reinfection and recurrent stenosis of the biliary anastomosis, repeatedly treated with ERCP. In a total of 10 ERCPs, 3 balloon dilatations, 4 placements of a total of 7 pigtails, and 2 stent placements were conducted. In addition, because of biopsy-proven significant fibrosis (METAVIR F3, Ishak 4) 12 months after LT, the patient was successfully treated with pegylated interferon and ribavirin over a period of 50 weeks.

Thirty-four months after LT and 29 months after the first ERCP, the patient was scheduled for an elective ERCP (#11) for biliary pigtail exchange. After recovery of 3 plastic double-pigtails, cholangiogram revealed a large portobiliary fistula at the site of the anastomosis with slight hemobilia from the papilla. During the same intervention, the decision was made to place a FCSEMS inside the bile duct to seal the

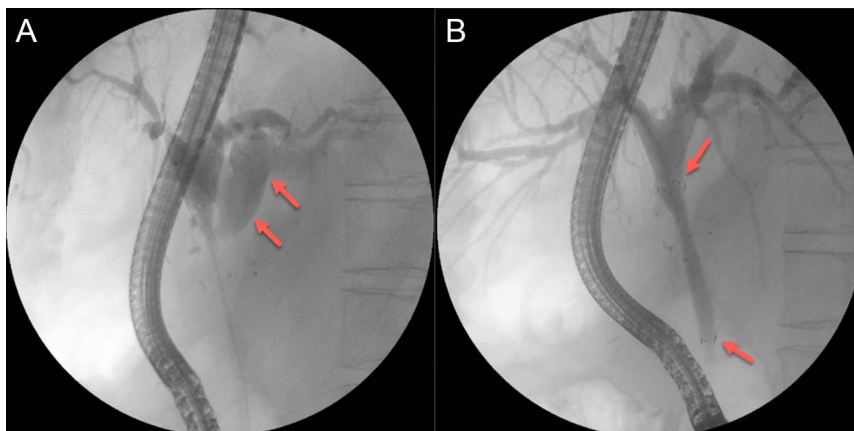


Figure 1. Cholangiogram at diagnosis. (A) Cholangiogram with contrast in the common and intrahepatic bile duct and within the left portal vein (arrows; visually almost corresponding with a regular portography). (B) Closure of the fistula by fully covered self-expandable metal stent (arrows: proximal and distal end of the stent).

leak. Consequently, a 10-mm-diameter and 4-cm-long fully covered self-expandable metal stent (FCSEMS) (Hanarostent Biliary Flap CCC; M.I. Tech Co., Ltd, South Korea) was placed with no evidence of further leakage in the subsequent cholangiogram and ceasing of hemobilia (Figure 1). Prophylactic antibiotic treatment with ciprofloxacin was established.

Forty-eight hours later, the patient presented with signs of septic shock and was admitted to the intensive care unit for hemodynamic support and empiric broad-spectrum antibiotic treatment (piperacillin and tazobactam). Computed tomography and subsequent angiography showed no evidence of persistent fistula, but revealed a chronic obliteration of the iliac conduit with partial perfusion of the hepatic artery by gastroduodenal collaterals. Because of anuric kidney failure, continuous venovenous hemofiltration was necessary for 4 days, followed by intermittent hemodialysis over the period of 1 month. Eventually, the patient recovered well and an evaluation for liver re-transplantation to treat the portobiliary fistula was discussed.

Four months later, the patient was scheduled for FCSEMS replacement (ERCP #12). Surprisingly, after extraction of the lying FCSEMS no evidence of persisting leakage on cholangiogram and no relevant stenosis was found (Figure 2). During the 50-month follow-up, no evidence of recurrent stenosis or portobiliary fistula was found, making no further endoscopic intervention necessary.

DISCUSSION

As presented, portobiliary fistulas may cause potentially life-threatening complications like cholangiosepsis. In other cases, hemobilia with anemia, elevated liver enzymes, or abdominal pain might be the leading clinical sign. Given the rarity of these fistulas, the recognition of clinical signs, or rather the awareness of the possibility of portobiliary fistulas in patients having undergone surgical and/or endoscopic interventions in close proximity of the biliary structures is of utmost importance. Hence, a detailed history taking regarding procedures involving biliary structures is essential in the case of the abovementioned clinical signs.

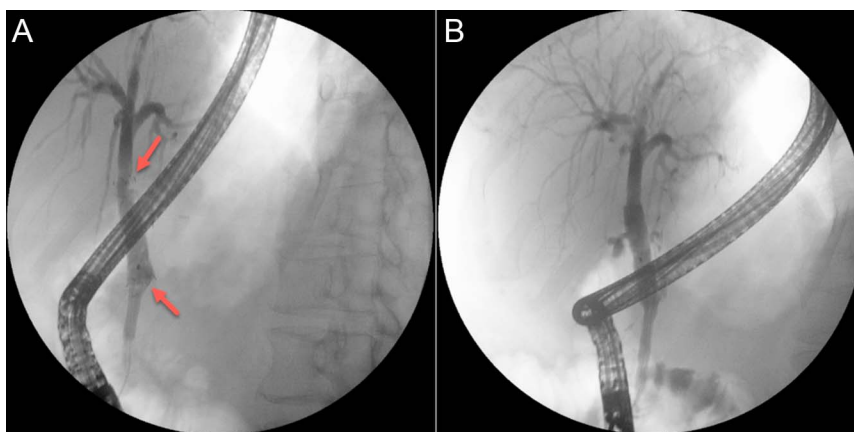


Figure 2. Follow-up cholangiogram. (A) Fully covered self-expandable metal stent (arrows: proximal and distal end of the stent) in situ. (B) Cholangiogram after stent removal without signs of fistula or stenosis.

Possible treatment strategies include medical management, balloon tamponade, coil embolization, percutaneous or transjugular stent placements, and surgical repair.¹ In addition, So et al reported a successful treatment of a portobiliary fistula with a FCSEMS.³ In their case, the fistula, caused by a biliary stent for management of obstructive jaundice in a palliative setting in a patient diagnosed with hepatocellular carcinoma, led to recurrent bacteremia and upper gastrointestinal bleeding.

In a recent review, Roos et al considered biliary complications “to be the Achilles’ heel of LT” with leaks and bile duct strictures being the most common ones. Bile duct leaks after duct-to-duct anastomosis are usually treated endoscopically by plastic stent insertion.⁴ However, in refractory cases or larger leaks, FCSEMS is frequently used.⁴ In their review, the authors did not address on the treatment of portobiliary fistulas, most likely because of the very low prevalence.

Regarding the above mentioned, ERCP in general and the use of FCSEMS in specific has been shown to be effective and safe in the treatment of biliary complications after LT. As discussed previously, we believe that an advantage of ERCP over percutaneous procedures is the use of natural orifices and the possibility to visualize the bile duct before starting the intervention resulting in increased patient safety.⁴ In addition, the complication ratio of ERCP, even if multiple interventions are necessary, is favorable compared with those of surgical interventions like hepatico-jejunostomy.⁴

The use of FCSEMS in the presented case resulted in a quick and complication-free closure of the fistula. The shown technique is unique because the stenting was conducted in the “low pressure zone” within the bile duct, not in the portal vessel. The advantage of the chosen approach is 2-fold. First, diagnosis of the fistula and its treatment were possible within 1 therapeutic procedure without the need of further delay. Second, the portal vein, representing the most important hepatic vascular structure providing 70% of the blood supply, was neither injured nor embolized. Especially in this patient with previously unknown

obliteration of the iliac conduit, an obliteration of the portal vein could have been fatal.

In summary, the presented case shows the first successful treatment of a portobiliary fistula by endoscopically deployed FCSEMS after LT. In accordance with the already established use in refractory bile leaks, we believe that FCSEMS resembles a safe and efficient treatment option for portobiliary fistula.

DISCLOSURES

Author contributions: F. Murray, S. Buetikofer, and C. Gubler designed the report. All authors collected the patient’s clinical data. P. Dutkowski provided critical revision. F. Murray and S. Buetikofer wrote the manuscript. C. Gubler is the article guarantor.

Financial disclosure: None to report.

Informed consent was obtained for this case report.

Received November 27, 2018; Accepted February 27, 2019

REFERENCES

1. Merrick B, Yue D, Sodergren MH, Jiao LR. Portobiliary fistula following laparoscopic cholecystectomy. *Ann R Coll Surg Engl.* 2016;98(7):e123-5.
2. Quinn C, Johnston SD. Portobiliary fistula at ERCP. *Gastrointest Endosc.* 2007;65(1):175-7.
3. So H, Song TJ, Lee D, et al. Endoscopic treatment of recurrent bleeding from a portobiliary fistula with a fully covered self-expandable metal stent. *Endoscopy.* 2015;47(Suppl 1):E616-7.
4. Roos FJM, Poley JW, Polak WG, Metselaar HJ. Biliary complications after liver transplantation; recent developments in etiology, diagnosis and endoscopic treatment. *Best Pract Res Clin Gastroenterol.* 2017;31(2):227-35.

Copyright: © 2019 The Author(s). Published by Wolters Kluwer Health, Inc. on behalf of The American College of Gastroenterology. This is an open-access article distributed under the terms of the Creative Commons Attribution-Non Commercial-No Derivatives License 4.0 (CCBY-NC-ND), where it is permissible to download and share the work provided it is properly cited. The work cannot be changed in any way or used commercially without permission from the journal.