

Case Report

Primary Extranodal Diffuse Large B-Cell Lymphoma of the Prostate: A Case Report

Daniel E. Ezekwudo^a Foluso Ogunleye^a Bolanle Gbadamosi^a
LeAnn M. Blankenship^a Michael Kinoyan^b Daniel Krauss^c
Mitchell Hollander^a Kristle Haberichter^d Ishmael Jaiyesimi^a

^aDepartment of Hematology and Oncology, William Beaumont Hospital, Oakland University William Beaumont School of Medicine, Royal Oak, MI, USA; ^bDepartment of Biochemistry, University of Michigan, Ann Arbor, MI, USA; ^cDepartment of Radiation Oncology, William Beaumont Hospital, Oakland University William Beaumont School of Medicine, Royal Oak, MI, USA; ^dDepartment of Pathology and Laboratory Medicine, William Beaumont Hospital, Oakland University William Beaumont School of Medicine, Royal Oak, MI, USA

Keywords

Diffuse large B-cell lymphoma · Primary prostatic lymphoma · Transurethral prostatic resection · CD20 · BCL-6 · R-CHOP

Abstract

We report a case of primary diffuse large B-cell lymphoma of the prostate in a 54-year-old Caucasian male who presented with urinary retention and benign prostatic hyperplasia. We discuss the rare presentation of this disease and its clinicopathologic features and review the literature for up-to-date information on the diagnosis and clinical management. Despite the low incidence of lymphoma involving the prostate gland, it should always be considered as part of the differential diagnosis in cases of prostate gland enlargement with urinary tract obstructive symptoms resistant to medical therapy. Treatment modalities for this rare disease are also discussed.

© 2017 The Author(s)
Published by S. Karger AG, Basel

Introduction

In the United States, prostate cancer constitutes approximately 21% of new cases of cancer among men and is the cause of 14% of all cancer death in men [1]. Prostate adenocarcinoma still represents about 90% of prostate cancer cases [1] with few incidences of lymphoma of the prostate, the majority of which are of diffuse large B-cell Non-Hodgkin subtype [2]. Non-Hodgkin lymphoma (NHL) of the prostate is classified into primary or secondary based on whether the cancer is localized to the prostate gland. Primary NHL of the prostate is characterized by the presence of an enlarged prostate at the beginning of the disease, localization of the tumor to the prostate gland, and the absence of involvement of any other tissue or lymphoid node within 1 month of diagnosis [3, 4].

Case Presentation

A 54-year-old male with a past medical history of benign prostatic hyperplasia presented with complaints of worsening urinary urgency and weak urinary stream. He was unable to void despite medical therapy, and transurethral prostatic resection (TURP) utilizing a coagulating intermittent cutting device was recommended. Physical examination was normal, and digital rectal exam showed a firm and enlarged prostate without nodular surface. An initial laboratory test showed hemoglobin of 14.5 g/dL (normal 13.5–17.5), WBC of $8.4 \times 10^9/L$ (normal 3.5–10.5), platelet count of $378 \times 10^9/L$ (normal 150–450), and serum prostate-specific antigen of 2.03 ng/mL (normal 0–4). TURP showed an enlarged prostate with a total volume of approximately 67.2 mL, with hypoechoic regions consistent with benign prostatic hyperplasia. A computerized tomography scan of the neck, chest, abdomen, and pelvis revealed diffuse urinary bladder wall thickening and an enlarged prostate, as well as a 2.4-cm soft tissue mass within the cecum involving the ileocecal valve, and no evidence of obstruction (Fig. 1). A positron emission tomography (PET) scan showed significantly increased metabolic activity in the cecum and prostate gland (Fig. 2a) and mild ^{18}F -fluorodeoxyglucose avidity within the distal esophagus. Following colonoscopy, the increased metabolic activity noted in the cecum was determined to correlate with a large tubulovillous adenoma with high-grade dysplasia and 2 smaller tubular adenomas, but no colitis or diverticulitis. The patient underwent a right ileocelectomy. No other areas of increased metabolic activity were observed.

Tissue obtained during TURP was sent for pathologic evaluation and immunohistochemical analysis and revealed prostatic tissue essentially replaced by large atypical neoplastic lymphoid cells within a background of small reactive T lymphocytes. The large atypical cells were pleomorphic with irregular nuclear contours and occasional cleaved nuclei, and prominent nucleoli were also identified (Fig. 3A). The atypical cells expressed CD20, BCL-6 (Fig. 3B), and BCL-2 (variable positivity), while lacking expression of CD5, CD10, AE1/3, EMA, P501S, and PAP. The Ki-67 proliferation index accounted for approximately 30–40% of the atypical lymphocyte population. The overall morphology and immunohistochemistry profile was noted to be diagnostic of diffuse large B-cell lymphoma (DLBCL) (Fig. 3).

Bone marrow aspiration was performed that showed polytypic B cells comprising approximately 1% of total cells and T cells without immunophenotypic aberrancy. There were no abnormalities of granulocytes or monocytes, and blasts were not increased. A bone marrow core biopsy showed normocellular marrow with adequate multilineage hematopoiesis,

no evidence of lymphoma or metastatic malignancy, and adequate iron storage. Cytogenetic examination of 20 metaphase cells revealed a normal male diploid karyotype with no consistent numerical or structural chromosome aberrations. The pathology report was consistent with the diagnosis of primary DLBCL of the prostate. The patient was treated with R-CHOP followed by radiation without any obvious complications. Posttreatment PET scans (Fig. 2b, c) showed complete remission, and the patient has been disease free for the past 2 years with continuing surveillance in our clinic.

Discussion

NHL involving the prostate accounts for 0.09% of prostate cancers and 0.1% of all NHL [5, 6]. Various subtypes of NHL of the prostate have been reported, including but not limited to follicular lymphomas, Burkitt lymphomas, mantle cell lymphomas, and mucosa-associated lymphoid tissue lymphomas; however, DLBCL remains the most common [4–7]. The majority of reported prostate NHL are secondary in origin, representing late manifestation of advanced nodal disease [8]. Based on the literature, primary extranodal lymphoma of the prostate is extremely rare, representing about 0.2–0.8% of extranodal lymphomas [9, 10], and it usually occurs in the 6th decade of life. To the best of our knowledge, our case is the only reported case of primary DLBCL of the prostate, localized only to the prostate without nodal involvement or distant metastasis. Both primary prostate lymphoma and other prostate-related conditions, such as benign prostatic hyperplasia, have similar clinical features; therefore, misdiagnosis of DLBCL is common. However, confirmation of the diagnosis can be made by flow cytometry and immunohistochemical analysis of prostatic tissue [11]. Imaging modalities such as computed tomography and magnetic resonance imaging scans are often non-specific for diagnosing DLBCL of the prostate [12]. PET is helpful in determining the metabolic ^{18}F -fluorodeoxyglucose activity in suspicious lesions and is useful in disease monitoring prior to and after treatments.

Currently, there is no consensus on therapeutic modalities for treatment of primary DLBCL of the prostate. Preceding the development of adequate chemotherapy and radiotherapy for lymphoma, a retrospective study by Bostwick et al. [4] showed a 33% five-year survival rate. While some current studies have shown excellent outcomes with anthracycline-based chemo- and radiotherapy [6], others have shown equally good outcomes with R-CHOP with or without radiotherapy. The R-CHOP regimen has shown better disease-free survival in primary DLBCL compared to disease with nodal involvement or extensive disease, after correction for the differences in the International Prognostic Index score [13].

The impressive efficacy seen with R-CHOP has been attributed to the synergistic effect of rituximab with CHOP, which enhances the chemo-sensitivity of the lymphoma cells [14]. Rituximab (Rituxin, Biogen/Genentech, San Francisco, CA, USA) is a monoclonal antibody against CD20, a highly expressed cell surface protein in DLBCL. Our patient was treated with an R-CHOP regimen followed by 36 Gy of fractionated radiotherapy to the prostate and entire seminal vesicles (18 fractions of 2 Gy). He had an excellent response to treatment with complete resolution of urinary symptoms. Successful management of localized DLBCL with radiotherapy alone has also been reported [15]. Early studies reported that 73% of patients with primary prostate lymphoma developed metastasis within 1–59 months following diagnosis [5], thus necessitating the need for closer surveillance during this period. Although the prognostic outlook for primary DLBCL of the prostate is determined by histological type and stage of the disease, curative response to chemotherapy has been well documented [15].

Conclusion

Primary extranodal lymphomas of the prostate, although a rare entity, can occur in men in their 6th decade of life. Including primary prostate lymphoma in the differential diagnosis of patients with obstructive urinary symptoms is imperative due to similar clinical features to other prostate-related conditions, such as benign prostatic hyperplasia. Despite the lack of consensus on the choice of treatment modality, based on currently available data R-CHOP with or without radiotherapy remains the standard of care for DLBCL. Posttreatment surveillance, especially within the first 5 years when disease relapse is most common, and enrollment in a clinical trial when available is highly recommended.

Statement of Ethics

The patient provided informed consent.

Disclosure Statement

The authors have no conflicts of interest to declare.

Funding Sources

This research did not receive any specific grant from funding agencies in the public, commercial, or not-for-profit sectors.

References

- 1 American Cancer Society: Cancer Facts and Figures 2016. Atlanta, American Cancer Society, 2016.
- 2 Chu PG, Huang Q, Weiss LM: Incidental and concurrent malignant lymphomas discovered at the time of prostatectomy and prostate biopsy: a study of 29 cases. *Am J Surg Pathol* 2005;29:693.
- 3 Yong RH, Srigley JR, Amin MB, et al: Tumors of the Prostate Gland, Seminal Vesicles, Male Urethra, and Penis. *Atlas of Tumor Pathology: Third Series, Fascicle 28*. Washington, DC, Armed Forces Institute of Pathology, 2000, pp 111–177.
- 4 Bostwick DG, Iczkowski KA, Amin MB, et al: Malignant lymphoma involving the prostate: report of 62 cases. *Cancer* 1998;83:732.
- 5 Freeman C, Berg JW, Cutler SJ: Occurrence and prognosis of extranodal lymphomas. *Cancer* 1972;29:252.
- 6 Sarris A, Dimopoulos M, Pugh W, et al: Primary lymphoma of the prostate: good outcome with doxorubicin-based combination chemotherapy. *J Urol* 1995;153:1852.
- 7 Patel DR, Gomez GA, Henderson ES, et al: Primary prostatic involvement in non-Hodgkin lymphoma. *Urology* 1988;32:96.
- 8 Iczkowski KA, Lopez-Beltran A, Sakr WA: Haematolymphoid tumours of the prostate; in Eble JN, Sauter G, Epstein JI, et al (eds): *World Health Organization Classification of Tumours: Pathology and Genetics of Tumours of the Urinary System and Male Genital Organs*. Lyon, World Health Organization International Agency for Research on Cancer, 2004.
- 9 Wazait HD, Al-Buheissi SZ, Dudderidge T, et al: Rare case of primary lymphoma of the prostate: giving the patient the benefit of the doubt. *Urol Int* 2003;71:338.
- 10 Petrakis G, Koletsa T, Karavasilis V, et al: Primary prostatic lymphoma with components of both diffuse large B-cell lymphoma (DLBCL) and MALT lymphoma. *Hippokratia* 2012;16:86.
- 11 Warrick JI, Owens SR, Tomlins SA: Diffuse large B-cell lymphoma of the prostate. *Arch Pathol Lab Med* 2014;138:1286.

- 12 Rao RN, Bansal M, Raghuvanshi S, et al: Diffuse large B-cell non Hodgkin lymphoma of the prostate presenting with urinary outlet obstruction: a case report. *Urol Ann* 2015;7:100.
- 13 Kroll ADG, Le Cessie S, Snijder S, et al: Primary extranodal non-Hodgkin's lymphoma (NHL): the impact of alternative definitions tested in the Comprehensive Cancer Center West population-based NHL registry. *Ann Oncol* 2003;14:131.
- 14 Coiffier B, Lepage E, Briere J, et al: CHOP chemotherapy plus rituximab compared to CHOP alone in elderly patients with diffuse large B cell lymphoma. *N Engl J Med* 2002;346:235.
- 15 Fukutani K, Koyama Y, Fujimori M, et al: Primary malignant lymphoma of the prostate: report of a case achieving complete response to combination chemotherapy and review of 22 Japanese cases. *Nippon Hinyokika Gakkai Zasshi* 2003;94:621.

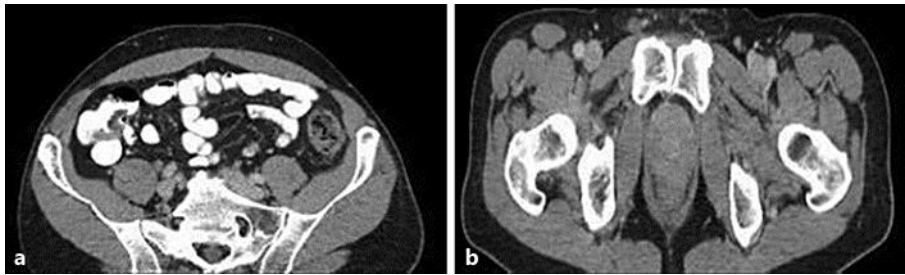


Fig. 1. Computed tomography scan of the abdomen/pelvis showing cecal mass (a) and enlarged prostate (b). The scan shows a prostatic space-occupying lesion with unclear rectal boundaries and an absence of the bladder seminal vesicle angle.

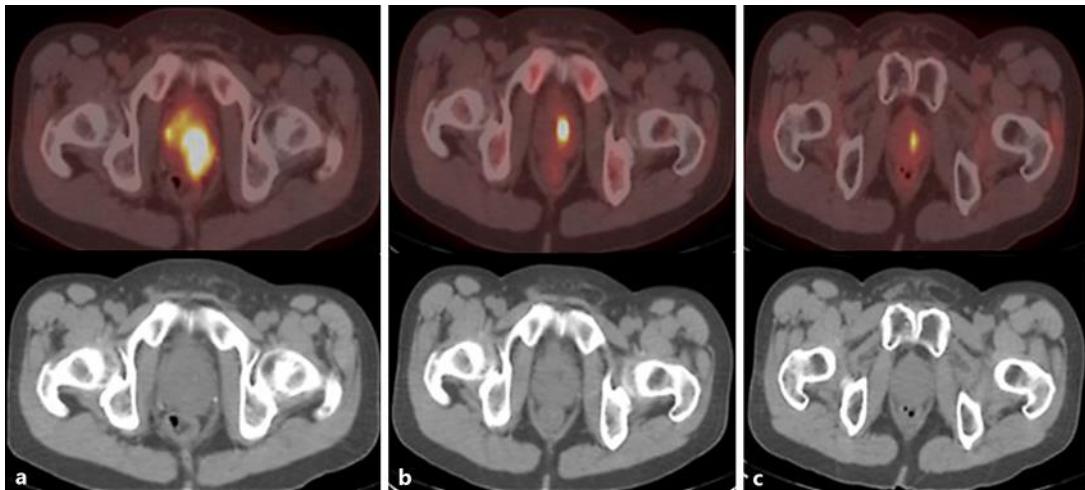


Fig. 2. Positron emission tomography scan showing increased uptake in the prostate prior to therapy (a) and decreased metabolic activity following treatment (b) and 12 months after therapy (c).

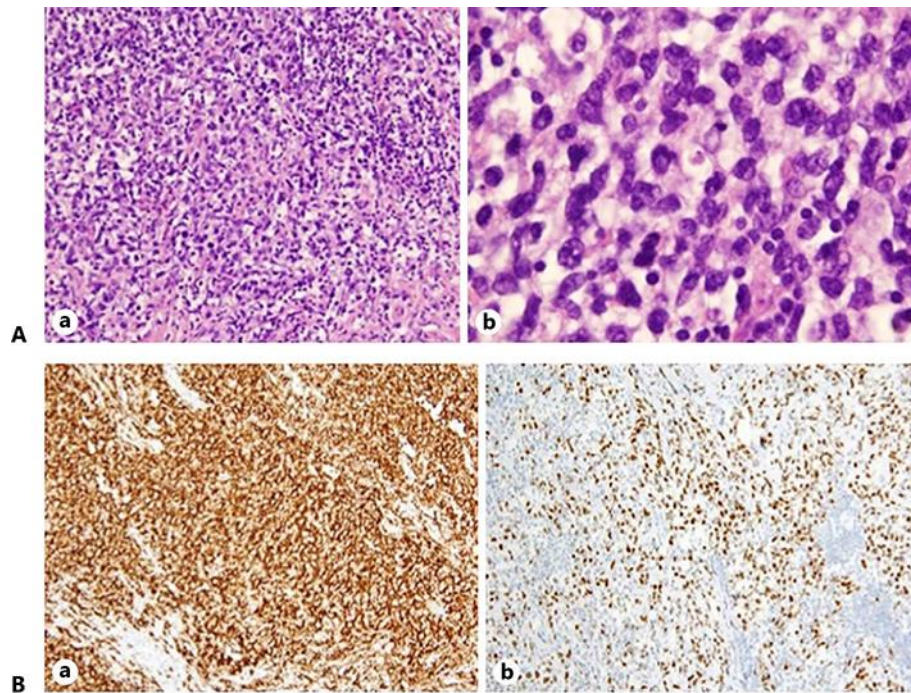


Fig. 3. A The prostate transurethral resection specimen was remarkable for a diffuse infiltrate of large atypical lymphoid cells and background small mature lymphocytes (**a**). The large atypical cells consisted of a mixture of immunoblast-like and centroblast-like cells that replaced the normal prostate parenchyma (**b**). (Hematoxylin and eosin at 200× magnification.) **B** Immunohistochemical staining of the large atypical lymphoid cells showed diffuse positivity with CD20 (**a**) and BCL-6 (**b**). Overall, the immunohistochemical staining patterns were consistent with a diagnosis of diffuse large B-cell lymphoma. (Both images at 200× magnification.)